



Original Article

Surgical repair of Tetralogy of Fallot following primary palliation: Right ventricular outflow track stenting versus modified Blalock-Taussig shunt

Hamid Bigdelian^a, Mehdi Ghaderian^b, Mohsen Sedighi^{c,*}^a Department of Cardiovascular Surgery, School of Medicine, Isfahan University of Medical Science, Isfahan, Iran^b Pediatric Cardiology Research Center, Isfahan Cardiovascular Research Institute, Isfahan, Iran^c Department of Neuroscience, Faculty of Advanced Technologies in Medicine, Iran University of Medical Sciences, Tehran, Iran

ARTICLE INFO

Article history:

Received 21 February 2018

Accepted 20 June 2018

Available online 24 June 2018

Keywords:

Cardiac catheterization

Tetralogy of Fallot

Thoracic surgery

Infant

Low birth weight

ABSTRACT

Background: Tetralogy of Fallot (TOF) is a cyanotic disease requiring early intervention. We assessed the effect of right ventricular outflow tract (RVOT) stenting versus modified Blalock-Taussig shunt (mBTS) on outcomes of surgical repair of TOF.

Methods: Fifteen palliated TOF infants underwent complete repair surgery. RVOT stenting was performed in seven infants and mBTS was done in eight infants. Data on sequential patients who underwent surgery were collected and reviewed retrospectively.

Results: Stenting group were significantly younger (1.62 ± 0.34 vs 2.80 ± 0.52 , $p = 0.001$), had lower body weight (3.28 ± 0.48 vs 5.03 ± 0.67 , $p = 0.001$) and lesser body surface area (0.20 ± 0.01 vs 0.26 ± 0.02 , $p = 0.001$) than the mBTS group at palliation. Mean right pulmonary artery (RPA) diameter in stenting group at palliation was 2.9 ± 0.54 mm (z-score -3.08 ± 0.97) and increased at surgery to 4.6 ± 0.49 mm (z-score -0.79 ± 0.66) ($p = 0.001$). The mean left pulmonary artery (LPA) diameter was 2.5 ± 0.42 mm (z-score -3.3 ± 0.86), which increased to 3.3 ± 0.40 mm (z-score -2.2 ± 0.74) at surgery ($p = 0.005$). The mean RPA diameter in mBTS group at palliation was 3.2 ± 0.32 mm (z-score -2.9 ± 0.70) and increased at surgery to 4.3 ± 0.55 mm (z-score -1.1 ± 0.94) ($p = 0.001$). The mean LPA diameter was 2.8 ± 0.26 mm (z-score -3.3 ± 0.62), which increased to 3.2 ± 0.24 mm (z-score -2.4 ± 0.52) at surgery ($p = 0.032$). Repeat echocardiography showed significant increase in McGoon ratio and Nakata index in both groups ($p = 0.001$). No significant differences were seen between the two groups regarding surgical procedure and postoperative complications.

Conclusion: RVOT stenting is a safe and effective approach instead of mBTS in hazardous TOF infants with hypercyanotic spell, small PAs and complex anatomies.

© 2018 Published by Elsevier B.V. on behalf of Cardiological Society of India. This is an open access article under the CC BY-NC-ND license (<http://creativecommons.org/licenses/by-nc-nd/4.0/>).

1. Introduction

Tetralogy of Fallot (TOF) is the most common cyanotic cardiac anomaly and was among the first congenital heart diseases (CHD) to be both palliated and repaired successfully. Surgical repair or palliation is often needed to relieve cyanosis during the newborn period but carries an increased risk of mortality, particularly in high-risk infants of small size and those having genetic disorders or other comorbidities [1–3].

Traditionally, the modified Blalock-Taussig shunt (mBTS) has been the treatment of choice for improvement of pulmonary blood flow in infants with TOF, but is a challenging procedure in cyanotic

patients with tet spells and low birth weight [4]. RVOT stenting is an alternative for infants with hazardous symptoms which offers advantages such as cyanosis stabilization, improvement of pulmonary arteries (PAs) circulation and the option of elective surgery in the future [5]. We undertook this research to describe and compare our surgical experiences with TOF repair following primary palliation by RVOT stenting and mBTS with particular emphasis on the outcomes of subsequent surgery.

2. Materials and methods

2.1. Patient population

This retrospective study was carried out between May 2015 and October 2016 on 18 infants with TOF, who were admitted at our

* Corresponding author.

E-mail address: Sedighi1984@yahoo.com (M. Sedighi).

center and underwent corrective surgery. This study was approved by the local Ethics Committee and informed consent was obtained from all individuals. Doppler and two-dimensional (2D) echocardiography and clinical evaluation were done routinely by the pediatric cardiologist before and after catheterization and surgery. Medical records, echocardiographic and surgical data were reviewed retrospectively to compare variables between groups. Measurements of the PAs diameter were made using echocardiographic imaging and the z-scores were calculated based on the body surface area (BSA)-adjusted z-scores using data published by Detroit Children's Hospital [6].

The cases for all infants were discussed at the multidisciplinary cardiac meeting and the final decision for palliation or single-stage repair was taken according to the criteria outlined below. The indicators for two-stage repair and primary palliation were active cyanosis, low birth weight, (<5 kg) with or without spells and PAs of small size (McGoon ratio <1.5; Nakata index $\leq 120 \text{ mm}^2/\text{m}^2$). Accordingly, premature infants with severe RVOT stenosis and hypercyanotic spells ($\text{SpO}_2 \leq 70$) underwent RVOT stenting ($n = 7$) and infants with PA stenosis and appropriate baseline saturation were selected for mBTS ($n = 8$).

2.2. Procedural details

All cardiac catheterizations were performed under mild anaesthesia with fluoroscopic guidance. Catheterization was done through the right femoral venous approach. The patients were given 100 IU/kg of heparin in two doses (50 IU/kg first and 50 IU/kg half hour later) to maintain an activated clotting time of >200 s after catheterization. Prophylactic intravenous antibiotic with 30 mg/kg of cefazolin was administered at the beginning of the procedure and in two subsequent doses every 8 h during the following 24 h. A 4-F catheter was advanced through a sheath into the right ventricle (RV) and a 0.14 guide wire was passed across the RVOT into the main PA. After stabilization of the guide wire, balloon angioplasty of the RVOT and the main PA was performed to alleviate the difficulties of stent implementation into the RVOT (Fig. 1). The stents were selected based on the size of the infants, RVOT infundibular length and anticipated length of palliation. Peripheral stents with nominal diameters that were 1–2 mm greater than the annular dimension were selected and implanted in the RVOT. The stents were 6–7 mm in diameter and 12–16 mm in

length. Post-stenting angiography was done before catheter removal and indicated a remarkable increase in pulmonary blood flow and oxygen saturation.

In the mBTS group, after induction of general anaesthesia, expanded polytetrafluoroethylene grafts were placed from the proximal brachial artery to the ipsilateral right or left PA through the standard thoracotomy approach. The diameter of the shunts was determined by the infant weight and size. The median shunt diameter in the mBTS group was 3.5 mm (3.5 to 4.0 mm).

2.3. Statistical analysis

All statistical analyses were done using IBM SPSS ver. 22.0 (IBM; USA). Continuous variables are presented as mean \pm standard deviation. The two-tailed student *t*-test was used to identify statistically significant differences among these data points. Categorical variables are presented as frequency (percentage) and were analyzed using the Fisher's exact test. All *p*-values of less than 0.05 were considered to indicate statistical significance.

3. Results

3.1. Demographic data

Table 1 shows that the study population consisted of 8 (53.3%) males and 7 (46.7%) females ($p = 0.315$). The cardiac comorbidities were double-outlet right ventricle (DORV), PA stenosis, atrioventricular septal defect (AVSD) and ventricular septal defect (VSD). Infants who underwent single-stage repair and infants with concomitant coronary anomalies ($n = 3$) were excluded from the study. Patients in the RVOT stenting group were significantly younger (1.62 ± 0.34 vs 2.80 ± 0.52 ; $p = 0.001$), had lower weights (3.28 ± 0.48 vs 5.03 ± 0.67 ; $p = 0.001$) and BSA (0.20 ± 0.01 vs 0.26 ± 0.02 ; $p = 0.001$) than the mBTS group. Moreover, infants in the stenting group had severe RVOT stenosis with hypercyanotic spells while infants in mBTS group showed PA stenosis without spells and low saturation. The mean oxygen saturation increased from 70% to above 89% after palliation and was maintained above that. Further postoperative echocardiography revealed two cases of infundibular pulmonary stenosis (IPS) in the stenting group who underwent subsequent catheterization and balloon dilatation.

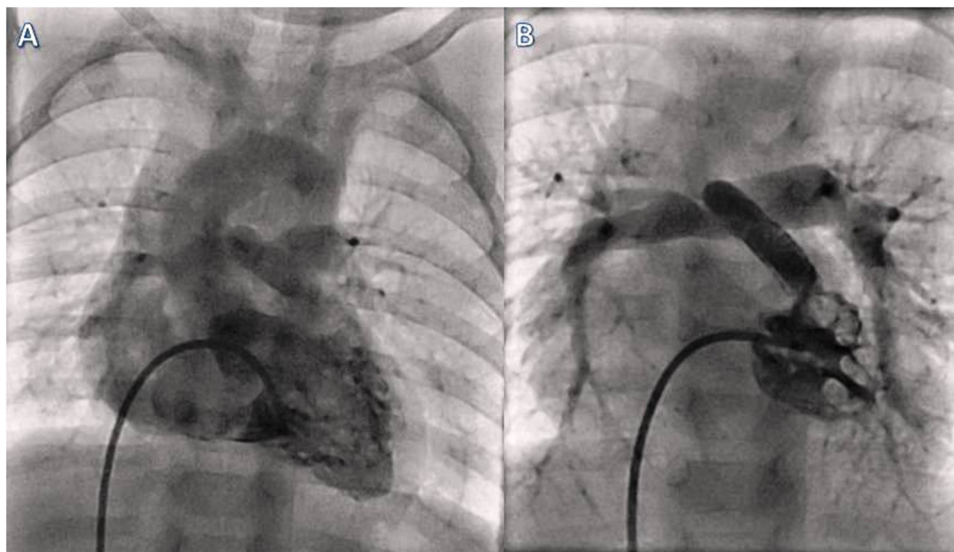


Fig. 1. Right ventricular injection in anteroposterior view from the same patient before (A) and after (B) right ventricular outflow tract stenting shows significant resolved stenosis and increased pulmonary artery flow.

Table 1
Demographic, clinical and paraclinical data of patients at palliation and surgery time.

Patient No	Age (month)	Gender	Weight (kg)	BSA (m ²)	Diagnosis	Tet spells	Hb1 (mg/dl)	O ₂ SAT1 (%)	Procedure	Hb2 (mg/dl)	O ₂ SAT2 (%)
1	1.5	Female	2.5	0.22	TOF	Yes	20.3	66	RVOT stent	16.2	91
2	2	Male	3.5	0.22	TOF/PS/VSD	"	18.4	65	"	14.5	86
3	1	Female	3.5	0.20	TOF	"	20.1	69	"	16.5	87
4	1.6	Female	2.5	19.0	TOF	"	20.9	70	"	17.0	94
5	1.8	Female	3.5	0.23	TOF	"	19.9	65	"	16.8	85
6	1.5	Female	3.9	0.19	TOF/DORV	"	18.5	64	"	14.5	89
7	2	Male	3.6	0.21	TOF	"	19.2	65	"	15.6	94
8	3	Male	5.1	0.26	TOF	No	18.5	77	mBTS	14.9	90
9	3.5	Male	5.5	0.26	TOF/AVSD	"	17.7	72	"	14.0	87
10	3	Female	5.9	0.29	TOF	"	18.1	75	"	14.5	85
11	2	Female	4	0.25	TOF	"	17.9	68	"	15.0	90
12	3	Female	5.3	0.27	TOF/PS/VSD	"	18.8	79	"	15.9	93
13	3	Male	4.9	0.25	TOF/DORV	"	19.0	76	"	16.1	89
14	2	Male	4.1	0.23	TOF	"	19.1	77	"	15.7	92
15	2.9	Male	6	0.29	TOF	"	18.6	75	"	16.2	88

BSA: Body Surface Area, TOF: Tetralogy of Fallot, PS: pulmonary stenosis, VSD: ventricular septal defect, DORV: double outlet right ventricle, AVSD: atrio-ventricular septal defect, RVOT: right ventricle outflow track, mBTS: modified Blalock Taussig shunt.

3.2. Pulmonary arteries growth

The mean pulmonary valve dimension in stenting group was 3.7 ± 0.7 (z-score: -7.01 ± 1.7) versus 4.2 ± 0.4 (z-score: -7.0 ± 1.0) in the mBTS group ($p = 0.119$). As Table 2 shows, the mean diameter of the right pulmonary artery (RPA) in the stenting group was 2.9 ± 0.54 mm at palliation and increased to 4.6 ± 0.49 mm at repair time ($p = 0.001$; z-score: -3.08 ± 0.97 vs -0.79 ± 0.66 ; $p = 0.001$).

Likewise, the mean diameter of the left pulmonary artery (LPA) at palliation time was 2.5 ± 0.42 mm increased to 3.3 ± 0.40 mm ($p = 0.005$) (z-score: -3.3 ± 0.86 vs -2.2 ± 0.74 ; $p = 0.027$). The mean diameter of the RPA in the mBTS group was 3.2 ± 0.32 mm at palliation and increased to 4.3 ± 0.55 mm at repair time ($p = 0.001$; z-score: -2.9 ± 0.70 vs -1.1 ± 0.94 ; $p = 0.002$). The mean diameter of the LPA was 2.8 ± 0.26 mm at palliation and increased to 3.2 ± 0.24 mm ($p = 0.032$; z-score: -3.3 ± 0.62 vs -2.4 ± 0.52 ; $p = 0.021$). Moreover, the average McGoon ratio before palliation was 0.82 ± 0.04 in the stenting group versus 0.99 ± 0.12 in the mBTS group. The mean Nakata PA index in the stenting group was 90 ± 6.4 mm²/m² versus 112.7 ± 6.1 mm²/m² in the mBTS group.

At repair time, the McGoon ratio increased to 1.4 ± 0.04 and 1.5 ± 0.18 in the stenting and mBTS group, respectively ($p = 0.001$). The Nakata PA index increased to 126.9 ± 9.7 mm²/m² in the stenting group and 146 ± 8.9 mm²/m² in the mBTS group

($p = 0.001$). As depicted in Fig. 2, the PAs z-score index showed a remarkable increase after palliation in both groups, but was slightly more desirable in the stented infants.

3.3. Surgical repair and complications

All infants underwent complete repair surgery six months subsequent to palliation involving the establishment of a cardiopulmonary bypass (CPB) and midline sternotomy. In the stenting group, stent removal was done completely in four infants. One infant with a diminutive PA in the mBTS group received RV-PA conduit because of undeveloped PA after the mBTS. In another case, a small portion of the stent was preserved in place to avoid damage to the surrounding cardiac tissue. In the mBTS group, shunt closure was done successfully in all infants. Three infants had mBTS on the right side and four on the left side. One infant underwent bilateral mBTS. One infant experienced stenosis at the site of shunt anastomosis that was relieved at the time of repair.

Four infants in stenting group and five infants in mBTS group (57.1% vs 62.5%) received a transannular patch (TAP). In two cases in the stenting group, the stents were placed in the PA valve pathway. There were no significant differences between groups regarding the TAP rate, aortic cross-clamp (ACC) and CPB time, intubation and ICU stay. However, the operation time was slightly more prolonged in the shunt group due to cardiac tissue adhesion.

Table 2
Comparison of pulmonary arteries variables at palliation and surgery time.

Variables	Palliation time	Range	Surgery time	Range	p value
RVOT stent (n = 7)	2.9 ± 0.54	2.1 - 3.5	4.6 ± 0.49	4-5.2	0.001
RPA diameter	-3.08 ± 0.97	-4.6 to -2	-0.79 ± 0.66	-1.6 to 0.0	0.001
RPA Z-Score					
LPA diameter	2.5 ± 0.42	1.9 - 3.1	3.3 ± 0.40	2.8-3.8	0.005
LPA Z-Score	-3.3 ± 0.86	-4.7 to -2.2	-2.2 ± 0.74	-3.3 to -1.3	0.027
McGoon ratio	0.82 ± 0.04	0.79 - 0.92	1.45 ± 0.04	1.40 - 1.53	0.001
Nakata index	90.0 ± 6.4	83.1 - 98.6	126.9 ± 9.7	112 - 145.6	0.001
mBTS (n = 8)	3.2 ± 0.32	2.9 - 3.8	4.3 ± 0.55	4 - 5	0.001
RPA diameter	-2.9 ± 0.70	-3.8 to -2.05	-1.1 ± 0.94	-1.6 to -0.25	0.002
RPA Z-Score	2.8 ± 0.26	2.5 - 3.1	3.2 ± 0.24	2.8 - 3.5	0.032
LPA diameter					
LPA Z-Score	-3.3 ± 0.62	-4.1 to -2.5	-2.4 ± 0.52	-3.2 to -1.8	0.021
McGoon ratio	0.99 ± 0.12	0.79 - 1.11	1.5 ± 0.18	1.4 - 1.96	0.001
Nakata index	112.7 ± 6.1	104 - 167	146.1 ± 8.9	140 - 167	0.001

RVOT: right ventricle outflow track, RPA: right pulmonary artery, PLA: left pulmonary artery, mBTS: modified Blalock Taussig shunt. Continues data are presented as Mean \pm Standard Deviation.

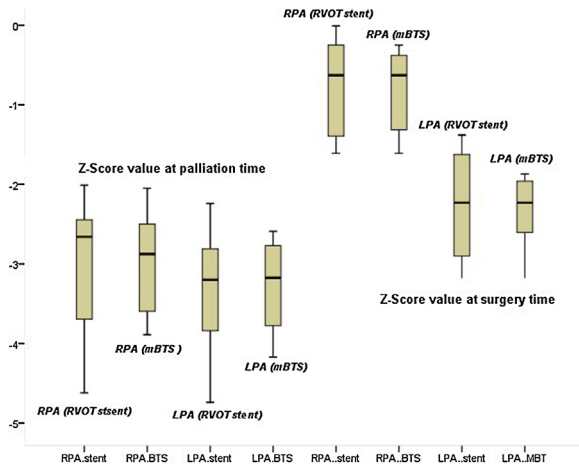


Fig. 2. Pulmonary arteries growth based on Z-Score index at the time of palliation and surgery, *P < 0.05.

There was one early death in the stenting group because of prematurity and acute respiratory distress syndrome (ARDS) after palliation. One infant in mBTS group died from endocarditis and sepsis five days after surgery (Table 3). No complications, such as shunt failure or occlusion, stent fracture, postoperative tachycardia, complete heart block, bleeding or RV failure, were observed.

4. Discussion

TOF is the common form of cyanotic CHD and represents about 6% of congenital morbidities. The presence and degree of cyanosis in this condition depend on the degree of RVOT obstruction and PAs development. There are various types of anatomical features in TOF that have different clinical and hemodynamic outcomes. For many years, staged surgical repair of the TOF has been a standard approach, especially in high-risk infants with low ages and weights and complex anatomies. Accordingly, infants with TOF who have complications such as critical RVOT obstruction, PA hypoplasia and the presence of major aortopulmonary collateral artery

(MAPCA) are candidates for primary palliation as a first step to avert hypoxia, improvement of oxygen saturation and PAs development until the complete repair [2,7–9].

After the introduction of mBTS, this surgical approach has been performed extensively and has rescued the lives of numerous infants with TOF. However, mBTS palliation is associated with serious problems, particularly shunt thrombosis and decreased pulmonary blood flow that increases the chance of sudden death and morbidity. The young age, low weight, small PAs diameter and complex cardiac anatomy of the infants are major risk factors for shunt failure.

Table 3
Clinical data of patients at surgery time.

Variable ^{a,b}	RVOT stenting (n = 7)	mBTS (n = 8)	p value
ACC time (min) ^a	111.8 ± 27.5	89.3 ± 20.3	0.093
CPB time (min)	165.5 ± 49.4	129.2 ± 38.5	0.134
TAP ^b	4 (57.1%)	5 (62.5%)	0.622
IPS	2(28.6%)	0	0.200
Mortality	1(14.3%)	1(12.5%)	0.733
ICU stay (hour)	94.4 ± 4.2	94.3 ± 3.9	0.980

ACC: aortic cross-clamp. CPB: cardiopulmonary bypass, TAP: transannular patch, IPS: infundibular pulmonary stenosis, ICU: intensive care unit.

^a Continues data are presented as Mean ± Standard Deviation.

^b Categorical data are presented as Frequency (Percentage).

Nevertheless, shunt occlusion due to shunt failure is a relatively rare life-threatening condition [10,11]. In our series, the majority of infants who underwent mBTS had favorable PAs growth and showed no sign of shunt failure and occlusion before complete repair. On the other hand, there is no possibility for shunting in infants with underdeveloped PAs who experience hypercyanotic spells during the neonatal period. RVOT stenting was introduced as a substitute for primary palliative or corrective surgery in high-risk infants. RVOT stenting increases the PAs blood flow, improves systemic saturation and ameliorates hemodynamic conditions. More importantly, RVOT stenting enables symmetric growth of both PA branches, which may be asymmetric in mBTS [7,12–16].

Our findings are consistent with those of others studies that report remarkable growth of both PAs after either palliative approach (p < 0.05), which was valuable in high-risk cases, especially those with tet spells [3,5,8,17]. Despite the advantages of RVOT stenting over mBTS, early palliation in symptomatic infants increases the chance of requiring TAP at repair time. More importantly, infants with RVOT stents may be at risk for RV-PA conduits, which is a major limitation of stenting and will likely require future surgery. In our series, similar to other investigations, there were no significant differences between RVOT stenting and mBTS regarding TAP requirement, ACC time, CPB time and postoperative complications [5,18]. The present study had some limitations. Firstly, this retrospective study included a small number of infants who underwent complete surgical repair of TOF following primary palliation. Hence, the statistical analyses may not have sufficient power to support a definitive conclusion in favor of palliation. Secondly, as in previous studies, a longer follow-up time is needed to assess PAs growth and RVOT function.

5. Conclusion

Our outcomes support the assertion that RVOT stenting is a safe and valuable approach for use in place of mBTS in infants who exhibit hazardous TOF symptoms with hypercyanotic spells, underdeveloped PAs and complex anatomies. Moreover, RVOT stenting improved oxygen saturation, increased the z-score of both PAs and noticeably decreased the spells until surgical repair was possible. There is no doubt that single-stage repair can successfully be done in stable and non-cyanotic TOF cases, but RVOT stenting as a primary palliation is a safe and effective procedure for high-risk TOF cases to avert the risks of mBTS.

Financial support

Nil

Conflict of interest

None declared.

References

1. Bigdelian H, Mardani D, Sedighi M. The effect of pulmonary valve replacement (PVR) surgery on hemodynamics of patients who underwent repair of Tetralogy of Fallot (TOF). *J. Cardiovasc. Thorac. Res.* 2015;7:122–125.
2. Bigdelian H, Sedighi M. Repair of Tetralogy of Fallot in infancy via the atrioventricular approach. *Korean J Thorac. Cardiovasc. Surg.* 2016;49:9–14.
3. Castleberry CD, Gudausky TM, Berger S, Tweddell JS, Pelech AN. Stenting of the right ventricular outflow tract in the high-risk infant with cyanotic teratology of Fallot. *Pediatr. Cardiol.* 2014;35:423–430.
4. Barron DJ. Tetralogy of Fallot: controversies in early management. *World J. Pediatr. Congenit. Heart Surg.* 2013;4:186–191.
5. Barron DJ, Ramchandani B, Murala J, et al. Surgery following primary right ventricular outflow tract stenting for Fallot's tetralogy and variants: rehabilitation of small pulmonary arteries. *Eur. J. Cardiothorac. Surg.* 2013;44:656–662.

6. Pettersen MD, Du W, Skeens ME, Humes RA. Regression equations for calculation of z-scores of cardiac structures in a large cohort of healthy infants, children, and adolescents: an echocardiographic study. *J. Am. Soc. Echocardiogr.* 2008;21:922–934.
7. Dryżek P, Moszura T, Górczny S, Michalak KW. Stenting of the right ventricular outflow tract in a symptomatic newborn with tetralogy of Fallot. *Postępy w Kardiologii Interwencyjnej*. *Adv. Interv. Cardiol.* 2015;11:44.
8. Mortezaeian H, Meraji M, Naghibi M, et al. Long-term outcome of the right ventricular outflow tract palliation procedure in children with cyanotic congenital heart disease: a case-series study. *Res. Cardiovasc. Med.* 2016;5:e31948.
9. Kim H, Sung SC, Chang YH, et al. Outcome of staged repair of Tetralogy of Fallot with pulmonary atresia and a ductus-dependent pulmonary circulation: should primary repair be considered? *Korean J Thorac. Cardiovasc. Surg.* 2011;44:392.
10. Stanley PH, Chartrand C, Davignon A, et al. Palliative surgery in tetralogy of Fallot. *Can. J. Surg. J. canadien de chirurgie.* 1981;24:475–479.
11. Yuan SM, Shinfeld A, Raanani E. The Blalock-Taussig shunt. *J. Cardiac. Surg.* 2009;24:101–108.
12. Laudito A, et al. Right ventricular outflow tract stent as a bridge to surgery in a premature infant with tetralogy of Fallot. *Ann. Thorac. Surg.* 2006;81:744–746.
13. Dryzek P, Mazurek-Kula A, Moszura T, Sysa A. Right ventricle outflow tract stenting as a method of palliative treatment of severe tetralogy of Fallot. *Cardiol. J.* 2008;15:376–379.
14. Shenoy A, Padmakumar P, Subashchandra V. Right ventricular outflow tract stenting in tetralogy of fallot with restrictive ventricular septal defect. *J. Invasive Cardiol.* 2006;18:E59–60.
15. Zeidenweber CM, Kim DW, Vincent RN. Right ventricular outflow tract and pulmonary artery stents in children under 18 months of age. *Catheter. Cardiovasc. Interv.* 2007;69:23–27.
16. Bigdelian H, Sedighi M. The role of preoperative sildenafil therapy in controlling of postoperative pulmonary hypertension in children with ventricular septal defects. *J. Cardiovasc. Thorac. Res.* 2017;9:179–182.
17. Hirsch JC, Mosca RS, Bove EL. Complete repair of tetralogy of Fallot in the neonate: results in the modern era. *Ann. Surg.* 2000;232:508–514.
18. Kanter KR, Kogon BE, Kirshbom PM, Carlock PR. Symptomatic neonatal tetralogy of Fallot: repair or shunt? *Ann. Thorac. Surg.* 2010;89:858–863.