

Received: 2013.07.20  
Accepted: 2013.07.24  
Published: 2013.10.02

## Double superior vena cava on fistulogram: A case report and discussion

Authors' Contribution:  
Study Design A  
Data Collection B  
Statistical Analysis C  
Data Interpretation D  
Manuscript Preparation E  
Literature Search F  
Funds Collection G

ABCDEF 1 **Chad J. Cooper**  
BDEF 2 **Anwar Soliman Gerges**  
BDEF 2 **Emmanuel Anekwe**  
BDEF 1 **German T. Hernandez**

1 Department of Internal Medicine, Texas Tech University Health Sciences Center, El Paso, TX, U.S.A.  
2 Universal Vascular Center, El Paso, TX, U.S.A.

**Corresponding Author:** Chad J. Cooper, e-mail: [chad.cooper@ttuhsc.edu](mailto:chad.cooper@ttuhsc.edu)

**Patient:** Female, 50  
**Final Diagnosis:** Double superior vena cava  
**Symptoms:** —  
**Medication:** —  
**Clinical Procedure:** —  
**Specialty:** Nephrology

**Objective:** Anatomical anomaly/variation





**Background:** Superior vena cava anomalies are caused by variations in the development of the embryonic thoracic venous system. Duplication of the superior vena cava is a rare anomaly with an incidence in the general population of 0.3%. The majority of cases are asymptomatic and diagnosed incidentally by imaging done for another reason.

**Case Report:** A fifty year old female patient presented to our care with a history of end stage renal disease that has been recently started on dialysis. Procedures performed included a fistulogram, PermaCath placement and angiogram of internal jugular vein. Angiogram was done and showed that the patient has a good sized cephalic vein which is wide open and mild to moderate stenosis at the subclavian area which proved to be a dual superior vena cava.

**Conclusions:** Double SVC is a rare congenital anomaly. The literature available on this congenital anomaly is sparse. The majority of cases are diagnosed incidentally on imaging for other reasons, which can alert the physician of other congenital abnormalities that will need further work up. However, these venous anomalies should be recognized, as they can have significant clinical implications, especially during central venous catheter placement, radiofrequency ablation, pacemaker insertion or coronary artery bypass graft.

**Key words:** dialysis catheter • dual superior vena cava • fistulogram

**Full-text PDF:** <http://www.amjcaserep.com/download/index/idArt/889589>

 687   1  6

## Background

The superior vena cava (SVC) is a large vein that delivers deoxygenated blood from the upper half of the body to the right atrium. It is formed by the left and right brachiocephalic veins. Superior vena cava anomalies are rare occurrences caused by variations in the development of the embryonic thoracic venous system. Many anatomical variations could be possible due to the complex nature of these developmental stages. The anomalies that involve the superior vena cava include the persistent left superior vena cava with or without the right superior vena cava, absence of superior vena cava, hypoplasia of the superior vena cava, and abnormal opening of the superior vena cava into the left atrium, coronary sinus, azygous venous system, and the pulmonary vein [1]. The presence of double superior vena cava can be alone or with other congenital anomalies. Some of the conditions that have been described include horseshoe kidney, absence of left brachiocephalic vein, univentricular heart, double coronary sinus, conduction tissue anomalies, common atrium, atrioseptal defect, transposition of great vessels, and dextrocardia [1].

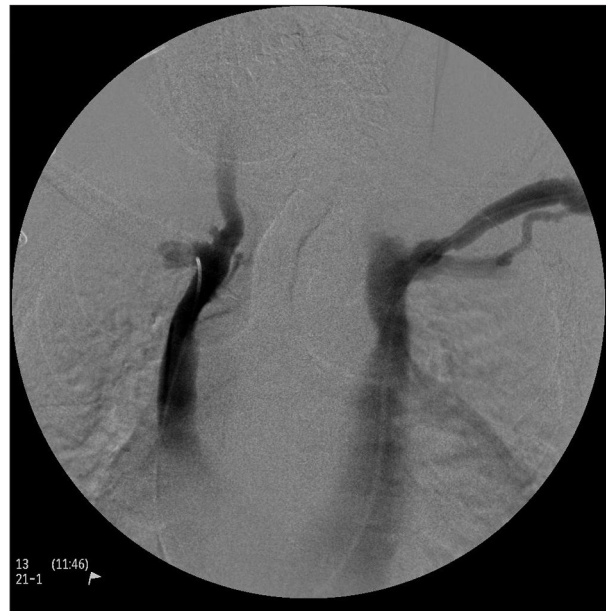A double superior vena cava with a persistent left superior vena cava is rarely encountered but is the most common venous anomaly in the setting of SVC, with a frequency of between 0.3% and 1.3%, and it usually drains into the coronary sinus [2]. Double SVC is usually asymptomatic unless other cardiac anomalies exist. The incidence of double SVC in the general population is 0.3% whereas in patients with an associated congenital heart disease it varies between 10–11% [3]. The majority of cases are clinically silent and are diagnosed incidentally by imaging done for other reasons.

## Case Report

We hereby present a 50 year old female with a history of end stage renal disease who has been recently started on dialysis. She has a left upper fistula but was advised to seek our care due to difficult cannulation. A fistulogram, PermaCath placement and angiogram of internal jugular vein were performed. The angiogram revealed a good sized cephalic vein that is wide open and mild to moderate stenosis at the subclavian area which later proved to be a double superior vena cava (Figure 1). Afterwards, a PermaCath was placed in the right internal jugular. No other cardiac anomalies were found. No complications occurred during the procedure.

## Discussion

The gold standard for the definitive diagnosis of double SVC is usually discovered with invasive angiography. A double SVC



**Figure 1.** Fistulogram – double superior vena cava.

may also be incidentally diagnosed at surgery or autopsy and may be a cause of widened mediastinum on chest radiography. When encountered there should be an investigation of other possible congenital defects should be sought with echocardiogram, magnetic resonance imaging (MRI) or a CT scan. A double superior vena cava may make it difficult for internal jugular or subclavian venous catheterization, radiofrequency ablation, pacemaker insertion or coronary artery bypass graft [4]. If a right to left shunt is present then cyanosis, sepsis and cerebral abscess may possibly occur.

When a double superior vena cava is ascertained by these diagnostic techniques and if other congenital anomalies are discovered then comprehension of the risks related to catheterization and selection of a safe route should be considered [5]. A double SVC may account for aberrant appearances while positioning a central venous catheter placed from the left side of the body. It is safer to have a definite venous access with the help of ultrasound guidance. The injection of contrast will help delineate the venous anatomy when a variation in the venous anatomy is suspected [6].

## Conclusions

Double SVC is a rare congenital anomaly. The literature available on this congenital anomaly is sparse. The majority of cases are diagnosed incidentally on imaging for other reasons, which can alert the physician of other congenital abnormalities that will need further work up. However, these venous anomalies should be recognized, as they can have significant clinical implications, especially during central venous catheter placement or during surgical procedures in the chest.

## Disclosures

All participated authors in this study declare no financial,

professional or personal conflicts. No grant support was received for this case report. All Authors were involved in manuscript preparation and literature review.

## References:

---

1. Fabian FM, Gesase AP, Ngassapa DN: Double superior vena cava presenting with anomalous jugular and azygous venous systems. *Indian Heart J*, 2008; 60: 352–58
2. Chen M, Ma Ji, Xu G, Ying Z: Double superior vena cava with a persistent left superior vena cava. *The Japanese Society of Intern Med*, 2008; 47: 679–80
3. Albay S, Cankal F, Kocabiyik N et al: Double superior vena cava. *Morphologie*, 2006; 90: 39–42
4. Arguder E, Celenk MK, Gumus B, Koksak A: A case with double vena cava superior discovered during the investigating of persistent cough. *Tuberk Toraks*, 2012; 60: 199–200
5. Limura A, Oguchi T, Shibata M et al: Double superior vena cava and anomaly of cardiovascular system with a review of the literature. *Okajimas Folia Anat Jpn*, 2011; 88: 37–42
6. Brown R, Shyamkumar NK: Double superior vena cava with a persistent left superior vena cava: an incidental finding during peripherally inserted central catheter placement. *Australas Radiol*, 2007; 51: B257–59