




Successful Management of a Rare Gastric Mucormycosis Presenting with Massive Melena in a Polytrauma Patient

This article was published in the following Dove Press journal:
International Medical Case Reports Journal

Hanna Jung 
Gun Jik Kim 
Tak-hyuk Oh 

Department of Thoracic and
Cardiovascular Surgery, Kyungpook
National University Hospital, Kyungpook
National University School of Medicine,
Daegu, Republic of Korea

Abstract: Mucormycosis is a rare, life-threatening, and opportunistic fungal infection that usually occurs in immunocompromised patients. Rhinocerebral and pulmonary manifestations are the common form. The rare form of gastrointestinal mucormycosis occur in all parts of the alimentary tract, with emphasis on the stomach being the most common site. Primary gastric mucormycosis following traumatic injury is an extremely rare form that is usually lethal; thus, only a few cases of survival have been reported even after early diagnosis and aggressive surgical resection, combined with antifungal treatment. We herein report a case of delayed-onset gastric mucormycosis in a polytrauma patient without predisposing factors, which was successfully treated by antifungal medical therapy alone with no surgical debridement.

Keywords: antifungal antibiotics, fungal infection, melena, mucormycosis, multiple trauma

Introduction

Mucormycosis is a rare and lethal invasive fungal infection that usually occurs in severely immunocompromised hosts. Primary gastric mucormycosis after trauma is exceedingly rare. Gastric mucormycosis is histologically classified into colonization, infiltration, and vascular invasion types, and vascular invasion has the poorest prognosis.^{1,2} The current management is antifungal therapy, if feasible since surgical debridement is the mainstay of treatment. Our case is unique because trauma, with no other underlying risk factor or medical condition, may have predisposed the patient to invasive fungal disease with massive melena. We encountered a special case of infiltrative gastric mucormycosis with massive melena, which was managed by appropriate transfusion, hemostatic agent, and antifungal therapy without surgical debridement.

Case Report

A 41-year-old woman with no relevant medical history was transferred to our emergency department after a vehicular accident. On arrival, the patient was in a state of stupor with Glasgow coma scale 9, with a blood pressure of 37/21 mmHg, a heart rate of 112 beats per minute, and undetectable peripheral saturation. Five minutes after arrival, cardiac arrest occurred, which required us to perform cardiopulmonary cerebral resuscitation (CPCR). Chest computed tomography showed hemopericardium due to cardiac rupture, leading to cardiac tamponade. After the

Correspondence: Tak-hyuk Oh
Department of Thoracic and
Cardiovascular Surgery, Kyungpook
National University Hospital, Kyungpook
National University School of Medicine,
130 Dongdeok-ro, Jung-gu, Daegu 41944,
Republic of Korea
Tel +82-53-200-5665
Fax +82-53-426-4765
Email ohhidongii@gmail.com

recovery of spontaneous circulation, emergency exploration was planned, and in the operation room, another 10 minutes of CPR was performed during sternotomy. The operative findings were rupture of the right atrium and left hemothorax. Eight hours later, emergency reexploration was performed due to mediastinal bleeding. The bleeding was controlled, but the patient's vital signs remained unstable, indicating acute kidney injury and right heart failure; general edema was severe, and the central venous pressure was 30 cmH₂O due to massive transfusion and volume overload resuscitation. Therefore, continuous renal replacement therapy was necessary to treat the acute renal injury, and extracorporeal membrane oxygenation (ECMO) support was required to maintain her rapidly deteriorating vital signs. On postoperative day (POD) 1, ECMO was removed; on POD 3, the patient was extubated, and dialysis was stopped. She was recovering well, and was transported from the intensive care unit to the general ward in POD 4. The patient's recovery in the general ward was uneventful, but on POD 16, she suddenly had massive melena (~1500 mL) without prodromal

symptoms such as abdominal pain or nausea. The patient underwent emergency esophagogastrosopy, which revealed a large amount of ulceration with bloody discharge at the greater curvature of the fundus to the mid-body (Figure 1).

Biopsy was performed, and the esophagogastrosopy was completed by the administration of an epinephrine spray and a massive infusion of sodium alginate (Lamina G solution; Taejoon Pharm Co., Ltd., Seoul, Korea). During melena, the patient's body temperature was normal, her C-reactive protein was not elevated, and only the white blood cell count had increased (17,470 cells/mm³). Three days later, the pathology report of the biopsy revealed fungal hyphae consistent with gastric mucormycosis (Figure 2), and intravenous liposomal amphotericin B (5 mg/kg), was started.

The antifungal agent was administered for 8 weeks, and the patient's melena gradually resolved. In the follow-up esophagogastrosopy on POD 24, a large active ulceration formed without bleeding. There was no evidence of melena relapse or abnormal abdominal symptoms. Stool output was

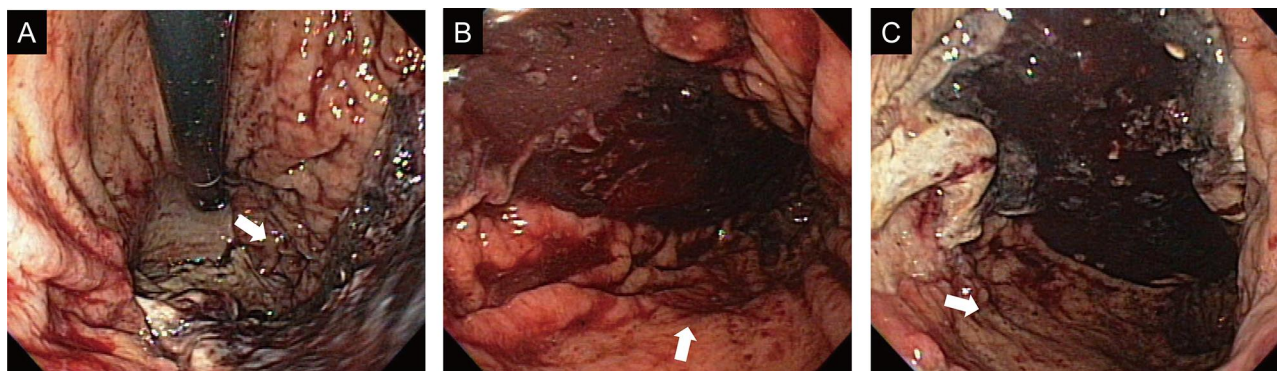


Figure 1 Endoscopic images after melena episode. Large amount of ulcerations with bloody discharge at the greater curvature of the fundus to the mid-body (A–C, white arrow).

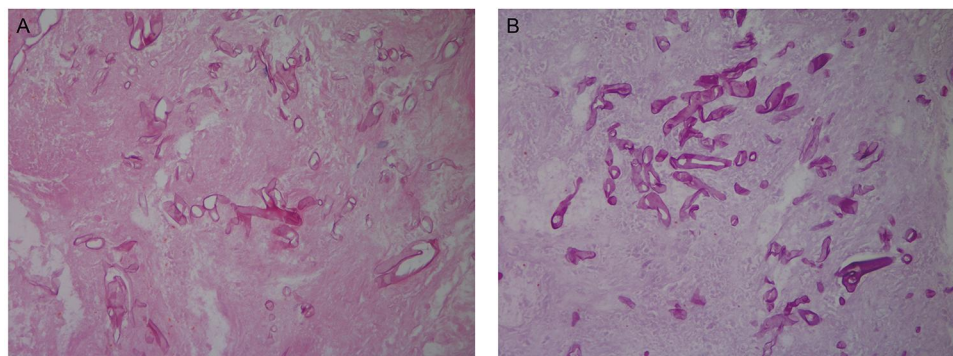


Figure 2 Microscopic findings of the gastric ulcer showing numerous nonseptate fungal hyphae. (A) Hematoxylin and eosin staining (original magnification, ×400). (B) Periodic acid–Schiff staining (original magnification, ×400).

normal, and no abnormal inflammatory markers were observed. On POD 76, the patient was discharged without any other complications or oral medications. One year after discharge, follow-up esophagogastrosocopy was performed, which revealed a large post-inflammatory ulcer scar without rugal fold formation, but there was no active inflammation at the previous lesion (Figure 3). Biopsy was again performed, and no fungal hypha was found.

Discussion

Zygomycetes include organisms that cause human disease, among those members they have two orders: the Mucorales and the Entomophthorales.^{3,4} The majority of fungal infections human illness was reported to be caused by the Mucorales, that usually live in the soil and cause food decay.⁵ Although *Rhizopus* spp. is the fungi most usually linked to diseases, other organisms are also associated with human infection, such as *Mucor*, *Rhizomucor*, and *Absidia*. These cause an acute, angio-invasive infection in immunocompromised hosts, which has a high mortality rate.^{1,6} The most common clinical infection of mucormycosis is the rhinocerebral type; other types are pulmonary, cutaneous, gastrointestinal, and disseminated mucormycosis. Among them, the gastrointestinal type invades the stomach (67%), followed by the colon (21%), small intestines (4%), and esophagus (2%).¹ Histologically, mucormycosis is classified into colonization, infiltration, and vascular invasion types, with vascular invasion having the worst prognosis.²

Gastric mucormycosis is usually known to occur in patients with immunocompromised states, those with diabetes mellitus, steroid users, solid-organ transplant donors, those with histories of alcohol abuse, and those with liver cirrhosis.⁷ It also occurs in high-risk patients using corticosteroids, antineoplastic chemotherapy, and antirejection

agents. A study reported an outbreak of gastric mucormycosis associated with wooden tongue depressors in critically ill patients.⁸ Recently, it was found to occur in patients with polytrauma with no special underlying factors, like in the case of our patient.^{1,9} The immunosuppressive effect of the transfusion might have increased the infection rate of mucormycosis in polytrauma patients.¹⁰

In our case, the patient was diagnosed with hemopericardium due to right atrial rupture after a vehicular accident. She underwent emergency operations and had ECMO support. The patient had no predisposing factors for gastric mucormycosis. Since gastric ulcers usually create favorable conditions for the development of primary gastric mucormycosis,¹¹ we could only assume that, even with the use of proton pump inhibitors, a stress-induced ulcer may have contributed to the development of mucormycosis with massive ongoing melena.

Gastric mucormycosis is rare and has a disseminated course; it has no definite treatment, and the prognosis for all patients is poor. However, rapid diagnosis, treatment of predisposing risk factors, surgical debridement, and prompt antifungal therapy might lead to successful treatment.^{12,13} Therefore, a rapid diagnosis is critical to enable early initiation of antifungal therapy. Surgical debridement could be an option with antifungal medication. However, surgery is chosen depending on the resection range of the stomach and the patient's overall condition. In this case, the patient had infiltration-type gastric mucormycosis, which would be responsive to surgical debridement plus antifungal medication. However, the patient needed total gastrectomy, for which we could not determine the extent of damage and the degree of disseminated intravascular coagulopathy because of the massive melena. Therefore, we opted for antifungal therapy alone and monitored the effect.

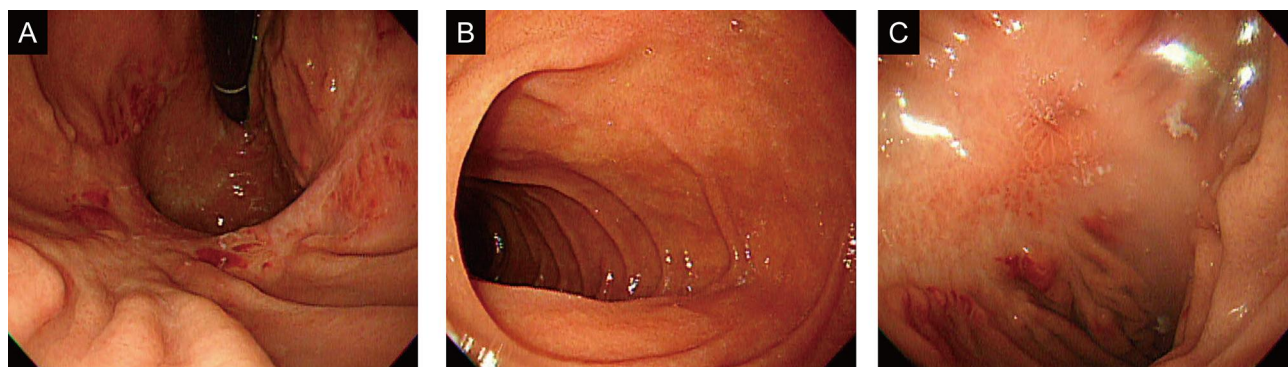


Figure 3 Endoscopic images one year after discharge. Large post-inflammatory ulcer scar without rugal fold formation (A and B) and small erosion with surrounding regenerating mucosa (C) at the greater curvature of the proximal body to the mid-body.

Recently, posaconazole, an oral antifungal drug, was recommended for the prevention of recurrence in a case of remission confirmed by gastroscopy.^{14,15} However, the patient was doing well without any oral antifungal drug. Endoscopy revealed no evidence of recurrence during the 1-year follow-up. Comparative data do not exist to justify the basis for the duration of antifungal therapy. However, many suggest that antifungal therapy be continued until the resolution of symptoms and signs or stabilization of serial imaging.¹⁶

Conclusion

Gastrointestinal mucormycoses proliferate rapidly and may occur during stress-induced ulcer which might contribute to the development of mucormycosis with massive ongoing melena. Whether or not the ulcer was persistent already at the time of the vehicular accident or later could not be determined. This case of gastric mucormycosis presenting with massive melena in a polytrauma patient was treated by transfusion, a hemostatic agent, and antifungal therapy immediately after early diagnosis.

Abbreviations

CPCR, cardiopulmonary cerebral resuscitation; ECMO, extracorporeal membrane oxygenation; POD, postoperative day.

Ethics Approval and Informed Consent

The patient or her legal guardian was uncontactable, so the authors were unable to obtain informed consent from the patient. The paper will be published anonymous without any patient's face or distinctive body markings and the authors have done their best to remove the identifying features of our patient in this case report. Institutional approval was not required to publish the case details.

Disclosure

The authors report no conflicts of interest in this work.

References

1. Prabhu RM, Patel R. Mucormycosis and entomophthoromycosis: a review of the clinical manifestations, diagnosis and treatment. *Clin Microbiol Infect.* 2004;10(Suppl 1):31–47. doi:10.1111/j.1470-9465.2004.00843.x
2. Kahn LB. Gastric mucormycosis: report of a case with a review of the literature. *S Afr Med J.* 1963;14(37):1265–1269.
3. Voigt K, Vaas L, Stielow B, de Hoog GS. The zygomycetes in a phylogenetic perspective. *Persoonia.* 2013;30(1):1–4. doi:10.3767/003158513X666277
4. Mendoza L, Vilela R, Voelz K, Ibrahim AS, Voigt K, Lee SC. Human fungal pathogens of mucorales and entomophthorales. *Cold Spring Harb Perspect Med.* 2014;5(4):a019562.
5. Hassan MIA, Voigt K. Pathogenicity patterns of mucormycosis: epidemiology, interaction with immune cells and virulence factors. *Med Mycol.* 2019;57(Supplement_2):S245–S256. doi:10.1093/mmy/myz011
6. Ribes JA, Vanover-Sams CL, Baker DJ. Zygomycetes in human disease. *Clin Microbiol Rev.* 2000;13(2):236–301.
7. Lee SH, Son YG, Sohn SS, Ryu SW. Successful treatment of invasive gastric mucormycosis in a patient with alcoholic liver cirrhosis: a case report. *Exp Ther Med.* 2014;8(2):401–404. doi:10.3892/etm.2014.1753
8. Maravi-Poma E, Rodriguez-Tudela JL, de Jalon JG, et al. Outbreak of gastric mucormycosis associated with the use of wooden tongue depressors in critically ill patients. *Intensive Care Med.* 2004;30(4):724–728. doi:10.1007/s00134-003-2132-1
9. Roden MM, Zaoutis TE, Buchanan WL, et al. Epidemiology and outcome of zygomycosis: a review of 929 reported cases. *Clin Infect Dis.* 2005;41(5):634–653.
10. Dunne JR, Malone DL, Tracy JK, Napolitano LM. Allogenic blood transfusion in the first 24 hours after trauma is associated with increased systemic inflammatory response syndrome (SIRS) and death. *Surg Infect (Larchmt).* 2004;5(4):395–404. doi:10.1089/sur.2004.5.395
11. Lehrer RI, Howard DH, Sypherd PS, Edwards JE, Segal GP, Winston DJ. Mucormycosis. *Ann Intern.* 1980;93(1_Part_1):93–108. doi:10.7326/0003-4819-93-1-93
12. Spellberg B, Edwards J, Ibrahim A. Novel perspectives on mucormycosis: pathophysiology, presentation, and management. *Clin Microbiol Rev.* 2005;18(3):556–569. doi:10.1128/CMR.18.3.556-569.2005
13. Chamilos G, Lewis RE, Kontoyiannis DP. Delaying amphotericin B-based frontline therapy significantly increases mortality among patients with hematologic malignancy who have zygomycosis. *Clin Infect Dis.* 2008;47(4):503–509. doi:10.1086/590004
14. Van Sickels N, Hoffman J, Stuke L, Kempe K. Survival of a patient with trauma-induced mucormycosis using an aggressive surgical and medical approach. *J Trauma.* 2011;70(2):507–509. doi:10.1097/TA.0b013e31820784ff
15. Katta J, Gompf SG, Narach T, et al. Gastric mucormycosis managed with combination antifungal therapy and no surgical debridement. *Infect Dis Clin Pract.* 2013;21(4):265–268. doi:10.1097/IPC.0b013e31826e81b3
16. Martinello M, Nelson A, Bignold L, Shaw D. “We are what we eat!” Invasive intestinal mucormycosis: a case report and review of the literature. *Med Mycol Case Rep.* 2012;1(1):52–55. doi:10.1016/j.mmcr.2012.07.003

International Medical Case Reports Journal

Dovepress

Publish your work in this journal

The International Medical Case Reports Journal is an international, peer-reviewed open-access journal publishing original case reports from all medical specialties. Previously unpublished medical posters are also accepted relating to any area of clinical or preclinical science. Submissions should not normally exceed 2,000 words or 4

published pages including figures, diagrams and references. The manuscript management system is completely online and includes a very quick and fair peer-review system, which is all easy to use. Visit <http://www.dovepress.com/testimonials.php> to read real quotes from published authors.

Submit your manuscript here: <https://www.dovepress.com/international-medical-case-reports-journal-journal>