

# Why borrow from Peter when Paul can afford it? Reverse homodigital artery flap for fingertip reconstruction

Narayanamurthy Sundaramurthy, Surya Rao Venkata Mahipathy, Alagar Raja Durairaj

Department of Plastic and Reconstructive Surgery, Saveetha Medical College, Kancheepuram, Tamil Nadu, India

**Address for correspondence:** Dr. Narayanamurthy Sundaramurthy, Department of Plastic and Reconstructive Surgery, Saveetha Medical College, Thandalam, Kancheepuram - 602 105, Tamil Nadu, India. E-mail: nanathesurgeon@gmail.com

## ABSTRACT

**Background:** Fingertip injuries that are complicated by pulp loss, bone or tendon exposure will need a flap cover. Cross finger flap is commonly used to cover such defects. However, patients are apprehensive about injuring the uninjured finger as a donor site. Reverse homodigital artery flap (RHAF) can provide reliable vascularised cover to such defects. **Aims:** This study aims to assess the functional and aesthetic outcomes along with the patient satisfaction of RHAFs done for fingertip defects. **Materials and Methods:** RHAFs done in 18 patients operated between August 2015 and October 2016 were retrospectively analysed on flap survival, sensory recovery, range of movements, hypersensitivity, cold intolerance, flexion contracture and donor site morbidity. **Results:** Seventeen of the 18 flaps done survived completely. One flap had partial necrosis of 3 mm that healed conservatively. Middle finger of the right hand was the most commonly injured finger. Touch, pain and pressure sensations recovered in 8–12 weeks. Two-point discrimination was 4.5 mm at 6 months. The deficit of 5° s was present at distal interphalangeal joint during active flexion at 6 months. Cold intolerance and flexion contracture were not seen and 2 instances of hypersensitivity at 2 months got cured conservatively after 4 months. Overall satisfaction of patients was 8/10. **Conclusion:** RHAF provides single staged well-vascularised cover for fingertip injuries with good sensory recovery without damaging the adjacent uninjured finger. Hence, it can be a reliable flap for fingertip reconstruction in selected cases.

## KEY WORDS

Fingertip injuries; fingertip reconstruction; reverse homodigital artery flap; sensory recovery in reverse homodigital artery flap

## INTRODUCTION

Fingertip injuries from industrial accidents are some of the most commonly seen types of hand injuries presenting to a plastic surgery emergency set up.

These injuries are generally complicated by loss of pulp, exposure of bone or tendon and injury to nail complex. Such wound beds require a good vascularised tissue cover in the form of a flap. Cross finger flap is generally used

This is an open access article distributed under the terms of the Creative Commons Attribution-NonCommercial-ShareAlike 3.0 License, which allows others to remix, tweak, and build upon the work non-commercially, as long as the author is credited and the new creations are licensed under the identical terms.

**For reprints contact:** reprints@medknow.com

**How to cite this article:** Sundaramurthy N, Venkata Mahipathy SR, Durairaj AR. Why borrow from Peter when Paul can afford it? Reverse homodigital artery flap for fingertip reconstruction. Indian J Plast Surg 2017;50:187-92.

Access this article online	
Quick Response Code:	Website: www.ijps.org
	DOI: 10.4103/ijps.IJPS_98_17

to cover such defects. We regularly find patients who are apprehensive about 'surgery to the uninjured finger' and the prolonged immobilisation involved. We have also appreciated the stiffness of fingers due to the same. Hence, we explored this flap for a reliable vascularised tissue from the same finger. In this retrospective analysis of 18 cases done between August 2015 and October 2016, we have tried to assess the functional and aesthetic outcomes along with patient satisfaction.

## MATERIALS AND METHODS

Eighteen Patients with fingertip injuries who presented to our hospital between August 2015 and October 2016 were analysed retrospectively. All of them had loss of tip or pulp of the fingertip with exposure of flexor digitorum profundus tendon or terminal phalanx [Figure 1a and b]. The patients were admitted, clinical pictures taken, basic blood investigations and serological markers assessment done and posted for surgery on an emergency basis. Doppler was done to make sure that there was a digital artery on both sides of the finger. Anaesthesia was provided in the form of axillary block and supplemented with sedation/general anaesthesia if needed. All were operated in supine position with arms abducted and under tourniquet control. Tourniquet was started after elevation for 3 min. Surgical debridement of the wound was done followed by lavage. Once the defect was created, measurement of the same was done with a ruler. Reverse homodigital artery flap (RHAF) was planned with either the ulnar or radial neurovascular bundle as the central axis [Figure 1c and d]. The incision was first made at the proximal end of the flap, digital artery and nerve identified. Neurovascular bundle [Figure 2a] was ligated in-Toto and cut. Incision extended laterally on either sides and two dermal flaps

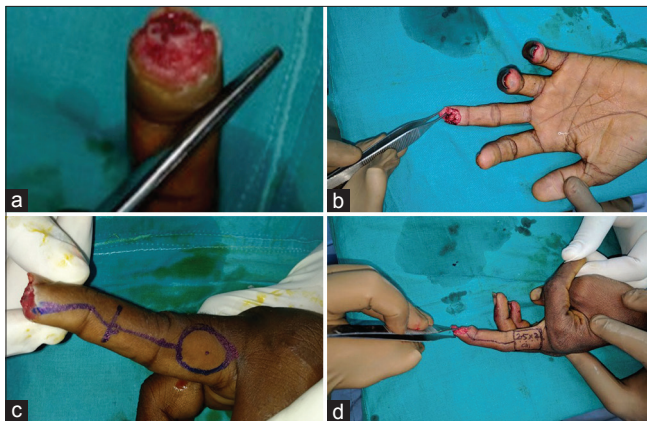
were raised on either sides of the subcutaneous pedicle distal to the flap exposing the pedicle [Figure 2b and c]. Flap was lifted off from bed in a plane of loose areolar tissue deep to the neurovascular bundle and superficial to paratenon of the extensor expansion [Figure 2d]. Transverse branches of digital artery were encountered as the dissection proceeds proximally. The ones around proximal interphalangeal (PIP) joint were sacrificed. The distal transverse digital artery found at the neck of middle phalanx was used as the pivot point. Flap was propelled to cover the defect without tension. Flap inset was done with 3–0 polyethylene sutures [Figure 2e and f]. Dermal flaps proximal to the pivot point were closed primarily. Donor site was covered with either split skin graft (SSG) from arm or glabrous skin graft from hypothenar eminence or primarily closed depending on size of the defect [Figure 3a and b]. Reversed pedicle, in all cases, was covered with skin grafts to avoid tension. Sterile dressing done and hand was immobilised with a plaster of Paris (POP) slab.

Flap was monitored every 2 h's on the 1<sup>st</sup> day, every 6 h on the 2<sup>nd</sup> day and the patient was discharged on the 2<sup>nd</sup> post-operative day (POD) once the flap was healthy. Grafts were examined on the 5<sup>th</sup> POD and sutures on grafts were removed on the 7<sup>th</sup> POD.

Patients were reviewed on a regular basis at weekly intervals in the 1<sup>st</sup> month till complete wound healing. Later reviews were done at 2<sup>nd</sup>, 4<sup>th</sup> and 6<sup>th</sup> month after surgery. During every visit, functional and aesthetic assessments were done along with an assessment of patient satisfaction. The functional assessment was based on sensory recovery, two point discrimination (2-PD), active and passive range of movements of PIP joints and distal interphalangeal (DIP) joints, development of flexion contracture, hot/cold intolerance and hypersensitivity. Patient satisfaction was assessed based on scale of 0–10 on appearance, function and overall satisfaction. Results were assimilated at the end of 6 months and analysed.

## RESULTS

During the study, 18 patients were operated of whom 17 were men and 1 was female. Thirteen were industrial accidents and five were accidental injuries due to other causes such as road traffic accidents and domestic injuries. Age of the injured ranged between 17 and 55 (12 persons in the age group 15–25). The right hand was injured in



**Figure 1:** Fingertip defects and planning of reverse homodigital artery flap. (a) Bone and tendon exposure, (b) Loss of pulp. Flap planning for the respective defects (c and d)

15 cases. Among the fingers affected, long finger was the most commonly injured in 11 cases, ring finger in 3, index finger in 3 cases and little finger in one [Figure 4].

Intraoperatively, the average size of the defect was 2.3 cm × 1.8 cm. Flap was harvested based on ulnar neurovascular bundle in 7 cases and radial neurovascular bundle in 11 cases. Preservation of digital nerve was done in one case. Donor site was closed primarily in 1 case, with SSG from arm in 16 cases and with glabrous skin graft from hypothenar eminence in 1. The average operating time was 124.6 min.

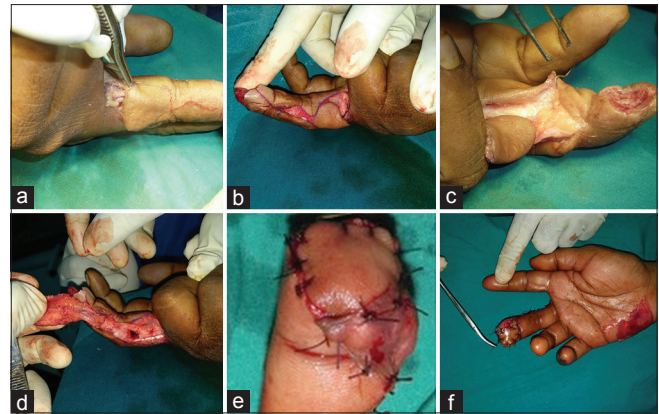
Seventeen flaps survived completely. One had partial necrosis and healed conservatively with regular dressings in 12 days. Three patients had marginal graft loss (<3 mm) at donor site again treated conservatively with regular dressings.

Regarding sensory recovery, pain, pressure and touch sensations recovered by 8–12 weeks. The mean static 2-PD was 5.6 mm at the end of 4 months and 4.5 mm at the end of 6 months. The range of movements at PIP and DIP were near normal with a deficit averaging 5° s in active flexion at DIP joint at the end of 6 months. Cold intolerance was not appreciated in any of the cases. Hypersensitivity was present at the distal-most tips in 2 patients at 2<sup>nd</sup> month visit which settled with tapping and compression garment application by the end of 4 months. By 6 months none of the patients had any hypersensitivity.

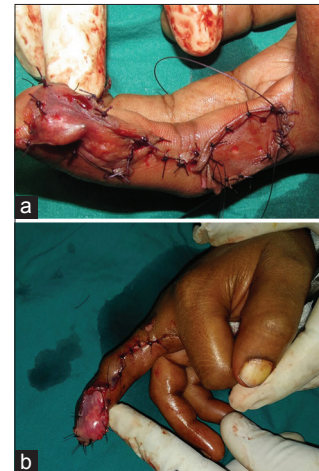
Patients were able to return to work in about 52 days on an average. In patient satisfaction on a scale of 1–10, patients gave a score of 7/10 for appearance, 7.5/10 for function and 8/10 for overall satisfaction.

## DISCUSSION

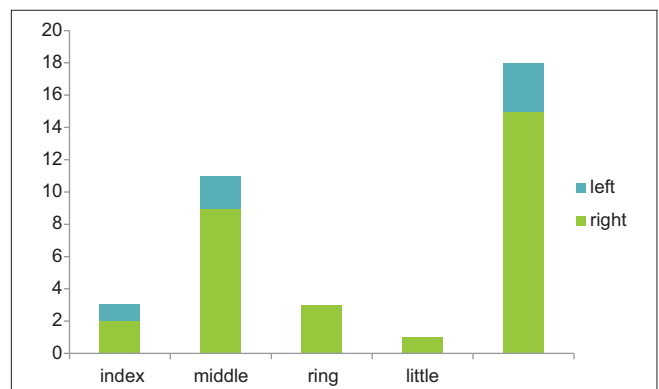
Fingertips are not only important to touch and feel but also provide good soft tissue padding for bone tips and tendon insertions. Loss of fingertip is ideally managed by replanting the tissue but more often than not may not be possible. Hence, reconstruction of the fingertip with like tissue that will enable us to maintain the length of the finger, provide sensation, padding, an adequate range of motion without adverse effects of prolonged immobilisation is crucial. Cross finger flaps are the workhorse flaps for fingertip reconstruction, but they



**Figure 2:** Steps of flap harvest. (a) Proximal incision with the identification of neurovascular bundle. (b) Distal incision over neurovascular pedicle. (c) Elevation of dermal flaps. (d) Flap lifted up from the base and pivoted at the level of distal transverse digital artery. (e) Flap inset. (f) Harvest of the 2<sup>nd</sup> layer hypothenar graft to cover exposed pedicle



**Figure 3:** Coverage of secondary defect. (a) Donor site covered with split skin graft from the left arm. (b) Donor site closed primarily with 2<sup>nd</sup> layer glabrous skin graft from hypothenar eminence



**Figure 4:** Finger affected

have the disadvantage of disturbing the uninjured finger and prolonged immobilisation. Most of our patients are apprehensive about these factors. An effective alternative will be to mobilise tissue from the same finger for the



reconstruction of the injured fingertip. RHAF, originally described by Lai *et al.*,<sup>[1]</sup> provides a suitable alternate plan to treat such defects.

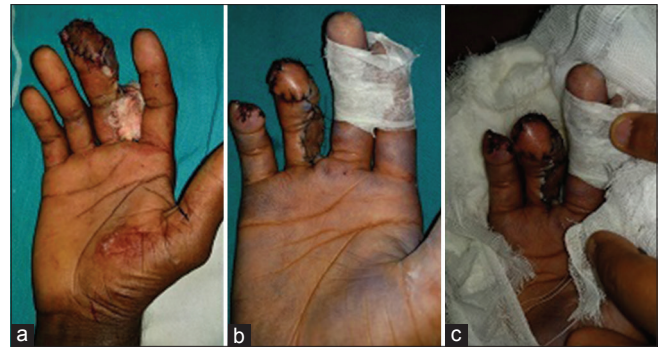The fingers are supplied by ulnar and radial digital arteries that are accompanied by digital nerves. These arteries communicate with each other by proximal and distal transverse digital arteries at the level of the neck of proximal and middle phalanges.<sup>[2]</sup> Blood supply to the flap is through retrograde flow from the opposite side digital artery through distal transverse digital artery. This runs deep very close to the bone. The pivot for rotation lies at the level of neck of middle phalanx. Venous drainage is through peripedicle venules that drain through distal and dorsal venous plexus.

Defects distal to DIP joints were selected. The choice of digital vessel that was to be used was based on the fact to avoid contact surface of the respective fingers. For example, radial side of index and ulnar side of little fingers were avoided. In middle and ring finger defects, choice was based on obliquity of the defect.

We found that this flap can be used to cover a defect as large as 2.7 cm × 2.5 cm. Among the 18 cases done, digital nerve was not taken with the flap in only one case and that flap showed venous congestion and partial loss of flap (3 mm at tip) that healed with conservative measures. Dissection around the artery could have damaged the peripedicle venous plexus and that could have been the reason for congestion. Donor site and pedicle were covered with SSG from arm in 17 cases. When the donor site was closed primarily, glabrous skin graft from hypothenar eminence was used to cover the pedicle.

While doing dressing, bolster was given to cover the graft on donor site [Figure 5a]. This not only improved graft uptake but also prevented compression at the pedicle by moving the adjacent finger away. In addition to it, the finger adjacent to the pedicle and the 1 further adjacent to it were tagged together [Figure 5b]. POP was applied in a functional position for a couple of weeks as a support to the hand [Figure 5c].

In our study, we found that the middle finger of a male industrial labourer is the most vulnerable for a fingertip injury/amputation. The domestic injury was the aetiology in the only female who presented during the study period. Size of the flap ranged from 1.8 cm × 1.5 cm to



**Figure 5:** Dressing technique. (a) bolster dressing to cover donor site with a split skin graft. (b) Taping of adjacent fingers. (c) Plaster of Paris slab in functional position

2.8 cm × 2.5 cm. Pneumatic tourniquet was applied in all patients after elevation for 3 min and all flaps were elevated in one tourniquet time. Operating time reduced gradually and ranged between 175 min and 90 min. Time taken to harvest the flap was about 25 min.

In a meta-analysis, done by Regmi *et al.*,<sup>[3]</sup> that included 8 studies and 230 fingertip injuries flap survival rate was 98% (including partial survival). In our study, all our flaps survived [Figure 6]. One of the flaps had venous congestion in the 1<sup>st</sup> POD that was treated conservatively with elevation and anti-oedema measures. It eventually had a distal flap necrosis of 3 mm without exposure of underlying bone, and complete healing occurred in 4 weeks. Following this, attempt to separate the digital artery from nerve was not taken.

In spite of not including the nerve, mean static 2-PD was 4.5 mm (range-3–5.5 mm). In a study by Karamese *et al.*,<sup>[4]</sup> adipofacial RHAF was done with skin graft and nerve coaptation to contralateral nerve ending, mean static 2-PD was 4.86 mm (range-3–6 mm). Surprisingly, in spite of not doing a nerve coaptation, we had similar results with sensory recovery. In another study by Huang *et al.*,<sup>[5]</sup> nerve was preserved and not harvested with the flap, this study reported a mean static two point discrimination of 10.1 mm (7–12 mm). Among various other studies by Alagoz *et al.*,<sup>[6]</sup> Yazar *et al.*,<sup>[7]</sup> and Kayalar *et al.*,<sup>[8]</sup> where sensate flap was done, mean static 2-PD was 6.5, 5.7 and 4.3 mm. Based on these observations, we would like to propose that harvesting the nerve along with the flap not only prevents disruption of venules and improves flap survival, but also improves better sensory recovery by virtue of neural elements being present in the flap-tip which can communicate with the nerve endings of the contralateral digital nerve

present in the edge of the ulcer. As we reverse the flap, the tip reaches the contralateral edge of the ulcer. Neurotrophic factors could play a role in this though further research and more number of cases are needed to prove this point.

We did not find any deficit in the range of motion at the PIP joint whereas a mean deficit of  $4.75^\circ$  was present in active flexion of the DIP joint. Full range was present on complete flexion of DIP joint [Figure 7]. This did not have any implication on function and though patients were worried in initial couple of months, by 4–6 months, all were satisfied about functional ability of the finger. Post-operative physiotherapy helped in this regard. We are hoping for better results in further follow-up beyond 6 months. Physiotherapy also helped in earlier return to work which was 52 days on an average.

None of our patients had cold intolerance. These findings were consistent with the studies by Han *et al.*<sup>[9]</sup> and Momeni *et al.*<sup>[10]</sup> Two patients had hypersensitivity at the flap tip around 8–9 weeks. Fortunately, both settled with conservative measures.

Flexion contracture was not seen in any of the patients as the incision was made in the mid-axial line and none of the flaps had its distal margin distal to the PIP joint. Post-operative scar therapy with silicone gel sheets, compression garment, physiotherapy and triamcinolone injections were provided to reduce scar and contracture formation.

Graft take in all donor sites was satisfactory with no major healing issues [Figure 8]. Three patients had minimal margin loss of  $<3$  mm that healed conservatively.

Overall patient satisfaction was 8/10. At the end of 6 months, all patients were satisfied about the contour and function.

## CONCLUSION

RHAF for fingertip reconstruction provides single stage well vascularised soft tissue cover to fingertips from the same finger with good sensory recovery, decent contour and negligible donor site morbidity. Harvesting the flap along with the digital nerve did not have any adverse effect on sensory recovery in the flap in our study. The

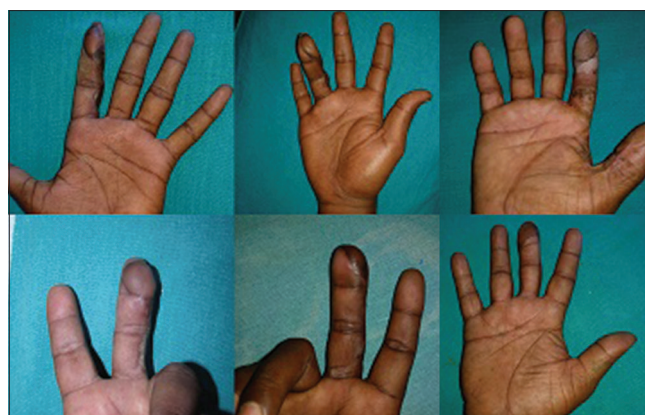


Figure 6: Well settled flaps

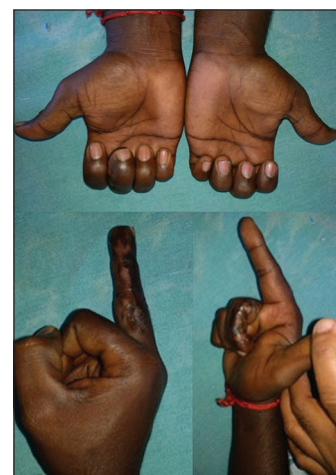

Figure 7: Post-operative range of movements at proximal interphalangeal and distal interphalangeal joints

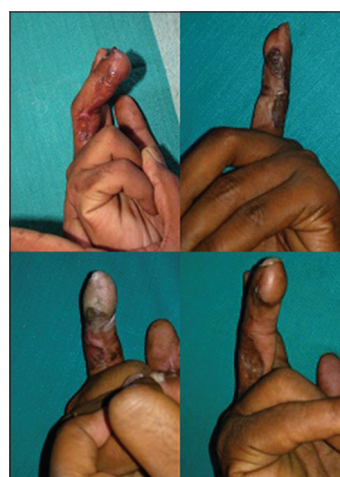

Figure 8: Healing of donor site

only major disadvantage of sacrificing 1 digital vessel also did not have any functional adverse effect during the study period. Hence, we recommend this flap as a reliable choice for fingertip reconstruction in carefully selected cases.

## Acknowledgement

Authors would like to thank Prof. Rathna, Department of anaesthesiology. Prof. Sridhar, Department of anaesthesiology. OT support staff, technicians and last but not the least, our patients.

## Financial support and sponsorship

Nil.

## Conflicts of interest

There are no conflicts of interest.

## REFERENCES

1. Lai CS, Lin SD, Yang CC. The reverse digital artery flap for fingertip reconstruction. *Ann Plast Surg* 1989;22:495-500.
2. Cormack GC, Lamberty GB. *The Arterial Anatomy of Skin Flaps*. 2<sup>nd</sup> ed. London Churchill Livingstone; 1994. p. 213-5.
3. Regmi S, Gu JX, Zhang NC, Liu HJ. A Systematic review of outcomes and complications of primary fingertip reconstruction using reverse-flow homodigital Island flaps. *Aesthetic Plast Surg* 2016;40:277-83.
4. Karamese M, Akatekin A, Abac M, Koplay TG, Tosun Z. Fingertip reconstruction with reverse adipofascial homodigital flap. *Ann Plast Surg* 2015;75:158-62.
5. Huang YC, Liu Y, Chen TH. Use of homodigital reverse island flaps for distal digital reconstruction. *J Trauma* 2010;68:429-33.
6. Alagoz MS, Uysal CA, Kerem M, Sensoz O. Reverse homodigital artery flap coverage for bone and nailbed grafts in fingertip amputations. *Ann Plast Surg* 2006;56:279-83.
7. Yazar M, Aydin A, Kurt Yazar S, Basaran K, Güven E. Sensory recovery of the reverse homodigital island flap in fingertip reconstruction: A review of 66 cases. *Acta Orthop Traumatol Turc* 2010;44:345-51.
8. Kayalar M, Bal E, Toros T, Ozaksar K, Sığün ST, Ademoglu Y. The results of reverse-flow island flaps in pulp reconstruction. *Acta Orthop Traumatol Turc* 2011;45:304-11.
9. Han SK, Lee BI, Kim WK. The reverse digital artery island flap: An update. *Plast Reconstr Surg* 2004;113:1753-5.
10. Momeni A, Zajonc H, Kalash Z, Stark GB, Bannasch H. Reconstruction of distal phalangeal injuries with the reverse homodigital island flap. *Injury* 2008;39:1460-3.