



Contents lists available at ScienceDirect

Respiratory Medicine Case Reports

journal homepage: <http://www.elsevier.com/locate/rmcr>

Case report

An unusual case of eosinophilic lung disease with multiple cyst formation



Hitomi Nogawa^a, Hiroki Suzuki^{a,*}, Yoshinori Kawabata^b, Takahito Ota^a, Yoshihiko Yuki^a, Yuji Katagiri^a, Toshihiko Hino^a, Naoki Yanagawa^c, Shigeharu Ueki^d

^a Department of Respiratory Medicine, Yamagata Prefectural Central Hospital, 1800, Aoyagi, Yamagata-city, Yamagata, 990-2292, Japan

^b Division of Diagnostic Pathology, Saitama Cardiovascular and Respiratory Center, 1696, Itai, Kumagaya-city, Saitama, 360-0105, Japan

^c Department of Diagnostic Pathology, Yamagata Prefectural Central Hospital, 1800 Aoyagi, Yamagata-city, Yamagata, 990-2292, Japan

^d Department of General Internal Medicine and Clinical Laboratory Medicine, Akita University Graduate School of Medicine, 1-1-1, Hondo, Akita, 010-8543, Japan

ARTICLE INFO

Keywords:

Multiple cystic lesions
Spontaneous resolution
Eosinophilic abscesses
Eosinophil extracellular trap cell death
Charcot–Leyden crystal

ABSTRACT

We report here an unusual case of eosinophilic necrotizing inflammation of the lung that mimicked chronic eosinophilic pneumonia. A 71-year-old man who lived in an unsanitary environment and was referred to our hospital with suspected pneumonia. Peripheral blood eosinophilia was observed, and computed tomography indicated extensive consolidation with multiple cystic lesions, mainly in the left lung. A histological analysis using video-assisted thoracic surgery revealed diffuse infiltration of inflammatory cells into the alveolar wall and massive accumulation of macrophages and eosinophils in the airspace. Many tiny eosinophilic abscesses were scattered through the tissue. These findings were more severe than those associated with chronic eosinophilic pneumonia. Immunostaining revealed the deposition of eosinophil granular protein and the presence of extracellular traps and Charcot–Leyden crystals, which suggested excessive eosinophil activation. Interestingly, the patient's symptoms and clinical findings gradually improved without treatment after admission. He was discharged to a clean residence and did not have a recurrence for 19 months. The observations suggest a hypersensitivity reaction to an environmental allergen and consequent multiple cyst formation in association with eosinophilic necrotizing inflammation, although further studies are warranted.

1. Introduction

Eosinophilic lung diseases are a diverse group of pulmonary disorders involving tissue eosinophilia. The main etiologic categories are unknown causes, infection, allergic reaction, and vasculitis. Idiopathic chronic eosinophilic pneumonia (ICEP) is a lung disease characterized by a subacute presentation and typically occurs in patients with a history of asthma or atopic disease. Although ICEP is sensitive to corticosteroid therapy and has a favorable prognosis, relapses commonly occur during corticosteroid tapering and discontinuation. On chest computed tomography (CT), ICEP appears as characteristic opacities predominately in the peripheral upper lobes [1,2].

The pathology of ICEP is characterized by intraalveolar accumulations of eosinophils and macrophages in varying proportions. An interstitial infiltrate characteristically accompanies the intraalveolar change.

There may also be foci of intraluminal organization and eosinophilic microabscesses, but they are usually unremarkable [3,4]. Eosinophilic granulomatosis with polyangiitis (EGPA) is a typical disease exhibiting the pathological features of eosinophilic abscess. This condition, which was first described as allergic granulomatosis angiitis by Churg and Strauss in 1951, is distinct from Wegener granulomatosis and other vasculitides [5]. In their report, Churg and Strauss described common characteristic granulomatous nodules in 13 of 14 patients who presented with asthma, fever, and peripheral eosinophilia, and Loeffler reported similar findings in “pulmonary infiltration with eosinophilia” [6]. The pathology of these so-called allergic granulomas or eosinophilic abscesses are centrally necrotic nodules of tightly packed eosinophils surrounded by multinucleated giant cells and macrophages. However, the formation of lung cysts or cavities is considered extremely rare in either ICEP or EGPA [1,2,7–9].

Abbreviations: CitH3, citrullinated histone H3; EETosis, eosinophil extracellular trap cell death; EETs, eosinophil extracellular traps; EGPA, eosinophilic granulomatosis with polyangiitis; ICEP, idiopathic chronic eosinophilic pneumonia; MBP, major basic protein; NETs, neutrophil extracellular traps.

* Corresponding author. Department of Respiratory Medicine, Yamagata Prefectural Central Hospital, 1800, Aoyagi, Yamagata-city, Yamagata, 990-2292, Japan.

E-mail addresses: hnogawa0124@gmail.com (H. Nogawa), hiroki042155@gmail.com (H. Suzuki), kawabata.yoshinori@pref.saitama.lg.jp (Y. Kawabata), taka0321.ra@gmail.com (T. Ota), f8h2bv@bma.biglobe.ne.jp (Y. Yuki), katagiri@ypch.gr.jp (Y. Katagiri), thino@ypch.gr.jp (T. Hino), naoki.yanagawa@gmail.com (N. Yanagawa), shigeharu.ueki@gmail.com (S. Ueki).

<https://doi.org/10.1016/j.rmcr.2020.101300>

Received 3 July 2020; Received in revised form 6 November 2020; Accepted 16 November 2020

Available online 19 November 2020

2213-0071/© 2020 The Authors.

Published by Elsevier Ltd.

This is an open access article under the CC BY-NC-ND license

(<http://creativecommons.org/licenses/by-nc-nd/4.0/>).

Eosinophils are short-lived granulocytes involved in inflammatory response initiation and propagation. The effector function of eosinophils is characterized by the release of toxic granule proteins. Additionally, EETosis has been recognized as a novel active cell death pathway that involves the release of intact granules and net-like chromatin structures (eosinophil extracellular traps: EETs) from eosinophils [10]. Recent studies revealed that EETosis is closely associated with the presence of Charcot–Leyden crystals, which are classical hallmarks of pathological eosinophilic inflammation [11,12].

In this report, we present a case of a patient with eosinophilic lung disease who exhibited multiple cyst formation. The patient had a chronic disease course with peripheral eosinophilia, and a pathological examination revealed infiltration of eosinophils, into the alveolar walls and exudation of eosinophils and macrophages into alveolar spaces. Although these findings were suggestive of ICEP, the case was pathologically characterized by a highly prominent presence of eosinophilic abscesses, which was not characteristic of ordinary ICEP. Immunostaining revealed the presence of eosinophil granular protein deposition, EETs, and Charcot–Leyden crystals. In spite of these significant pathological findings, the patient achieved a spontaneous resolution of the cystic lesions without recurrence. To the best of our knowledge, this is the first case of EETosis-related eosinophilic necrotizing inflammation associated with a unique clinical course and multiple cyst formation.

2. Case presentation

In early March 2018, a 71-year-old man visited a nearby clinic with a more than 2-month history of a cough, which had recently worsened and was complicated by anorexia and dyspnea on exertion. He was

subsequently referred to our hospital, where it was determined that he had been living in an unsanitary environment, leaving food moldy. He had worked in the casting industry for 20 years and had smoked 10 cigarettes per day when he was 20–55 years of age. His past medical history included appendicitis in middle school, surgical treatment for a torn shoulder rotator cuff at approximately 10 years ago, alcoholism until 69 year of age, but no history of asthma or atopic diseases. No sick contact and current medication were reported.

At the first visit to our hospital, his body temperature was 37.4 °C and his oxygen saturation was 89% (room air). A blood analysis revealed a white blood cell count of 17000 cells/ μ L with 26.6% (4500 cells/ μ L) eosinophils and C-reactive protein and immunoglobulin E (IgE) concentrations of 8.0 mg/dL and 180 IU/mL, respectively. A fluorescence enzyme immunoassay did not detect specific IgEs against *Candida albicans*, *Aspergillus fumigatus*, and *Alternaria alternata*, and a serum precipitating antibody test against *Penicillium glaucum*, *Penicillium digitatum*, *Cladosporium*, *Aureobasidium pullulans*, *Trichosporon cutaneum*, *Cephalosporium acremonium*, *A. fumigatus*, *A. flavus*, *A. glaucus*, *A. nidulans*, *A. nigar*, *A. restrictus*, *A. versicolor*, *Candida albicans*, and *Cryptococcus neoformans* did not yield positive findings.

Tests for myeloperoxidase-specific antineutrophil cytoplasmic antibody (ANCA) and proteinase 3-ANCA yielded negative results. Pulmonary function testing yielded the following results: vital capacity, 73.4% of predicted value; forced expiratory volume 1.0%, 73.0%. Chest computed tomography (CT) scan revealed consolidation and heterogeneous ground-glass opacities with multiple cystic lesions, predominantly in the left lung (Fig. 1).

A bronchoscopy was performed on 7 days after admission. The proportion of eosinophils in bronchoalveolar lavage (BAL) fluid

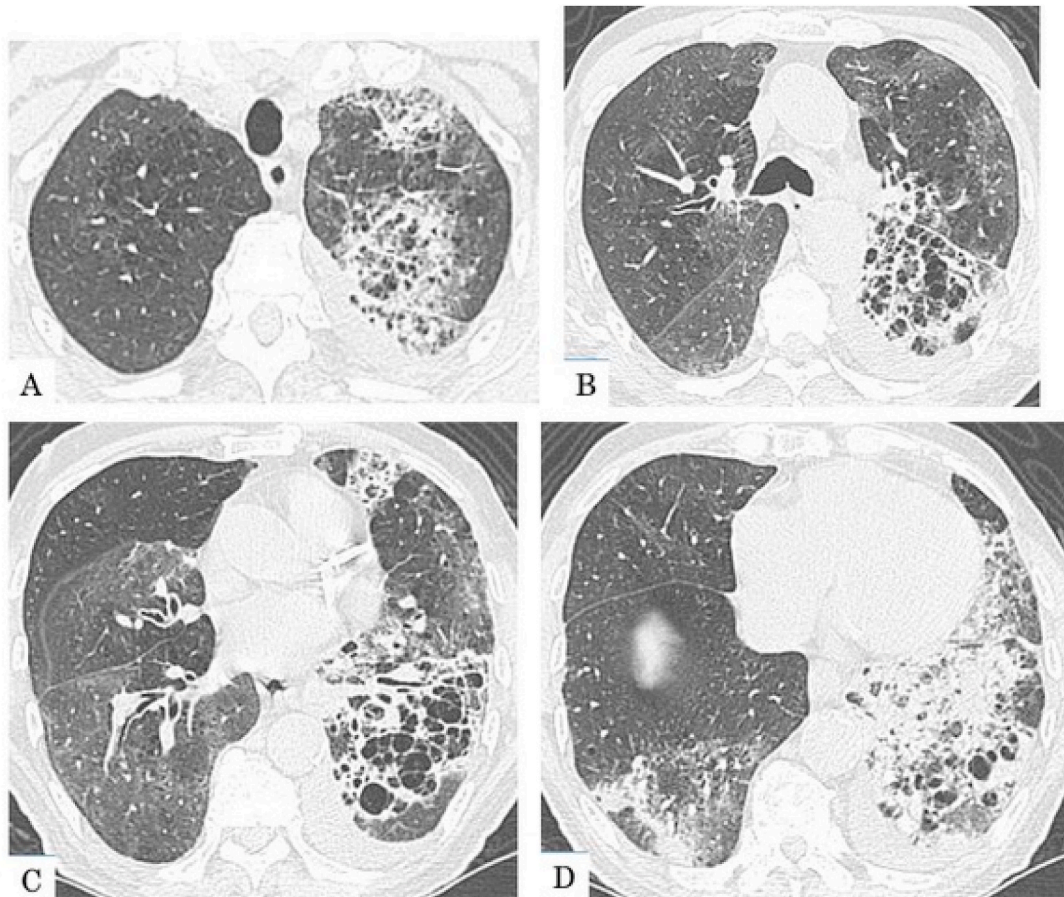


Fig. 1. Chest CT findings at the initial examination. Consolidation and heterogeneous ground-glass opacities with multiple cystic lesions are observed mainly in the left lung. The lesions are distributed predominantly in the inner layer of the lung. Areas of mildly low attenuation are observed predominantly in the right upper lobe.

collected from the left bronchus 5 (B⁵) was markedly elevated (95%). No pathogenic bacteria and acid-fast bacteria was detected. A trans-bronchial lung biopsy of the main lesions was performed. A histopathological biopsy examination revealed eosinophilic infiltration in the alveolar spaces and walls, mild fibrosis of the alveolar walls, and intraluminal organization.

On day 24, video-assisted thoracic surgery (VATS) from left S⁵ was performed. Histological findings assessed by hematoxylin and eosin (H&E) staining showed diffuse infiltration of inflammatory cells into the alveolar wall and massive exudation into the airspace, resulting in unclear margin between alveolar wall and airspace. The degree of inflammation was different among lobules (Fig. 2A). In a higher-magnification image, massive accumulation of macrophages and eosinophils were noted in the airspace and associated with many tiny eosinophilic abscesses containing basophilic necrotic cells (Fig. 2B). Interstitial connective tissue framework assessed by Elastica van Gieson (EvG) staining indicated that majority of lung structure was preserved (Fig. 2C). Various shaped intraluminal organization was also noted (Fig. 2C, arrows) in many areas in addition to cellular accumulation. No evidence for vasculitis was observed. Immunostaining using anti-cytokeratin antibodies AE1/AE3, differentiation between alveolar wall and airspace was impossible in many areas and disruption of epithelial layer (black arrows) and dropout epithelia (red arrow) were noted in many areas in addition to cuboidal and atypical metaplasia (Fig. 2D).

To study eosinophil activation further, we performed immunofluorescence staining to detect two eosinophil-specific proteins, major basic protein (MBP) and galectin-10, as previously described [11]. MBP is an eosinophil granule protein that can be released via degranulation and is prone to tissue deposition. Galectin-10 is a cytosolic protein that can be crystallized and released by active cytolytic cell death (e.g., EETosis) [11]. After acquiring confocal fluorescence images, we stained the same slides with H&E for comparison. As shown in Fig. 3Ai and ii, H&E

staining revealed an inflamed tissue with few intact eosinophils and significant tissue MBP deposition. A higher-magnification image (Fig. 3Aiii, iv) showed few recognizable eosinophils and the presence of cell-free eosinophilic granules and Charcot-Leyden crystals, some of which had likely been phagocytosed. To investigate the presence of EETs further, we stained the tissues to detect citrullinated histone H3, as histone citrullination is considered essential to extracellular trap formation [13]. A substantial numbers of cells exhibited decondensed/disrupted nuclei and abundant cell-free granules with histone hyper-citrullination (Fig. 3Bi-iv).

After admission, his condition gradually began to improve without corticosteroid treatment over a period of approximately 2 weeks. We asked his family to clean his residence prior to his discharge. He was discharged to a cleaned-up residence on day 36. To date (approximately 19 months post-discharge), no recurrence has been detected (Fig. 4).

3. Discussion

3.1. Mechanisms of cyst formation

The patient presented with an eosinophilic lung disease that manifested clinically as the formation of multiple cysts, which resolved spontaneously. In a high-resolution CT and histopathological analysis of a rabbit model of tuberculous cavities, Ihms et al. reported that all cavities were pathologically associated with the central necrotic areas of granulomas and that a certain level of communication was observed between the cavities and respiratory tract [14]. Based on the results, they proposed the following mechanisms of thin-walled cavity formation and progression: 1) with inspiration, external tension in the surrounding lung tissue pulls air into the necrotic center, 2) if the outlet is severely obstructed creating a ball-valve effect, extreme air trapping occurs and causes the cavity to assume a thin-walled morphology. In our

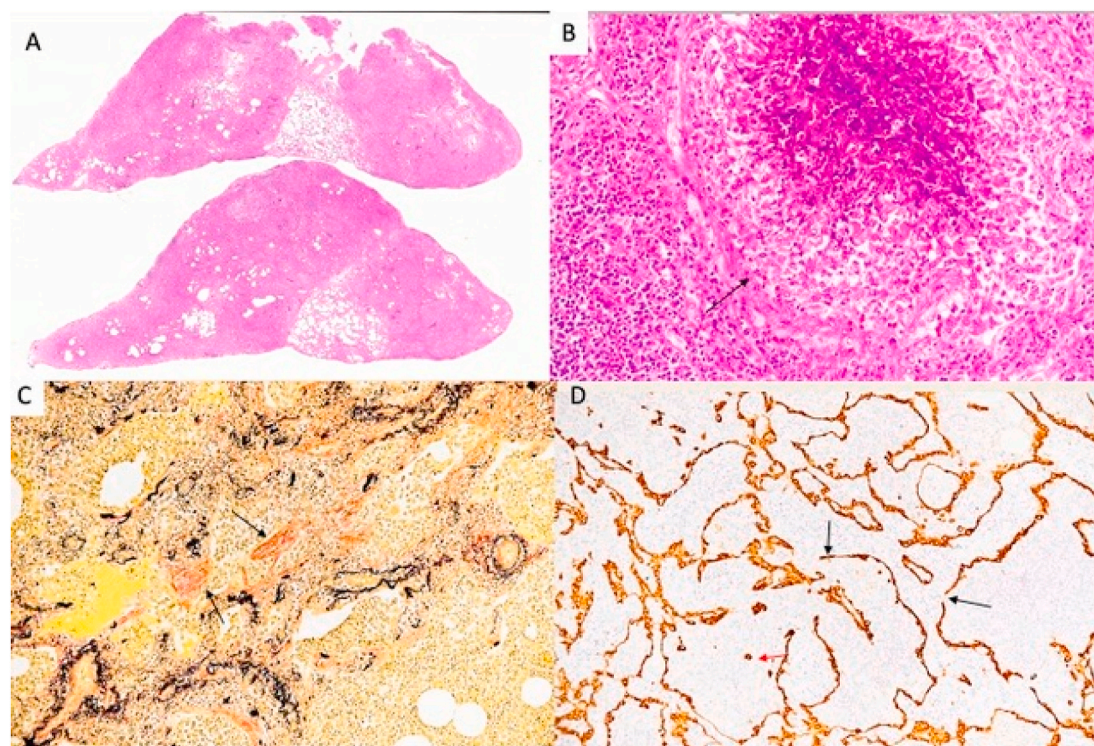


Fig. 2. Histological features of VATS lung. A. Panoramic view showing massive accumulation and infiltration of inflammatory cells with various degree. H&E staining. B. Central basophilic necrosis containing many eosinophils around and surrounded by epithelial cell layer (arrow). H&E staining, x200. C. Tiny intraluminal organizations (arrows) were noted together with inflammatory cells in the airspace and interstitium. Lung structure was preserved. EvG staining, x100. D. Disruption of epithelial layer (black arrows) and dropout (red arrow) were noted. Immunostaining using AE1/AE3, x100. (For interpretation of the references to colour in this figure legend, the reader is referred to the Web version of this article.)

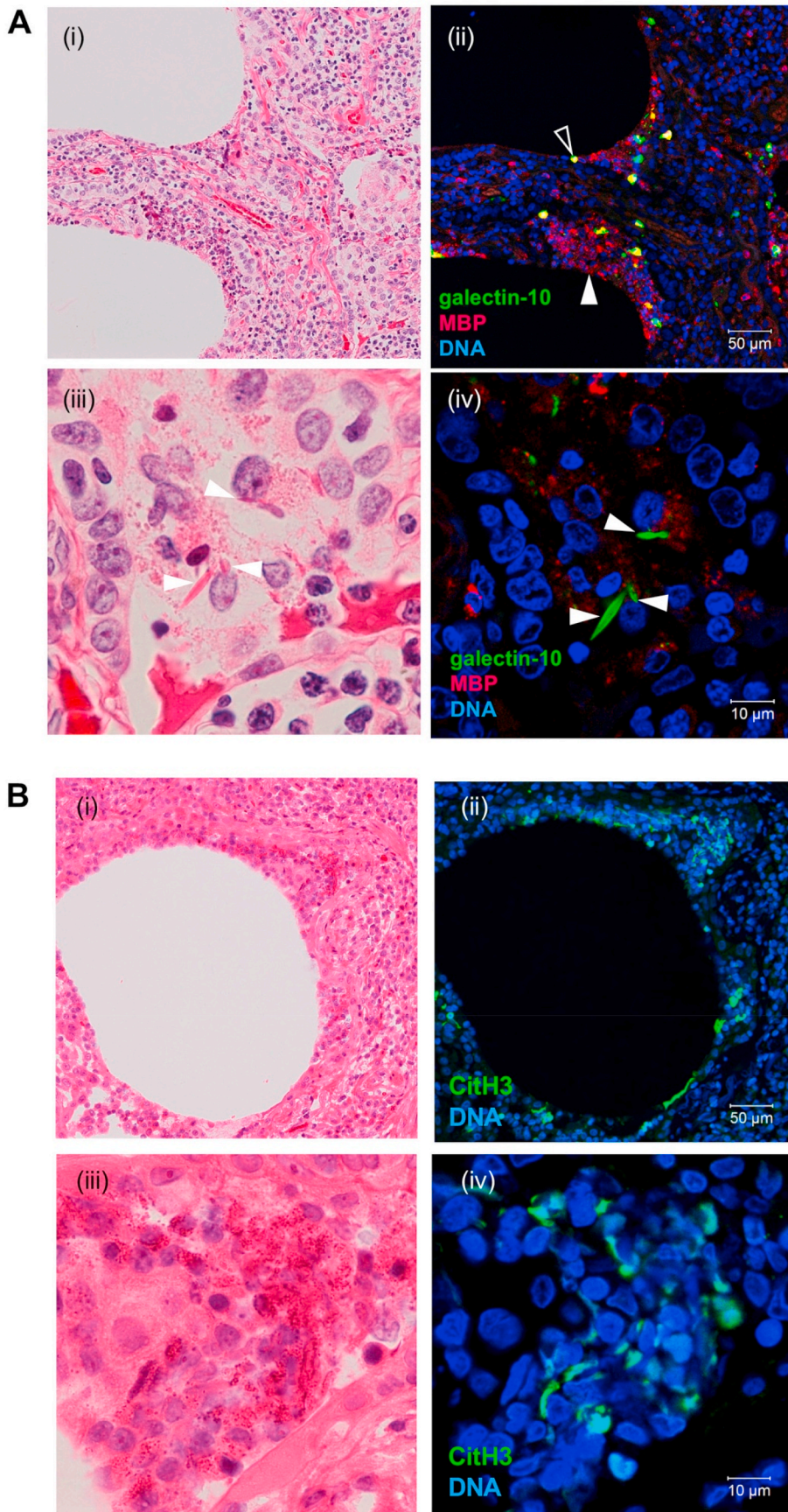


Fig. 3. Histology and immunostaining of a lung obtained throughout video-assisted thoracoscopic surgery. After immunofluorescence staining for the indicated targets (ii, iv), identical tissue slides were further stained with hematoxylin and eosin (H&E) (i, iii) and identical fields were compared. The open arrowhead in Aii indicates an example of an intact eosinophil containing a large amount of cytoplasmic galectin-10. In contrast, the closed arrowhead in Aii shows an area of granule protein deposition without galectin-10 staining, which indicates cytolytic degranulation. At a higher magnification, galectin-10-positive needle-like Charcot-Leyden crystals (CLCs; closed arrowheads in Aiv) and granular major basic protein (MBP) staining (cell-free granules) are visible. Bi-iv demonstrates the massive formation of a collection of chromatolytic cells with free eosinophilic granules/eosinophil extracellular traps, which stained positively for citrullinated histone 3 (citH3). The biopsy samples were fixed and processed as previously described. DNA was counterstained with Hoechst 33342 (blue). (For interpretation of the references to colour in this figure legend, the reader is referred to the Web version of this article.)

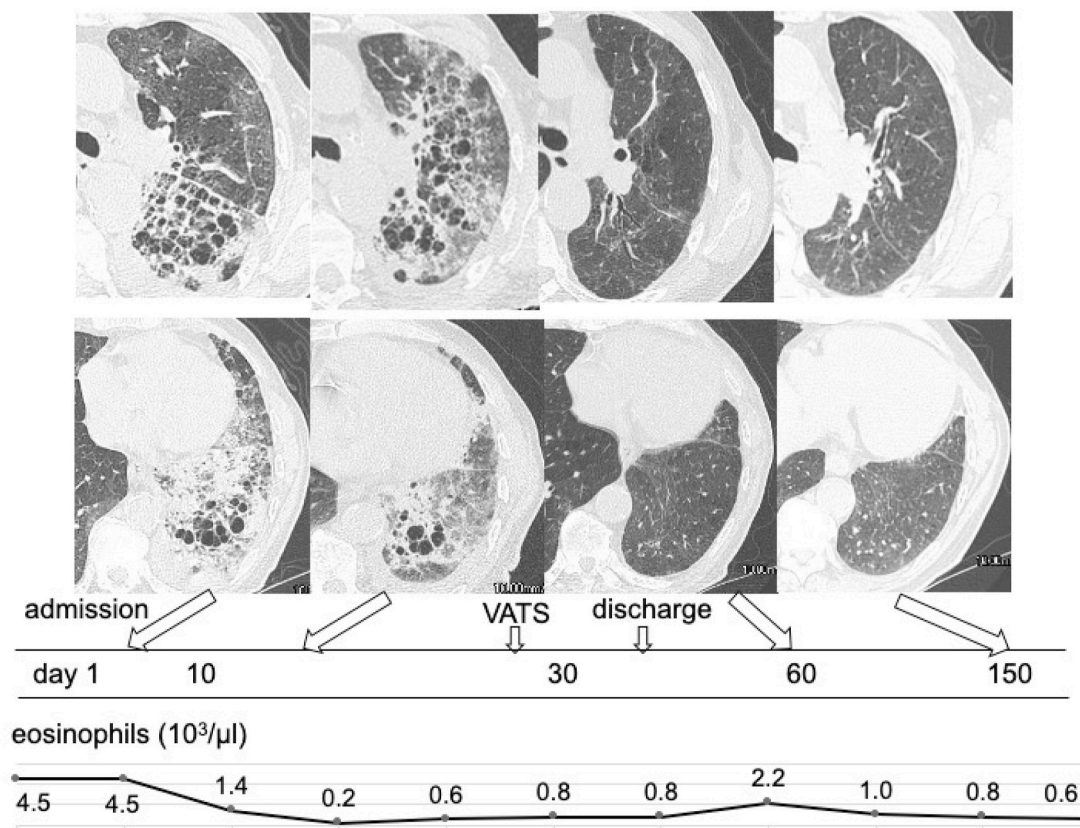


Fig. 4. The patient's clinical course. The patient's peripheral blood eosinophil count tended to decrease during a post-admission follow-up without treatment. Chest CT obtained on day 13 reveal that the extent of the lesions in the left upper lobe has increased. However, the extent of the lesions in the left lower lobe has decreased, and some cysts have become smaller. He was discharged on day 36.

case, no apparent cleft formation secondary to lung structure tears were detected in the microscopic necrotic lesions seen in the surgical lung biopsy specimen.

EETosis is a form of programmed cell death caused by the activation of eosinophils [10]. This phenomenon is similar to neutrophil extracellular trap cell death (NETosis). In EETosis, the nuclear and plasma membranes of the eosinophil are rapidly disrupted and filamentous chromatin are released, leading to tissue injury and enhanced coagulation reactions. These events underlie the involvement of EETosis in the pathologies of various allergic diseases [15]. Meanwhile, the Charcot-Leyden crystals (CLC) produced during EETosis may activate the Nod-like receptor family pyrin domain-containing 3 inflammasome in macrophages, leading to the production of proinflammatory cytokines and increased local inflammation [16].

The detection of EETs, CLCs, and MBP in the lesions led us to assume that the cysts were formed via the following mechanism. First, EETosis due to the over-activation and degranulation of eosinophils caused severe tissue-damaging inflammation, resulting in necrosis and tearing of the alveolar walls. Second, cysts were formed consequent to the clearance of necrotic debris and collapse of airspaces in the inflammatory lesions. Third, the alveolar spaces in the lesions expanded to reduce the tissue defects after a subsequent spontaneous resolution. In our case, the formation of thin-walled cysts might have been associated variably with a mechanism similar to that proposed by Ihms et al [14]. Additionally, the severe tissue-damaging inflammation might have led to the continuous accumulation of leaked air in the tissue defects, leading to pulmonary pneumatoceles [17,18]. Regarding the self-limiting course of lung lesions, the following points should be considered: 1) eosinophils contain far lower levels of proteases, compared to neutrophils [19], and 2) eosinophils are not merely tissue-damaging cells but are also a potent source of anti-inflammatory mediators [20]. We speculate that the

extensive eosinophilic necrotic inflammation in this case may be because of exposure to high concentrations of the substance in the unsanitary home environment.

3.2. Differential diagnosis

The pathological features of our case appeared to mimic those of ICEP, given the patient's chronic course and peripheral eosinophilia. However, his pathological features, particularly the highly prominent eosinophilic abscesses, were much more severe than those of ordinary ICEP. The possibility of EGPA could not be pathologically excluded, but it appeared to be unlikely because of the lack of signs of vasculitis, history of allergic diseases, and physical findings suggestive of vasculitis. In addition, a parasitic infection appeared unlikely based on results of screening for serum anti-parasite antibodies (multiple-dot enzyme-linked immunoassay), and pathological findings.

Based on the patient's spontaneous resolution in the hospital, we assumed that his condition was due to a hypersensitivity reaction induced by unknown antigen in the home environment. Such a clinical picture is reminiscent of hypersensitivity pneumonia. Xu et al. reported elevated serum eosinophil cationic protein levels in more than half of the patients with lung biopsy-confirmed hypersensitivity pneumonia of unknown etiology [21]. However, in terms of pathology of hypersensitivity pneumonia, eosinophils are not prominent, although they may be occasionally observed; eosinophilic abscesses have also not been reported [22,23]. Nevertheless, similar to hypersensitivity pneumonia, eosinophilic lung disease may also spontaneously resolve [1,24]. Furthermore, environmental fungal components such as *Alternaria*, *Penicillium*, and *Aspergillus* can reportedly directly activate eosinophils [25–27].

4. Conclusions

We have reported a unique case of eosinophilic necrotizing inflammation that mimicked chronic eosinophilic pneumonia. We consider this case valuable because it demonstrates that the severe tissue injury associated with EETosis/EETs and CLCs may induce the formation of multiple cysts that resolve spontaneously. Additional cases are needed for a further elucidation of the underlying pathology.

Patient consent

This study was carried out in accordance with the ethical principles of the Declaration of Helsinki and written informed consent to publish the findings was obtained from the patient.

Declaration of interest

The authors declare that there are no competing interests regarding the publication of this case report.

Acknowledgements

We are grateful to Noriko Tan for technical assistance. This study was funded in part by a Research Grant on Allergic Disease and Immunology from the Japan Agency for Medical Research and Development (JP20ek0410055), The Mochida Memorial Foundation for Medical and Pharmaceutical Research, the Japanese Society of Laboratory Medicine Fund for Promotion of Scientific Research, JSPS KAKENHI (20K08794) to SU. The rest of authors received no financial support for the research, authorship, and/or publication of this article.

References

- [1] E. Marchand, M. Reynaud-Gaubert, D. Lauque, J. Durieu, A.B. Tonnel, J.F. Cordier, Idiopathic chronic eosinophilic pneumonia. A clinical and follow-up study of 62 cases, *Medicine (Baltim.)* 77 (5) (1998 Sep) 299–312, <https://doi.org/10.1097/00005792-199809000-00001>.
- [2] T. Johkoh, N.L. Müller, M. Akira, K. Ichikado, M. Suga, M. Ando, T. Yoshinaga, T. Kiyama, N. Mihara, O. Honda, N. Tomiyama, H. Nakamura, Eosinophilic lung diseases: diagnostic accuracy of thin-section CT in 111 patients, *Radiology* 216 (3) (2000 Sep) 773–780, <https://doi.org/10.1148/radiology.216.3.r00se01773>.
- [3] A.A. Liebow, C.B. Carrington, The eosinophilic pneumonias, *Medicine (Baltim.)* 48 (4) (1969 Jul) 251–285, <https://doi.org/10.1097/00005792-196907000-00001>.
- [4] Chronic eosinophilic pneumonia, in: P. Hasleton, D.B. Flieder (Eds.), *Spencer's Pathology of the Lung*, sixth ed., Cambridge University Press, 2013, pp. 568–573.
- [5] J. Churg, L. Strauss, Allergic granulomatosis, allergic angiitis, and periarteritis nodosa, *Am. J. Pathol.* 27 (2) (1951 Mar-Apr) 277–301.
- [6] E.C. Bayley, D.O. Lindberg, A.H. Baggenstoss, Loeffler's syndrome; report of a case with pathologic examination of the lungs, *Arch. Pathol.* 40 (1945 Nov-Dec) 376–381.
- [7] M. Furuiye, N. Yoshimura, A. Kobayashi, M. Tamaoka, Y. Miyazaki, Y. Ohtani, S. Miyake, N. Inase, Y. Yoshizawa, Churg-Strauss syndrome versus chronic eosinophilic pneumonia on high-resolution computed tomographic findings, *J. Comput. Assist. Tomogr.* 34 (1) (2010 Jan) 19–22, <https://doi.org/10.1097/RCT.0b013e3181ae2949>.
- [8] D.E. Amundson, Cavitary pulmonary cryptococcosis complicating Churg-Strauss vasculitis, *South. Med. J.* 85 (7) (1992 Jul) 700–702, <https://doi.org/10.1097/00007611-199207000-00007>.
- [9] G.E. Degeys, R.A. Mintzer, R.F. Vrla, Allergic granulomatosis: Churg-Strauss syndrome, *AJR Am. J. Roentgenol.* 135 (6) (1980 Dec) 1281–1282, <https://doi.org/10.2214/ajr.135.6.1281>.
- [10] S. Ueki, R.C. Melo, I. Ghiran, L.A. Spencer, A.M. Dvorak, P.F. Weller, Eosinophil extracellular DNA trap cell death mediates lytic release of free secretion-competent eosinophil granules in humans, *Blood* 121 (11) (2013 Mar 14) 2074–2083, <https://doi.org/10.1182/blood-2012-05-432088>. Epub 2013 Jan 9.
- [11] S. Ueki, T. Tokunaga, R.C.N. Melo, H. Saito, K. Honda, M. Fukuchi, Y. Konno, M. Takeda, Y. Yamamoto, M. Hirokawa, S. Fujieda, L.A. Spencer, P.F. Weller, Charcot-Leyden crystal formation is closely associated with eosinophil extracellular trap cell death, *Blood* 132 (20) (2018 Nov 15) 2183–2187, <https://doi.org/10.1182/blood-2018-04-842260>. Epub 2018 Aug 28.
- [12] E.K. Persson, K. Verstraete, I. Heyndrickx, E. Gevaert, H. Aegerter, J.M. Percier, K. Deswarte, K.H.G. Verschuere, A. Dansercoer, D. Gras, P. Chanez, C. Bachert, A. Gonçalves, H. Van Gorp, H. De Haard, C. Blanchetot, M. Saunders, H. Hammad, S.N. Savvides, B.N. Lambrecht, Protein crystallization promotes type 2 immunity and is reversible by antibody treatment, *Science* 364 (6442) (2019 May 24), eaaw4295, <https://doi.org/10.1126/science.aaw4295>.
- [13] V.S. Muniz, J.C. Silva, Y.A.V. Braga, R.C.N. Melo, S. Ueki, M. Takeda, A. Hebisawa, K. Asano, R.T. Figueiredo, J.S. Neves, Eosinophils release extracellular DNA traps in response to *Aspergillus fumigatus*, e7, *J. Allergy Clin. Immunol.* 141 (2) (2018 Feb) 571–585, <https://doi.org/10.1016/j.jaci.2017.07.048>. Epub 2017 Sep. 21.
- [14] E.A. Ihms, M.E. Urbanowski, W.R. Bishai, Diverse cavity types and evidence that mechanical action on the necrotic granuloma drives tuberculous cavitation, *Am. J. Pathol.* 188 (7) (2018) 1666–1675, <https://doi.org/10.1016/j.ajpath.2018.04.006>. Epub 2018 May 23.
- [15] M. Mukherjee, P. Lacy, S. Ueki, Eosinophil extracellular traps and inflammatory pathologies-untangling the Web!, *Front. Immunol.* 9 (2018 Nov 26) 2763, <https://doi.org/10.3389/fimmu.2018.02763>, eCollection 2018.
- [16] J.F. Rodríguez-Alcázar, M.A. Ataide, G. Engels, C. Schmitt-Mabumnyo, N. Garbi, W. Kastentmüller, E. Latz, B.S. Franklin, Charcot-leyden crystals activate the NLRP3 inflammasome and cause IL-1 β inflammation in human macrophages, *J. Immunol.* 202 (2) (2019 Jan 15) 550–558, <https://doi.org/10.4049/jimmunol.1800107>. Epub 2018 Dec 17.
- [17] Acquired lesions of the lung and pleura, in: G.W. Holcomb, J.P. Murphy (Eds.), *Ashcraft's Pediatric Surgery, fifth ed.*, Saunders, 2010, pp. 290–303.
- [18] M.J. Quigley, R.S. Fraser, Pulmonary pneumatocele: pathology and pathogenesis, *AJR Am. J. Roentgenol.* 150 (6) (1988 Jun) 1275–1277, <https://doi.org/10.2214/ajr.150.6.1275>.
- [19] S. Ueki, Y. Konno, M. Takeda, Y. Moritoki, M. Hirokawa, Y. Matsuwaki, K. Honda, N. Ohta, S. Yamamoto, Y. Takagi, A. Wada, P.F. Weller, Eosinophil extracellular trap cell death-derived DNA traps: their presence in secretions and functional attributes, *J. J. Allergy Clin Immunol* 137 (1) (2016 Jan) 258–267, <https://doi.org/10.1016/j.jaci.2015.04.041>. Epub 2015 Jun 9.
- [20] Y. Isobe, T. Kato, M. Arita, Emerging roles of eosinophils and eosinophil-derived lipid mediators in the resolution of inflammation, *Front. Immunol.* 3 (2012 Aug 28) 270, <https://doi.org/10.3389/fimmu.2012.00270>, eCollection 2012.
- [21] J.F. Xu, L. Shen, Y. Zhang, P. Zhang, J.M. Qu, H.P. Li, Lung biopsy-proved hypersensitivity pneumonitis without known offending antigen: characteristics and follow-up, *Clin. Res. J* 8 (3) (2014 Jul) 297–304, <https://doi.org/10.1111/crj.12071>. Epub 2014 Jan 16.
- [22] Hypersensitivity pneumonitis: a review and update of histologic findings. Grunes D, Beasley MB, J. Clin. Pathol. 66 (10) (2013 Oct) 888–895, <https://doi.org/10.1136/jclinpath-2012-201337>. Epub 2013 Jul 23. Review.
- [23] Hypersensitivity pneumonitis, in: P. Hasleton, D.B. Flieder (Eds.), *Spencer's Pathology of the Lung*, sixth ed., Cambridge University Press, 2013, pp. 439–474.
- [24] T. Iwami, S. Umemoto, K. Ikeda, H. Yamada, M. Matsuzaki, A case of acute eosinophilic pneumonia. Evidence for hypersensitivity-like pulmonary reaction, *Chest* 110 (6) (1996 Dec) 1618–1621, <https://doi.org/10.1378/chest.110.6.1618>.
- [25] Y. Inoue, Y. Matsuwaki, S.H. Shin, Ponikau Ju, H. Kita, Nonpathogenic, environmental fungi induce activation and degranulation of human eosinophils, *J. Immunol.* 175 (8) (2005 Oct 15) 5439–5447, <https://doi.org/10.4049/jimmunol.175.8.5439>.
- [26] R.T. Figueiredo, J.S. Neves, Eosinophils in fungal diseases: an overview, *J. Leukoc. Biol.* 104 (1) (2018 Jul) 49–60, <https://doi.org/10.1002/JLB.4MR1117-473R>. Epub 2018 Mar 9.
- [27] S. Ueki, A. Hebisawa, M. Kitani, K. Asano, J.S. Neves, Allergic bronchopulmonary aspergillosis-A luminal hyper-eosinophilic disease with extracellular trap cell death, *Front. Immunol.* 9 (2018 Oct 11) 2346, <https://doi.org/10.3389/fimmu.2018.02346>, eCollection 2018.