



Access this article online

Quick Response Code:



Website:

<https://turkjemergmed.com/>

DOI:

10.4103/tjem.tjem\_219\_23

# Pattern and clinical profile of patients with ocular trauma presenting to the emergency department of a teaching hospital in India: A prospective observational study

Sandip Kumar Sahu<sup>1</sup>, Rakesh Vadakkethil Radhakrishnan<sup>2</sup>,  
Chitta Ranjan Mohanty<sup>3\*</sup>, Sucheta Parija<sup>1</sup>, Shanmugasundaram Palanisamy<sup>1</sup>,  
Priyadarshini Mishra<sup>1</sup>, Debasish Sadangi<sup>1</sup>

Departments of <sup>1</sup>Ophthalmology and <sup>2</sup>Trauma and Emergency, All India Institute of Medical Sciences, <sup>3</sup>College of Nursing, All India Institute of Medical Sciences, Bhubaneswar, Odisha, India  
\*Corresponding author

Submitted: 07-10-2023

Revised: 25-01-2024

Accepted: 01-02-2024

Published: 04-04-2024

ORCID:

SKS: 0000-0001-5764-1456

RVR: 0000-0003-1274-2354

CRM: 0000-0002-8525-2084

SP: 0000-0003-1637-8238

PM: 0000-0002-0069-209X

DS: 0009-0000-5914-9860

Address for  
correspondence:

Dr. Chitta Ranjan Mohanty,  
Department of Trauma  
and Emergency,  
All India Institute of  
Medical Sciences, Sijua,  
Bhubaneswar - 751 019,  
Odisha, India.  
E-mail: drchitta8@gmail.  
com

## Abstract:

**OBJECTIVES:** One major contributor to avoidable ocular morbidity is ocular trauma (OT). The study aimed to document the epidemiological factors, pattern of injury, and outcome among patients with OT presenting to the emergency department (ED).

**METHODS:** This was a prospective observational study conducted in the ED of a tertiary care teaching hospital in Eastern India after due approval from the institutional ethics committee. The data were collected during the period from March 2021 to February 2022. Data pertaining to age, sex, type of injury, mechanism of injury, time and place of injury, details of tissue involvement, visual acuity, any prior history of injury, initial diagnosis, and management were noted. To estimate the severity of the injury and the probable visual outcome, we calculated through OT score (OTS), including one raw score and OTS. Statistical analysis was performed using the R, version 4.6.1.

**RESULTS:** A total of 180 patient's data were included for final analysis. The median (interquartile range) age of the patients was 32 (24–45) years. The majority were males ( $n = 147$  [81.6%]) with a male–female ratio of 4.5:1. Road traffic accidents (RTA) were the common cause of injury ( $n = 122$  [67.7%]). Unilateral eye involvement was the most common ( $n = 147$  [81.6%]). In the pattern of injury, most of the patients sustained closed globe injuries (CGIs) ( $n = 158$  [87.7%]). Among the CGIs, injury to the ocular adnexa and conjunctiva ( $n = 141$  and 127, respectively) was the most common. Injury to the retina and choroids occurred in 20 (11%) patients. The vision was not affected in most of the cases ( $n = 125$  [69.4%]) with a visual acuity of  $> 6/18$ . The majority ( $n = 120$  [67%]) of the patients had an OTS of grade-4, followed by grade-2 ( $n = 22$  [12%]). Most of the patients required only medical management ( $n = 100$  [56%]), whereas 77 (43%) patients required surgical interventions.

**CONCLUSION:** OT was a common presentation in the ED. Male patients with monocular injuries involved in RTAs were mostly affected. The vision was preserved in most of the cases.

## Keywords:

Emergency department, ocular trauma, ocular trauma score, visual impairment

This is an open access journal, and articles are distributed under the terms of the Creative Commons Attribution-NonCommercial-ShareAlike 4.0 License, which allows others to remix, tweak, and build upon the work non-commercially, as long as appropriate credit is given and the new creations are licensed under the identical terms.

For reprints contact: WKHLRPMedknow\_reprints@wolterskluwer.com

**How to cite this article:** Sahu SK, Radhakrishnan RV, Mohanty CR, Parija S, Palanisamy S, Mishra P, *et al.* Pattern and clinical profile of patients with ocular trauma presenting to the emergency department of a teaching hospital in India: A prospective observational study. Turk J Emerg Med 2024;24:90-6.

**Box-ED section****What is already known on the study topic?**

- One major contributor to avoidable ocular morbidity is ocular trauma (OT)
- Initial interventions in the emergency department (ED) play a vital role in preventing prolonged morbidity and improving visual outcomes following OTs.

**What is the conflict on the issue? Has its importance for readers?**

- There exist only a few pieces of literature that have examined the epidemiological and injury patterns following OTs
- There is a need to have epidemiology and injury patterns of OTs presenting to ED, which is lacking in Indian literature.

**How is this study structured?**

- This was a single-center, prospective observational study that included data from 180 patients.

**What does this study tell us?**

- OT was a common presentation in the ED
- Male patients with monocular injuries involved in road traffic accidents were mostly affected
- There is a need to increase public awareness and strict implementation of safety guidelines and policies for the prevention of these OTs.

**Introduction**

Ocular trauma (OT) is an important public health issue that is predominantly preventable and influenced by multiple factors within rapidly changing global contexts.<sup>[1,2]</sup> It serves as a substantial cause of visual impairment and vision loss.<sup>[1]</sup> Population-based surveys have indicated that OT accounts for 20%–50% of cases of monocular blindness and 3.2%–5.5% of cases of bilateral blindness.<sup>[1,3]</sup> Unfortunately, the young productive age group becomes the most common victim, posing significant challenges in terms of functional incapacities, loss of productivity, and socioeconomic burden.<sup>[3-5]</sup> Ocular injuries are broadly categorized into open- and closed-globe injuries as per the widely accepted Birmingham Eye Trauma Terminology System (BETTS).<sup>[6]</sup> The severity of ocular injury encompasses a wide range of conditions, ranging from simple subconjunctival hemorrhage and lid laceration to even lens subluxation or dislocation, vitreous hemorrhage, retinal detachment, traumatic optic neuropathy, orbital fracture, and globe rupture.<sup>[4-7]</sup> Managing OT in the emergency department (ED) presents a clinical challenge where nonophthalmologists often become the initial responders. Initial interventions in the ED play a vital role in preventing prolonged morbidity and improving visual outcomes.<sup>[8,9]</sup> Ocular

injuries frequently accompany facial trauma with varying degrees of severity.<sup>[10]</sup> Inadequate management can result in blindness or severe visual impairment, leading to significant social, economic, and medicolegal implications.<sup>[9,10]</sup>

India is a densely populated country with vivid geographical and sociocultural zones, each representing diverse living and occupational patterns. Some literature exists on epidemiological features and patterns of ocular injuries from the northern and southern parts of India and their western counterparts.<sup>[2-5,8]</sup> However, the clinical and epidemiological correlates of ocular injuries among the eastern Indian population are not well documented in the literature. What is lacking is a detailed clinical profile and injury patterns among the victims of OT. The present study aims to comprehensively document the prevalence, injury patterns, severity, seasonal variation, and outcomes among OT patients presenting to the ED.

**Methods****Study design**

This was a prospective observational study conducted in the Departments of Trauma and Emergency and Ophthalmology of a tertiary care teaching hospital in Eastern India. Approval was obtained from the institutional ethics committee (T/IM/-NF/Ophthal/20/173, dated February 11, 2021, All India Institute of Medical Sciences).

**Participants**

All the OT patients with or without other associated injuries reporting to the ED diagnosed as OT (International Classification of Diseases-10: S05.0-9) were included in the study. Before any data were collected, written informed consent was obtained from each participant. Patients who have refused to give consent, are not able to comprehend questions, or are not accompanied by caregivers, and those referred from other centers after receiving treatment for ocular injuries were excluded from the study.

**Data collection and variables**

The data were collected during the period from March 2021 to February 2022. Data pertaining to age, sex, mode of injury, type of injury, mechanism of injury, time, and place of injury, details of tissue involvement, any associated injuries, visual acuity, any prior history of injury, initial diagnosis, and management, as well as the need for secondary management, plan, and follow-up, were recorded using a structured performa. OTs were classified according to the BETTS.<sup>[6]</sup> Closed globe injuries (CGIs) were classified as a contusion or a lamellar laceration. The open globe injuries (OGIs) were classified as a rupture, penetration, intraocular foreign body-related, or perforation. The visual acuity

was recorded with Snellen's visual acuity chart for patients having a Glasgow Coma Scale (GCS) of 15 or assessed later once they regained a GCS of 15 within our observation period. To assess the severity of ocular injuries and predict the potential visual outcomes of an open-globe OT, an OT score (OTS) was calculated for each patient in this study.<sup>[7]</sup> The OTS model incorporates raw scores ranging from 0 to 100, which are then used to determine OTS categories. These raw scores are based on initial visual acuity measurements as well as additional factors such as globe rupture, endophthalmitis, perforating injury, retinal detachment, and relative afferent pupillary defect. The resulting OTS values range from 1 to 5, where a score of 1 signifies the most severe injury and indicates the poorest prognosis at the 6-month follow-up, while a score of 5 represents the least severe injury and suggests the most favorable prognosis at the 6-month mark. Each individual score within the OTS system is linked to a particular range of predicted visual acuities after the injury. It is noteworthy that the OTS exhibits a predictive accuracy of approximately 80%.<sup>[7]</sup> The details of associated injuries were recorded according to the anatomical area affected. These included head injuries, maxillofacial injuries, spine injuries, chest injuries, abdominal injuries, extremity injuries, and soft-tissue injuries. The emergency management was recorded as medical, surgical, or both. The outcome was recorded as admission for surgical interventions, primary repair and management in the ED, medical management, and observation, or only observation and follow-up. The authors attest that the manuscript adheres to the standards of strengthening the reporting of observational studies in epidemiology guidelines for observational studies.

### Statistical analysis

The statistical analysis was performed using R version 4.6.1. (The R Foundation, Vienna, Austria). Categorical variables were presented as counts and percentages. The nonparametric numerical variables are expressed as median with interquartile ranges (IQR), and the parametric variables are expressed as mean  $\pm$  standard deviation. The Mann-Whitney *U*-test was used to compare nonparametric variables, and the *t*-test was used to compare parametric variables. A level of  $P < 0.05$  was considered statistically significant.

## Results

A total of 180 patients' data were included for final analysis. The study flow diagram is depicted in Figure 1. The median (IQR) age of the patients was 32 (24–45) (range) years. The majority were males ( $n = 147$  [81.6%]), with a male–female ratio of 4.5:1. Road traffic accidents (RTAs) were the most common cause of injury ( $n = 122$  [67.7%]), followed by

accidental self-injuries ( $n = 16$  [8.8%]). Most of the injuries occurred in public places ( $n = 127$  [70.5%]), followed by household settings ( $n = 37$  [20.5%]). Unilateral eye involvement was most common ( $n = 147$  [81.6%]), and right eye involvement was more common than left eye involvement (121 vs. 92). The time of injury was 4–8 pm in most of the patients ( $n = 69$  [38.3%]). The mechanism of injury was self-fall from moving objects in most of the cases ( $n = 118$  [66%]), followed by injury from blunt objects ( $n = 27$  [15%]). Among the 122 RTA victims, 112 (92%) were occupants of two-wheelers. One hundred ten (98%) of the occupants of the two-wheeler were not wearing helmets during the RTA and suffered OT. Out of the 15 occupational injuries, none of the victims had any protective eyewear at the time of injury. Almost 22 (12%) were intoxicated with psychoactive substances at the time of injury. The details are depicted in Table 1.

In the pattern of injury, most of the patients sustained CGIs ( $n = 158$  [87.7%]), and 22 (12.2%) patients sustained OGI with a CGI to OGI ratio of 7.18:1. Among the CGIs, injuries

**Table 1: Sociodemographic and epidemiological variables of ocular trauma victims ( $n=180$ )**

Variable	Class	Frequency (%)
Age (years), median (IQR)	32 (24–45)	
Gender	Male	147 (81.6)
	Female	33 (18.3)
Time of injury	12 pm–4 pm	35 (19.4)
	4 pm–8 pm	69 (38.3)
	8 pm–12 am	33 (18.3)
	12 am–4 am	10 (5.5)
	4 am–8 am	8 (4.4)
	8 am–12 pm	25 (13.8)
Type of trauma	Road traffic accident	122 (67.7)
	Physical assault	13 (7.2)
	Occupational injury	15 (8.3)
	Self-injury	16 (8.8)
	Blast injury	8 (4.4)
	Others	6 (3.3)
Mechanism of injury	Fall from a moving object	118 (65.5)
	Injury by sharp objects	14 (7.7)
	Injury by blunt objects	27 (15)
	Injury by animals	3 (1.6)
	Blast injury	18 (10)
	Others	2 (1.1)
Place of injury	Street/public places	127 (70.5)
	Home	37 (20.5)
	Industries	8 (4.4)
	Farmland	6 (3.3)
	School	1 (0.6)
	Others	1 (0.6)
Eye protective wear	Yes	2 (1.2)
	No	178 (98.8)
Substance intoxication	Yes	22 (12)
	No	158 (88)

IQR: Interquartile range

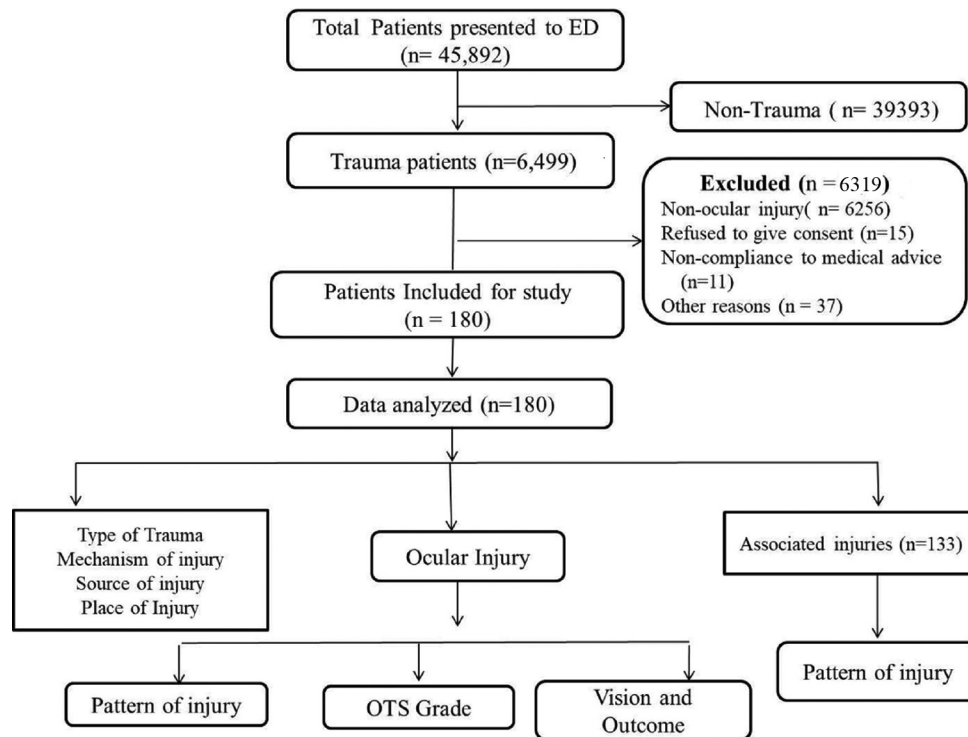


Figure 1: The flow diagram of the study. ED: Emergency department, OTS: Ocular trauma score

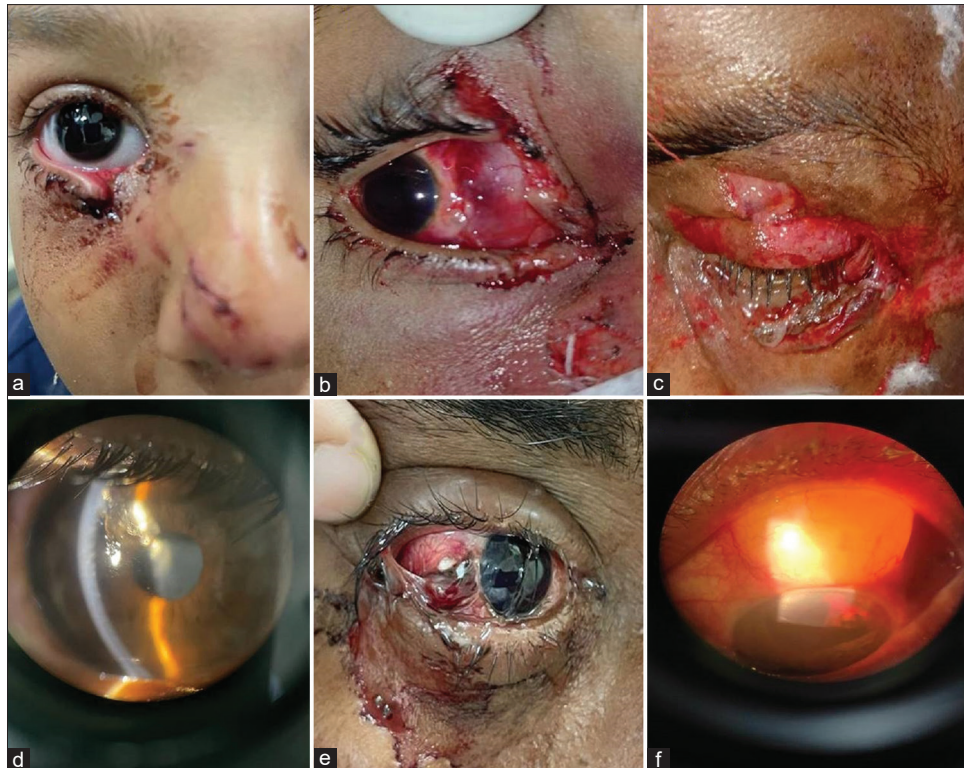to the ocular adnexa and conjunctiva ( $n = 141$  and  $127$ , respectively) were the most common. Injury to the retina and choroids occurred in 20 (11%) patients. The clinical image showing the pattern of ocular injuries is depicted in Figure 2. One patient sustained an injury to the optic nerves. One hundred and thirty-three (73.1%) patients sustained associated injuries along with ocular injuries. Maxilla-facial injury ( $n = 120$ ) was the most associated injury, followed by head injury ( $n = 62$ ). The vision was not affected in most of the cases ( $n = 125$  [69.4%]) with a visual acuity of  $>6/18$ . The majority ( $n = 120$  [67%]) of the patients had an OTS of grade 4, followed by grade 2 ( $n = 22$  [12%]). Most of the patients required only medical management ( $n = 100$  [56%]), whereas 77 (43% of patients) required surgical interventions along with medical management. As per the OTS, the visual outcomes are fair: 15 (8%) patients, good: 134 (74%), poor: 26 (14%), and very poor: Five (3%) patients. The details are depicted in Table 2. One hundred and thirty-six (75.5%) patients were discharged from the ED after primary treatment; 22 (12.2%) patients required inpatient treatments for surgical interventions and evaluation in the ophthalmology department; 18 (10%) patients were admitted to other surgical departments; and two (1%) patients left against medical advice from the ED. To validate the OTS scale for predicting visual outcomes, a follow-up evaluation was done at 6 months for the 22 OGI patients and found that 17 (77.27%) patients accurately predicted their visual acuity by the initial OTS score.

## Discussion

This prospective observational study involved 180 patients who sought treatment at a tertiary care hospital's ED due to OT. The young, productive male population in their 3<sup>rd</sup>–4<sup>th</sup> decades of life involved in RTAs becomes the common victims. Most injuries occurred in public places with blunt objects as the source of injury. The majority sustained a unilateral eye injury. CGIs were the most common injury pattern, with the involvement of the lids and conjunctiva. The vision was unaffected in most of the victims, with the majority having an OTS score of grade 4, indicating a good visual prognosis.

The current study revealed a higher prevalence of OT among males, with a male-to-female ratio of 4.5:1. These findings are consistent with previous research conducted in India and other regions, which also reported a significant gender bias toward males in ocular injury cases.<sup>[2-5]</sup> The male gender typically assumes the role of breadwinner within their families and often engages in more outdoor activities and occupational settings compared to their female counterparts, thereby increasing their susceptibility to various injuries, including OT. A study from northern India by Mohanty *et al.*<sup>[11]</sup> reported that the 21–30-year-old age group was the most affected by OT, which aligns with our study population. Earlier epidemiological studies have documented age as an important predictive factor for





**Figure 2:** The Clinical image showing pattern of ocular injuries. (a) Lid injury with lacerated nose injury, (b) Close globe injury with conjunctival tear, (c) multiple lid laceration with lower lid avulsion, (d) open globe injury with corneal tear and a metallic foreign body over iris, (e) open globe injury - scleral tear with choroid and vitreous prolapse, (f) open globe injury with Phacocele and Anterior Chamber Hyphema

ocular injuries, with the younger population having higher odds of injury than old age.<sup>[2-5]</sup> In contrast, Belmonte-Grau *et al.*,<sup>[8]</sup> in their study on the Spanish population, reported a mean age of 54 years among the victims of OT. Another study by Choovuthayakorn *et al.*<sup>[12]</sup> on the Asian population revealed age differences between genders in ocular injuries and observed a mean age of 39.8 (22.9) years for females and 43.8 (17.8) years for males. Notably, studies by Belmonte-Grau *et al.* and Choovuthayakorn *et al.* had domestic accidents and workplace injuries, respectively, as the major cause of OT in contrast to RTAs in the present study, which may partially explain the mean age difference between these studies.<sup>[8,12]</sup> The higher incidence of ocular injuries among the young and productive age group has long-lasting effects on their productivity and imposes a significant economic burden on both the affected individuals' families and society at large.

The study noted RTAs as the most common cause of OT, followed by accidental self-injury. The findings contrast with epidemiological studies from most Western countries such as Spain, the USA, and Korea, where occupational injuries and domestic accidents are the major causes of ocular injury.<sup>[5,8,13]</sup> The study done on the Singapore population by Voon *et al.*<sup>[14]</sup> also reported occupational injuries as the most common mode of injury among OT victims. India is a developing country

with an enormous burden of mortality and morbidity from RTAs and unintentional injuries where adherence to safety guidelines, protective wear, and conducive environmental factors such as road infrastructure are suboptimal. However, earlier studies in northern and southern India also reported that RTAs are the major cause of ocular injuries in their injury victims.<sup>[2,9]</sup> The study center was also a tertiary care center located near national highways, with a high load of RTA cases, ferried to the ED as the first treatment center. The high incidence of RTAs could be partially attributed to this fact. Earlier studies showed occupational injury is the most common mode, with differences in work types between countries.<sup>[4,12,14,15]</sup> Kinderan *et al.*<sup>[15]</sup> reported the pattern of ocular injuries among the western Nepal population and found injuries by sticks as the common mechanism of ocular injuries, followed by injuries from human body parts such as hands and fists. Choovuthayakorn *et al.*,<sup>[12]</sup> in their study from Taiwan, reported occupational injury as the most common mode, particularly with wooden objects or flying objects from an electrical grass trimmer. In our study, only 15 (8%) had OT in an occupational setting. The difference could be due to the center being a tertiary care setup located in an urban setting.

The study observed that the specific mechanism of ocular injury was that eye injuries predominantly occurred by falling from a moving vehicle (118, 66%), followed

**Table 2: Clinical variables of ocular trauma victims (n=180)**

Variable	Class	Frequency (%)
Eye involved	Left	59 (33)
	Right	88 (49)
	Both	33 (18)
Tissue involved	Adnexa	141 (78)
	Conjunctiva	127 (71)
	Anterior segment	35 (19)
	Choroid and posterior segment	20 (11)
	Extra-ocular muscle	90 (50)
	Nerve injury	1 (0.5)
	Associated injuries (n=133; 73.9%)	No associated injuries
	Ear	3 (2)
	Nose	14 (8)
	Maxilla-facial	120 (67)
	Head injury	62 (34)
	Spine injury	2 (1)
	Other injuries	11 (6)
Vision (codes)	0 (NPL)	4 (2)
	1 (PL PR-HM)	11 (6)
	2 (> HM-6/60)	14 (8)
	3 (>6/60-6/18)	5 (3)
	4 (>6/18-6/6)	125 (69)
	Could not be assessed	21 (12)
OTS raw score, median (IQR)	90 (90-90) (37-100)	
OTS grade	1 (0-44)	8 (4)
	2 (45-65)	22 (12)
	3 (66-80)	12 (7)
	4 (81-91)	120 (67)
	5 (>91)	18 (10)
Initial diagnosis	Close globe	158 (88)
	Open globe (penetrating/perforating)	22 (12)
Initial management	Medical	100 (56)
	Surgical	77 (43)
	Observation	2 (1)
Outcome	Fair	15 (8)
	Good	134 (74)
	Poor	26 (14)
	Very poor	5 (3)

OTS: Ocular trauma score, PL PR: Perception of light projection of rays, HM: Hand movement, NPL: No perception of light, IQR: Interquartile range

by blunt injury (27, 15%) and sharp objects (14, 8%), respectively. Out of 122 RTA victims, 112 patients were drivers or pillion riders of two-wheelers and 110 of them did not have helmets at the time of the accident. Similarly, out of the 15 patients with occupational injuries, none had any protective eyewear at the time of the accident. The study findings corroborate the Voon *et al.*<sup>[14]</sup> study from Singapore, which reported that only 21.4% of occupational eye injury victims used eye protective devices at the time of injury. Wearing protective gear such as a helmet can substantially reduce OT during RTAs, and compulsory protective eyewear such as goggles can reduce the incidence of ocular

injuries in occupational settings.<sup>[16-19]</sup> The study observed that evening time (4-8 pm) was the most common time of OT. This could be attributed to the fact that most OT victims sustained injuries following RTAs, and there is a high incidence of RTAs during this evening time, as reported by earlier epidemiological studies from eastern India.<sup>[18,19]</sup> The study observed that 22 (12%) victims were intoxicated with psychoactive substances at the time of OT. These factors can alter the attention and judgmental capacity of road users and workers and predispose them to various kinds of trauma, including OTs.

The study observed that 147 patients had mono-ocular injuries, with involvement of the right eye more than the left eye (121 vs. 92). Regarding the injury pattern, the majority of patients experienced CGIs, accounting for 87.7% of cases, while OGIs were observed in 12.2% of patients. The findings are in line with a study by Park *et al.*<sup>[5]</sup> and Kinderan *et al.*<sup>[15]</sup> that reported more CGIs than OGIs in their subjects of ocular injuries. However, Choovuthayakorn *et al.*<sup>[12]</sup> in their study on the Thai population, reported a marginally higher proportion of OGIs than CGIs (48.6% vs. 43.8%). Choovuthayakorn *et al.*<sup>[12]</sup> observed that contusions and lamellar lacerations were the most common injury patterns in their subjects with CGIs.

The study observed that 133 (73.1%) patients sustained associated injuries along with ocular injuries, with maxilla-facial injury ( $n = 120$ ) as the most common associated injury, followed by head injury ( $n = 62$ ). The findings are in line with a study by Park *et al.*<sup>[5]</sup> that reported 50.2% of blow-out fractures among subjects with ocular injuries being complex orbital and facial fractures. The study observed that 125 (69.4%) subjects had a visual acuity of >6/18, indicating no visual impairment following OT. A population-based study from South India by Krishnaiah *et al.*<sup>[3]</sup> reported unilateral blindness in 39 out of 824 subjects who sustained ocular injuries. The findings corroborate a study by Kinderan *et al.* that reported that 74.8% of subjects regained normal vision following the OT, as per the World Health Organization criteria.<sup>[15]</sup>

The present study graded the OT in the subjects as per the OTS and found that the majority were in OTS grade IV (67%). Only a few epidemiological studies documented the severity and visual outcome as per the OTS.<sup>[5]</sup> The initial OTS score following OT was documented to be a good predictor of visual prognosis and was first introduced by Kuhn *et al.*<sup>[7]</sup> Park *et al.*<sup>[5]</sup> in their study from Korea, reported that out of 37.1% of subjects who graded with OTS, the majority belonged to the grade-V OTS category, followed by grade-IV. The present study observed that only 22 patients had OGI. A follow-up evaluation was done for all 22 patients at 6 months after initial interventions. The study found

the predictive accuracy of OTS to be 77.27%. Out of 22 OGI patients, the visual outcomes of 17 patients were accurately predicted: Two patients with a better visual outcome and three patients with a worse outcome.

### Limitations

It was a single-center data on ocular injuries in the eastern geographical part of a densely populated country. The study center was a tertiary care center and many patients with minor ocular injuries would have taken treatment from a local hospital without presenting to the study center.

### Conclusion

OT is a common presentation of ED, with RTAs emerging as the predominant causative factor. This affliction predominantly affects the young and economically active male population. A unilateral, closed globe ocular injury is the most frequently observed presentation. The vision remains unimpaired in most of the victims, as indicated by a majority achieving an OTS grade of 4, signifying a favorable visual prognosis. OTS scores have a good predictive accuracy for visual prognosis following OGI which can be used for counseling the patient before any procedure. Wearing a helmet is a protective factor for the prevention of ocular injury in the case of RTA, while the utilization of protective gear such as goggles serves as a preventive measure in occupational settings.

### Author contributions statement

SKS and CRM: Conceptualization (lead); Methodology (lead); Writing – original draft (Support); Software and investigation (Lead), Writing – review and editing (equal). RVR and SP: Writing – original draft (Lead, equal), Software and investigation (Support), and writing – review and editing (support, equal). SPS, PM and DS: Writing – review and editing, Visualization. CRM did the overall supervision of the whole study, and all authors had made a substantial contribution. All authors have read and agreed on the content of the final manuscript.

### Conflicts of interest

None Declared.

### Ethical approval

Approval was obtained from the institute ethics committee of All India Institute of Medical Sciences, Bhubaneswar (T/IM/-NF/Ophthal/20/173, dated February 11, 2021).

### Declaration of patient consent

The authors certify that they have obtained all appropriate patient consent forms. In the form the patient(s) has/have given his/her/their consent for his/her/their images and other clinical information to be reported in the journal. The patients understand that their names and initials will not be published and due efforts will be made to conceal their identity, but anonymity cannot be guaranteed.

### Funding

None.

### References

- Négre AD, Thylefors B. The global impact of eye injuries. *Ophthalmic Epidemiol* 1998;5:143-69.
- Qayum S, Anjum R, Garg P. Epidemiological pattern of ocular trauma in a tertiary hospital of Northern India. *Int J Biomed Res* 2016;7:420-2.
- Krishnaiah S, Nirmalan PK, Shamanna BR, Srinivas M, Rao GN, Thomas R. Ocular trauma in a rural population of Southern India: The Andhra Pradesh Eye Disease Study. *Ophthalmology* 2006;113:1159-64.
- Vats S, Murthy GV, Chandra M, Gupta SK, Vashist P, Gogoi M. Epidemiological study of ocular trauma in an urban slum population in Delhi, India. *Indian J Ophthalmol* 2008;56:313-6.
- Park J, Yang SC, Choi HY. Epidemiology and clinical patterns of ocular trauma at a level 1 trauma center in Korea. *J Korean Med Sci* 2021;36:e5.
- Kuhn F, Morris R, Witherspoon CD, Mester V. The Birmingham Eye Trauma Terminology system (BETT). *J Fr Ophtalmol* 2004;27:206-10.
- Kuhn F, Maisiak R, Mann L, Mester V, Morris R, Witherspoon CD. The Ocular Trauma Score (OTS). *Ophthalmol Clin North Am* 2002;15:163-5, vi.
- Belmonte-Grau M, Garrido-Ceca G, Marticorena-Álvarez P. Ocular trauma in an urban Spanish population: Epidemiology and visual outcome. *Int J Ophthalmol* 2021;14:1327-33.
- Raiturcar TA, Naik PG, Cacodcar JA. Clinical profile and visual outcome of ocular injuries presenting at a tertiary care hospital in Goa. *J Clin Ophthalmol Res* 2019;7:41-4.
- Magarakis M, Mundinger GS, Kelamis JA, Dorafshar AH, Bojovic B, Rodriguez ED. Ocular injury, visual impairment, and blindness associated with facial fractures: A systematic literature review. *Plast Reconstr Surg* 2012;129:227-33.
- Mohanty L, Bhayani J, Shah A, Patel N, Patel A. Clinical profile of ocular trauma in a tertiary care hospital of Southern Rajasthan. *Int J Res Med Sci* 2022;10:127.
- Choovuthayakorn J, Worakriangkrai V, Patikulsila D, Watanachai N, Kunavisarut P, Chaikitmongkol V, *et al.* Epidemiology of eye injuries resulting in hospitalization, a referral hospital-based study. *Clin Ophthalmol* 2020;14:1-6.
- McGwin G Jr., Owsley C. Incidence of emergency department-treated eye injury in the United States. *Arch Ophthalmol* 2005;123:662-6.
- Voon LW, See J, Wong TY. The epidemiology of ocular trauma in Singapore: Perspective from the emergency service of a large tertiary hospital. *Eye (Lond)* 2001;15:75-81.
- Kinderan YV, Shrestha E, Maharjan IM, Karmacharya S. Pattern of ocular trauma in the Western region of Nepal. *Nepal J Ophthalmol* 2012;4:5-9.
- Chatterjee S, Agrawal D. Primary prevention of ocular injury in agricultural workers with safety eyewear. *Indian J Ophthalmol* 2017;65:859-64.
- Liu BC, Ivers R, Norton R, Boufous S, Blows S, Lo SK. Helmets for preventing injury in motorcycle riders. *Cochrane Database Syst Rev*. 2008;1: CD004333.
- Jain M, Radhakrishnan RV, Mohanty CR, Behera S, Singh AK, Sahoo SS, *et al.* Clinicoepidemiological profile of trauma patients admitting to the emergency department of a tertiary care hospital in Eastern India. *J Family Med Prim Care* 2020;9:4974-9.
- Sasmal PK, Mohanty CR, Jain M, Radhakrishnan RV, Sahoo S, Krishna VS, *et al.* The effect of 'THE MOTOR VEHICLES (AMENDMENT) ACT, 2019' on the clinico-epidemiological profile of road traffic accident patients presenting to a tertiary care trauma centre in Bhubaneswar. *J Family Med Prim Care* 2020;9:3682-7.