

CARRIAGE OF THE VIRUS OF POLIOMYELITIS, WITH  
SUBSEQUENT DEVELOPMENT OF THE INFECTION.

BY EDWARD TAYLOR, M.D., AND HAROLD L. AMOSS, M.D.

(From the Research Laboratory\* of the Vermont State Board of Health, Burlington.)

PLATES 55 AND 56.

(Received for publication, September 20, 1917.)

The solution of the problem of the mode of infection in poliomyelitis has been attempted in various ways, with results which have led to the conclusion that the microbic cause is conveyed from one individual to another by personal contact. This belief is based upon clinical observation and experiment. Wickman first brought clinical proof, since supported by many independent observations, of the correctness of this generalization; and Flexner and Lewis, and later Kling and Pettersson, provided the experimental demonstration of its adequacy.

However, a considerable number of physicians and others still refuse to accept this explanation. They hold that the mode of infection remains undiscovered, or they account for it through some variety of insect transmission, also undetected. In recognition of the skepticism still prevailing, we have been led to describe in detail the experimental demonstrations of the carriage by healthy persons of the virus of poliomyelitis, to which may now be added our own successful inoculations. Our results include the demonstration, recorded for the first time, that a proved carrier of the virus may come down with acute poliomyelitis. This observation should serve to strengthen the position of those who accept as established the personal communication of the microbic cause, or virus, of the disease.

\* Maintained by a special fund privately donated.

*Previous Reports.*

Wickman's<sup>1</sup> clinical studies may be said to have disseminated the view of the personal factor in the communication of the virus of poliomyelitis. He emphasized the occurrence and epidemiological importance of the non-paralytic or abortive cases, the first description of which is usually credited to him, and of healthy intermediaries, or bacillary carriers, who function as purveyors of the microbic agent. His study constituted a great step forward; but the first person to allude to non-paralytic cases of epidemic poliomyelitis is Caverly,<sup>2</sup> who records the occurrence of 6 cases among the total of 132 cases on which he based his report describing the Rutland epidemic of 1894.

Soon after Landsteiner and Popper's<sup>3</sup> experimental transmission of poliomyelitis, Flexner and Lewis<sup>4</sup> detected the virus in the nasopharyngeal mucous membrane of infected monkeys. This observation, soon confirmed by several independent bacteriologists, was followed by a study made by Kling, Pettersson, and Wernstedt<sup>5</sup> who injected into monkeys buccal washings from so called abortive cases and from healthy contacts. Their results were inconclusive, as the clinical condition produced was not typical of poliomyelitis, and the pathological changes described as present in the spinal cord were not characteristic of the disease. They explained the discrepancy by the supposition that the virus present in the abortive cases and healthy carriers was relatively avirulent. This view is repeated in their recent report<sup>6</sup> in which they describe an instance of healthy carriage of the highly active virus inducing paralysis and characteristic lesions. The first demonstration of the typical virus in the nasopharyngeal washings of healthy persons was, however, made by Flexner, Clark, and Fraser,<sup>7</sup> whose report follows in detail.

E. A., female, age 4 years and 4 months. The patient had been ill from Oct. 12 to 17, 1912. On the latter date she was admitted to the Hospital of The Rockefeller Institute for Medical Research, suffering from severe paralytic polio-

---

<sup>1</sup> Wickman, I., Beiträge zur Kenntnis der Heine-Medinschen Krankheit, Berlin, 1907.

<sup>2</sup> In view of the importance which the non-paralytic cases have assumed in the epidemiology of poliomyelitis it is pertinent to quote Caverly, who states that paralysis occurred in 119 cases, 7 cases died before paralysis was detected, "and the remaining 6 had no paralysis, but all had a group of symptoms very common in the initial stage in those which were paralyzed, such as headache, fever, convulsions, or nausea, one or all" (*J. Am. Med. Assn.*, 1896, xxvi, 1).

<sup>3</sup> Landsteiner, K., and Popper, E., *Z. Immunitätsforsch., Orig.*, 1909, ii, 377.

<sup>4</sup> Flexner, S., and Lewis, P. A., *J. Am. Med. Assn.*, 1910, liv, 1140.

<sup>5</sup> Kling, C., Pettersson, A., and Wernstedt, W., *Communications Inst. méd. État à Stockholm*, 1912, iii, 5.

<sup>6</sup> Kling, C., and Pettersson, A., *Deutsch. med. Woch.*, 1914, xl, 320.

<sup>7</sup> Flexner, S., Clark, P. F., and Fraser, F. R., *J. Am. Med. Assn.*, 1913, lx, 201.

myelitis. She subsequently improved and was discharged. Oct. 28. The mother and father of the child were subjected to a nasopharyngeal irrigation with normal saline solution; about 150 cc. of washings were obtained. The fluid was shaken and passed through a Berkefeld filter; of the filtrate, 1.5 cc. were injected the same day into the sheath of each sciatic nerve and 140 cc. into the peritoneal cavity of a *Macacus cynomolgus* (Monkey A). Recovery from the anesthesia was prompt and the animal remained well until Nov. 11, when it was noted to be excited and to drag the right leg; the left leg was weak. Nov. 12. Right leg flaccid. A lumbar puncture yielded 2.5 cc. of fluid containing excess of white corpuscles. Nov. 13. The condition was unchanged; the animal was etherized. The organs generally were normal in appearance; the spinal cord was edematous. Microscopic examination of sections of the spinal cord, medulla, and interstitial ganglia revealed the characteristic lesions of poliomyelitis. The blood vessels and ground substance showed infiltrations with mononuclear cells; the motor nerve cells were degenerated and invaded by phagocytes.

Dec. 3. An emulsion of the glycerolated spinal cord and medulla was injected into each sciatic nerve and the peritoneal cavity of a *Macacus cynomolgus* (Monkey B) and a *Macacus rhesus* (Monkey C). Dec. 9. The *rhesus* monkey was noted to be excited. Dec. 10. Lumbar puncture yielded 3 cc. of turbid fluid containing excess of white cells. By Dec. 13, the legs were partially paralyzed; the animal was etherized. Microscopic sections of the spinal cord, medulla, and intervertebral ganglia showed typical infiltrative and degenerative lesions of poliomyelitis. The *cynomolgus* monkey became excited on Dec. 10, and on the 19th paralysis of the legs appeared. By Dec. 21 the arms and back were weak, and the paralysis was extending. Dec. 23. The animal was etherized. The general viscera appeared normal, but the spinal cord was both edematous and congested. The microscopic sections of the cord, medulla, and intervertebral ganglia showed typical infiltrative and degenerative lesions attended by neurophagocytosis. Subsequently the glycerolated specimens of the nervous organs of Monkeys B and C were used for inoculating still other monkeys, in which typical paralysis was induced.

The conclusion drawn by the authors from this demonstrative experiment was to the effect that the parents of E. A., neither of whom showed any symptoms of illness and who evidently were not suffering from poliomyelitis, harbored the virus of the disease in the nasopharynx. Hence the existence of the healthy carrier was thus established experimentally.

The next demonstrative experiment was supplied by Kling and Pettersson<sup>6</sup> who, in referring to their earlier failure to produce clinically and anatomically typical poliomyelitis with nasopharyngeal washings, attribute the failure to the injection of insufficient amounts of virus into the monkeys. They repeated the tests, using washings concentrated *in vacuo* with the Faust-Heim apparatus.

They started out by determining the heat lability of the active virus, and ascertained that a liter of fluid carrying an effective dose could be evaporated at

temperatures ranging from 35 to 38°C. to 200 cc. without losing its potency. They now obtained nasopharyngeal washings in amounts of 1 to 2 liters from healthy persons in contact with cases of acute poliomyelitis. In one instance in which the washings were taken from the healthy members of a family in which one member had recently died of acute poliomyelitis, the inoculation resulted successfully.

The patient was a male, age 41 years. The illness began on Sept. 10, the legs becoming paralyzed 2 days later. Death took place on the 4th day of illness from respiratory failure. The surviving members of the family consisted of the wife and three children ranging from 10 to 14 years, all remaining well. One day after the death of the father in a hospital, nasal washings were taken in distilled water from the surviving members of the family. The combined washings, amounting to 1 liter, were evaporated *in vacuo* to 75 cc., sodium chloride was added, and the mixture was filtered first through paper and then through a Berkefeld candle.

Sept. 20. 0.5 cc. of the filtrate was injected intracerebrally and 20 cc. were introduced into the peritoneal cavity of a *Macacus sinicus*. Oct. 2. The right leg and on the next day both legs and back were paralyzed, and death resulted. The microscopic sections of the spinal cord showed moderate perivascular and diffuse infiltration of the nervous tissue with mononuclear cells and neurophagocytosis. Oct. 3. A second *Macacus sinicus* was inoculated intracerebrally and intraperitoneally with an emulsion of the spinal cord of the first animal. On Oct. 13 the right leg and on the next day the left leg were paralyzed. Oct. 15. The animal was killed. Sections of the spinal cord showed typical infiltrative and degenerative lesions of poliomyelitis.

There can be no doubt, therefore, that in this family one or more healthy carriers of the active virus of poliomyelitis existed. That the result was not due entirely to the employment of concentrated washings is indicated by the failure to detect the virus in the washings obtained from the healthy associates of two other cases of acute poliomyelitis.

#### OBSERVATIONS.

In the two successful instances just reviewed, mixed washings were employed for inoculation. It is, therefore, impossible to state whether one or more of the healthy contacts of the cases of poliomyelitis were carriers. In the instance which we shall report the individuals were irrigated separately. The final result proved that more than one virus carrier was present, and it was demonstrated that such a healthy carrier may develop poliomyelitis. We may

therefore regard the chain of the mode of infection as now having been completed for the first time. The separate links may be defined as follows:

Case of acute poliomyelitis—→ contact carrier—→ second case.

A still further analysis would determine that through the contact carrier other carriers occur, among which a certain number of additional cases arise.

Poliomyelitis occurred in epidemic form in Washington County, Vermont, in the summer of 1917. From June 1 until September 1, 79 cases were recognized among the population of 45,000.

Carey P., male, age 16 years. The patient lived in the village of Waitsfield, 18 miles from Montpelier, where cases of poliomyelitis existed. No case of the disease had been discovered in Waitsfield. On June 2, 1917, he attended a ball game at Northfield where there were no cases, and returning home stopped in Montpelier for supper. Probably in the assembly at Northfield persons from the infected district were present. Until June 12 there were no symptoms of illness; on that day there was complaint of headache and pain in the back and legs. The patient vomited once. June 13. First seen by a physician who observed that the patient had fever, and treated him for a gastrointestinal upset. June 16. Extensive paralysis involving both legs, right triceps, intercostals, pectorals, and diaphragm. Lumbar puncture yielded clear fluid under pressure, containing 400 white cells per cmm. and excess of globulin. Death occurred on this date.

The family consisted of the father, age 59 years, mother, age 42, sister, Hazel, age 13, two brothers, Everett, age 10, and Dwight, age 7. The two younger brothers slept in the same bed, and in the same room with the elder brother Carey.

June 16. Everett and Hazel were given nasopharyngeal irrigation with distilled water, 60 cc. being obtained from the former and 100 cc. from the latter. 10 per cent of ether was added to each, and the fluids were sent at once to the laboratory. One of us had previously determined that ether inhibits bacterial development without injuring the poliomyelitic virus. The washings were treated separately as follows: Glass beads were added and they were shaken mechanically for  $2\frac{1}{2}$  hours. They were then centrifuged at high speed for  $2\frac{1}{2}$  minutes, and the supernatant fluid was passed through a Berkefeld N candle and concentrated *in vacuo* by the method already described by us<sup>8</sup> at 35°C. to 2 cc. The entire concentrate was injected intra-

<sup>8</sup> Amoss, H. L., and Taylor, E., *J. Exp. Med.*, 1917, xxv, 507.

cerebrally into two *Macacus rhesus* monkeys (Monkey A (Everett) and Monkey B (Hazel)). The time elapsing between the collection and the injection of the washings was less than 6 hours.

We return briefly to the history of the two children. Everett had not been away from the village and was in usual health until June 13, the day after Carey fell ill. He also felt indisposed, showed a temperature of 102° F. and suffered from diarrhea, but did not vomit. However, he recovered quickly and subsequently on minute examination has shown no muscular weakness or abnormality of reflexes.

Hazel had not been away from Waitsfield. She had been entirely well at the time the washings were taken and remained well until June 21, at which time she complained of headache. She showed a temperature of 102° F. On June 22 her reflexes were exaggerated and stiffness of the back was present, but no muscular weakness was detected. Lumbar puncture was unsuccessful. The symptoms subsided gradually, but reexamination made on July 22 revealed partial paralysis of the left deltoid, right anterior tibial, and abdominal muscles. She had, therefore, suffered a mild attack of poliomyelitis.

*Monkey A.*—June 16, 1917. Inoculated. Remained well until June 29, when it was excitable, emitted staccato cries, and showed ruffled hair. The animal was noted to be clumsy in movement and unable to jump. June 30. Both legs were weak. July 4. The right leg was paralyzed and flaccid; the left leg and back were weak. The paralysis of the left leg and back, but not of the right leg, disappeared; the latter remained and contracture gradually set in. At the present time (Sept. 1) the contraction of the right leg is so marked that in moving about the animal does not touch the limb to the floor. On Aug. 8 blood was withdrawn for a neutralization test and at the same time an intracerebral inoculation was made with a large dose of virus proved active in another monkey; the result was negative. The animal, as is usually the case, having recovered from a recent infection, was resistant to reinoculation.

*Monkey B.*—June 17, 1917, 3 a.m. Injected intracerebrally with 1.5 cc. of the concentrated washings. Recovery from the anesthesia was immediate, and the first symptoms, consisting of excitability, ruffled hair, staccato cries, and partial paralysis of the right leg, were observed. June 26. The paralysis being stationary, the animal was etherized. The organs appeared normal to the naked eye. Microscopic sections revealed, however, marked typical lesions of poliomyelitis. They affected the spinal cord (Fig. 1), medulla (Fig. 2), and intervertebral ganglia (Figs. 3 and 4), and consisted of typical infiltration with mononuclear cells and nerve cell degeneration with phagocytosis.

*Monkey C.*—June 26, 1917. Injected intracerebrally under ether anesthesia with 2.5 cc. of a 20 per cent emulsion of spinal cord and medulla of Monkey B. July 7. The first symptoms were noted, consisting of ruffled hair and inclination of head to the left. July 8. The animal was ataxic and protected the right leg. July 9. Unable to jump; legs and back weak. July 10. Paralysis progressing. July 15. Etherized. The spinal cord showed typical focal lesions of poliomyelitis in which cicatrization was beginning.

These experiments leave no doubt that the washings, both from Everett and from Hazel, contained the virus of poliomyelitis. The instance of Hazel is of particular importance since in her case the virus was detected in washings taken 5 days before the first symptoms of what proved subsequently to be a mild attack of poliomyelitis set in. In other words, she was carrying the virus in her nasopharynx several days in advance of the appearance of any signs of illness. She constitutes, therefore, an example of a carrier of the virus developing poliomyelitis—the first one in which the demonstration has been proved experimentally.

The interpretation in the case of Everett is not so simple. When the virus was detected in his nasopharynx he had passed through a slight attack of illness, at about the same time with, and of about the same character as that of his brother Carey who died, but unattended by paralysis. The presumption is that Everett suffered from a non-paralytic or abortive attack of poliomyelitis. The detection of the virus in his case proves him not to have been a healthy, but a recovered carrier of the microbic cause of the disease.

The two children having been shown to be virus carriers, their nasopharyngeal secretions were tested by the method of Amoss and Taylor,<sup>8</sup> to determine whether they would neutralize an active poliomyelitic virus.

July 23, 1917. Washings with sterile water were taken from the children, and fractionally sterilized and mixed. To 15 cc. of the mixture were added 3.75 cc. of a Berkefeld filtrate of a 5 per cent stock glycerolated poliomyelitic spinal cord. After shaking, the combined fluids were permitted to remain at 37°C. for 24 hours. 1 cc. of the fluid was injected intracerebrally into a *Macacus rhesus*. No symptoms appeared until Aug. 4, when excitability, ataxia, paralysis of the right arm, and weakness of the back were noted. Aug. 8. Animal prostrate. Aug. 10. Died. The microscopic lesions were typical of poliomyelitis.

The mixed nasal washings failed, in this experiment, to neutralize the virus.

The youngest child, Dwight, age 7 years, was refractory and no washings were obtained from him on June 16 when they were taken from the other children. On June 18 he complained of being unwell. The symptoms were severe headache, stiffness of neck, exaggerated reflexes, but no diarrhea. Lumbar puncture yielded a fluid containing 500 white cells per cmm. and an excess of globulin. Immune poliomyelitic serum from recovered cases of the disease was administered intraspinaly, intravenously, and subcutaneously: 24 cc. were given intraspinaly, 30 cc. intravenously, and 39 cc. subcutaneously. Recovery was prompt, with a slight paralysis of the right anterior tibial muscle. Nasopharyngeal washings were, however, obtained on September 4, which after filtration and concentration were inoculated into a *Macacus rhesus* (Monkey D). The monkey remained well.

#### DISCUSSION.

This series of cases of poliomyelitis in one family, with the circumstances surrounding their origin, forms an instructive illustration of the mode of infection of the disease as brought out by the clinical and experimental study.

In the first place, one child only—the eldest boy, Carey—was exposed in a locality in which poliomyelitis was epidemic. The exposure took place on June 2. Immediately afterwards he returned home, to a village in which no previous case of the disease had occurred, and mingled freely with his younger brothers and sister. The contacts may be considered to have been intimate in that the three male children slept in the same room, two of them in the same bed.

The incubation period in Carey's case was 9 or 10 days, as he was taken ill on June 12. His brother Everett, 6 years younger, developed symptoms 1 day later and passed through what was probably a non-paralytic attack of poliomyelitis. He may be considered as having been infected by Carey some time during the incubation period, and to have exhibited a shorter incubation than his brother. The youngest brother, Dwight, was also freely exposed to both older brothers and exhibited symptoms passing into those indicative of



poliomyelitis 5 or 6 days later than his brothers. Finally, Hazel, the sister, in age between the two older brothers and possibly less freely exposed, developed symptoms and muscular weakness last of all and about 10 days after the eldest brother. The incubation periods of the cases, therefore, probably were 10 days or less, and the order of the attacks was such as to indicate successive infection and not a common one.

The second feature worthy of emphasis is the detection in this one family of two carriers of the poliomyelitic virus by the inoculation test. One (Everett) was discovered to be a carrier probably following a non-paralytic attack. In the instance of Hazel there is no doubt, first that she was discovered to be a healthy carrier, and second that she developed typical poliomyelitis during the period of carriage. Incidentally the nasopharyngeal secretions of Hazel and Everett failed to neutralize the poliomyelitic virus.

If the view that the mode of infection in epidemic poliomyelitis is by way of the nasopharyngeal mucous membrane and is brought about or greatly facilitated through the operation of healthy carriers of the virus, we may well consider whether in the final analysis every case of the disease does not develop from a carrier. At first this may seem startling, and yet it merely means that after contamination of the nasopharynx with the virus, an intervening period exists during which persistence, multiplication, and invasion of the virus take place. In not all contaminated persons does this process become complete; in some the virus may merely persist for a time, in others it may multiply in the nasopharynx (these constitute the healthy carriers of greater or less endurance), while in the exceptional few invasion also occurs. In the latter, symptoms arise, and such individuals compose the class of poliomyelitis cases.

#### SUMMARY.

A family group containing four children of whom all showed in varying degree symptoms of poliomyelitis is described. The source of infection and periods of incubation have been followed. Two of the children were proven by inoculation tests to carry the virus of poliomyelitis in the nasopharynx. Of these, one was detected to be

a carrier after recovering from a non-paralytic attack of the disease, and the other was discovered to be a carrier about 5 days before the initial symptoms, attended later by paralysis, appeared. The original case from which the three others took origin was fatal; the youngest child, after quite a severe onset, was treated with immune serum, and made a prompt and almost perfect recovery. The nasopharyngeal secretions of two of the cases, taken 1 month after the attack, proved incapable of neutralizing an active poliomyelitic virus.

The proposition is presented that every case of poliomyelitis develops from a carrier of the microbic cause, or virus, of poliomyelitis.

#### EXPLANATION OF PLATES.

##### PLATE 55.

FIG. 1. Spinal cord of Monkey B, showing perivascular infiltration and neurophagocytosis.  $\times 90$ .

FIG. 2. Medulla of Monkey B, showing diffuse mononuclear infiltration, nerve cell degeneration, and neurophagocytosis.  $\times 230$ .

##### PLATE 56.

FIG. 3. Intervertebral ganglion of Monkey B, showing infiltrative changes and nerve cell invasion.  $\times 120$ .

FIG. 4. Intervertebral ganglion of Monkey B, showing mononuclear infiltration, nerve cell degeneration, and neurophagocytosis.  $\times 240$ .

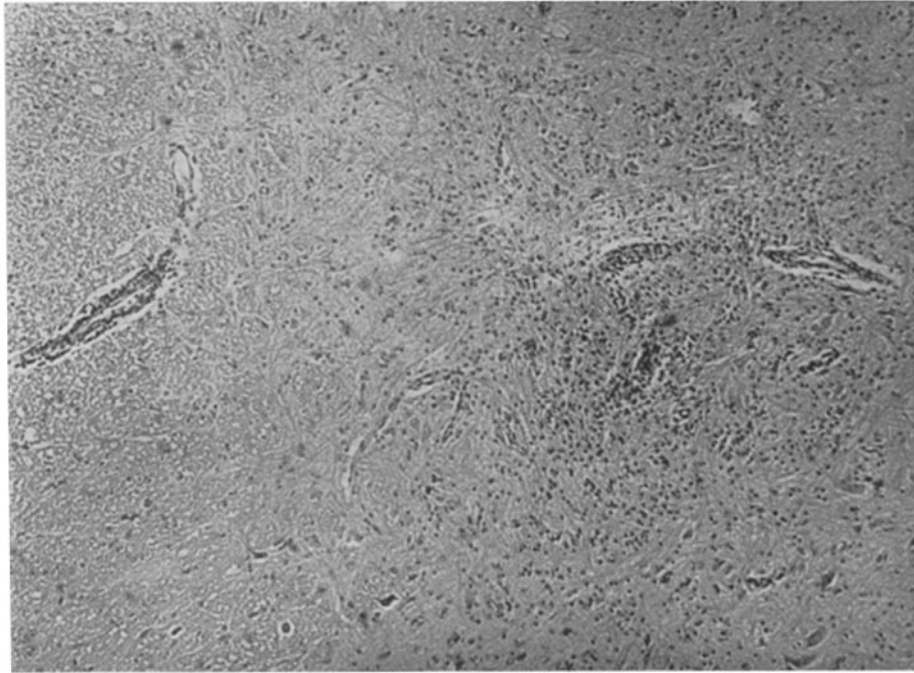


FIG. 1.

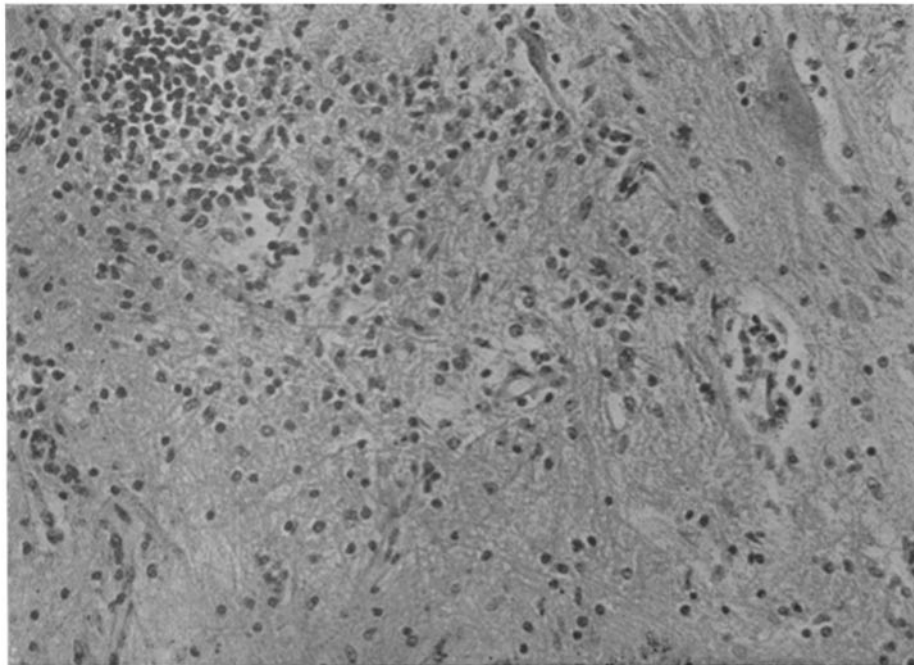


FIG. 2.

(Taylor and Amoss: Carriage of the virus of poliomyelitis.)

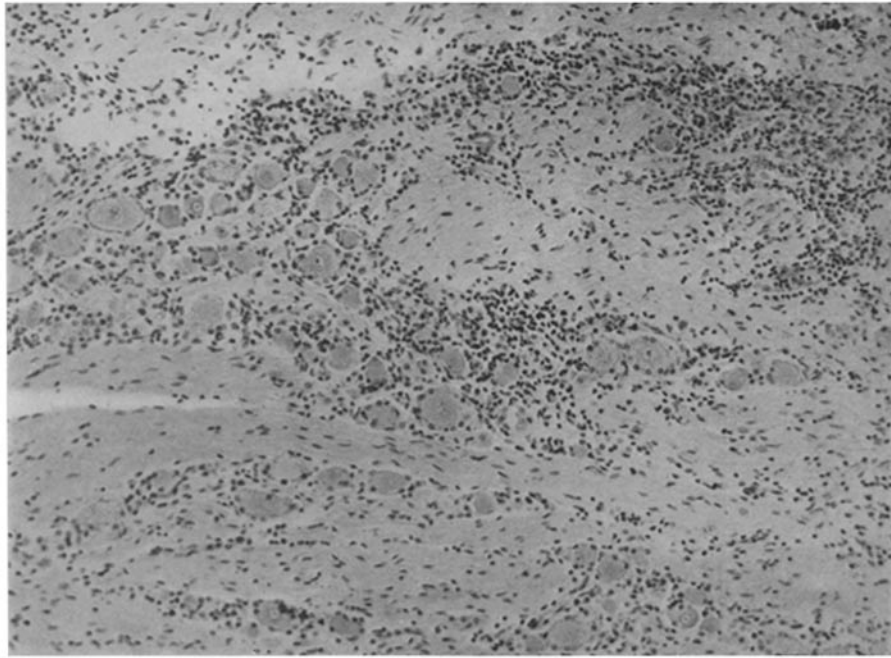


FIG. 3.

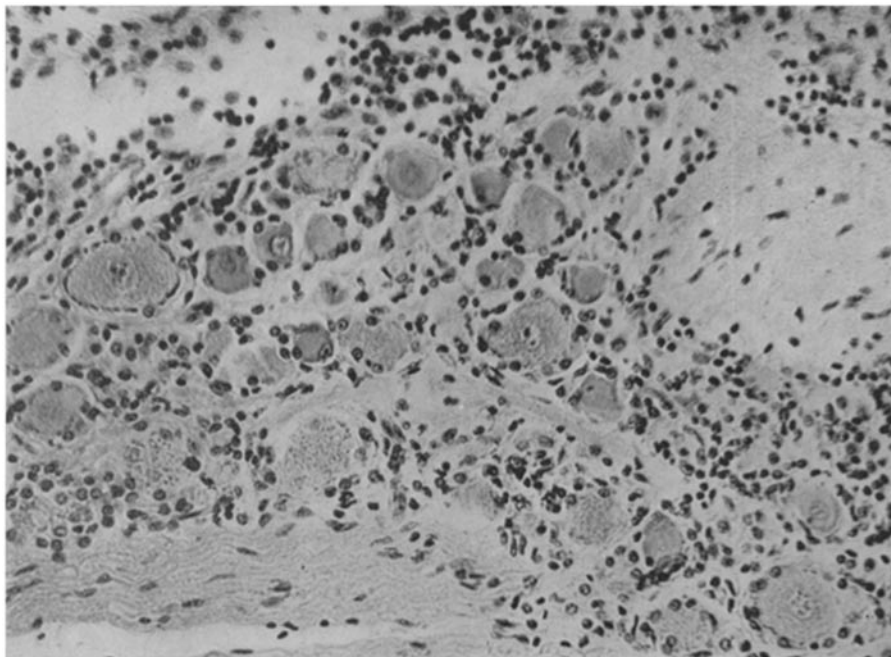


FIG. 4.

(Taylor and Amoss: Carriage of the virus of poliomyelitis.)