

Establishment of a trans-vaginal ultrasound-guided pinpoint transfer method

Sumihide Okamoto 

ART Okamoto Women's Clinic, Nagasaki City, Japan

Correspondence

Sumihide Okamoto, ART Okamoto Women's Clinic, Nagasaki City, Japan.
Email: okamotoclinic@okamotoclinic.gr.jp

Abstract

Purpose: Through the use of the trans-vaginal ultrasound-guided pinpoint transfer method, the aim was to ensure the safety of the embryo being transferred in cases of difficult cervixes. It also was aimed to be able to stop embryo transfers in difficult cases and to be able to restart the process under anesthesia or cryopreservation.

Methods: A new type of transfer catheter was developed. With this method, after reaching the internal os, the embryologist begins the loading of the embryo into the inner catheter. Then, the embryo transfer begins. Under the guidance of the trans-vaginal ultrasonography, the optimal position for implantation is selected.

Results: Out of 666 cases, 14 were difficult cervixes. This transfer method enabled 221 of the 666 patients to become pregnant successfully, which was a success rate of 33.2%.

Conclusion: From start to finish, this method takes only 2 min. It is simple, fast, and reliable, with a high satisfaction rate amongst patients.

KEYWORDS

assisted reproductive technology therapy, blastocyst, embryo, ultrasonography, uterine cervix

1 | INTRODUCTION

With falling birth rates and an increasingly aging population, efficient and highly advanced reproductive medicine must take into account the fact that there is limited time to use a small number of gametes. It is therefore imperative to select a controlled ovarian hyperstimulation technique that is suited to ovarian reserve, ensure the collection and successful incubation of ovarian follicles from the limited number that is available, and to rapidly and successfully transplant them. This can be termed "tailor-made clinical work." According to one

study, 30% of failed assisted reproductive technology transfers are due to inappropriate embryo transfer methods, with post-transfer embryo expulsion occurring in 45%-50% of cases, mainly due to the uterine contraction that is associated with the transfer procedure.¹ Cervical stenosis – or "difficult cervix" – also is thought to be involved in ~10% of cases. The following seven conditions to optimize the embryo transfer technique are: (1) proper evaluation of the uterine cavity, (2) avoiding the initiation of any uterine contractility, (3) the use of soft catheters, (4) avoiding touching the uterine fundus, (5) gentle manipulation, (6) getting rid of cervical mucus, and (7) proper delivery of the embryo inside the uterine cavity.² After many years of being involved in in vitro fertilization, surgeons have observed that although there are many cases in which embryo transfer can be performed easily, one also can suddenly encounter cases of "difficult cervix," in which it is extremely difficult to insert the catheter.³ In

The Japanese version of this article was published in Volume 30, pages 30-35, 2013, at <https://mol.medicalonline.jp/archive/search?jo=eh3ferti&ye=2013&vo=30&issue=1>, of the Japan Society of Fertilization and Implantation. The authors have obtained permission for secondary publication of the English version in another journal from the Editor of the Japan Society of Fertilization and Implantation. This article is based on the translation of the Japanese version, with some slight modification.

This is an open access article under the terms of the Creative Commons Attribution-NonCommercial-NoDerivs License, which permits use and distribution in any medium, provided the original work is properly cited, the use is non-commercial and no modifications or adaptations are made.

© 2018 The Authors. *Reproductive Medicine and Biology* published by John Wiley & Sons Australia, Ltd on behalf of Japan Society for Reproductive Medicine.

such instances, if the surgeon is manipulating the catheter containing the embryo, they might fall into a state of panic. Exposure of the embryo to the external atmosphere causes its pH to increase and its temperature to decrease, resulting in devastating damage to the embryo. At the current clinic, the trans-vaginal ultrasound-guided Pinpoint transfer method was developed to ensure that embryos can be transferred by using a standardized method without causing damage, even in cases in which insertion is difficult (Figure 1).⁴

2 | MATERIALS AND METHODS

2.1 | Development of a transfer catheter that is adapted to the Pinpoint method

The clinic used a double-tube transfer catheter system. The catheter's outer tube has a round tip to increase the level of echogenicity and to make it easier to pass through the cervix. The outer tube is fitted with a silicone flange stopper, which is fixated on the outside of the cervix, preventing over-insertion. The Pinpoint method uses the double catheter, with a firm outer catheter and a soft inner catheter, so that the appropriate hardness can be selected in accordance with the transfer method. In trans-vaginal ultrasound-guided transfer, the catheter is guided through the internal os to the intracervical transfer point and therefore only the internal tube that is loaded with the embryo is used.⁵

2.2 | Pinpoint transfer technique

Prior to the pinpoint transfer technique⁶⁻¹³ (Figure 2), the uterus is measured by using trans-vaginal ultrasound tomography and the entire uterus is imaged on the sagittal plane, with a line from the uterine fundus to the internal or external os as the major axis. Then, the length of the uterine cavity and the length of the cervical duct (from the internal os to the external os) are measured. The margin of the endometrium is traced along a curved line with calipers, the ultrasonic probe is removed without freezing the image, and its trajectory

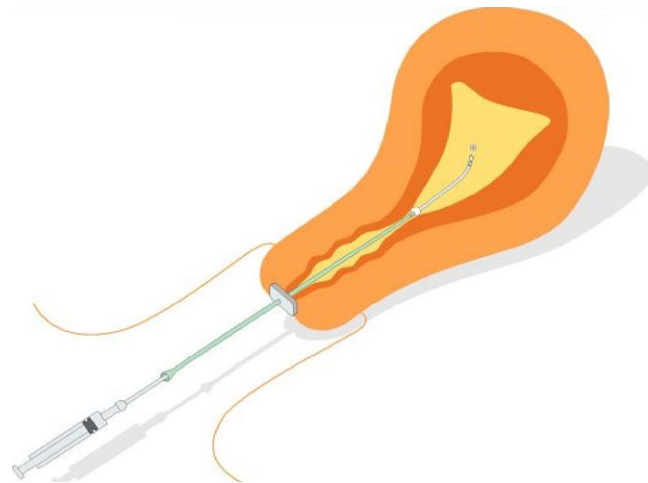


FIGURE 1 Pinpoint embryo transfer method procedure

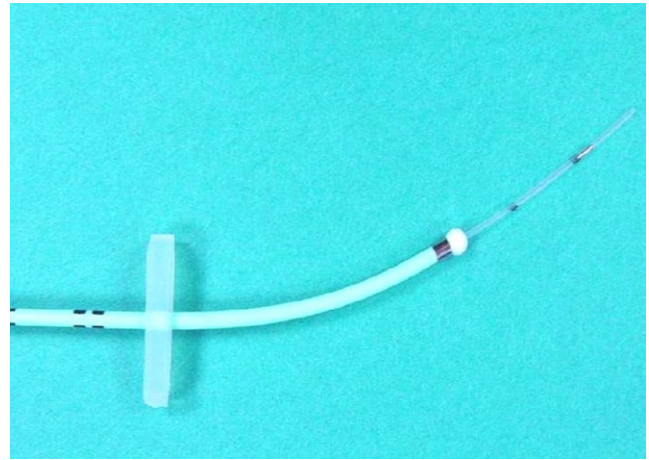


FIGURE 2 Double catheter that was developed for use in the Pinpoint method

is left on the display. Then, this is used as a reference to guide the inner catheter. After removing the cervical mucus, the outer catheter is inserted through the external os. The outer catheter is fitted with a round tip to improve echogenicity and to allow for smooth insertion into the cervix. The shaft of the catheter is fitted with a silicon stopper that is adjusted to the length of the cervical duct, as previously measured by using ultrasound tomography, and the stopper is fixated on the external os so that the tip of the outer catheter does not pass beyond the inner os. The outer catheter is inserted into the internal os before reinserting the ultrasound tomography probe. Once the outer catheter tip echo and the caliper trajectory are matched, preparations are complete. The adjacent incubation room is then contacted and the embryologist opens the incubator for the first time and begins loading the embryo. The time between loading and delivery to the surgeon in charge of the transfer should take 70 seconds and the time that it takes for the surgeon to transfer the embryo should be 50 seconds, meaning that the entire transfer process from the incubator into the uterus should take place within 2 minute. The inner catheter is inserted into the outer catheter and the surgeon confirms that the inner and outer catheter tips are aligned by using the double-line mark on the inner catheter. The surgeon then views the ultrasound tomography display and inserts the catheter 1-2 cm while monitoring the position of the tip on the screen. Once the tip reaches the center of the uterine cavity, the surgeon in charge of the transfer instructs the embryologist, who is on stand-by beside the surgeon, to press the syringe piston 10 γ to complete the transfer. The entire process, including the time required for explanation, should take no longer than 15 minute. Equipment proposal and improvement, curve rendering through the introduction of ultrasonic tomography caliper tracing, the reduction of the time that the embryo is exposed to the outer atmosphere, the ability to discontinue the process in mid-transfer due to improvements in the transfer procedure, the introduction of para-cervical block, and the selection of a transfer medium that includes hyaluronan, which prevents air bubble movement, all were achieved by using the iterative improvement concept.

2.3 | Procedure and background

The procedure and background includes the outer and inner catheter insertion.¹³

2.3.1 | Outer catheter insertion

Even when a woman is not pregnant, the size of the uterus undergoes small variations due to cyclical hormonal changes. Thus, measurements that are taken during a mock transfer that are performed prior to the *in vitro* fertilization (IVF) cycle are not useful because they might not ensure accurate insertion. Therefore, in this clinic's procedure, the ultrasonic measurement that is taken immediately prior to transfer is regarded as the most important data. The length of the cervical duct, as measured prior to the transfer, is used to calibrate the insertion length of the outer catheter. The silicon stopper usually is used to prevent the tip of the outer catheter from penetrating beyond the internal os. The ultrasonic image of the endometrial cavity immediately prior to the transfer is used to trace the measuring caliper. The probe is removed without pausing the image (by pushing the ultrasound machine's freeze key), so that an outline of the endometrial cavity remains on the screen. Then, the outer catheter is inserted without ultrasonic guidance, as is done in the clinical touch method. However, the outer catheter tip is fixated to the internal os. After this, the probe is reinserted and matched to the internal os echo and the surgeon places the probe in his or her left hand, so that now both the probe and the catheter are in the left hand. This outline is used as a reference to track the inner catheter tip. Thus, the outer catheter tube insertion is not the start of the embryo transfer; rather, it is like an initial stage prior to the embryo transfer. Incidentally, there is no need to insert the outer catheter tube with ultrasound guidance as this only complicates the procedure.

2.3.2 | Inner catheter insertion

Regarding the inner catheter insertion (Figure 3), the endometrial cavity, which is the transfer zone, is a fan-shaped region that extends from the internal os to uterus-tube angles on both sides. The inner catheter is the narrowest permissible size (3 Fr-size) and is made of soft material. Thus, it can be twisted easily about within the uterine cavity between the posterior and anterior walls of the uterus. As sagittal images are used, the tip of the inner catheter disappears from view on occasion. In some instances, the catheter shaft might be mistaken for the tip. This is why it is important that both the probe and the outer catheter are held in the surgeon's left hand. In the clinic's Pinpoint method, the most important point is the internal os. While maintaining careful attention on the ultrasound image so that the inner catheter tip can be confirmed to have emerged from the internal os, the surgeon uses his or her right hand to operate the inner catheter and the left hand to move the trans-vaginal ultrasound-guided probe left and right like a pendulum in order to keep the tip of the inner catheter in the center of view so that it can be manipulated within 1-2 cm from the inner os. This requires

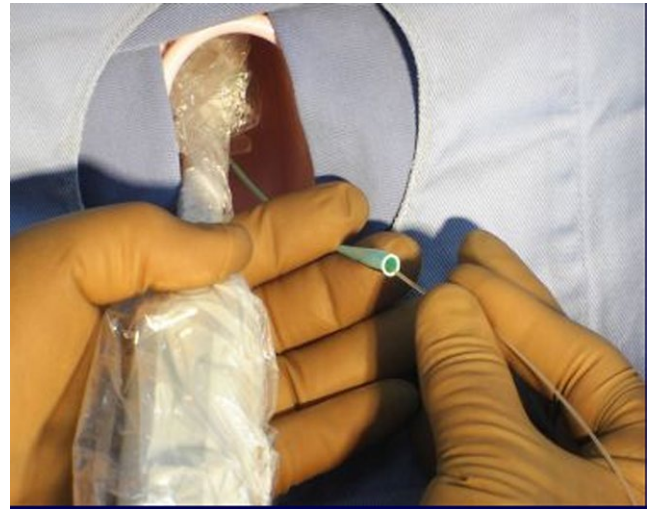

FIGURE 3 Photograph of the catheter that is loaded with the embryo being inserted. *Outer catheter insertion:* Outer catheter tip is fixed to the internal os. The probe then is reinserted and matched to the internal os echo. Next, the surgeon places the probe in his or her left hand, so that now both the probe and the catheter are in the left hand. Thus, the outer catheter tube insertion is performed not at the start of the embryo transfer, but rather as a prior stage to embryo transfer. *Inner catheter insertion:* Inner catheter is inserted into the outer catheter and the surgeon confirms that the inner and outer catheter tips are aligned by using the double-line mark on the inner catheter. The surgeon then shifts his or her attention to the ultrasound tomography display and inserts the catheter 1-2 cm while monitoring the position of the tip on the screen. Once the tip reaches the center of the uterine cavity, the surgeon in charge of the transfer instructs the embryologist, who is on stand-by beside the surgeon, to press the syringe piston 10 γ to complete the transfer

the surgeon's full concentration. Once the tip of the inner catheter reaches the center of the endometrium, a signal is given to the embryologist, who then presses the syringe piston and completes the embryo transfer process.

2.4 | Measures to deal with cases of difficult transfer, or so-called "difficult cervix"

Usually, in relation to difficult transfers³ (Figure 4), the round tip is effective in allowing the easy insertion of the outer catheter through the internal os without becoming lost in the entrance of the cervical duct, which has an inverted abatis shape. The silicon stopper, which fixates the position of the outer catheter, is positioned at the external os, based on previous ultrasound measurements, and the insertion of the outer catheter is completed at the same time. The stopper prevents the tip of the outer catheter from going beyond the internal os. If the outer catheter does not reach the silicon stopper while being inserted into the cervical duct, this indicates that this is a case of difficult cervix. The outer catheter then is temporarily removed, the catheter's obturator is removed, and an orthodontal platinum needle stylet is used. The outer catheter is reinforced and matched to the shape of the cervical duct. Once it is formed into

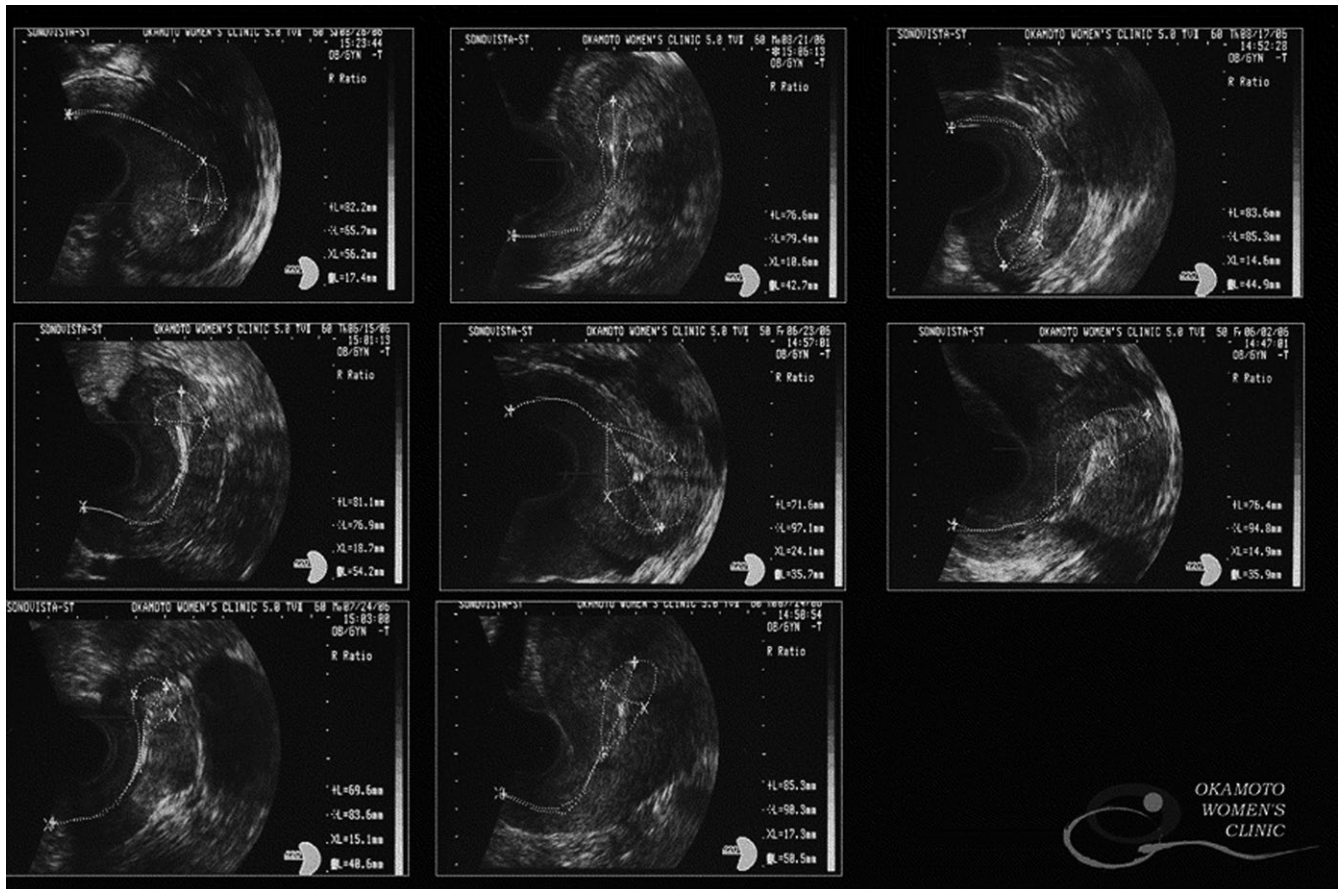


FIGURE 4 Differences in the individual uterine shapes and embryo transfer results using the trans-vaginal ultrasound guided pinpoint method. Uterine shapes can differ markedly. When an embryo transfer is performed by using trans-vaginal ultrasound guidance, it is absolutely imperative that the embryo transfer site is identified accurately

the shape of the cervical duct, insertion is possible in most cases. If insertion is still difficult, a para-cervical block (1% lidocaine local anesthetic) is administered so that the cervical duct can be widened to allow for insertion. If insertion is still impossible to perform, the outer tube insertion and embryo transfer is temporarily discontinued. The following day, the patient can undergo an embryo transfer again after fasting and under the same i.v. anesthesia that is used for egg retrieval. The major merit of the Pinpoint method is the fact that the embryo remains in the incubator, while the outer catheter is being inserted prior to the embryo transfer, making it possible to discontinue the process at any point. This is an important improvement over conventional methods. The transfer can be completed as a simple mock transfer without loading the embryo and therefore without any risk of damaging the embryo in cases in which transfer is made impossible by a difficult cervix. This is the first method in which this is possible. The embryo transfer surgeon can perform the procedure in complete confidence, which ensures the patient's trust, making this improvement revolutionary. If, in the case of blastocyst transfer on cycle day 5, the embryo transfer is postponed, the blastocysts are cryopreserved by using vitrification, dilatation of the cervical canal is performed, and the embryo transfer is reattempted in the next IVF cycle.

2.5 | Measures to deal with cervical deviation that is caused by uterine deformity or past surgery

In relation to cervical deviation,¹⁴ one of the characteristics of trans-vaginal ultrasound is the fact that it can be used to visualize the endometrium, even if the uterus is retroflexed. Naturally, it is also able to image cases of a deformed uterus, such as a double uterus, unicornuate or bicornuate uterus, and other types of deformities. It also can be used for cases in which the uterus is elongated and there is only a small amount of endometrium and in cases of heteromorphic lesions in the cervix or intra-epithelial carcinoma, in which conization of the cervix was unavoidable. The fact that the silicon stopper can be affixed to the tip of the outer catheter and fixed at the inner os makes this technique extremely effective even in such cases.

2.6 | Effects on the psychology of the patient and husband who wants to be present during the procedure

The adoption of this reliable transfer procedure improves the work process and allows the embryo transfer to be performed in a familiar environment. A counselor can be standing next to the transfer

patient and provide updates in real time regarding the insertion of the catheter and call attention to the ultrasound image of the moment of embryo transfer. This leads to less anxiety on the part of the patient herself. In addition, the fact that the husband can be present during the procedure in order to observe the embryo transfer has received praise. Some women feel happiness when they experience the embryo being reintroduced into their uterus. These women look back on the many days of treatment they underwent prior to this point and often shed tears of joy. It can be a very moving moment.

3 | RESULTS

At the current clinic, all the embryo transfers are performed by using the Pinpoint method. The outcomes are shown in Table 1. Between January 4 and December 27, 2011, a total of 666 cases (317 fresh embryo transfers, 349 cryogenically preserved embryo transfers), resulting in 221 pregnancies (pregnancy rate: 33.2%), was handled. This number represents the number of clinically confirmed pregnancies. Fourteen cases involved difficult transfers. During the year in question, local anesthetic was used in only three cases in which a pregnancy was subsequently confirmed, but there have been reports of pregnancy being confirmed when general anesthetic is used. The number of transferred embryos was in accordance with the views of the Japan Society of Obstetrics and Gynecology, Tokyo, Japan.¹⁴

4 | DISCUSSION

In order to achieve the clinic's goal, an original double-tube transfer catheter system was conceived.¹⁵ The characteristic shape and material of the catheter were selected in accordance with this concept. An important point during the embryo transfer is the internal os. The Pinpoint method was conceived so as to allow for passage into the cervical canal, which is encountered prior to the internal os, and then the insertion into the endometrium to be two separate procedures.

Therefore, the outer catheter does not pass beyond the internal os. The passage of the outer catheter beyond the internal os has been reported to cause uterine contractility.¹⁶ The insertion of the outer catheter into the cervical canal and fixing the tip at the internal os is significant because it allows the inner catheter to pass through the cervical canal barrier-free. Once the cervical canal is passed, the endometrium is accessed. As the endometrium is delicate and easily injured, a soft catheter is used. The endometrium is in an inverted triangle shape and there is only a narrow space between the anterior and posterior walls. Thus, it is easier to navigate a soft catheter through this space. As the sagittal plane is used, the catheter tip can disappear from sight. The catheter stem also can be transected in such a way that it can be mistaken for the tip. This could lead to excessive insertion past the 2 cm mark. Once the alignment of the tips of the inner and outer catheters is confirmed, the surgeon shifts his or her view to the ultrasound image monitor display and waits for the inner catheter tip to appear, while maintaining attention on the echo image of the round tip in the internal os. The surgeon grasps both the ultrasound probe and the catheter in the left hand and moves the probe in a pendulum-like manner. Using the right hand, the surgeon moves the inner catheter forward while focusing on the inner catheter tip on the monitor as it advances into the endometrium. Once it reaches the center of the endometrial cavity, the surgeon signals the embryologist, who then presses the syringe piston 10 γ .

Recently, this Pinpoint method has been regarded as a negative-control conventional method and it has been reported that, due to its complexity, the surgeon and the embryologist must perform the transfer together, with the embryologist advancing the catheter for the embryo transfer into the endometrial cavity at the instruction of the surgeon.¹⁷ In the Pinpoint method, the role of the embryologist is the same as for conventional methods as the embryologist is only required to load and deliver the embryo to the surgeon. The only difference is that, at the end of the procedure, the embryologist presses the syringe piston that is connected to the loaded catheter by 10 γ .¹⁵ This method is widely used worldwide. As the area in which to work is so narrow, it makes little sense for both the

TABLE 1 Clinical results of the assisted reproductive technology procedures that were performed at this study's clinic during 2011

		Fresh embryo transfer (mean age = 36.1)			Vitrified-warmed embryo transfer (36.3)			Total (36.3)		
Easy case		1 (35.1)	2 (38.6)		1 (36.2)	2 (37.8)				
		55/226	22/85		133/321	7/20				
		(24.8%)	(25.9%)		(41.4%)	(35%)				
		78/311 (25.1%)			140/341 (41.1%)			218/652 (33.4%)		
Difficult case	Local anesthesia	0/3	0/5	0/2	3/6	3/6	0/0			
	General anesthesia	0/1	0/0		0/2	0/0				
	total	0/6 (0%)			3/8 (37.5%)			3/14 (21.4%)		
Total		56/230 (24.3%)			22/87 (25.3%)			136/329 (41.3%)	7/20 (35.0%)	221/666 (33.2%)

Between January 4 and December 27, 2011, a total of 666 cases (317 fresh embryo transfers, 349 cryogenically preserved embryo transfers) was handled, resulting in 221 pregnancies (pregnancy rate: 33.2%). This number represents the number of clinically confirmed pregnancies. Fourteen cases involved difficult transfers. During the year in question, local anesthetic was used in only three cases in which pregnancy was subsequently confirmed, but there are reports of pregnancy being confirmed when general anesthetic is used. The number of transferred embryos was in accordance with the views of the Japan Society of Obstetrics and Gynecology, Tokyo, Japan.

embryologist and the surgeon¹⁵ to both be involved in the catheter insertion.¹⁷ For this reason, the Pinpoint method that is used at the clinic uses an improved surgical procedure. An assessment of the shape of the uterus is done prior to the procedure by using ultrasonography. The probe is removed without freezing the image, so that the trajectory of the caliper on the sonographic slice remains visible. Then, the outer catheter is fixed at the internal os without ultrasound guidance and the probe is reinserted. Therefore, the outer catheter does not require ultrasound guidance when this procedure is used. This is significant because in cases of so-called “difficult cervix,” ultrasound guidance does not lead to a solution to the problems with catheter insertion. Therefore, the author emphasizes the fact that this method uses a double-catheter system, which allows the Pinpoint method to satisfy all seven Mansour conditions.²

ACKNOWLEDGEMENTS

The author would like to express appreciation to all the persons who offered guidance and advice as the Pinpoint embryo transfer method was developed. This article is based on presentations given at the 50th Annual Meeting of Japan Society for Reproductive Medicine “Development of Embryo Transfer Methods”, Reproductive Biology Tokyo Symposium, and the 30th Annual Meeting of Japan Society of Fertilization and Implantation Symposium.

DISCLOSURES

Conflict of interest: The author declares no conflict of interest. *Human Rights Statement and Informed Consent:* All the procedures were followed in accordance with the ethical standards of the responsible committees on human experimentation (institutional and national) and with the Helsinki Declaration of 1964 and its later amendments. Informed consent was obtained from all the patients for being included in the study. *Animal studies:* This article does not contain any study with animal participants that have been performed by any of the authors.

ORCID

Sumihide Okamoto  <http://orcid.org/0000-0001-8904-3127>

REFERENCES

- Chakravarty BN. Foreword. In: Allahbadia GN, ed. *Embryo Transfer*. Tunbridge Wells, United Kingdom: Anshan, Ltd.; 2008:13-14.
- Mansour RT, Aboulghar MA. Optimizing the embryo transfer technique. *Hum Reprod*. 2002;17:1149.
- Ritzk B. The influence of a difficult embryo transfer on the results. In: Allahbadia GN, ed. *Embryo Transfer*. Tunbridge Wells, UK: Anshan, Ltd.; 2008:391-396.
- Okamoto S. Tailor-made trans-vaginal ultrasound guided pinpoint transfer method [Abstract]. *J Japan Soc Reprod Med*. 2006;51:193.
- Vereczkey A, Balyi B, Berkes E, Kovac G. The impact of the embryo transfer catheter on the pregnancy rate. In: Allahbadia GN, ed. *Embryo Transfer*. Tunbridge Wells, UK: Anshan, Ltd.; 2008:22-39.
- Woolcott R, Stanger J. Potentially important variables identified by transvaginal ultrasound-guided embryo transfer. *Hum Reprod*. 1997;12:963-966.
- Kojima K, Nomiyama M, Kumamoto T, Matsumoto Y, Iwasaka Y. Transvaginal ultrasound-guided embryo transfer improves pregnancy and implantation rates after IVF. *Hum Reprod*. 2001;16:2578.
- Kovacs GT. What factors are important for successful embryo transfer after in-vitro fertilization? *Hum Reprod*. 1999;14:590.
- Anderson R, Nugent N, Gregg A, Nunn S, Behr B. Transvaginal ultrasound-guided embryo transfer improves outcome in patients with previous failed in vitro fertilization cycles. *Fertil Steril*. 2002;77:769.
- Okamoto S. Device for embryo transfer method [Abstract]. In: The 9th Reproductive Biology Tokyo Symposium. 2010.
- Okamoto S. Establishment of a trans-vaginal ultrasound guided pinpoint transfer method [Abstract]. In: The 30th Annual Meeting of Japan Society of Fertilization and Implantation. 2012.
- Woolcott R, Stanger J. Ultrasound tracking of the movement of embryo-associated air bubbles on standing after transfer. *Hum Reprod*. 1998;13:2107-2109.
- Drakeley AJ, Jorgensen A, Sklavounos J, et al. A randomized controlled clinical trial of 2295 ultrasound-guided embryo transfers. *Hum Reprod*. 2008;23:1101-1106.
- Abou-Setta AM, Mansour RT, Al-Inany HG, Aboulghar MM, Aboulghar MA, Serour GI. Among women undergoing embryo transfer, is the probability of pregnancy and live birth improved with ultrasound guidance over clinical touch alone? A systemic review and meta-analysis of prospective randomized trials. *Fertil Steril*. 2007;88:333-341.
- Eskandar M, Abou-Setta AM, Almushait MA, El-Amin M, Mohamad SE. Ultrasound guidance during embryo transfer: a prospective, single-operator randomized, controlled trial. *Fertil Steril*. 2008;90:1187-1190.
- Bodri D, Colodrón M, García D, Obradors A, Vernaev V, Coll O. Transvaginal versus transabdominal ultrasound guidance for embryo transfer in donor oocyte recipients: a randomized clinical trial. *Fertil Steril*. 2011;95:2263-2268.
- Furui K. Transvaginal ultrasound guided simple embryo transfer method. *J Japan Soc Assisted Reprod*. 2012;15:52-53.

How to cite this article: Okamoto S. Establishment of a trans-vaginal ultrasound-guided pinpoint transfer method. *Reprod Med Biol*. 2018;17:182-187. <https://doi.org/10.1002/rmb2.12091>