

Extracorporeal Membrane Oxygenation in a 1,360-g Premature Neonate after Repairing Total Anomalous Pulmonary Venous Return

Youn Ju Rhee, M.D., Sung Joon Han, M.D., Yoo Young Chong, M.D.,
Min-Woong Kang, M.D., Ph.D., Shin Kwang Kang, M.D., Ph.D., Jae-Hyeon Yu, M.D., Ph.D.

*Department of Thoracic and Cardiovascular Surgery, Chungnam National University Hospital,
Chungnam National University School of Medicine*

With advancements in complex repairs in neonates with complicated congenital heart diseases, extracorporeal membrane oxygenation (ECMO) has been increasingly used as cardiac support. ECMO has also been increasingly used for low birth weight (LBW) or very low birth weight (VLBW) neonates. However, since prematurity and LBW are risk factors for ECMO, the appropriate indications for neonates with LBW, especially VLBW, are under dispute. We report a case of ECMO performed in a 1,360-g premature infant with VLBW due to cardiopulmonary bypass weaning failure after repairing infracardiac total anomalous pulmonary venous return.

Key words: 1. Very low birth weight
2. Extracorporeal membrane oxygenation
3. Neonate

Case report

A premature male infant was born at 30 weeks of gestation. The patient had a birth weight of 1,360 g, which was categorized as very low birth weight (VLBW <1,500 g). After birth, the patient presented with cyanosis and severe chest wall retraction. The patient was referred to Chungnam National University Hospital and transferred to the neonatal intensive care unit at arrival. The patient's vital signs included a systolic blood pressure of 40 mmHg, a heart rate of 150 beats/min, and an oxygen saturation level of 80%–90% with bag valve mask to maintain oxygen saturation under 100% O₂. An initial arterial blood

gas analysis showed a pH of 7.21, pO₂ of 37 mmHg, and pCO₂ of 59 mmHg. Chest radiography demonstrated diffuse pulmonary infiltration of the bilateral lung fields without cardiomegaly (Fig. 1). Initial echocardiography showed that the size of the atrial septal defect was 2.89 mm and that patent ductus arteriosus was present. The infant was diagnosed with respiratory distress syndrome (RDS), was intubated with mechanical ventilation, and surfactant was administered for the RDS. After showing improvement, the endotracheal tube was removed from the patient 7 days after hospital admission. On the 15th day after admission, the patient's oxygen saturation level started to decrease gradually while pulmonary infiltration

[†]This article was presented at the 45th Annual Meeting of the Korean Society for Thoracic and Cardiovascular Surgery as poster presentation.

Received: October 6, 2015, Revised: November 1, 2015, Accepted: November 3, 2015, Published online: October 5, 2016

Corresponding author: Jae-Hyeon Yu, Department of Thoracic and Cardiovascular Surgery, Chungnam National University Hospital, Chungnam National University School of Medicine, 282 Munhwa-ro, Jung-gu, Daejeon 35015, Korea (Tel) 82-42-280-7377 (Fax) 82-42-280-7373 (E-mail) jahyu@cnu.ac.kr

© The Korean Society for Thoracic and Cardiovascular Surgery. 2016. All right reserved.

© This is an open access article distributed under the terms of the Creative Commons Attribution Non-Commercial License (<http://creativecommons.org/licenses/by-nc/4.0>) which permits unrestricted non-commercial use, distribution, and reproduction in any medium, provided the original work is properly cited.

increased on chest radiography. Follow-up echocardiography showed that all pulmonary veins drained to the intrahepatic vein and the right atrium, indicating an infracardiac type of total anomalous pulmonary venous return (TAPVR). The maximum velocity of tricuspid regurgitation was 4.7 m/sec, suggesting obstruction of the pulmonary vein. Therefore, emergency repair of TAPVR was performed 21 days after birth. The patient's weight was 1,360 g at the time of surgery, with no weight gain since birth.

Cardiopulmonary bypass (CPB) was implemented with ascending aorta cannulation (8-Fr Medtronic

DLP cannula; Medtronic Inc., Minneapolis, MN, USA) and bicaval venous cannulation (10-Fr right-angled cannulae; Edwards Lifesciences, Irvine, CA, USA). Re-routing of the TAPVR to the left atrium and ligation of the vertical vein to the patent ductus arteriosus were performed under moderate hypothermia. It was difficult to wean the patient from CPB. Therefore, we placed extracorporeal membranous oxygenation (ECMO) using an 8-Fr aortic cannula and a 12-Fr Medtronic DLP venous cannula on the right atrial appendage with a membrane oxygenator (Dideco 901; Dideco, Mirandola, Italy) and centrifugal pump (Stockert Instrumente, Munich, Germany) (Fig. 2A). On the day of the operation, ECMO flow was maintained at 120–150 mL/min with a fraction of inspired oxygen of 0.3 supported by inotropics. Minimal systemic heparinization (initiation dose of 30 IU/hr) was used with activated clotting times (ACTs) of 180–200 seconds.

We attempted to wean the infant off ECMO after 44 hours of good left ventricular function on follow-up echocardiography. However, it was impossible to wean the patient from ECMO due to his decreased mean blood pressure. Therefore, we restarted ECMO with a 5-Fr central venous catheter, as the previous 8-Fr DLP cannula was considered too large when compared to the ascending aortic size (Fig. 2B). However, the 5-Fr central venous catheter failed to maintain the flow of ECMO. The patient's cardiac function slowly recovered, and the arterial and venous cannulae were removed. The patient recovered and ultimately exhibited good cardiac function. A thrombus in the lumen of the central venous catheter

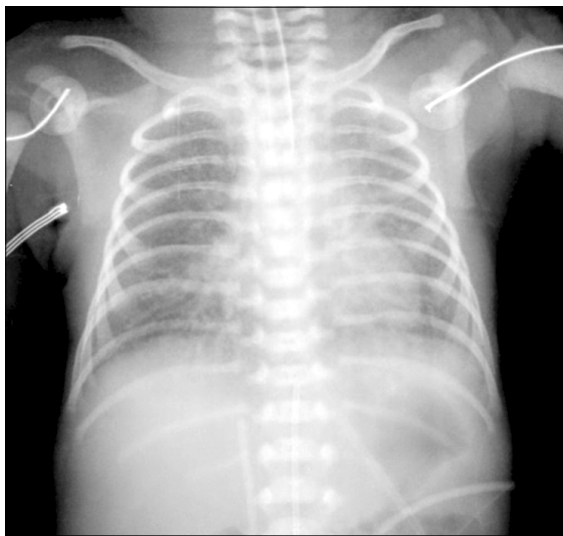


Fig. 1. Chest radiograph on admission showing diffuse pulmonary infiltration of the bilateral lung fields.

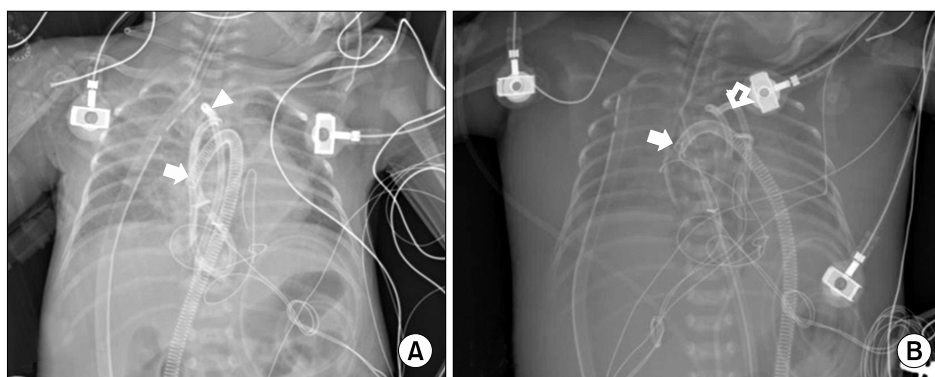


Fig. 2. (A) Chest radiograph immediately after the operation. Extracorporeal membranous oxygenation was instituted with ascending aorta cannulation using an 8-Fr Medtronic DLP arterial cannula (indicated by the arrow; Medtronic Inc., Minneapolis, MN, USA) and right atrial cannulation using a 12-Fr Medtronic DLP venous cannula (indicated by the arrow head). (B) The 8-Fr Medtronic DLP arterial cannula was replaced with a 5-Fr central venous catheter (outline arrow). The right atrial venous cannula (arrow) was maintained.

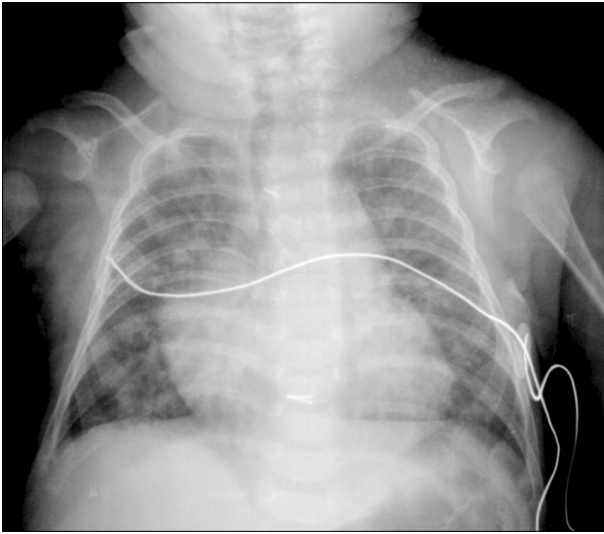


Fig. 3. Chest radiograph of the patient at the time of discharge with a weight of 2,600 grams.

ter had obstructed ECMO.

The infant underwent approximation of the sternum 7 days postoperatively, and was extubated on day 16 postoperatively. Follow-up echocardiography showed normal left ventricular function without pulmonary venous obstruction on day 18 postoperatively. Brain sonography performed during the ECMO procedure did not display any sign of intracranial hemorrhage (ICH). After recovery from the operation, brain sonography revealed periventricular leukomalacia (PVL). We deduced that the periventricular hyperechogenicity revealed by the brain sonography on the 13th day after birth might have developed during the course of recovery. The patient was discharged on the 64th day postoperatively with a weight of 2,600 g (Fig. 3). During follow-up, a pulmonary venous obstruction developed. Therefore, we performed another operation when the patient was 14 months old (weight, 6.6 kg). Currently, the patient shows no sign of pulmonary venous obstruction and is undergoing rehabilitation therapy.

Discussion

As complex repairs for neonates with complicated manifestations of congenital heart disease (CHD) become more common, ECMO support is more often used [1]. According to the Extracorporeal Life Support Organization (ELSO) international registry, more than

5,000 cases of neonatal cardiac ECMO have been reported. The application of neonatal cardiac ECMO has steadily risen in frequency to encompass 30% of all non-early cardiopulmonary resuscitation procedures in neonates [2]. Approximately 8% to 18% of patients with CHD have low birth weight (LBW <2,500 g) or VLBW (<1,500 g) due to prematurity or preterm birth. CHD is a major cause of death for LBW and VLBW neonates, with prematurity accounting for a quarter of all neonate deaths [3]. Early corrective repair is often the preferred strategy for CHD, requiring surgery in LBW or VLBW infants rather than delay or palliative operations [3-5]. The increasing number of in high-risk infant operations implies a potential increase in the frequency of cardiac ECMO in premature LBW or VLBW [1].

The primary indications of neonatal cardiac ECMO include preoperative stabilization of uncorrected CHD, postcardiotomy low cardiac output state, and failure to wean from CPB [1,2]. Other indications of ECMO are pulmonary hypertension, intractable arrhythmias, cardiac arrest, myocarditis, cardiomyopathy, bridge to transplantation, hemodynamic stabilization for procedures, and respiratory failure or sepsis [2]. When infants demonstrate cardiopulmonary failure, especially when weaning from CPB, using ECMO in neonates requires recognition that it is a viable option and astute decision-making on the part of the pediatric cardiac surgeons. The use of ECMO in such a high-risk population is associated with significant morbidity and mortality, with an overall survival rate of approximately 40% [1,2,6]. It is difficult to come to a consensus regarding absolute contraindications for neonatal ECMO, although it is generally agreed that ECMO should not be used in patients with a lethal congenital malformation or severe irreversible brain injury. A number of previously recognized absolute contraindications are now reconsidered to be relative contraindications, such as gestational age <34 weeks, weight <2.5 kg, end-organ damage, and intracranial or solid-organ hemorrhage [2]. According to the ELSO registry data, the overall survival rate for premature infants under 37 weeks of gestational age is 31%, whereas it is 41% for term infants, and only 19% for those under 33 weeks of gestation [2]. The survival rate has a stepwise improvement according to increases in gestation age. However, central nervous system hemorrhages are inversely correlated with gesta-

tional age. Historically, weight <2 kg has been considered a relative contraindication [2]. Gelehrter et al. [7] reported a 10% survival rate in hypoplastic left heart syndrome neonates (weight <2.5 kg) who were treated using ECMO [7]. Bhat et al. [6] reported an overall 30-day survival rate of 33% in infants (weight <3 kg) who required postcardiotomy ECMO support after decannulation. Their report listed single-ventricle anatomy, low birth weight (especially <2.5 kg), longer duration of ECMO, and renal replacement therapy as some of the factors associated with poor outcomes [6].

Problems with cannulation are the most common mechanical complication related to cardiac ECMO in neonates. Clinical seizures, ICH, cannulae site bleeding, and surgical site bleeding are some of the other frequent complications [1,2]. Seizures, ICH, and cannula problems develop with high frequency in neonates, particularly in patients with LBW or VLBW. In general, the neonatal ECMO survival rate is excellent. However, it is important to note that serious intracranial injuries, which are a major complication of ECMO, are one of the main causes of fatalities in neonates who undergo ECMO [2].

In this case, a neonate patient with a weight of 1,360 g at 30 weeks of gestation was initially diagnosed with RDS. After treating the patient for 21 days, no improvement was noted. After reevaluation, the infant was diagnosed with obstructed infracardiac TAPVR. During an emergency operation under CPB, weaning from CPB failed. Therefore, ECMO was performed. We maintained low ACTs (180–200 seconds) while running ECMO given the patient's tendency to bleed. No complications related to bleeding were found. Selection of an appropriate cannula was a major problem for the patient. An aortic cannula measuring 8 Fr was too large for the aorta, which could lead to failure in weaning from CPB due to an increased afterload and subsequent obstruction of the outflow from the aorta, potentially compromising left ventricle function. After changing the aortic cannula to a 5-Fr central venous catheter, thrombosis occurred within the small lumen. Eventually, ECMO flow halted. An appropriately sized cannula is critical to maintain the flow in ECMO, but choosing an appropriate cannula for neonates with VLBW or ELOW is very difficult.

Although brain sonography performed during the ECMO run did not display signs of ICH, brain sonography after recovery from the operation revealed PVL. We deduced that the periventricular hyperechogenicity revealed by the brain sonography on the 13th day after birth might have developed during the course of recovery. Developmental delays may have developed due to PVL.

The patient survived. However, neurologic injury occurred after recovery from the operation. Based on this case, the decision to perform ECMO in patients with preoperative abnormal neurologic findings should be made prudently, with consideration of both the potential benefit in terms of survival and the possibility of neurologic injury.

Conflict of interest

No potential conflict of interest relevant to this article was reported.

References

1. Delmo Walter EM, Alexi-Meskishvili V, Huebler M, et al. *Extracorporeal membrane oxygenation for intraoperative cardiac support in children with congenital heart disease*. *Interact Cardiovasc Thorac Surg* 2010;10:753-8.
2. Mesher AL, McMullan DM. *Extracorporeal life support for the neonatal cardiac patient: outcomes and new directions*. *Semin Perinatol* 2014;38:97-103.
3. Reddy VM. *Low birth weight and very low birth weight neonates with congenital heart disease: timing of surgery, reasons for delaying or not delaying surgery*. *Semin Thorac Cardiovasc Surg Pediatr Card Surg Annu* 2013;16:13-20.
4. Wu ET, Huang SC, Wu MH, Wang JK, Chang CI. *Rerouting surgery of cardiac type total anomalous pulmonary venous return in a premature newborn with very low birth weight*. *J Formos Med Assoc* 2007;106(2 Suppl):S23-6.
5. Alsoufi B, Manlhiot C, Mahle WT, et al. *Low-weight infants are at increased mortality risk after palliative or corrective cardiac surgery*. *J Thorac Cardiovasc Surg* 2014;148:2508-14.e1.
6. Bhat P, Hirsch JC, Gelehrter S, et al. *Outcomes of infants weighing three kilograms or less requiring extracorporeal membrane oxygenation after cardiac surgery*. *Ann Thorac Surg* 2013;95:656-61.
7. Gelehrter S, Fifer CG, Armstrong A, Hirsch J, Gajarski R. *Outcomes of hypoplastic left heart syndrome in low-birth-weight patients*. *Pediatr Cardiol* 2011;32:1175-81.