

Twiddler's Syndrome

Jason A. Lesnick, MD
Benjamin L. Cooper, MD
Pratik B. Doshi, MD

McGovern Medical School at the University of Texas Health Science Center in Houston (UTHealth), Department of Emergency Medicine, Houston, Texas

Section Editor: Christopher Sampson, MD

Submission history: Submitted December 31, 2018; Revision received February 6, 2019; Accepted April 1, 2019

Electronically published May 20, 2019

Full text available through open access at http://escholarship.org/uc/uciem_cpccem

DOI: 10.5811/cpcem.2019.4.42123

Twiddler's syndrome refers to a rare condition in which a pacemaker or automatic implantable cardioverter-defibrillator (AICD) malfunctions due to coiling of the device in the skin pocket and resultant lead displacement. This image is the chest radiograph (CXR) of a 54-year-old male who presented to the emergency department with chest pain five months after his AICD was placed. The CXR shows AICD leads coiled around the device and the absence of leads in the ventricle consistent with Twiddler's syndrome. Patients with twiddler's syndrome should be admitted for operative intervention. [Clin Pract Cases Emerg Med. 2019;3(3):299-300.]

CASE PRESENTATION

A 54-year-old male with an automatic implantable cardioverter-defibrillator (AICD) placed five months prior to arrival presented with sharp, left-sided chest pain for one day. He stated that his "pacemaker is moving." On physical exam, the vital signs were within normal limits, the patient was in no distress, and the left superolateral chest wall was tender to palpation. The electrocardiogram showed a normal sinus rhythm without ischemic changes. Chest radiograph revealed AICD leads wrapped around the device and absence of leads in the ventricle (Image).

DIAGNOSIS

Twiddler's syndrome refers to pacemaker or AICD malfunction due to coiling of the device in the skin pocket and resultant lead displacement. It is rare, estimated to occur in 0.07 – 7% of implanted devices, and almost always occurs within the first year of implantation.¹ It requires urgent attention as patients with malfunctioning AICDs are at risk for ventricular dysrhythmias and death,^{2,3} and patients who rely on pacemakers lose extrinsic pacemaking activity. Patients with twiddler's syndrome should be admitted to a telemetry bed for operative repair. Twiddler's syndrome is classically associated with the patient twiddling or twisting his pacemaker causing lead dislodgement. While our patient denied intentionally manipulating the device, he did mention that he felt like his pacemaker moved when he changed positions.

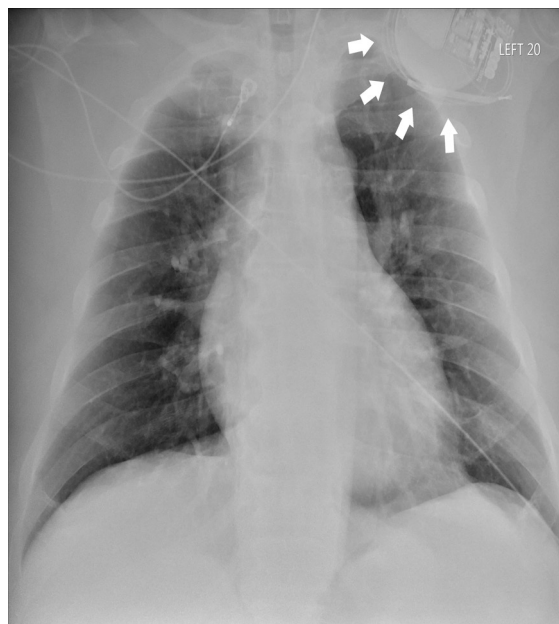


Image. Anteroposterior chest radiograph revealing automatic implantable cardioverter-defibrillator leads wrapped around the device (white arrows) and absence of leads in the ventricle.

As implantable devices increase in popularity, emergency physicians should be aware of this potentially life-threatening condition.

Documented patient informed consent and/or Institutional Review Board approval has been obtained and filed for publication of this case report.

Address for Correspondence: Benjamin L. Cooper, MD, McGovern Medical School at the University of Texas Health Science Center in Houston (UTHealth), Department of Emergency Medicine, 6431 Fannin Street, JLL 434, Houston, Texas 77030. Email: benjamin.l.cooper@uth.tmc.edu

Conflicts of Interest: By the CPC-EM article submission agreement, all authors are required to disclose all affiliations, funding sources and financial or management relationships that could be perceived as potential sources of bias. The authors disclosed none.

Copyright: © 2019 Lesnick et al. This is an open access article distributed in accordance with the terms of the Creative Commons Attribution (CC BY 4.0) License. See: <http://creativecommons.org/licenses/by/4.0/>

CPC-EM Capsule

What do we already know about this clinical entity?

Twiddler's syndrome is a rare condition in which a pacemaker malfunctions due to coiling of the device in the skin pocket and resultant lead displacement.

What is the major impact of the image(s)?

The chest radiograph shows AICD leads coiled around the device and the absence of leads in the ventricle consistent with twiddler's syndrome.

How might this improve emergency medicine practice?

Patients with twiddler's syndrome should be admitted for operative intervention.

REFERENCES

1. Salahuddin M, Cader FA, Nasrin S, et al. The pacemaker-twiddler's syndrome: an infrequent cause of pacemaker failure. *BMC Res Notes*. 2016;9:32.
2. Bardy GH, Lee KL, Mark DB, et al. Amiodarone or an implantable cardioverter-defibrillator for congestive heart failure. *N Engl J Med*. 2005;352(3):225-37.
3. Moss AJ, Hall WJ, Cannom DS, et al. Improved survival with an implanted defibrillator in patients with coronary disease at high risk for ventricular arrhythmia. *N Engl J Med*. 1996;335(26):1933-40.