

Capsulotomy and hydroprocedures for nucleus prolapse in manual small incision cataract surgery

Rengaraj Venkatesh, Kannusamy Veena, Ravilla D Ravindran

Manual small incision cataract surgery (MSICS) involves the manual removal of nucleus through a scleral tunnel. To achieve 100% success every time, one has to do a good capsulotomy and should master the technique to prolapse the nucleus into anterior chamber. During conversion from extracapsular cataract surgery to MSICS, one can perform a can-opener capsulotomy and prolapse the nucleus. However, it is safer and better to perform a capsulorrhexis and hydroprolapse the nucleus, as it makes the rest of the steps of MSICS comfortable. Use of trypan blue in white and brown cataracts makes the capsulorrhexis and prolapse simple and safe. Extra caution should be taken in cases with hypermature cataracts with weak zonules and subluxated cataracts.

Key words: Capsulorrhexis, can-opener capsulotomy, hydrodissection, hydroprolapse, manual small incision cataract surgery, trypan blue

Indian J Ophthalmol: 2009;57:15-8

Manual small incision cataract surgery (MSICS) is popular in developing countries, as it is inexpensive and allows high-volume cataract surgery without compromising quality of medical care.^[1-3] MSICS involves the manual removal of nucleus through a scleral tunnel.

To achieve this, one has to safely prolapse the nucleus from the capsular bag into the anterior chamber. As is the case with most surgical techniques, this looks simple when one observes an experienced surgeon performing the prolapse, but there are few hurdles for the beginners; this does not imply that it is a difficult step. It is just a matter of learning few techniques and certainly lot of practice.

The technique of nucleus prolapse into the anterior chamber depends on the type of capsulotomy. Either a can-opener capsulotomy or a capsulorrhexis can be performed to prolapse the nucleus. As there are many advantages of having an intraocular lens in the bag, it is preferable to prolapse the nucleus from the capsular bag through a capsulorrhexis with an intact rim.

Nucleus prolapse through can-opener capsulotomy

Following a can-opener capsulotomy, the nucleus can be prolapsed mechanically without any of the hydro procedures. The Sinsky hook or the lens dialer is used for performing this step. The hook is introduced through the scleral tunnel, and after gentle retraction of the pupillary border of iris, the hook is embedded in the substance of nucleus at the edge of the equator or slightly posterior to it at the 12 o'clock position. The nucleus is then pushed down towards 6 o'clock position till the superior equator of the nucleus clears the pupillary margin. At this point,

the nucleus is lifted up and rotated so that the superior pole of the nucleus gets prolapsed over the iris. Once one part of the nucleus is out, it is engaged with the Sinsky hook and rotated either in a clockwise or in an anticlockwise direction, until the whole nucleus is in the anterior chamber. Some surgeons find it easier to engage the nucleus at the 9 o'clock position to perform the step described above. In patients with white cataracts, the loose and fluffy superficial cortex is aspirated exposing the firm nucleus underneath before prolapsing it mechanically with the Sinsky hook.

This technique is ideal for surgeons changing from extracapsular cataract extraction (ECCE) with sutures to MSICS, who are yet to master capsulorrhexis. With can-opener capsulotomy, we lose the advantages of having intraocular lens in an intact bag.

Nucleus prolapse through capsulorrhexis

Prolapsing the nucleus into anterior chamber after capsulorrhexis using fluid (hydroprolapsing method) is a vital step. Normally hydrodissection or fluid injection underneath the capsule breaks the adhesions between cortex and capsule.^[4] Here, we use the same step to increase the hydrostatic pressure within the bag without putting any stress on the zonules to prolapse the nucleus.^[5]

First prerequisite is an adequate-sized capsulorrhexis. The margin of the rhexis is highly elastic and can allow safe expression of nucleus, which is larger than the opening.^[6-8] Hydroprolapsing method is safe when the diameter of the capsulorrhexis is 5 mm or more.^[9,10] Getting a right-sized capsulorrhexis is crucial, and its significance in MSICS cannot be overemphasized. With smaller or incomplete capsular rhexis, it is safer to make a few relaxing cuts and proceed as described under can-opener capsulotomy. If one is experienced and skill permits, one can go in for a double capsulorrhexis. The second prerequisite is to have a soft eye. Overfilling the anterior chamber with viscoelastic increases the resistance to nucleus prolapse. Partially emptying the anterior chamber of

Aravind Eye Hospital, Pondicherry, India

Correspondence to Dr. Rengaraj Venkatesh, Aravind Eye Hospital, Thavalakuppam, Pondicherry - 605 007, India.
E-mail: venkatesh@pondy.aravind.org

Manuscript received: 24.03.07; Revision accepted: 31.07.07

viscoelastic by pressing the floor of the incision with the shaft of the cannula will permit the nucleus to easily prolapse.

Partial hydroprolapse and rotation

Hydrodissection is usually done at 9 or 3 o'clock position, and the fluid injection is continued without decompressing the bag as in phacoemulsification, until one part of the equator of nucleus is forced out of the capsular rhexis. The purpose of continued injection of fluid is to increase the hydrostatic pressure within the bag to pop out the nucleus. This maneuver is safe, as the posterior capsule can withstand a pressure of 59 ± 10 mm Hg without rupturing.^[11] Once part of the equator is out, hydroprolapse is stopped [Fig. 1]. Viscoelastic is injected beneath the exposed equatorial region. Then a Sinskey hook is introduced through the scleral tunnel and the nucleus is rotated either clockwise or anticlockwise to bring the whole nucleus into the anterior chamber [Fig. 2].

Intracapsular flip

In this technique of intracapsular flip, hydrodelineation or fluid injection between the hard nucleus and epinucleus is performed prior to hydroprolapse. It helps in minimizing the size of the nucleus, which facilitates the easy maneuverability of the nucleus and also creates a soft epinuclear shell protecting the posterior capsule during the flipping procedure. Here

again, the hydroprocedures are continued until one part of the equator of the nucleus is forced out of the bag. Then, by using the same hydrodissection cannula, the part of the equator opposite to the prolapsed area is rotated towards the posterior capsule [Fig. 3]. The maneuver is continued through 180 degrees within the capsular bag (flipping of the nucleus), till it comes out of the bag, into the anterior chamber. The use of hydrodissection cannula to flip the nucleus within the capsular bag is safe as only the shaft of the cannula comes in contact with the epinucleus.

The manipulation of nucleus during intracapsular flip has minimal contact with iris tissue. Hence, if one masters this technique, it will be possible to prolapse the nucleus without altering the size of the pupil, and thereby the epinucleus and cortex can be quickly removed. In addition, the whole process of nucleus prolapse is achieved using a single instrument, resulting in lesser surgical time. This technique is not safe in eyes with very hard cataracts or poor zonular support.

Techniques for specific type of cataracts

Mature cortical cataracts

White cataracts can be managed by doing a capsulorrhexis after staining the capsule with 0.1 mL of 0.06% trypan blue dye. Nucleus can be levered out of the bag using a Sinskey

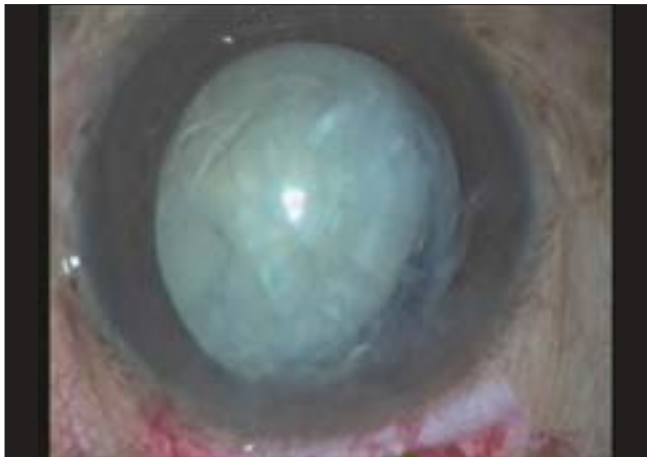


Figure 1: Partial prolapse of the nucleus over the iris

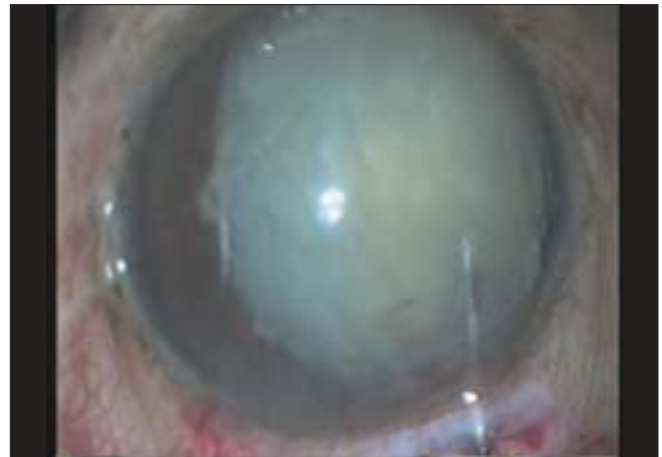

Figure 2: Completion of the prolapse using a Sinskey hook

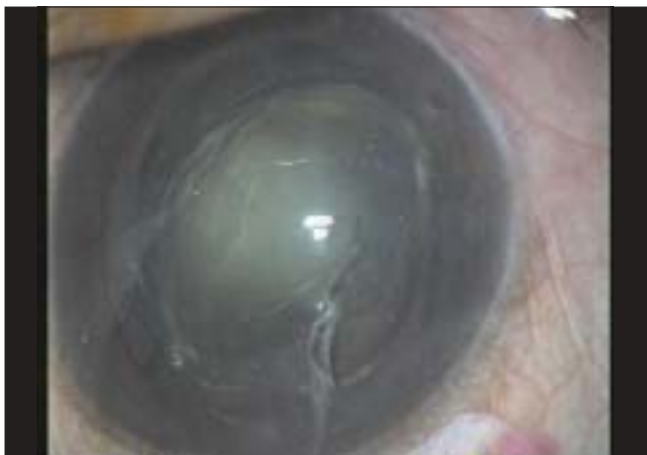

Figure 3: Intracapsular flip in progress

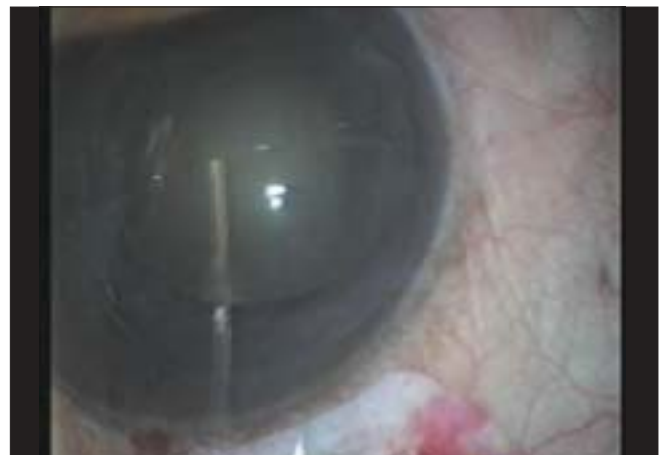

Figure 4: Nucleus lying in the anterior chamber

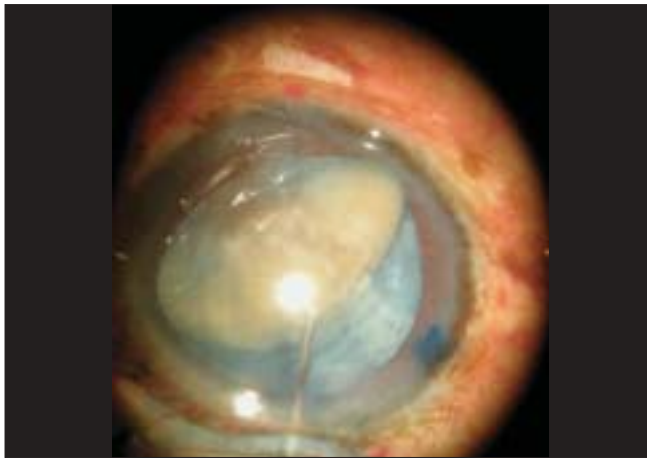

Figure 5: Trypan blue assisted nucleus prolapse in white cataract

hook even without hydroprocedures if the cortical attachment with the nucleus is loose. It will also be worthwhile to debulk the cortical matter using a simcoe cannula before prolapsing the nucleus. The capsular staining helps in performing the difficult step of nucleus prolapse through an intact capsulorrhexis safe and effortless, because the dye stained capsular rim is distinctly visible throughout the surgery. A Sinskey hook is used to retract the stained capsulorrhexis to engage the equator and lever out one pole of the nucleus outside the capsular bag and the rest of the nucleus is rotated into the anterior chamber [Fig. 4]. During this technique, any compromise to the capsular bag can be detected easily and relaxing incisions can be made at any point of the process, thereby saving the intracapsular removal of the nucleus.^[12]

Hyper mature cataracts and phacolytic glaucoma

In this technique, after staining the capsule, a small nick is made in the anterior capsule using a bent 26-G needle mounted on a syringe, and the liquid cortex is aspirated. The capsular bag is inflated with viscoelastic and the capsulorrhexis is completed using an Utrata capsulorrhexis forceps. A Sinskey hook is used to lever out one pole of the nucleus outside the capsular bag, and the rest of the nucleus is rotated out into the anterior chamber.^[13]

Hard brown/black cataracts

In these cases, the safest technique will be to perform a can-opener capsulotomy and prolapse the nucleus as described earlier. If the surgeon is keen to perform a capsulorrhexis, it will be safe to stain the capsule and perform a larger capsulorrhexis (6.0–6.5 mm) followed by a less-forceful hydrodissection. As the capsule is stained, it will be easy to retract the capsule and lever out a part of the nucleus with a Sinskey hook [Fig. 5]. The nucleus is then gently wheeled out, watching the movement of the capsular bag throughout the procedure. If the capsular bag seems to be compromised a few relaxing incisions in the capsule can avoid intracapsular extraction of the nucleus. Alternatively, a bimanual technique can be tried, which is described later.

Small pupil approach

One can resort to procedures such as stretch pupilloplasty with Kuglen's hooks or sphincterotomies. In certain high-risk

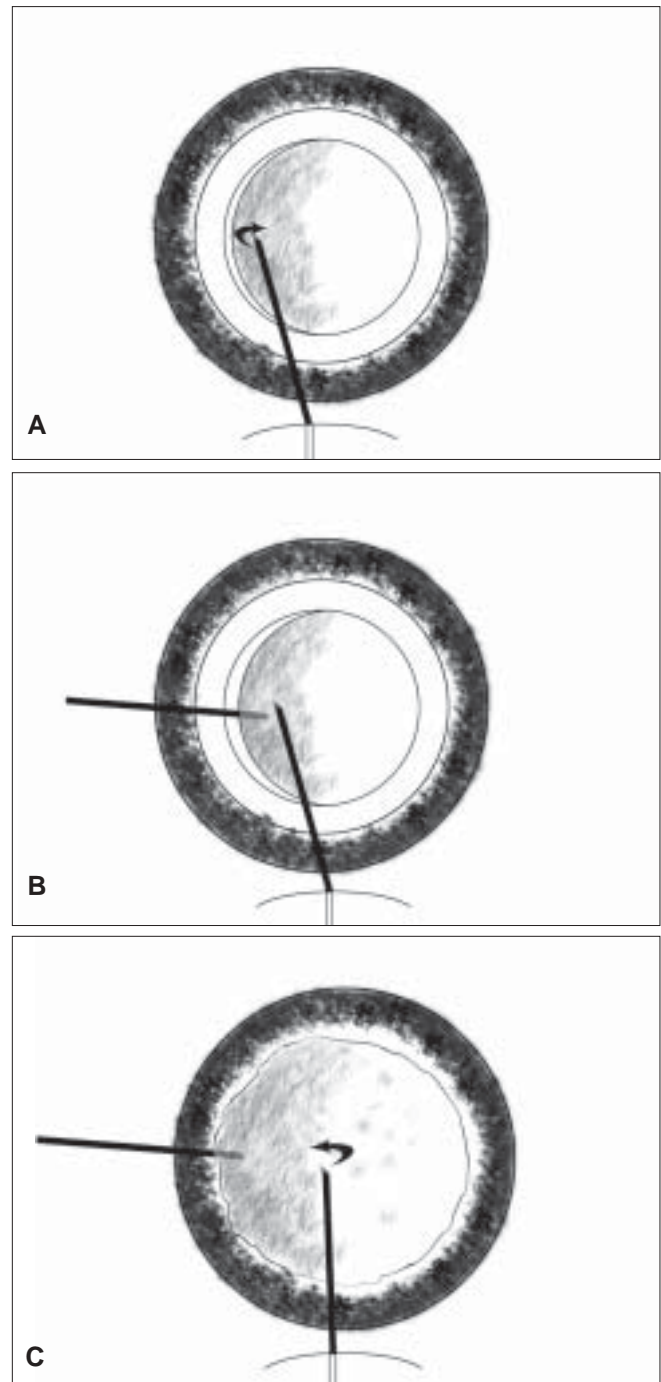


Figure 6: (A) The nucleus is retracted to one side (temporal in right eye or nasal in left eye) with a Sinskey hook from the scleral tunnel. (B) The spatula is introduced through the sideport incision and placed under the nucleus. (C) Using the spatula as a fulcrum the nucleus is rotated with the Sinskey hook out of the capsular bag

cases such as pseudoexfoliation with a small rigid pupil and an associated hard nucleus, it would be prudent to go in for a small sector iridectomy or a key hole iridectomy. In case it is a pliable small pupil and one's aesthetic sense does not allow mutilating the pupil, there is still an alternative technique, namely what we have termed the bimanual technique. This technique is useful if one has failed to prolapse the nucleus by

the mechanical method or in case of a small pupil with hard cataracts.

Bimanual technique

In cases with zonular compromise, a bimanual prolapse technique is employed: in this technique a cyclodialysis spatula and Sinskey hook is used for the prolapse. The nucleus is retracted to one side (temporal in right eye or nasal in left eye) with a Sinskey hook from the scleral tunnel [Fig. 6A]. Following this, a spatula is introduced through the side port incision and placed under the nucleus [Fig. 6B]. Using this as a fulcrum, the nucleus is rotated with the Sinskey hook out of the capsular bag [Fig 6C]. By this technique, the cyclodialysis spatula absorbs the rotational forces, minimizing stress on the zonules.^[13]

Subluxated cataracts

MSICS can be done in selected cases of subluxated cataracts wherein the pupil is well dilated and nucleus is not very hard. Here also, staining the capsule with trypan blue stain will facilitate in capsulorrhexis as well as in implanting the capsular tension ring (CTR) and in safely prolapsing the nucleus.

After assessing the extent of subluxation and density of nucleus, the capsule is stained, capsulorrhexis is followed by cortical cleaving hydrodissection, and CTR is manually inserted through the paracentesis. The nucleus is then hydrodelineated, and irrigation is continued until one pole of the nucleus prolapses out of the capsular bag. The rest of the nucleus is wheeled into the anterior chamber using a Sinskey hook.^[14]

Conclusion

To summarize, the technique of nucleus prolapse requires only simple instrumentation, namely a Sinskey hook and a 2-mL syringe with a 26-G cannula. During the learning process, one can perform the can-opener capsulotomy and prolapse the nucleus mechanically. For reasons discussed earlier, capsulorrhexis with hydroprolapse or intracapsular flip is ideal as the surgeon masters the technique. Moreover, the management of white and brown cataracts has become easier with the availability of cost-effective capsular stains, which can be effectively used, and the whole procedure made safe.

References

1. Venkatesh R, Muralikrishnan R, Balent LC, Prakash SK, Prajna NV. Outcomes of high volume cataract surgeries in a developing country. *Br J Ophthalmol* 2005;89:1079-83.
2. Natchiar G, DabralKar T. Manual small incision suture less cataract surgery: An alternative technique to instrumental phacoemulsification. *Oper Tech Cataract Refract Surg* 2000;3:161-70.
3. Muralikrishnan R, Venkatesh R, Prajna NV, Frick KD. Economic cost of cataract surgery procedures in an established eye care centre in Southern India. *Ophthal Epidemiol* 2004;11:369-80.
4. Fine IH. Cortical cleaving hydrodissection. *J Cataract Refract Surg* 1992;18:508-12.
5. Assia E, Blumenthal M, Apple DJ. Hydrodissection and viscoextraction of the nucleus in planned extracapsular cataract extraction. *Eur J Implant Ref Surg* 1992;4:3-8.
6. Krag S, Thim K, Corydon L. The stretching capacity of capsulorrhexis: An experimental study on animal cadaver eyes. *Eur J Implant Ref Surg* 1990;2:43-5.
7. Thim K, Krag S, Leif C. Stretching capacity of capsulorrhexis and nucleus delivery. *J Cataract Refract Surg* 1991;17:27-31.
8. Assia EI, Apple DJ, Tsai JC, Lim ES. The elastic properties of the lens capsule in capsulorrhexis. *Am J Ophthalmol* 1991;111:628-732.
9. Tana P, Belmonte J. Elasticity of the capsulorrhexis and delivery of the nucleus. *Eur J Implant Ref Surg* 1993;5:103-8.
10. Vasavada A, Desai J. Capsulorrhexis: Its safe limits. *Indian J Ophthalmol* 1995;44:185-90.
11. Krag S, Thim K, Corydon L. Strength of the lens capsule during hydroexpression of the nucleus. *J Cataract Refract Surg* 1993;19:205-8.
12. Venkatesh R, Das MR, Prashanth S, Muralikrishnan R. Manual small incision cataract surgery in white cataracts. *Indian J Ophthalmol* 2005;53:181-4.
13. Venkatesh R, Tan CSH, Kumar TT, Ravindran RD. Safety and efficacy of manual small incision cataract surgery for phacolytic glaucoma. *Br J Ophthalmol* 2007;91:279-81.
14. Venkatesh R. Use of capsular tension ring in phacoemulsification: Indications and technique. *Indian J Ophthalmol* 2003;51:197.

Source of Support: Nil, **Conflict of Interest:** None declared.