

Natural History of Seroma Following the Immediate Latissimus Dorsi Flap Method of Breast Reconstruction

Wen-Hui Yan^{1,2,3}, Jian-Bo Mang³, Li-Li Ren⁴, Da-Lie Liu¹

¹Department of Plastic Surgery, Zhujiang Hospital, Southern Medical University/The Second School of Clinical Medicine, Southern Medical University, Guangzhou, Guangdong 510280, China

²Department of Breast Surgery, National Cancer Center/National Clinical Research Center for Cancer/Cancer hospital & Shenzhen Hospital, Chinese Academy of Medical Sciences and Peking Union Medical College, Shenzhen, Guangdong 518116, China

³Department of Breast Surgery, Shenzhen People's Hospital, The Second Clinical Medical College of Jinan University, Shenzhen, Guangdong 518020, China

⁴Cytotherapy Laboratory, Shenzhen People's Hospital, The Second Clinical Medical College of Jinan University, Shenzhen, Guangdong 518020, China

Abstract

Background: The latissimus dorsi (LD) flap procedure remains a popular and useful breast reconstruction tool in China and Western countries, and donor site seroma formation is the main complication. This study was conducted in Chinese patients to determine whether stable cases of seromas would resolve without treatment.

Methods: A retrospective review of 45 consecutive cases of immediate breast reconstruction with LD flap from April 2012 to February 2017 was conducted. The scope of the seroma was demarcated with a marker pen, and cases that remained stable over time (i.e. the size of the seroma did not increase) were observed without treatment. The measured outcomes included the incidence of seromas, the volume and duration of postoperative wound drainage, and other demographic characteristics.

Results: Twenty-four patients (53.3%) developed a seroma at the donor site. Of these, 21 patients (87.5%) did not require treatment, and the seroma resolved over time. The mean duration of a sustained seroma was 6.8 ± 1.4 weeks (range: 4–9 weeks).

Conclusions: This study observed the scope and progression of the seromas and found that seromas at the LD donor sites resolved over time without treatment.

Key words: Autologous Breast Reconstruction; Breast Reconstruction; Latissimus Dorsi Myocutaneous Flap; Observation; Seroma

INTRODUCTION

The latissimus dorsi (LD) flap procedure is a useful tool for breast reconstruction and remains popular in China and Western countries.^[1-3] The LD flap procedure has many advantages, including safety and ease of use. This method is especially suitable for small- to medium-sized breasts and can be used to achieve good esthetic outcomes and high levels of patient satisfaction.

Seroma at the donor site, which is usually located on the back, is the main complication of the LD flap procedure. This complication is very common, with reported incidence rates ranging from 5% to 96%.^[4] A seroma is usually defined as fluid collection at the donor site that is either clinically palpable or detectable with ultrasound.^[4-6] Specifically, a seroma mainly comprises tissue fluids resulting from the disruption of lymphatic and vascular vessels. Many

approaches have been tried to prevent seroma, including progressive-tension closure at the donor site, fibrin sealants, and the use of harmonic focus shears.^[7] Once a seroma occurs, it is generally treated using serial aspiration. However, aspiration carries the risks of infection, patient discomfort, increased costs, and increased burdens on the medical team.

This study raised three main questions. First, if a seroma does not increase over time, might it resolve over time without

Address for correspondence: Dr. Da-Lie Liu, Department of Plastic Surgery, Zhujiang Hospital, Southern Medical University/The Second School of Clinical Medicine, Southern Medical University, Industrial Road No. 253, Guangzhou, Guangdong 510280, China
E-Mail: liudalie8811@126.com

This is an open access journal, and articles are distributed under the terms of the Creative Commons Attribution-NonCommercial-ShareAlike 4.0 License, which allows others to remix, tweak, and build upon the work non-commercially, as long as appropriate credit is given and the new creations are licensed under the identical terms.

For reprints contact: reprints@medknow.com

© 2018 Chinese Medical Journal | Produced by Wolters Kluwer - Medknow

Received: 11-03-2018 **Edited by:** Xin Chen

How to cite this article: Yan WH, Mang JB, Ren LL, Liu DL. Natural History of Seroma Following the Immediate Latissimus Dorsi Flap Method of Breast Reconstruction. Chin Med J 2018;131:1674-9.

Access this article online

Quick Response Code:



Website:
www.cmj.org

DOI:
10.4103/0366-6999.235877

treatment? Next, to what extent would a seroma resolve on its own? Finally, does a seroma at the donor site for breast reconstruction increase the risk of infection?

METHODS

Ethical approval

The study was conducted in accordance with the *Declaration of Helsinki* and was approved by the Ethics Committee of Shenzhen People's Hospital. The need for informed consent from patients was waived due to the study's retrospective nature.

Study population

This retrospective review included 45 consecutive cases of immediate breast reconstruction with LD flap performed by two surgeons between April 2012 and February 2017 from Shenzhen People's Hospital. Of these cases, 21 underwent extended LD flap breast reconstruction (LD group), and 24 underwent LD breast reconstruction with an implant (LD + implant group). Before the operation, all patients were fully informed about the surgical technique, the potential complications, and the potentially rigorous outpatient follow-up schedule that would be arranged if a seroma occurred.

For the purposes of this study, a seroma was defined as a palpable fluid collection at the donor site. The following patient's data were collected: age, date of surgery, side of surgery, body mass index (BMI), type of surgery with regard to axillary nodes, weight of resected LD flap, and the type of breast reconstruction. The measured outcomes included the incidence and duration of any seroma and the volume and duration of postoperative wound drainage.

Surgical technique

All patients underwent a skin-sparing mastectomy and immediate LD breast reconstruction. The surgeon attempted to preserve the skin envelope, except for the areola-nipple complex, and the skin above the tumor. To maintain symmetry with the contralateral breast and achieve a slight ptosis, the inframammary fold was marked before the procedure and preserved during the procedure.

Axillary node evaluations were based on the guidelines of the National Comprehensive Cancer Network.^[8] Harmonic focus shears (Ethicon Endo-Surgery, Inc., Cincinnati, OH, USA) were used to perform sentinel lymph node biopsies and axillary lymph node dissection, if indicated. Vessels <5 mm in diameter could be safely managed using the harmonic focus shears, but vessels with larger diameters required traditional closure with surgical sutures.

For the LD flap, the skin paddle was transversely located in the center of the back (i.e. horizontal bra strap area), with a height usually <7 cm and a length from the posterior axillary line to the vertebral line. Harmonic focus shears, rather than electrocautery, were used to harvest the LD flap. This process included muscle transection, fascia dissection, and connective tissue separation. The skin paddle was dissected

in the plane of Scarpa's fascia, with a superior border between the LD and teres major muscles. The inferior border was located up to 10 cm caudally from the low skin paddle incision and was not required to reach the iliac crest. The anterior border, which could surpass the middle axillary line in the plane of Scarpa's fascia, was more difficult to define because the LD fibers at that site were sometimes intertwined with those of the external abdominal oblique muscle. In addition, a much thinner layer of LD muscle covered the serratus muscle in that location, increasing the risk that the serratus muscle would be mistaken for the LD and thereby injured. The posterior border was the spinous processes of the six lower dorsal vertebrae. The trapezius muscle was easily recognized and protected because it was situated at the upper posterior border, with a fiber orientation nearly vertical to that of the LD muscle. The perforating branches of the intercostal and lumbar arteries were ligated similarly with axillary evaluation.

The attachment of the LD muscle to the humerus was routinely transected completely to avoid the formation of a bulge below the axilla and to avoid spontaneous muscle contractions. The thoracodorsal nerve was reserved in case of LD muscle atrophy. No quilting sutures were used at the donor site. The total weight of the resected flap was determined using a commercially available suspension scale, as has been done previously. When the flap was raised, tension among the neurovascular pedicle was avoided.^[9] For patients in the LD group, the transferred flap was laid on the pectoralis major muscle and fixed along the border of the resected site. The reconstructive breast was shaped to match the contralateral breast. For patients in the LD + implant group, an implant was inserted into the space between the transferred flap and the pectoralis major muscle. The volume of the implant was determined by the difference between the weight of the removed breast and the weight of the harvested flap.

At the end of the procedure, 16-Fr, 18-Fr, and 20-Fr drainage tubes were placed in the anterior chest, axillary fossa, and donor site, respectively. The drainage incision was located in the axillary fossa, and vacuum-assisted bottles were used to assist drainage. The drains were removed when the 24-h drainage volume decreased to <20 ml. As shown in Figure 1, patients were then asked to participate in follow-up procedures.

The treatment strategy for seroma is also presented in Figure 1. Once a seroma developed, the borders were demarcated with a marker pen, and the maximum length and height were recorded as the scope [Figure 2]. The patient was instructed to retain the mark. Typically, a mark could be maintained for at least 2 weeks in the absence of deliberate rubbing. A relative of the patient routinely checked the mark and remarked it as needed during the follow-up period. If the scope of the seroma increased, needle aspiration was applied using a 10-ml syringe every 3–5 days until the seroma disappeared.

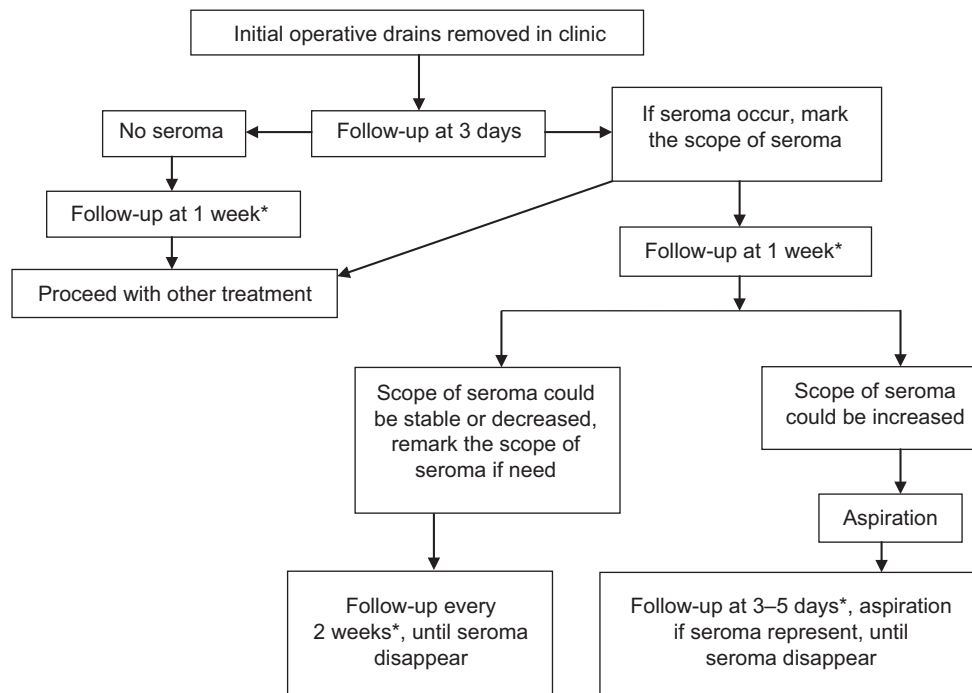


Figure 1: Algorithm for seroma management in latissimus dorsi breast reconstruction. *Sooner follow-up if indicated.

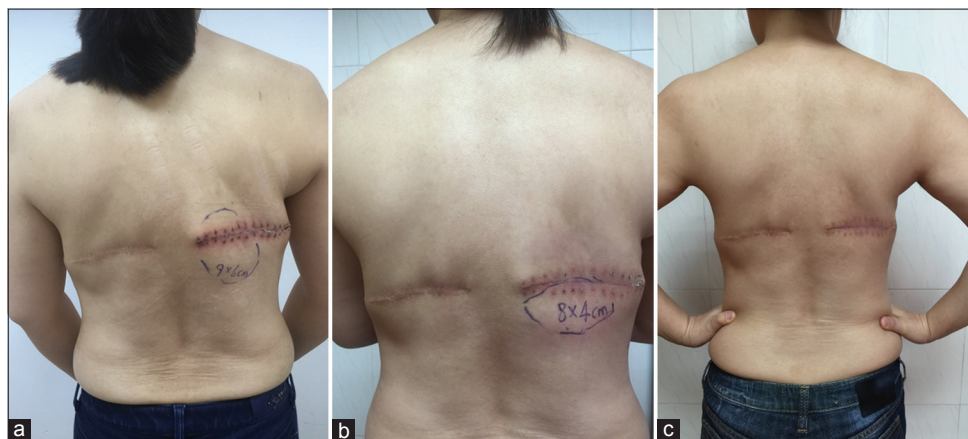


Figure 2: The scope of seroma on the back of a patient 3 days after removal of back drain (a); how much it had decreased 1 week later (b), and it disappeared 6 weeks after removal of back drain (c). The patient has undergone breast reconstruction using latissimus dorsi flap two times in 5 years.

Statistical analysis

The statistical analyses were performed using the statistical software package SPSS, version 18.0 (IBM; Chicago, IL, USA). All variables were summarized using descriptive statistics. The numerical variables were reported as mean \pm standard deviation (SD) and compared between the groups using the two-sample Student's *t*-test. The categorical variables were reported as numbers and frequencies and analyzed using the Chi-square test or Fisher's exact test. A value of $P < 0.05$ was considered as statistically significant.

RESULTS

Patient characteristics

From April 2012 to February 2017, 44 patients underwent immediate breast reconstruction with LD flap after

mastectomy (45 reconstructions). The characteristics of all patients undergoing immediate breast reconstruction with LD flap are shown in Table 1. Among all 45 reconstructions, the mean age was 37.4 ± 8.8 years, the mean BMI was 21.3 ± 2.4 kg/m², the weight of the extirpated breast tissue was 353.0 ± 126.0 g, and the weight of the resected LP flap was 263.0 ± 54.2 g. Compared with LD + implant group, the weight of the extirpated breast tissue was significantly lower, and the weight of the resected LD flap was significantly higher in the LD group (all $P < 0.001$). The two groups were similar with respect to other characteristics.

Seroma and drainage

Twenty-four patients (53.3%) developed a seroma at the donor site within 3 days of drain removal, including 13 patients in LD group and 11 patients in LD + implant group

($\chi^2 = 0.014$, $P = 0.905$). Based on the seroma management algorithm [Figure 1], however, only three patients required aspiration. The remaining 21 patients (87.5%) did not require treatment, and the seroma resolved with time. The mean duration of the seroma before self-resolution was 6.8 ± 1.4 weeks (range: 4–9 weeks). No significant intergroup difference was found for the duration of the sustained seroma.

Among all 24 patients with seroma, the mean total volumes from the back drains, and all drains were 434 ± 150 ml and 569 ± 190 ml, respectively. Notably, the total volumes from the back drains (524 ± 109 ml vs. 324 ± 116 ml, $P < 0.001$) and all drains (659 ± 170 ml vs. 462 ± 153 ml, $P = 0.010$) were significantly higher in the LD group than those of the LD + implant group [Table 2]. In addition, the time to drain removal was significantly longer in the LD group than that of the LD + implant group (8.2 ± 1.4 days vs. 6.6 ± 1.1 days, $P = 0.006$; Table 2). The longest indwelling period of back drainage was 11 days, and the average drainage volumes were around 20 ml/day over a 3-day period before the removal of the back drain [Figure 3].

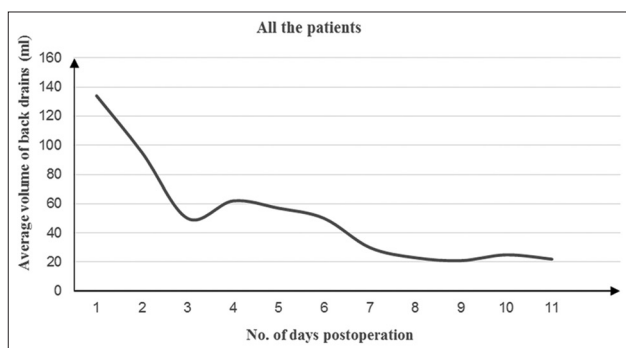

Figure 3: The average volume collected from back drains of all patients for each postoperative day.

Complications

The dorsal thoracic artery was accidentally injured and repaired microscopically with a 9-0 Monocryl suture in one patient. Two other patients developed hematomas: in one case, the hematoma presented within 24 h of surgery and was managed well with local pressure dressings; in the second case, the hematoma occurred 3 months after surgery in response to an inappropriate back massage, and reoperation was required for hemostasis. Five patients developed partial breast skin necrosis that resolved over time. Other complications, including infection, back skin healing problems and necrosis, implant contracture, and LD flap loss, were not reported.

DISCUSSION

The findings of this study demonstrated that a stable seroma in Chinese patients could resolve in 6.8 weeks on average. Although previous studies suggested that seroma might result in poor wound healing, skin flap necrosis, infection, and delayed systematic treatment,^[10] this study did not observe any issues with wound healing or skin flap necrosis at the donor sites. In addition, this study did not observe other complications related to a persistent seroma, in contrast to previously reported concerns. The seroma was usually located in the low part of the donor-site space. Minimal pressure to the wound was required because the ratio of the seroma volume to the donor-space volume was small. This small ratio might explain why seroma was not associated with wound healing problems in this study. At the time of back drain removal, the drainage should be characterized as clear and light red without any precipitates or blood clots. A seroma can be considered as a collection of non-infectious fluids and accordingly would be unlikely to lead to infection.

Of the patients in our study who developed a seroma, 21 patients (87.5%) had a stable condition (i.e., the scope

Table 1: Characteristics of patients undergoing immediate breast reconstruction with LD flap

Characteristics	LD group (n = 24)	LD + implant group (n = 21)	t	P
Age (years), mean ± SD	39.8 ± 7.3	34.6 ± 9.7	2.018	0.051
BMI (kg/m ²), mean ± SD	21.5 ± 2.0	21.0 ± 1.9	1.014	0.317
Type of surgery regarding to axillary				
Sentinel lymph node biopsy/seroma, n	15/10	13/8		
Axillary lymph node dissection/seroma, n	9/3	8/3		
Weight of breast removed (g), mean ± SD	244.0 ± 50.0	477.0 ± 42.0	-16.627	<0.001
Weight of resected LD flap (g), mean ± SD	294.0 ± 54.5	228.0 ± 23.5	5.437	<0.001

LD: Latissimus dorsi; BMI: Body mass index; SD: Standard deviation.

Table 2: Results of seroma and drainage volume in 24 patients with seroma after breast reconstruction

Items	LD group (n = 13)	LD + implant group (n = 11)	t	P
Duration of seroma (weeks), mean ± SD	6.9 ± 1.7	6.6 ± 0.9	0.670	0.510
Seroma cases requiring aspiration, n	2	1		
Total volume back drains (ml), mean ± SD	524 ± 109	324 ± 116	4.158	<0.001
Total volume all drains (ml), mean ± SD	659 ± 170	462 ± 153	2.823	0.010
Time to drain removal (days), mean ± SD	8.2 ± 1.4	6.6 ± 1.1	3.007	0.006

LD: Latissimus dorsi; SD: Standard deviation.

of the seroma did not increase over time). The average daily drainage volume decreased over time, with volumes of <30 ml during the final 3 days. Previously, Schwabegger *et al.*^[11] concluded that treatment might be unnecessary for seromas with volumes of <100 ml because they might spontaneously resorb within a short time. In our study, the back drains were removed when the 24-h drainage volume dropped below 20 ml. We hypothesized that the total volume of fluid accumulation at the donor site was <100 ml because the drainage volumes did not exceed 20 ml/day over the 3-day period when we first followed up the patients. Therefore, the observation strategy of this study was in line with that reported by Schwabegger *et al.*^[11] The findings of this study also confirmed that observation could be safely used for stable seroma because a persistent seroma was not associated with any other complications.

We noted that in addition to the inconsistent definitions of a seroma or symptomatic seroma,^[4-6] previous prospective and retrospective studies failed to use a definition of a clinically symptomatic seroma that required aspiration. Some researchers have recommended the use of serial aspiration or drainage only for patients with clinically symptomatic fluid collection at the donor site,^[4-6] which suggested that a seroma should be considered a minor complication.

We further noted that the drainage volumes in this study were less than those reported in previous studies. For example, the mean volume from the back drains in this study was 434 ml, less than the reported value of 1139 ml reported by a previous study,^[4] and the mean total volume in this study was 569 ml, compared to 1045 ml in another previous study.^[5] However, the shorter mean duration of drainage in this study might have contributed to the spontaneous resolution of the seroma in our cohort.^[12] We suggested two possible explanations for the self-resolution of the seroma. First, the patients in this study had low BMI values, and obesity (BMI >23 kg/m²) is a known as a significant contributor to the formation of seroma.^[13-15] Second, we used harmonic focus shears to transect and elevate the LD muscle in Scarpa's fascia. These shears can cut and coagulate tissues while simultaneously sealing vessels, including invisible lymphatic vessels. A previous study found that the use of these shears reduced the formation of seroma compared to the use of conventional electrocautery during LD flap breast reconstruction.^[7] The mean duration of an untreated seroma in this study was not different from the duration reported in a previous study that used serial aspiration (about 6.8 weeks), suggesting that a seroma might disappear within a set time interval regardless of treatment.^[13] However, the findings of this study were probably influenced by several factors, such as low BMI scores and the use of the harmonic shears. Serial aspiration of seroma might be required in other settings, but our findings could change the thinking about aspiration. Because the formation of a seroma did not increase the complication rate in this study, serial aspiration might be unnecessary in certain circumstances.

This study also found that the total volumes from back drains and all drains were significantly higher and the time to drain

removal was significantly longer in the LD group compared to the LD + implant group ($P < 0.05$). This finding might be attributable to the sacrifice of more donor tissue when using the extended LD flap technique to meet the weight of the extirpated breast tissue in the LD group. The data of this study showed that the weight of the resected LD flap in the LD + implant group was lower than that in the LD group. As expected, the patients in the LD + implant group experienced less severe trauma than those in the LD group.

This study used a simple strategy for seroma management that could reduce patient anxiety and discomfort, increase satisfaction, and decrease medical costs. The avoidance of repeated aspirations could also help prevent additional unnecessary physical and psychological trauma and aspiration-related wound infection.^[16-18] Despite the promising results, however, this study was limited because it was a non-randomized retrospective study with a small sample. Detection and selection biases could not be avoided completely. Prospective randomized controlled trials of seroma that compare no treatment with serial aspiration are needed to provide more powerful and reliable evidence.

In conclusion, this study observed the course of seromas in a sample of Chinese patients and found that in most cases, the seroma resolved over time without additional treatment.

Financial support and sponsorship

This study was supported in part by a grant from the Shenzhen Science and Technology Innovation Committee project (No. JCYJ20140416122811920).

Conflicts of interest

There are no conflicts of interest.

REFERENCES

1. Yu P. Breast reconstruction at the MD Anderson cancer center. *Gland Surg* 2016;5:416-21. doi: 10.21037/gs.2016.05.03.
2. Leff DR, Bottle A, Mayer E, Patten DK, Rao C, Aylin P, *et al.* Trends in immediate postmastectomy breast reconstruction in the United Kingdom. *Plast Reconstr Surg Glob Open* 2015;3:e507. doi: 10.1097/GOX.0000000000000484.2.
3. Yang B, Li L, Yan W, Chen J, Chen Y, Hu Z, *et al.* The type of breast reconstruction may not influence patient satisfaction in the Chinese population: A single institutional experience. *PLoS One* 2015;10:e0142900. doi: 10.1371/journal.pone.0142900.
4. Daltrey I, Thomson H, Hussien M, Krishna K, Rayter Z, Winters ZE, *et al.* Randomized clinical trial of the effect of quilting latissimus dorsi flap donor site on seroma formation. *Br J Surg* 2006;93:825-30. doi: 10.1002/bjs.5434.
5. Dancy AL, Cheema M, Thomas SS. A prospective randomized trial of the efficacy of marginal quilting sutures and fibrin sealant in reducing the incidence of seromas in the extended latissimus dorsi donor site. *Plast Reconstr Surg* 2010;125:1309-17. doi: 10.1097/PRS.0b013e3181d4fb68.
6. Landis LV, Brzeziński MA, Gao C, Lee T. The effect of progressive-tension closure on donor site seroma formation in delayed latissimus dorsi flaps for breast reconstruction. *Ann Plast Surg* 2016;76:170-3. doi: 10.1097/SAP.0000000000000510.
7. Sowa Y, Numajiri T, Kawarazaki A, Sakaguchi K, Taguchi T, Nishino K, *et al.* Preventive effects on seroma formation with use of the harmonic focus shears after breast reconstruction with the latissimus dorsi flap. *J Plast Surg Hand Surg* 2016;50:349-53. doi: 10.1080/2000656X.2016.1178129.

8. NCCN Guidelines for Treatment of Cancer by Site: Breast Cancer. V2.2012. Available from: <http://www.nccn.org>. [Last accessed on 2018 Feb 08].
9. Summerhayes C, Hurren J. Suspension scale to assist in volume estimation of autologous latissimus dorsi flap. *J Plast Reconstr Aesthet Surg* 2007;60:329-30. doi: 10.1016/j.bjps.2006.05.004.
10. Baciliou N, Kulber DA, Peters ED, Gayle LB, Chen MJ, Harper AD, *et al*. Harvesting of the latissimus dorsi muscle: A small animal model for seroma formation. *Microsurgery* 1995;16:646-9. doi: 10.1002/micr.1920160911.
11. Schwabegger A, Ninković M, Brenner E, Anderl H. Seroma as a common donor site morbidity after harvesting the latissimus dorsi flap: Observations on cause and prevention. *Ann Plast Surg* 1997;38:594-7.
12. Bailey SH, Oni G, Guevara R, Wong C, Saint-Cyr M. Latissimus dorsi donor-site morbidity: The combination of quilting and fibrin sealant reduce length of drain placement and seroma rate. *Ann Plast Surg* 2012;68:555-8. doi: 10.1097/SAP.0b013e318216b65c.
13. Jeon BJ, Lee TS, Lim SY, Pyon JK, Mun GH, Oh KS, *et al*. Risk factors for donor-site seroma formation after immediate breast reconstruction with the extended latissimus dorsi flap: A statistical analysis of 120 consecutive cases. *Ann Plast Surg* 2012;69:145-7. doi: 10.1097/SAP.0b013e3182259337.
14. Tomita K, Yano K, Masuoka T, Matsuda K, Takada A, Hosokawa K, *et al*. Postoperative seroma formation in breast reconstruction with latissimus dorsi flaps: A retrospective study of 174 consecutive cases. *Ann Plast Surg* 2007;59:149-51. doi: 10.1097/SAP.0b013e31802c54ef.
15. Fischer JP, Fox JP, Nelson JA, Kovach SJ, Serletti JM. A Longitudinal Assessment of Outcomes and Healthcare Resource Utilization After Immediate Breast Reconstruction-Comparing Implant- and Autologous-based Breast Reconstruction. *Ann Surg* 2015;262:692-9. doi: 10.1097/SLA.0000000000001457.
16. Woo KJ, Paik JM, Mun GH, Pyon JK, Jeon BJ, Bang SI. Analysis of factors influencing drain amount, time to drain removal, and seroma formation in patients undergoing immediate expander-implant breast reconstruction. *J Plast Surg Hand Surg* 2018 ;52:53-59. doi: 10.1080/2000656X.2017.1330208.
17. Griner D, Steffen CM, Day KM, Brzeziński MA. Barbed Ribbon Device for Progressive Tension Closure Reduces Seroma After Breast Reconstruction. *Ann Plast Surg* 2017;79:541-545. doi: 10.1097/SAP.0000000000001217.
18. Sajid MS, Betal D, Akhter N, Rapisarda IF, Bonomi R. Prevention of postoperative seroma-related morbidity by quilting of latissimus dorsi flap donor site: A systematic review. *Clin Breast Cancer* 2011;11:357-63. doi: 10.1016/j.clbc.2011.04.006.

即刻背阔肌皮瓣乳房重建术后供区血清肿的演变

摘要

背景: 在中国和西方国家, 背阔肌皮瓣法 (LD) 仍然是一个广泛应用的重建乳房方式, 其中供区血清肿是主要的并发症。我们的研究目的是判断患者术后稳定的供区血清肿是否会自然吸收。

方法: 我们对2012年4月至2017年2月的45例即刻背阔肌皮瓣乳房重建术患者进行了回顾性分析, 用记号笔标记患者供区血清肿的积液范围和对积液范围保持稳定的患者 (即积液容积没有增加者) 进行观察随访, 测量数据包括供区血清肿发生率、血清肿容量、术后伤口引流时间和患者基本特征。

结果: 24例患者 (53.3%) 出现供区血清肿, 其中21例患者的血清肿 (87.5%) 不需要干预而缓慢自然吸收, 血清肿的平均持续时间为 6.8 ± 1.4 周 (范围为4-9周)。

结论: 大部分即刻背阔肌皮瓣乳房重建术后稳定的供区血清肿会缓慢自然吸收。
