

Available online at www.sciencedirect.com

ScienceDirect

journal homepage: www.elsevier.com/locate/radcr

Case Report

Caudal regression syndrome (Currarino syndrome) with chromosom mutation 9 [☆]

Kristina Bevanda^{a,*}, Irma Memidžan^b, Ana Boban-Raguž^b

^a Health Center Mostar, Hrvatskih Branitelja b.b., 88000 Mostar, Bosnia and Herzegovina

^b University Clinical Hospital Mostar, Mostar, Bosnia and Herzegovina

ARTICLE INFO

Article history:

Received 18 January 2020

Revised 8 May 2020

Accepted 11 May 2020

Keywords:

Currarino syndrome

Agenesis of sacrum

Heterochromatin

Chromosome 9

Sequencing

ABSTRACT

Currarino syndrome is a rare set of congenital anomalies that include partial sacral agenesis, anorectal anomalies, presacral mass, urogenital malformation, and fistula between pelvic structures. We present a case of a 4-year and 10-month-old boy with incomplete Currarino syndrome, who was born with anus atresia, rectovesical fistula, and permanent perimembranous VSD. At the age of 3, he was diagnosed with neurogenic bladder and sacrococcygeal agenesis. Early psychomotor development was normal.

Cytogenetic GTG-banding test confirmed a male karyotype 46, XY with high heterochromatin in chromosome 9, without mutation of the MNX 1 gene (chromosome 7q36). This genetic analysis is a result of "de novo mutation" or it is the disorder of DNA methylation.

Further genetics analyses like whole-exome sequencing - WES should have been preformed if the test had been available.

The existence of Currarino syndrome should be suspected among the children born with anorectal malformation. Prompt diagnosis with multidisciplinary monitoring improves the care and quality of life of the patient, reduces morbidity and mortality.

© 2020 The Authors. Published by Elsevier Inc. on behalf of University of Washington.

This is an open access article under the CC BY-NC-ND license.

(<http://creativecommons.org/licenses/by-nc-nd/4.0/>)

Introduction

Currarino syndrome was described for the first time in 1981 as an unknown set of symptoms. The syndrome includes a set of congenital anomalies: sacral agenesis (with first sacral vertebrae intact), anorectal anomaly, presacral mass (anterior meningocele, enteric cyst and/or presacral teratoma), urogenital malformation, and fistula between pelvic structures. The

family predisposition of the disease is noticeable and it is an autosomal dominant inherited disease [1]. In 33% of cases, the disease remains asymptomatic. Since the expressiveness is various, it is difficult to estimate the exact prevalence of the disease. A certain number of cases are linked to gestational diabetes. A patient with Currarino syndrome requires long-term multidisciplinary monitoring and necessary invasive procedures [2].

[☆] Competing Interests: The authors have declared that no competing interests exist. Funding: None.

* Corresponding author.

E-mail address: kbevanda88@gmail.com (K. Bevanda).

<https://doi.org/10.1016/j.radcr.2020.05.023>

1930-0433/© 2020 The Authors. Published by Elsevier Inc. on behalf of University of Washington. This is an open access article under the CC BY-NC-ND license. (<http://creativecommons.org/licenses/by-nc-nd/4.0/>)

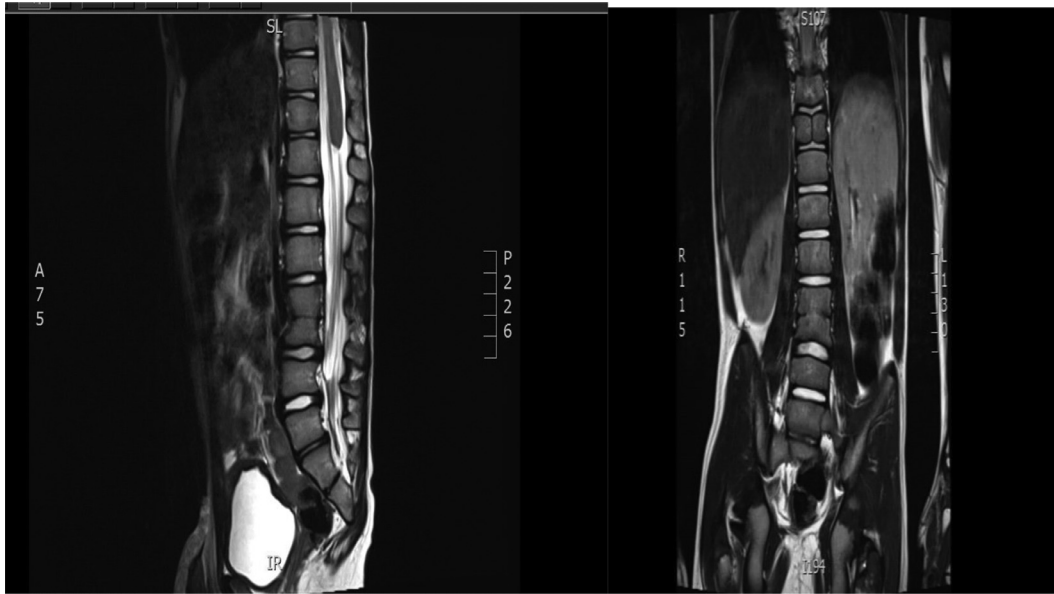

Fig. 1 – The conus medullaris ends high and obtuse at the level of intervertebral space of Th11-Th12. Nerve roots are visible up to S3 vertebra, but from the level of Th12, directly below the conus, they are atypically positioned intradurally, clustered/osculant and thickened.

Case presentation

The boy at the age of 4 years and 10 months was admitted for his first pediatric neurological examination within the nephrological treatment of neurogenic bladder. He was fourth born child of healthy parents (full-term pregnancy, natural vaginal delivery, BW 3000 g (10-25c.), BL 51 cm (50-75c.), Apgar score 10/10.) There are 2 older healthy children in the family. The boy was diagnosed with anus atresia that was surgical treatment and a colostomy was performed. A histologic examination of the colonic tissue confirmed Morbus Hirschsprung. When he was 2 months old, colostomy occlusion was performed as well as the repair of rectovesical fistula. He has been regularly vaccinated according to the National Immunisation Programme from Bosnia and Herzegovina.

PKU/CAH/hypothyroidism tests were performed. Rickets prophylaxis was carried out. His mother did not take folic acid prenatally. Regular early psychomotor development (sitting—7 months, running—14.5 months, saying the first words—18 months).

The boy suffered from occasional constipation and frequent asymptomatic bacteriuria. At the age of 3 years, widespread diagnostic treatment was recommended due to pure urination control.

Physical examination at the first pediatric neurological examination (4 years and 10 months: asthenic, BW 17 kg (10c), BH 114.5 cm (90c), BMI 12.97 (<3C), clinodactyly of the fifth finger, otapostosis, flat gluteus muscles, short intergluteal cleft, capable of establishing appropriate social contact.

Neuraxis MRI was performed as a part of diagnostic treatment. The Brain MRI scan was normal, without pathomorphological deviations. The MRI scan of thoracic and lumbosacral

regions shows the reduced height of the anterior part of the Th 11 vertebra body and lateral vertebral halves which failed to fuse, forming “Butterfly vertebrae.” There is an incomplete block of L3 and L4 vertebra bodies. It excludes a portion of the sacrum from the S3 level to the coccygeal bone. Conus medullaris ends high and obtusely at the level of the intervertebral area of Th11-Th12 vertebrae. Nerve roots are visible up to S3 vertebra, but from the level of Th12 body, directly below the conus, they are atypically positioned, intradural, clustered/osculant and thickened, all the way to the L3–L4 level, without signs of pathological imbibition after contrast application. The described changes correspond to the caudal regression syndrome. Pelvic MRI scan and ultrasound examination of the abdomen did not show any presacral mass (Figs. 1–3).

Diuretic dynamic scintigraphy of bladder verified hypotension of the renal canal system to the left. Electromyoneurography of motor fibers of n. peroneus bilaterally, sensory fibers of n. suralis to the right and myography of lower extremities were normal.

The ultrasound examination (2D Color Doppler) of the heart showed a perimembranous ventricular defect with diameter 3 mm. Psychological assessment (interview, RTČ test, M-CHAT) classifies the boy into the category of the lower limit of proper psychomotor development. Verbal knowledge, communication, and interaction skills are slightly below chronological age, so the boy is recommended to be treated, by a speech-language therapist and a special educator.

Cytogenetic analysis of GTG-banding established a cytogenetic diagnosis of male karyotype with an excess of heterochromatin in chromosome 9 – 46 XY, 9qh+ (attached illustration, Fig. 4). Both mother and father also had a cytogenetic analysis of GTG-banding, which showed that the father had the same cytogenetic diagnosis – male karyotype with an ex-

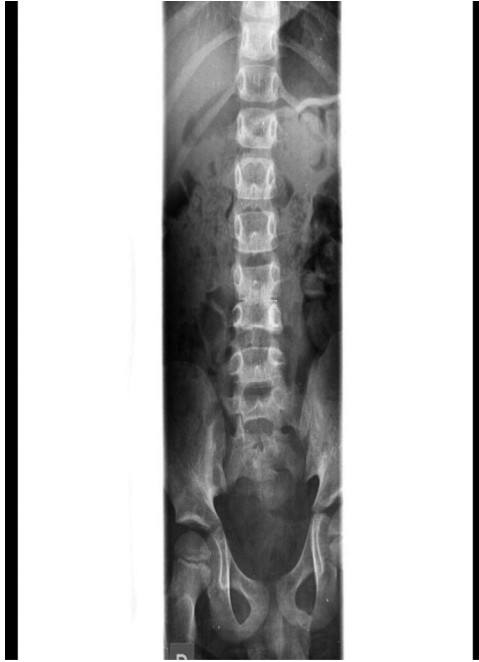

Fig. 2 – X-ray display of sacral agenesis with the first sacral vertebra intact.

cess of heterochromatin in chromosome 9 – 46 XY 9qh + (Fig. 5), while the mother of the child had a Normal female karyotype, 46 XX (attached findings, Fig. 5). The X-ray examination of the mother and father’s lumbar and sacral spine, as well as of their pelvis showed minor degenerative changes, with no signs significant for Currarino syndrome. Molecular genetic sequencing of the MNX1 gene did not identify a DNA-related

variant associated with the phenotype, which fails to exclude variants outside the analyzed MNX1 gene and confirms gene heterogeneity.

Discussion

There are 2 types of Currarino syndrome: complete and incomplete depending on the number of accompanying anomalies. Sacrococcygeal bone defect, presacral mass, and anorectal malformation represent a classical Currarino triad or the complete type. Or type I if only 1 or 2 of the above-mentioned malformations are present, then it is classified as an incomplete type of the syndrome [3]. Constipation, bowel obstruction, Hirschsprung’s disease, urinary retention, and incontinence are often the first presentation of Currarino syndrome [4]. The disease can occur at any age and it is rarely discovered in the neonatal period. Since our patient had anus atresia, a rectovesical fistula, and the absence of the development of the sacrococcygeal bone at birth, it points to the incomplete form of Currarino syndrome in this case. Due to the suspicion of urinary incontinence with the previously observed asymptomatic bacteriuria and the inability to establish proper urination control, a wider diagnostic treatment was started when he was 3 years old. Up to 15% of patients with Currarino syndrome have the accompanying anomaly of Mullerian ducts compared to the incidence of about 7% in the general population [5]. Therefore, the frequency of occurrence is slightly higher in females. Autosomal dominant inheritance was first described by Yates et al. in 1983 [6]. The gene mutation at chromosome 7q36 was discovered in 1995. In this locus, the mutation of gene HLXB9 was confirmed in most family-inherited Currarino syndromes. Gene HLXB9 has 3 exons, encoding a

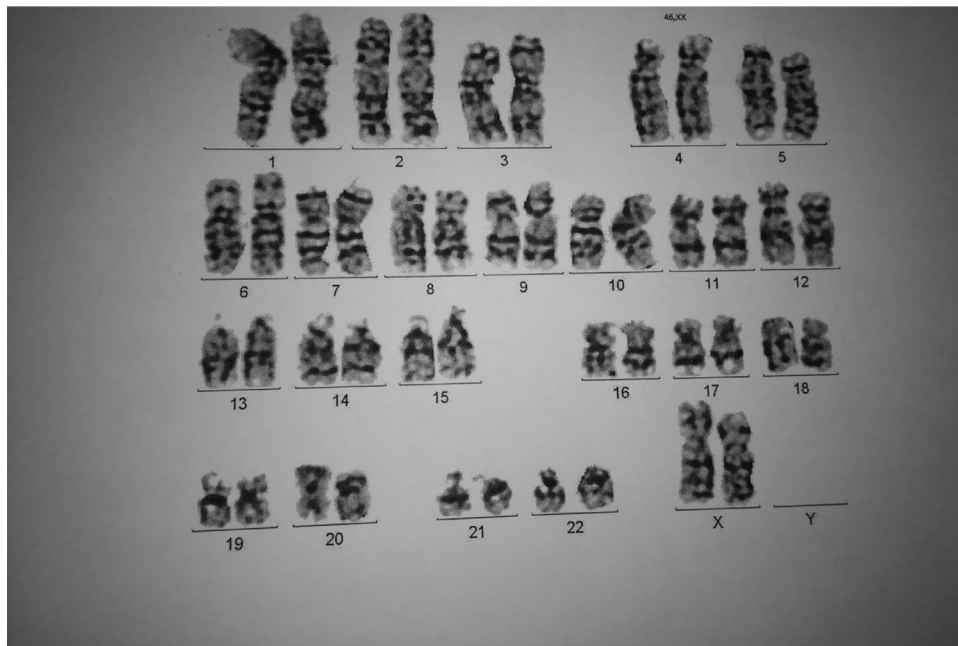


Fig. 3 – Cariogram of the mother.

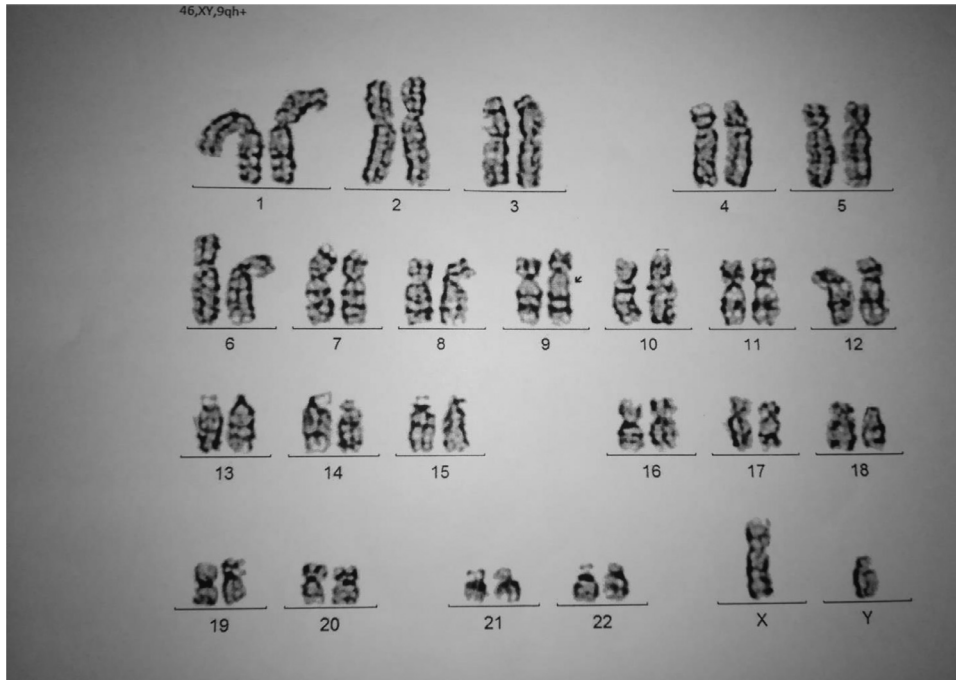


Fig. 4 – Cariogram of the patient.

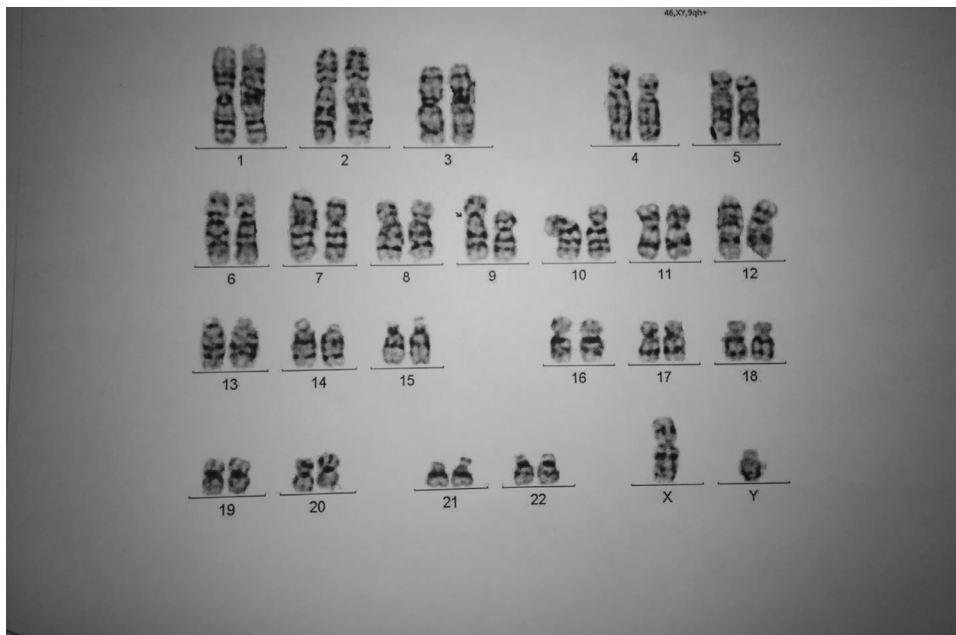


Fig. 5 – Cariogram of the father.

protein of 403 amino acids [7]. The role of the gene is unknown, and most probably it is a transcription factor. Further research should prove its role in normal development. Up to 30% of patients are sporadic cases, and out of the total number of sporadic cases, 30% of them are mutated [8,9]. Among the rest of sporadic cases, the mutation of the HLXB9 gene was not detected, which can be explained by somatic mosaicism, undetected mutation of another gene, or genetic heterogeneity.

In our patient, a karyogram confirmed a male karyotype with a variation in the population with the excess of heterochromatin in chromosome 9. All previous studies have linked the syndrome with the mutation in chromosome seven [10]. This is the first case of Currarino syndrome, as far as it is known to the authors, which is related to changes in chromosome 9. Some of the possible explanations are that there are changes in DNA methylation or a "de novo" mutation that resulted in

a diagnosis of Currarino syndrome. For these reasons, further investigation into this case needs to be made, as the described change may influence the further development of the clinical picture. This is additionally confirmed by the absence of presacral mass in our patients. In one large research on heteromorphisms on the ninth chromosome, it was found that 1.3 times more often, a mother is a source of heteromorphisms of the ninth chromosome, but those 2 observed cases showed the father to be a source of 9qh + [11].

Normally, it is believed that this is an early embryonic disorder of mesoderm differentiation, that is, disorders of secondary granulating that occur in early development [12]. One of the key tests for the diagnosis of Currarino syndrome is the radiological examination. Today, MRI is considered to be a better method than CT, since MRI is more available today than CT [13]. Radiological examinations in patients suffering from this disease regularly determine the anterior sacral defect. The first sacral vertebra is mostly intact with possible mild abnormalities. The sacrum is usually crescent-shaped or in the form of hemisacrum, and it might be Bifida-like with central defects along with coccygeal bone defects, combined or isolated [14].

MRI images of our patient's neuraxis fail to display sacrum portion from S3 level to coccygeal bone in terms of agenesis. The first sacral vertebra is preserved, which points to Currarino syndrome. Surgical interventions are often needed at an early age if anorectal malformations are present, which was the case with our patient. As a presacral mass, which alters into teratoma with a certain number of patients, is a part of the syndrome and surgical intervention is possible later in life. There was a case of a patient at the age of 52 who was diagnosed with teratoma and a woman at the age of 32 who, unlike the aforementioned patient, died of teratoma [6,13]. The patients with milder symptoms can be treated conservatively; however, regular controls are very important to a patient with Currarino syndrome due to various complications including perianal sepsis as a life-threatening condition that may indicate the presence of presacral mass [15]. Screening among nuclear family members is left to free choice because of a certain number of asymptomatic heterozygotes, but regular monitoring is certainly recommended for the possible development of symptoms in the coming years. It is possible to detect presacral mass with prenatal ultrasonography, which would be indicative of Currarino syndrome, although there is only 1 recorded case of prenatal diagnosis of presacral mass, namely in a patient with an extraordinarily large mass [14].

Conclusion

The existence of Currarino syndrome should, among other diseases, be suspected among the children born with an

anorectal malformation. Prompt diagnosis with multidisciplinary monitoring improves the care and quality of life of the patient, reduces morbidity and mortality, and enables genetic counseling and further family planning.

The Ethics Committee of the institution has issued an approval. The parents have signed the informed consent.

REFERENCES

- [1] Markljung E, Adamovic T, Cao J, et al. Novel mutations in the MNX1 gene in two families with Currarino syndrome and variable phenotype. *Gene* 2012;507(1):50–3.
- [2] Kassir R, Kaczmarek D. A late-recognized Currarino syndrome in an adult revealed by an anal fistula. *Int J Surg Case Rep* 2014;5(5):240–2.
- [3] Sarsua Sevgi Buyukbese, Parmaksiz Mehmet Ergun, Cabalar Esra, Karapur Ali, Kaya Cihat. A very rare cause of anal atresia: Currarino syndrome: case report. *J Clin Med Res* 2016;8(5):420–3.
- [4] Furuta S, Sato H, Hamano S, Kitagawa H. Currarino syndrome, associated with Hirschsprung's disease: case report, and literature review. *J Ped Surg Case Reports* 2015;3:308–11.
- [5] Robbins JB, Broadwell C, Chow LC, Parry JP, Sadowski EA. Mullerian duct anomalies: embryological development, classification, and MRI assessment. *J Magn Reson, Imaging* 2015;41(1):1–12.
- [6] Yates VD, Wilroy RS, Whittington L, Simmons JCH. Anterior sacral defects: an autosomal dominantly inherited, condition. *J Pediatr* 1983;102:239–42.
- [7] Harrison KA, Druey KM, Deguchi Y, Tuscano JM, Kehrl JH. A novel human homeobox gene distantly related to *proboscipedia* is expressed in lymphoid and pancreatic tissues. *J Biol Chem* 1994;269:19968–75.
- [8] Hagan DM, Ross AJ, Strachan T, et al. Mutation analysis and embryonic expression of the HLXB9 Currarino syndrome gene. *Am J Hum Genet* 2000;66(5):1504–15. doi:10.1086/302899.
- [9] Merello E, De Marco P, Ravegnani M, Riccipettoni G, Cama A, Capra V. Novel MNX1 mutations and clinical analysis of familial and sporadic Currarino cases. *Eur J Med Genet* 2013;56(12):648–54.
- [10] Pang D. Sacral agenesis and caudal spinal cord malformations. *Neurosurgery* 1993;32:755–78.
- [11] Kosyakova N, Grigorian A, Liehr T, Manvelyan M, Simonyan I, Mkrtchyan H. Heteromorphic variants of chromosome 9. *Mol Cytogenet* 2013;6:14. doi:10.1186/1755-8166-6-14.
- [12] Lang IM, Wilson BPM. Case report. An unusual association of a rectovaginal fistula with the Currarino triad. *Clin Radiol* 1994;49:281–3.
- [13] Ashcraft KW, Holder TM. Hereditary presacral teratoma. *J Pediatr Surg* 1974;9:691–7.
- [14] Lynch Sally Ann, Wang Yiming, Strachan T, Burn John, Lindsay Susan. Autosomal dominant sacral agenesis: Currarino Syndrome. *J Med Genet* 2000;37:561–6.
- [15] O'Riordain DS, O'Connell PR, Kirwan WO. Hereditary sacral agenesis with presacral mass and anorectal stenosis. *Br J Surg* 1991;78(5):536–8. doi:10.1002/bjs.1800780507.