

## Unusual cause of neuropathy: extensive dural spread of primary cervical osteosarcoma

Stephen N Ponnampalam<sup>1,2</sup>, Wilkinson YJ Tan<sup>3</sup>, Nayyer Naveed Wazir<sup>3</sup> and John George<sup>4</sup>

<sup>1</sup>Department of Orthopaedic Surgery, Hospital Tuanku Ja'afar, Seremban; <sup>2</sup>Cancer Research Center, Institute for Medical Research (IMR), Kuala Lumpur; <sup>3</sup>Department of Orthopaedic Surgery, International Medical University (IMU), Seremban; <sup>4</sup>Department of Biomedical Imaging, University of Malaya Medical Center, Kuala Lumpur, Malaysia  
Correspondence to: Stephen N Ponnampalam. Email: ponnams99@yahoo.com

### Abstract

We report a very rare case of a high grade osteosarcoma of the cervical spine in a 62-year-old woman. She presented with a relatively short history of a swelling in the posterior neck and cervical lymphadenopathy. This was associated with hoarseness of the voice, significant weight loss, and right upper arm radicular symptoms initially, progressing to paraplegia. Based on MR and CT imaging of the neck and an excision biopsy of an enlarged right supraclavicular lymph node, the histology revealed a high grade primary osteosarcoma of the cervical spine.

**Keywords:** Osteosarcoma, metastasis, paraplegia

Submitted November 15, 2011; accepted for publication January 18, 2012

Primary osteosarcoma of the spine is a very rare tumor. It accounts for only 3–5% of all osteogenic sarcomas and 4–14% of primary spinal tumors (1). While conventional (appendicular) osteosarcoma occurs predominantly between the ages of 10–25 years, osteosarcoma of the spine occurs at a mean age of 38 years (2). Overall, the prognosis is worse for osteosarcoma of the spine when compared to its appendicular counterpart. Due to the rarity of vertebral osteosarcoma, we report a case of a 62-year-old woman who presented with a primary osteosarcoma of the cervical spine. The tumor was centered around the C2–C4 vertebrae with the rare feature of extensive extension into the intradural space spanning the length of at least three vertebral bodies with metastasis to the cervical lymph nodes and lung. At the level of the C2–C4 vertebral bodies, the tumor extends into the spinal cord occupying almost the entire diameter of the spinal canal. As far as we are aware, there has been no other case report in the literature of a primary osteosarcoma of the spine with such extensive intradural spread resulting in paraplegia.

### Case report

The patient was a 62-year-old woman brought in to the hospital by her daughter who said that the patient had

complained of several swellings in her neck region over a period of 4 months.

All the swellings had progressively increased in size and the patient indicated that she had pain upon flexion, extension, and rotation of the neck. The pain was associated with hoarseness and a lowering in pitch of the voice. She had significant weight loss (approximately 30% reduction) over the past 4 months. The patient also complained of some weakness of the right upper limb and numbness of the right hand.

Upon examination, the patient was cachexic with significant muscle wasting especially in the supraclavicular fossae. Examination of the neck revealed three swellings as follows: swelling 1: Posterior neck: swelling measured 7 × 8 cm, round, well-defined margins, firm, rubbery, not attached to the superficial fascia but fixed to the muscle, not mobile, and mildly tender to palpation; swelling 2: Right level V(B) lymph node measuring 3 × 2 cm, well-defined borders, firm, rubbery, not mobile, not fixed to the superficial fascia, and mildly tender to palpation; and swelling 3: Left level III lymph node measuring 2 × 2 cm, well-defined borders, firm, rubbery, not attached to the superficial fascia, not mobile, and mildly tender to palpation.

The following investigations were carried out:

- (a) An excision biopsy of the right neck level V (B) lymph node showed a high grade sarcoma, consistent with

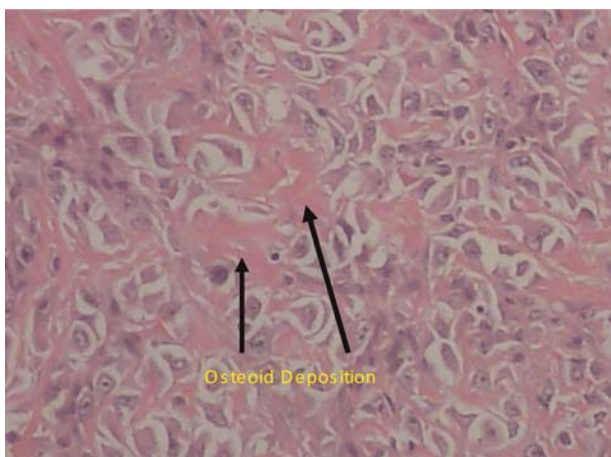
osteosarcoma. The histopathological examination showed cells having osteoid deposition (osteoblastic variant of osteosarcoma) (Fig. 1) and staining positively with vimentin and smooth muscle actin but not with S100 protein;

- (b) Magnetic resonance imaging (MRI) of the neck showed a  $5 \times 4$  cm posterior neck tumor, centered around the spinous processes of C2–C4, with bony destruction. The tumor also enveloped the posterior elements and wrapped around them. Anteriorly, the tumor extended up to the spinal canal, compressing the spinal cord but without any abnormal cord signal. There was enhancement of the posterior dura and body of C2 and C3 suggesting dural and bony involvement. There were also multiple enhancing neck nodes;
- (c) Computed tomography (CT) of the chest and abdomen showed pleural and lung nodules most likely metastasis, in view of the history;
- (d) Contrast-enhanced CT (CECT) of the neck, thorax, and abdomen after the patient had received three cycles of chemotherapy with IV Doxorubicin  $20 \text{ mg/m}^2$  and IV Cisplatin  $25 \text{ mg/m}^2$  showed tumor progression with worsening of lung metastases and cervical lymph node involvement; extensive intradural involvement from C2 to C4 (Figs. 2 and 3) was seen as well.

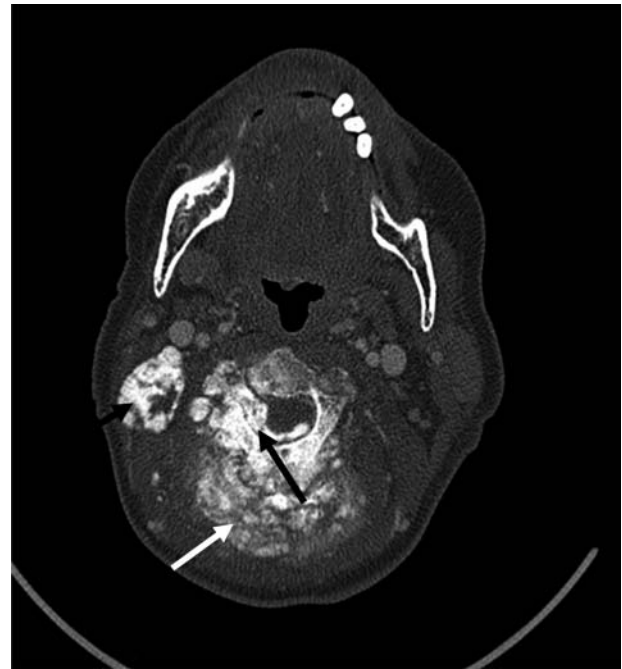
Due to these findings a decision was made to stop chemotherapy and start radiotherapy. The patient underwent one session of radiotherapy and was to continue with this treatment when she suddenly became paraplegic. The patient refused any further treatment.

## Discussion

In osteosarcoma of the spine, the lumbosacral spine is the most common site followed by the thoracic and cervical spine, respectively (3). The vertebral body is involved about 90% of the time while the remainder involve the body and posterior elements (4). The tumor may also extend into the pedicle and impinge on the spinal roots



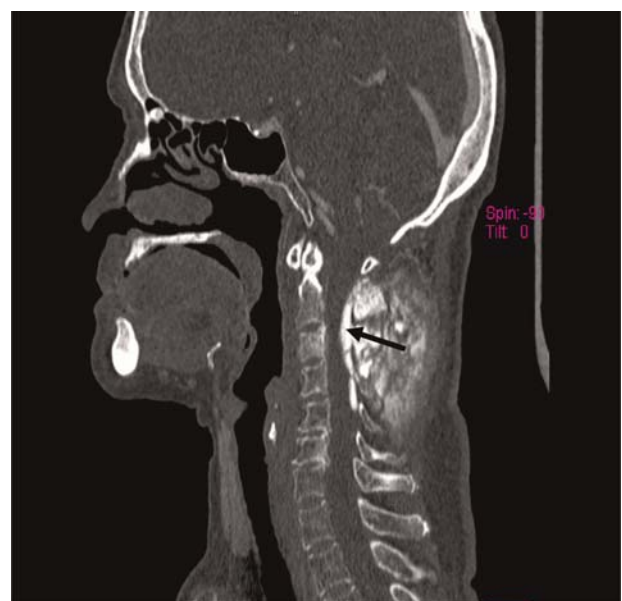**Fig. 1** Histopathological section of the ossified lymph node in Fig. 2 showing malignant cells dispersed in an osteoid matrix (hematoxylin-eosin, magnification  $\times 10$ )



**Fig. 2** Axial CT (bone window) with contrast of the upper neck shows a tumor arising from the lamina of C3 associated with large soft tissue ossification (white arrow), right ossified upper cervical lymph node (small black arrow), and intradural and right foraminal epidural ossification (large black arrow)

(5). In other cases, the tumor may be associated with an extraosseous mass (6).

The clinical presentation varies depending on the level of vertebral involvement. Pain is the commonest presenting feature. Over 85% of patients complain of pain, particularly severe neck pain when the cervical vertebrae are involved. Other clinical features include neurological symptoms



**Fig. 3** Sagittal reconstructed CT of the neck showing ossified intradural tumor posteriorly in the spinal canal from C2 to upper C5 level. Extensive intradural spread is a very rare finding in cervical osteosarcoma

such as sensory deficits and motor abnormalities, and the presence of a palpable mass (6). In some cases these symptoms may be longstanding before the diagnosis is made. In our case the patient had minimal neurological symptoms.

There are several histological variants of vertebral osteosarcoma (7). In the case presented here, the histopathology clearly showed malignant osteoid deposition (osteoblastic variant).

Radiologically, most spinal osteosarcomas present as an osteoblastic shadow of dense mineralized matrix (8). Compression of the vertebra occurs frequently. Since spinal osteosarcoma is a highly malignant tumor, it readily invades the spinal canal secondary to a soft-tissue mass as seen on CT and MRI (9). In our patient, the tumor epicenter and origin was at the C3 spinous process. There was direct extension into the soft tissues posteriorly and extensive intradural spread from C2 to C4 as evidenced from the CT and MRI scans.

Treatment of spinal osteosarcoma takes a multimodal approach. Current therapies include surgical resection, radiation, and chemotherapy. In addition, with recent advances using intensity-modulated, proton and carbon-ion radiotherapy, radiation doses can be safely administered to microscopic residual tumor (10–12).

In conclusion, this case emphasizes the need to use MRI first, to ascertain the full extent of spinal canal spread in a primary vertebral osteosarcoma, before treatment is instituted. It also demonstrates that intradural spread of such a tumor can be quite extensive, far beyond the primary region of involvement.

#### ACKNOWLEDGEMENTS

The authors thank the Director General of Health, Malaysia for permission to publish this manuscript. They also thank

Dr Suriyani Mohd Yusoff, Pathologist, Hospital Seremban for preparing the histopathology slides and Dr Noraini Mohd Dusa, Pathologist, Hospital Kuala Lumpur for a second opinion.

**Conflict of interest:** None.

#### REFERENCES

- 1 Shives TC, Dahlin DC, Sim FH, *et al.* Osteosarcoma of the spine. *J Bone Joint Surg Am* 1986;**68**:660–8
- 2 Campanacci M, Osteosarcoma Cervellati G. A review of 345 cases. *J Orthop Traumatol* 1975;**1**:5–22
- 3 Dregghorn CR, Newman RJ, Hardy GJ, *et al.* Primary tumors of the axial skeleton. Experience of the Leeds Regional Bone Tumor Registry. *Spine* 1990;**15**:137–40
- 4 Barwick KW, Huvos AG, Smith J. Primary osteogenic sarcoma of the vertebral column. A clinicopathologic correlation of ten patients. *Cancer* 1980;**46**:559–604
- 5 Gandolfi A, Bordi C. Primary Osteosarcoma of the cervical spine causing neurological symptoms. *Surg Neurol* 1984;**21**:441–4
- 6 Green R, Saifuddin A, Cannon S, *et al.* Pictorial review: Imaging of primary osteosarcoma of the spine. *Clin Radiol* 1996;**51**:325–9
- 7 Unni KK. Osteosarcoma. In: Unni KK. *Dahlin's Bone Tumors: General Aspects and Data on 11,087 Cases*. 5th edn. Philadelphia, PA: Lippincott Williams & Wilkins, 1996:143–83
- 8 Sansur CA, Pouratian N, Dumont AS, *et al.* Part II: Spinal-cord neoplasms: primary tumors of the bony spine and adjacent soft tissues. *Lancet Oncol* 2007;**8**:137–47
- 9 Ilasslan H, Sundaram M, Unni KK, *et al.* Primary vertebral osteosarcoma: imaging findings. *Radiology* 2004;**230**:697–702
- 10 Yamada Y, Lovelock DM, Yenice KM, *et al.* Multifractionated image-guided and stereotactic intensity-modulated radiotherapy of paraspinal tumors: a preliminary report. *Int J Radiat Oncol Biol Phys* 2005;**62**:53–61
- 11 DeLaney TF, Park L, Goldberg SI, *et al.* Radiotherapy for local control of osteosarcoma. *Int J Radiat Oncol Biol Phys* 2005;**61**:492–8
- 12 Imai R, Kamada T, Tsuji H, *et al.* Cervical spine osteosarcoma treated with carbon-ion radiotherapy. *Lancet Oncol* 2006;**7**:1034–5