

Case Report

Influence of bevacizumab on vaginal cuff evisceration eight months after ovarian cancer cytoreduction surgery: A case report [☆]



Amanda J. Skwara ^{a,*}, Russell J. Schilder ^{b,c}, Allison Zibelli ^b, Norman G. Rosenblum ^c

^a Jefferson Medical College of Thomas Jefferson University, Philadelphia, PA, USA

^b Department of Medical Oncology, Jefferson Medical College of Thomas Jefferson University, Philadelphia, PA, USA

^c Department of Obstetrics and Gynecology, Division of Gynecologic Oncology, Jefferson Medical College of Thomas Jefferson University, Philadelphia, PA, USA

ARTICLE INFO

Article history:

Received 2 April 2013

Accepted 24 June 2013

Available online 1 July 2013

Keywords:

Epithelial ovarian cancer

Delayed evisceration

Bevacizumab

Introduction

Novel developments in treatment have improved the 5-year survival rate for women diagnosed with epithelial ovarian cancer. In addition to standard surgical cytoreduction and platinum/taxane chemotherapy, bevacizumab has recently been demonstrated to improve the progression-free survival rate in patients with ovarian cancer (Burger et al., 2011). Bevacizumab is a humanized monoclonal antibody that binds to vascular endothelial growth factor A (VEGF-A), blocks the interaction with its receptor, and effectively alters angiogenesis (Braghiroli et al., 2012). Bevacizumab is thought to normalize hyperpermeable intratumoral blood vessels thereby increasing the delivery of simultaneously administered cytotoxic agents and, after continued treatment, collapsing these vessels (Martin and Schilder, 2007; Jain, 2005). Bevacizumab as a single agent has approximately a 20% response rate in recurrent ovarian cancer (Burger et al., 2007; Cannistra et al., 2007). This activity is among the highest for any cancer, and is probably because normal ovarian tissue is already primed to respond to VEGF for follicle maturation as well as growth and formation of the corpus luteum (Martin and Schilder, 2007).

Although generally well tolerated, bevacizumab has a number of side effects including hypertension, arterial/venous thromboembolic

events, proteinuria, neutropenia, gastrointestinal perforations, and, most important to this report, wound dehiscence (Braghiroli et al., 2012). The majority of wound-healing complications following bevacizumab have been reported early in the post-operative course, with few complications documented long after surgical intervention (Deshaies et al., 2010).

To our knowledge, this is the first report of vaginal cuff evisceration at eight plus months post cytoreduction surgery for ovarian carcinoma soon after initiation of antiangiogenic therapy.

Case report

We report on a 44 year old patient who was referred to our services in November 2010.

Prior to referral, the patient was identified as having a large multicystic heterogeneous right adnexal mass and a small left sided lesion, for which she underwent a laparoscopic bilateral salpingo-oophorectomy. The pathology showed the right and left ovary to be involved with a high-grade, poorly differentiated, mixed epithelial ovarian cancer with both clear cell and endometrioid adenocarcinoma histologies; the right ovary was fragmented and the left ovarian capsule intact. Peritoneal washings were negative and endometriosis was also identified. Post-operatively, she had a CA-125 level of 284 units/ml.

The patient was referred to our service and underwent an exploratory laparotomy, debulking, lysis of adhesions, hysterectomy, resection of a benign right lobe hepatic lesion, resection of a pelvic tumor at the posterior vaginal wall, pelvic peritoneotomy, omentectomy, appendectomy, pelvic, para-aortic, and common iliac bilateral lymph node dissection, and staging for ovarian carcinoma. At completion, there was no gross evidence of any disease and the final pathology confirmed FIGO stage IIC mixed epithelial ovarian carcinoma.

Subsequently, the patient was treated with six cycles of both intravenous and intraperitoneal chemotherapy, which was completed on April 4, 2011. At this time, the patient was examined and found to have a new firm right vaginal apex lesion suspicious for persistent disease with a CA-125 of 104 units/ml. She was then placed on bevacizumab for a total of 4 cycles and had a complete resolution of this nodular area with a CA-125 level returning to normal limits at 21 units/ml. Her last dose of bevacizumab was given on July 14, 2011.

By history, the patient had intercourse for the first time post-operatively on July 31, 2011, which she reported to be extremely

[☆] This is an open-access article distributed under the terms of the Creative Commons Attribution-NonCommercial-No Derivative Works License, which permits non-commercial use, distribution, and reproduction in any medium, provided the original author and source are credited.

* Corresponding author at: Jefferson Medical College, 310 S. 10th St. Apt. 4B Philadelphia, PA 19107, USA.

E-mail address: amanda.skwara@jefferson.edu (A.J. Skwara).

painful. The next day she complained of fullness in her vagina accompanied by a vaginal discharge. She was examined on August 2, 2011 and found to have complete dehiscence of the vaginal apex with small bowel evisceration into the upper vagina. The patient's vagina was packed, a foley catheter inserted, and she was emergently admitted to the hospital. She was then brought into the operating room for reduction of the small bowel evisceration (Fig. 1), repair of the vaginal apex with left rectus abdominal muscle flap reinforcement of this repair (Figs. 2 and 3), and placement of an On-Q ball pain system (Tobin et al., 1990). Peritoneal washings were obtained with pathology showing highly atypical cells present in a background of acute inflammation. The surgery was well tolerated. Bevacizumab was discontinued and the patient was placed on maintenance albumin-bound paclitaxel every three weeks for one year. She currently has no signs of disease with a most recent CA-125 of 13 units/ml (normal range <35). Upon physical examination all surgical incisions, including the vaginal apex, are well healed.

Discussion

Antiangiogenic therapy is known to directly result in a number of adverse reactions, including wound-healing complications. For this reason, bevacizumab is typically added to platinum/taxane chemotherapy at cycle 2 of adjuvant therapy to reduce the risk of dehiscence. Most reported bevacizumab-related wound complications in patients with ovarian cancer are in women recently in the postoperative period (Burger et al., 2011; Koskas et al., 2010). However, even after a significant period of time from surgery prior to bevacizumab administration, there have been reports of wound complications; most involving bowel perforation and some occurring as long as 78 months after surgical intervention (Deshaies et al., 2010;

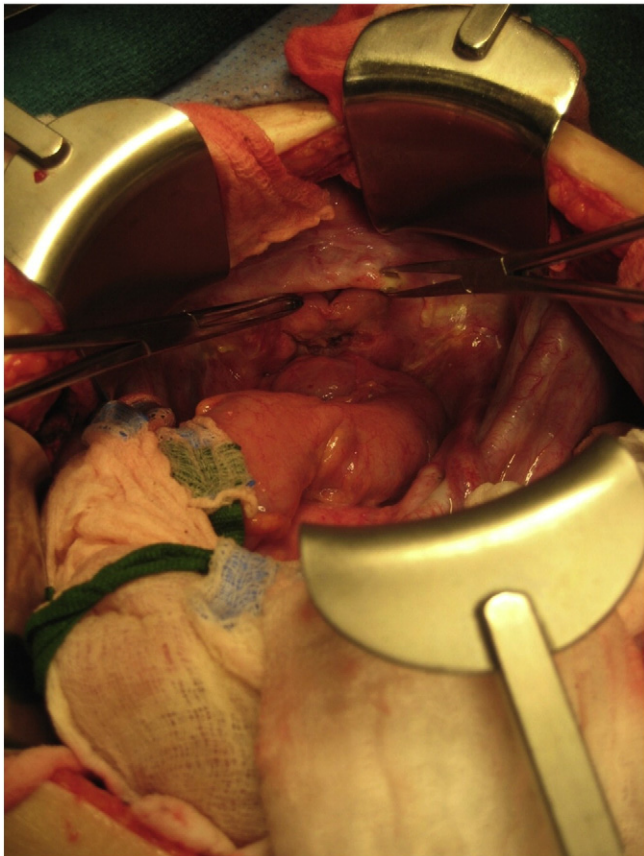


Fig. 1. Allis clamps on vaginal apex following reduction of the small bowel evisceration and prior to the vaginal cuff repair.

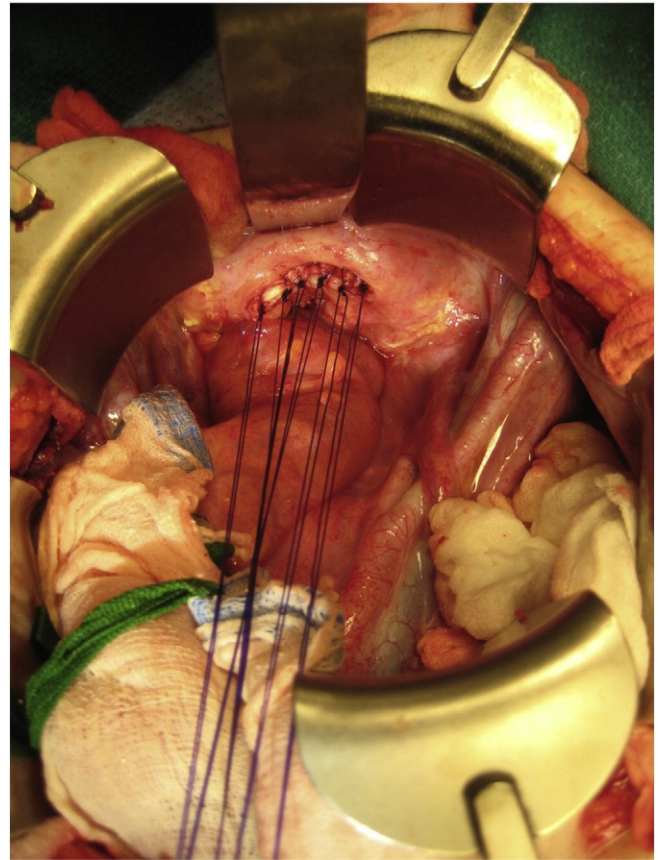


Fig. 2. Vaginal cuff repair using #0 Polydioxanone (PDS) sutures.

Eveno et al., 2011). In all of these cases, the correlation between bevacizumab administration and the wound complication seems to implicate the antiangiogenic compound as the causative agent. Here, we report on an unusual manifestation of this problem in a woman experiencing wound dehiscence and evisceration at the vaginal apex after 4 cycles of bevacizumab and 8+ months postoperatively. Because of the unusually long time span between surgical intervention and wound complication, it is likely, as there were no other risk factors so far removed from surgery other than the administration of bevacizumab, that the administered bevacizumab is the most likely cause.

Recent reports show that bevacizumab induces a vessel “normalization window,” decreasing hypoxia initially and allowing for the enhanced delivery of additional chemotherapeutics (Winkler et al., 2004). However, these effects wane with time, increasing hypoxia and ischemia within the solid tumor, and eventually leading to increased necrosis of the treated tissue. Since the patient's recurrent tumor had developed in an area nearby or possibly involving the former surgical wound at the vaginal cuff, potentially necrotic residual areas at the wound site following treatment with bevacizumab may have led to the vaginal wound dehiscence and subsequent bowel evisceration.

A surgical wound can take up to two years to heal completely with a maximal strength of only 80% of the original tissue even in the absence of wound healing impediments (Tibbs, 1997). This healing process is defined by inflammation, proliferation, and maturation. The inflammatory phase occurs during the first three days post operatively and includes the formation of the fibrin clot, migration of neutrophils, macrophages, and monocytes, and the enhancement of angiogenesis by macrophage derived VEGF-A (Willenborg et al., 2012). The proliferative phase occurs two days to three weeks post

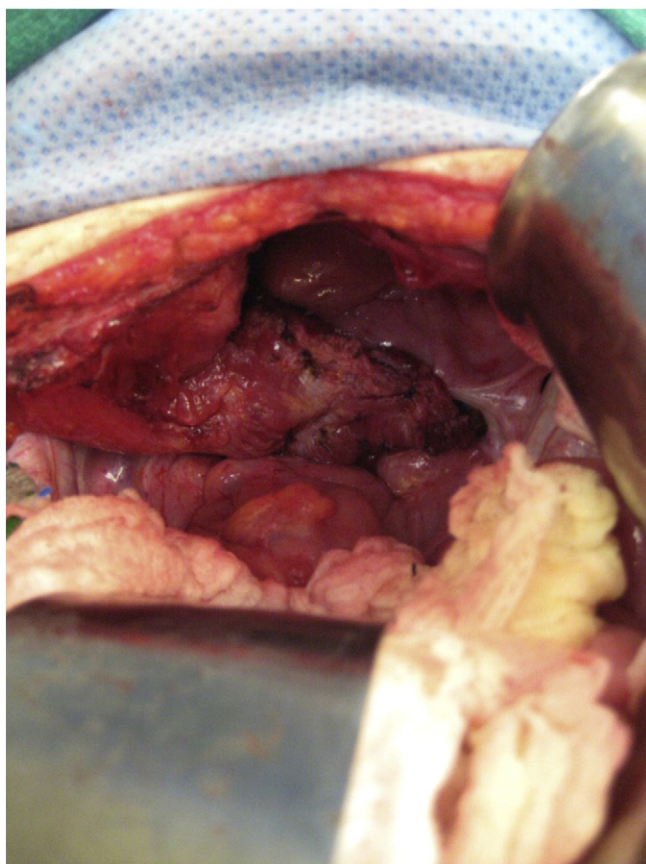


Fig. 3. Left rectus muscle flap reinforcement of the vaginal cuff repair.

operatively and encompasses the accelerated production of collagen, whereas the maturation phase includes an increase in collagen content and tensile strength beginning during the proliferative phase and continuing until the wound is completely healed. It is thought that anastomotic leaks and ascites may delay the healing process by halting wound repair in the inflammatory and proliferative phases, a time when VEGF-A production by monocytes/macrophages is at its peak (Deshaies et al., 2010; Koskas et al., 2010; Willenborg et al., 2012). Although there were no clinical signs of ascites evident in this patient, the lack of lymph nodes along her pelvic floor post-resection could have led to greater accumulation of fluid and potentially delayed vaginal cuff healing (Gmyrek et al., 2011). The vaginal cuff may have thereby been more susceptible to dehiscence following treatment with bevacizumab due to the increased presence of VEGF-A during the inflammatory and proliferative stages. This increase in susceptibility, in combination with bevacizumab's necrotic effect on the patient's solid tumor may very well have led to the complete dehiscence of the vaginal apex and subsequent evisceration.

Vaginal cuff dehiscence as a complication of total abdominal hysterectomy occurs rarely (reported incidence up to 0.26%) (Cronin et al., 2012). Risk factors include increased age, chronic cough, vaginal cuff infection and/or hematoma, a greater number of vaginal surgeries, and vaginal atrophy (Cronin et al., 2012). In concordance with this report, other factors associated with poor wound healing and dehiscence include malnutrition, tissue radiation, chronic steroid use, and malignancy. There is a great deal of variability in the timing of reported vaginal cuff dehiscence, ranging from 3 days to 30 years post-operatively. Over 70% of such cases have been reported to occur sponta-

neously; others have occurred with precipitating events such as valsalva, strained defecation, and, as in the case of this patient, intercourse (Cronin et al., 2012). Intercourse is likely to have been the trigger via trauma to a predisposed scar and surrounding tissue that was primed by exposure to bevacizumab resulting in deterioration of the vaginal cuff and subsequent bowel evisceration.

Conclusion

Antiangiogenic agents, such as bevacizumab, can result in wound healing complications even when primary administration occurs long after surgical intervention. The surgical wound at the vaginal apex was expected to be sufficiently healed at eight months, making this complication unanticipated. Although antiangiogenic drugs do not appear to be harmful to fully healed wounds, when metastases occur at a surgical site and/or a surgical site has the potential for chronic inflammation, the hypoxia that these agents induce may result in unexpected complications. In patients that meet these criteria, physicians should practice with a higher index of suspicion to avoid a possible life-threatening situation.

Conflict of interest statement

The authors report no conflict of interest.

Acknowledgements

Photographs courtesy of Patrick J. Greaney, MD.

References

- Braghiroli, M.I., Sabbaga, J., Hoff, P.M., 2012. Bevacizumab: overview of the literature. *Expert Rev. Anticancer Ther.* 12, 567–580.
- Burger, R.A., Sill, M.W., Monk, B.J., Greer, B.E., Sorosky, J.I., 2007. Phase II trial of bevacizumab in persistent or recurrent epithelial ovarian cancer or primary peritoneal cancer: a Gynecologic Oncology Group Study. *J. Clin. Oncol.* 25, 5165–5171.
- Burger, R.A., Brady, M.F., Bookman, M.A., Fleming, G.F., Monk, B.J., Huang, H., et al., 2011. Incorporation of bevacizumab in the primary treatment of ovarian cancer. *N. Engl. J. Med.* 365, 2473–2483.
- Cannistra, S.A., Matulonis, U.A., Penson, R.T., Hambleton, J., Dupont, J., Mackey, H., et al., 2007. Phase II study of bevacizumab in patients with platinum-resistant ovarian cancer or peritoneal serous cancer. *J. Clin. Oncol.* 25, 5180–5186.
- Cronin, B., Sung, V.W., Matteson, K.A., 2012. Vaginal cuff dehiscence: risk factors and management. *Am. J. Obstet. Gynecol.* 206, 284–288.
- Deshaies, I., Malka, D., Soria, J.C., Massard, C., Bahleda, R., Elias, D., 2010. Antiangiogenic agents and late anastomotic complications. *J. Surg. Oncol.* 101, 180–183.
- Eveno, C., le Maignan, C., Soyer, P., Camus, M., Barranger, E., Pocard, M., 2011. Late anastomotic colonic dehiscence due to antiangiogenic treatment, a specific drug-class complication requiring specific treatment: an example of pazopanib complication. *Clin. Res. Hepatol. Gastroenterol.* 35, 135–139.
- Gmyrek, L.J., Jonska-Gmyrek, J., Sobiczewski, P., Panek, G., Bidzinski, M., 2011. Evaluation of intraoperative and postoperative complications related to lymphadenectomy in ovarian cancer patients. *Oncol. Lett.* 2, 537–541.
- Jain, R.K., 2005. Normalization of tumor vasculature: an emerging concept in antiangiogenic therapy. *Science* 307, 58–62.
- Koskas, M., Chereau, E., Ballester, M., Selle, F., Rouzier, R., Darai, E., 2010. Wound complications after bevacizumab treatment in patients operated on for ovarian cancer. *Anticancer Res.* 30, 4743–4747.
- Martin, L., Schilder, R., 2007. Novel approaches in advancing the treatment of epithelial ovarian cancer: the role of angiogenesis inhibition. *J. Clin. Oncol.* 25, 2894–2901.
- Tibbs, M.K., 1997. Wound healing following radiation therapy: a review. *Radiother. Oncol.* 42, 99–106.
- Tobin, G.R., Pursell, S.H., Day Jr., T.G., 1990. Refinements in vaginal reconstruction using rectus abdominis flaps. *Clin. Plast. Surg.* 17, 705–712.
- Willenborg, S., Lucas, T., van Loo, G., Knipper, J.A., Krieg, T., Haase, I., et al., 2012. CCR2 recruits an inflammatory macrophage subpopulation critical for angiogenesis in tissue repair. *Blood* 120, 613–625.
- Winkler, F., Kozin, S.V., Tong, R.T., Chae, S.S., Booth, M.F., Garkavtsev, I., et al., 2004. Kinetics of vascular normalization by VEGFR2 blockade governs brain tumor response to radiation: role of oxygenation, angiopoietin-1, and matrix metalloproteinases. *Cancer Cell* 6, 553–563.