



Pitt Hopkins-Like Syndrome I with Novel CNTNAP2 Mutation in Siblings

Rea Mittal, BS¹ , Ashutosh Kumar, MD², Roger Ladda, MD³, Gayatra Mainali, MD², and Ermal Aliu, MD³

Abstract

Pitt Hopkins-like syndrome I (PTHLSI, OMIM # 610042) is an ultra-rare autosomal recessive condition with a prevalence of <1/1,000,000. Intragenic deletions of CNTNAP2 has been implicated in PTHLSI, however to our knowledge a compound heterozygous deletion of exon 4 and a c.1977_1989del13; p.V660Ffsx9 frameshift variant have not been published previously. In this case report, the proband is a seven year old female with PTHLSI, developmental delay, autism spectrum disorder, focal epilepsy, hypotonia, refractory errors, strabismus, and obstructive sleep apnea. Whole exome sequencing analysis revealed biallelic pathogenic variants of the CNTNAP2 gene. Proband has a three year old sister who has who has a similar phenotype including, developmental delay, epilepsy, gait abnormality, refractory errors, strabismus. Family variants were tested and she shared the same CNTNAP2 variants as her sister. The sisters described highlight two novel variants leading to PTHLSI. Genetic workup is essential in identification and management guidance in these populations.

Keywords

pitt Hopkins-like syndrome I, cortical dysplasia-focal epilepsy syndrome, CNTNAP2, pediatrics, epilepsy, developmental delay, intellectual disability

Received August 5, 2021. Received revised September 28, 2021. Accepted for publication October 5, 2021.

Background

Pitt-Hopkins-Like Syndrome 1 (PTHSL1) is a rare autosomal recessive inherited neurodevelopmental disorder, with prevalence estimated to be less than one in one million.¹ PTHSL1 is characterized by delayed psychomotor development, facial dysmorphisms, breathing abnormalities, hypotonia, and diminished deep tendon reflexes. Patients can also have severe intellectual disability, behavioral abnormalities, autistic features, and early onset epilepsy.²

PTHLS is caused by homozygous or compound heterozygous aberrations in the contactin-associated protein-like 2 gene (CNTNAP2) on chromosome 7q35-q36. The CNTNAP2 gene is one of the largest genes in the human genome, spanning 2.4 Mb and containing 24 exons.³ CNTNAP2 encodes contactin-associated protein 2 (CASPR2), a transmembrane protein of the neuroligin family theorized to function in clustering of voltage gated potassium channels at the nodes of Ranvier in myelinated axons, neural circuit assembly for developing neurons, and maturation of spiny synapses.⁴ CNTNAP2 alterations have been implicated in numerous neuropsychiatric disorders such as PTHLS1,

Cortical Dysplasia-Focal Epilepsy Syndrome (CDFES), intellectual disability, Tourette's syndrome, obsessive compulsive disorder, autism, schizophrenia, and attention deficit hyperactivity disorder.³

Certain CNTNAP2 deletions have been documented leading to PTHLS1. A case series listed pathogenic variants including both compound heterozygous and homozygous mutations involving different combinations of the 24 exons. All eight patients demonstrated epilepsy, intellectual disability, and absent or limited expressive speech and verbal comprehension. Five patients had behavioral problems such as aggression and

¹Penn State Health College of Medicine, Hershey, USA

²Department of Pediatrics and Neurology, Penn State Health College of Medicine, Hershey, USA

³Department of Pediatrics, Penn State Health College of Medicine, Hershey, USA

Corresponding Author:

Ermal Aliu, Department of Pediatrics, Penn State Health College of Medicine, 90 Hope Drive, Hershey, PA, 17033, USA.

Email: ealiu@pennstatehealth.psu.edu



stereotypic hand movements while three patients had decreased deep tendon reflexes.⁴ A similar case series including three patients with CNTNAP2 mutations demonstrated lack of speech, episodes of hyperventilation, wide mouth facial dysmorphism, and seizures onset before 40 months.⁵ Nine Amish individuals with CNTNAP2 homozygous single base deletions in exon 22 (c.3709delG) have been associated with gross motor delay, frontal and temporal seizures beginning at age 2, and language regression and stereotypic behaviors beginning at age 3.⁶

In this article, we describe two in trans novel pathogenic mutations causing PTHSL1 in siblings.

Case Report

The proband is a seven year old term female born via cesarean section without complications to non-consanguineous parents. In her first few years of life, she demonstrated delayed motor skills. She crawled at 15 months, walked independently at 26 months, and began putting words together at 28 months.

She had facial dysmorphic features including frontal bossing with slightly down-turning of orbital ridges. By 2.5 years, she had gross motor delay, speech delay, generalized hypotonia, hyporeflexia, strabismus, and astigmatism. Her strabismus required surgery and she needed glasses for her astigmatism and refractory error. At this age, an outside hospital MRI was completed that reported no abnormalities.

Relevant family history includes father's two grand mal seizures at 15 and 18 years who is now seizure free for the past 15 years.

Whole exome sequencing analysis through GeneDx (Bethesda, MD) revealed a paternally inherited deletion of exon 4 and maternally inherited c.1977_1989del13;p.V660FfsX9 pathogenic variant in the CNTNAP2 (NM_014141.5) gene, suggestive of

PTHSL1. The patient was also a carrier for a paternally inherited likely pathogenic variant (c.2539_2540dupCA; p.Q847HfsX18) in exon 28 of the COL6A2 gene (NM_001849.3).

At around three years of age, the patient presented with multiple focal seizures. One seizure type involved bilateral tonic clonic convulsions lasting three to five minutes followed by vomiting. Another seizure type involved staring with upward gaze and head deviation to one side, Patient was unresponsive during these five to ten minute episodes that were similarly followed by vomiting. Continuous EEG performed at out-side institution revealed over 20 right hemispheric onset focal seizures, for which she received levetiracetam and oxcarbazepine. Her processing difficulties and sensory issues at this age were also consistent with autism spectrum disorder.

At four years of age, Epilepsy Monitoring Unit (EMU) evaluation revealed poorly sustained background rhythm, frequent interictal right central temporal sharp waves and vertex sharp waves and rare left central and temporal sharp waves, consistent with focal seizure tendency (Figure 1). No electrographic seizures were recorded. She also presented with sleep disturbances, behavioral issues and agitation and was diagnosed with mild obstructive sleep apnea. She continued to have learning and cognitive delay.

At five years of age, family noted speech regression after prolonged seizures that improved slowly. Her CT brain/head without contrast revealed no intracranial abnormality. She was receiving speech therapy, occupational therapy, and physical therapy. Her oxcarbazepine was discontinued due to ineffective seizure control and levetiracetam was discontinued due to behavioral concerns. At seven years of age, the child's epilepsy was being managed with valproic acid and low dose CBD oil drop mainly for sleep and behavioral issues. Her seizures were not controlled, therefore lamotrigine was added recently.

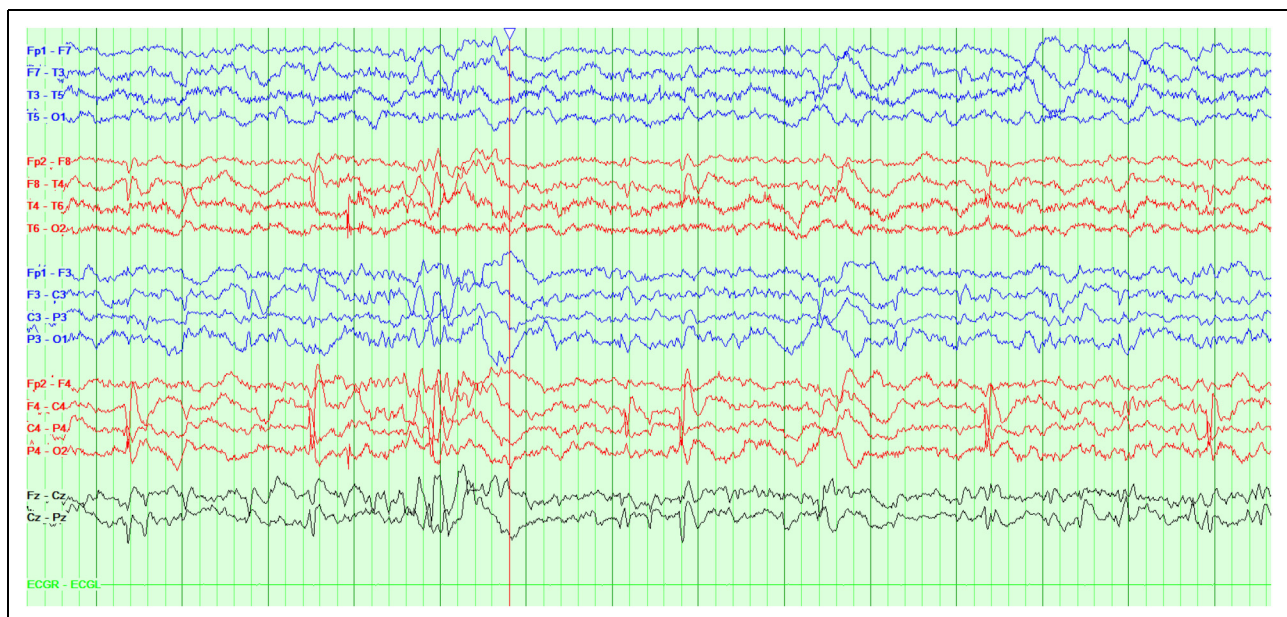


Figure 1. Interictal EEG of proband demonstrating frequent right centrotemporal spikes and sharps. Ictal episodes not captured during EEG monitoring.

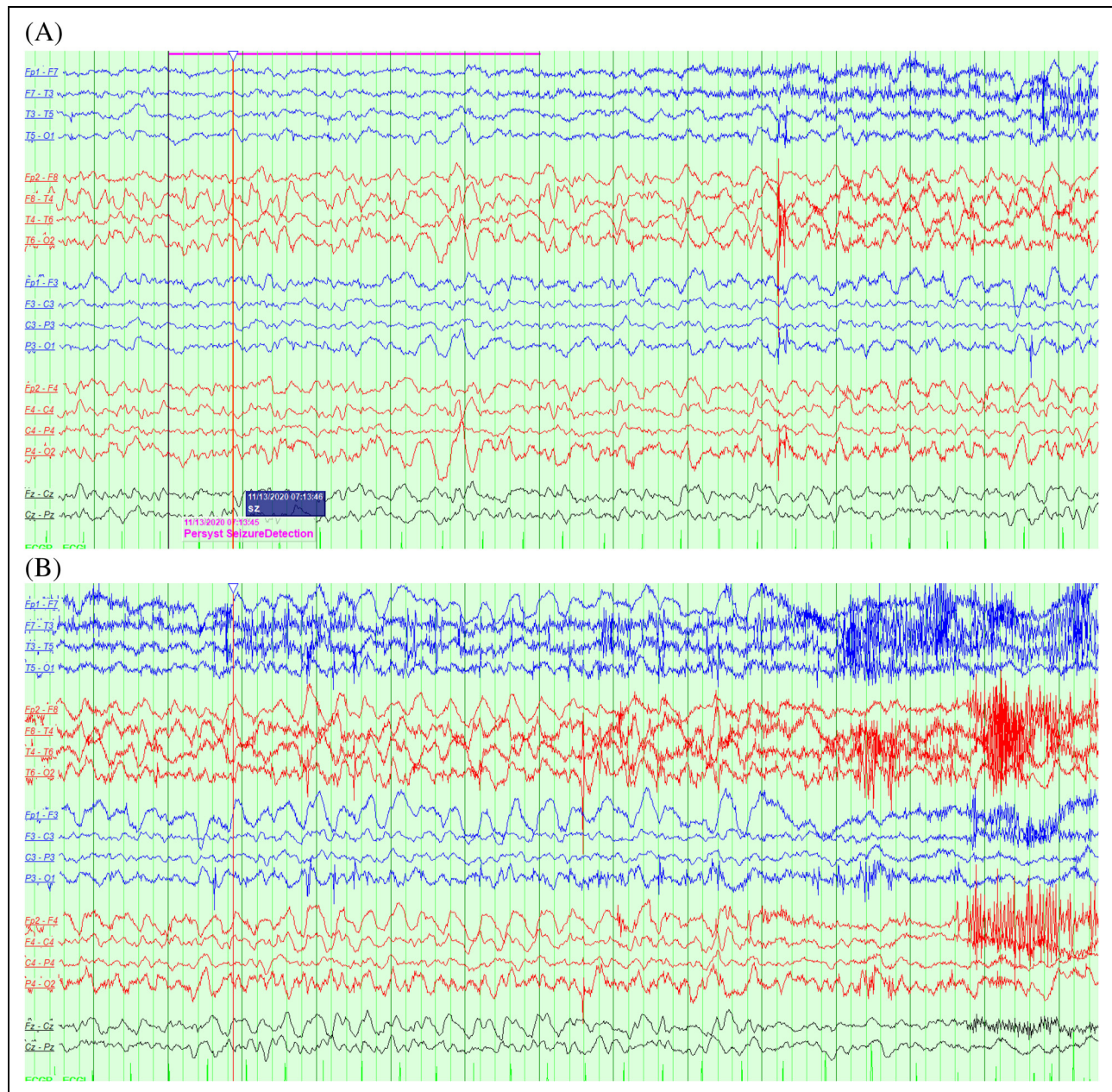


Figure 2. Ictal EEG of proband's sibling demonstrating seizure onset right fronto-temporal region (A) and subsequent seizure spread to entire right hemisphere and left frontotemporal region (B).

Proband has a younger three-year-old sister born at full term via vaginal delivery. She was kept in the NICU for a week due to suspected sepsis. Proband's sister shared motor developmental delays and did not stand independently until 16 months. Neurologic exam revealed mild hypotonia, areflexia, strabismus, refractory error requiring glasses, and facial dysmorphisms including hypertelorism, broad nasal bridges. Initial EEG and MRI revealed no abnormality.

Proband's sister also underwent genetic testing and was found to have the same pathogenic CNTNAP2 variants as the proband. She is not a carrier for the COL6A2 gene variant, however she maternally inherited a duplication at the 17p12 cytogenetic band which includes the PMP22 gene. The

mother was asymptomatic but was recommended for further evaluation for Charcot-Marie-Tooth disease.

At two years and eleven months, proband's sister had new onset bilateral convulsive status lasting 45 min. EEG revealed frequent right hemisphere interictal epileptiform discharges with diffuse and focal right hemisphere frontal and temporal region slowing consistent with focal seizure tendency (Figure 2A and B). Multiple seizures ensued in the following months which were initially managed with levetiracetam. Due to behavioral concerns, levetiracetam was discontinued and switched with divalproex sodium with subclinical seizures still noted on EEG. Oxcarbazepine was added and breakthrough seizures decreased.

Discussion

The siblings presented in this case report demonstrate two novel, unpublished pathogenic variants in CNTNAP2 gene. The entire deletion of exon 4 and c.1977_1989del13 variant. The second variants cause out of frame shift at position 660 starting with Valine to Phenylalanine residue change and creating a new reading frame with a premature stop codon at position 9 of the new reading frame, leading to protein truncation and expected to cause loss of normal protein function as it is predicted to be degraded via nonsense-mediated mRNA decay pathway. Several pathogenic variants of CNTNAP2 have been documented however this particular combination has not been reported to our knowledge.

The proband demonstrated many characteristics consistent with previous descriptions of PTHSL1. She presented with infantile delayed motor development, hyporeflexia, early onset epilepsy, hypotonia, behavioral issues including agitation, speech regression and autism spectrum disorder. Proband's sister similarly demonstrated delayed motor development, areflexia, early onset epilepsy, and hypotonia. She did not have reported behavioral issues or verbal regression as the proband did, but these may develop as she grows. Proband was also found to have likely pathogenic variant in COL6A2 gene. Pathogenic variants in COL6A2 have been associated with Ullrich congenital muscular dystrophy (UCMD) (OMIM #254090) on the severe end of the spectrum, Bethlem myopathy (OMIM #158810) on the mild and in between an intermediate myopathy with variable presentation in autosomal dominant or recessive fashion.⁷ A similar out of frame pathogenic variant (c.24642delA:p.Q881RfsX13) in exon 28 which affects C2 domain, has been reported in a patient with moderate-progressive UCMD but the inheritance was recessive as the patient carried a second pathogenic variant (c.2462-3C>A).⁸ As our patient's father is not reportedly affected and extrapolating previous reports, our impression is that she is a carrier for COL6A2 related disorders.

The proband's younger sister demonstrated an inherited 1.1 Mb duplication at the 17p12 cytogenetic band from her asymptomatic mother which includes the PMP22 gene associated with Charcot-Marie Tooth disease (CMT1A). This may have contributed to some of this patient's symptoms of motor delay, gait abnormality, and areflexia. Considering the mother is asymptomatic, there is the possibility that the daughter may also be asymptomatic and the symptoms could represent PTHSL1.

The siblings did not present with episodes of hyperventilation or breath holding apnea as described in some reports of PTHSL1.^{5,9} They both exhibit speech delay with the proband experiencing speech regression, where total loss of speech is seen in severe cases.^{4,9}

Both sisters demonstrated slightly differing dysmorphic features, where high variability in facial dysmorphisms including broad forehead, prominent columella, widely spaced teeth, and wide mouth have been documented for PTHSL1.^{5,9,10} They also presented with ophthalmic issues including refractory strabismus, requiring surgical correction for the proband. Ophthalmic abnormalities are infrequently cited in literature,

however this could broaden the phenotypic spectrum of this disorder, as it is present in both siblings and warrants further attention.

Conclusion

In this article, we describe novel pathogenic compound heterozygote mutations causing PTHSL1 in two siblings. Presentations of PTHSL1 can be variable yet these siblings share reports of generalized developmental delays, intellectual disability, subtle facial dysmorphisms, hypotonia, hyporeflexia, and early onset epilepsy. Other documented features of PTHSL1 are missing in their presentation, such as breathing abnormalities. Ophthalmic abnormalities seen in our patients may widen the phenotypic spectrum of this disorder. Genetic workup is essential in identification and further studies are needed to better understand the clinical spectrum of this condition.

Author Contributions

RM substantially contributed to conception or design, contributed to acquisition, analysis, or interpretation of data, drafted the manuscript, critically revised the manuscript for important intellectual content. AK, RL and GM substantially contributed to conception or design, contributed to acquisition, analysis, or interpretation of data, critically revised the manuscript for important intellectual content. EA contributed to acquisition, analysis, or interpretation of data, critically revised the manuscript for important intellectual content, gave final approval. All the authors agree to be accountable for all aspects of the work in ensuring that questions relating to the accuracy or integrity of any part of the work are appropriately investigated and resolved.

Declaration of Conflicting Interests

The author(s) declared the following potential conflicts of interest with respect to the research, authorship, and/or publication of this article. Gayatra Mainali—Member of Data Monitoring Committee for Molybdenum Cofactor Deficiency—Origin Biosciences.

Funding

The author(s) received no financial support for the research, authorship and/or publication of this article.

Informed Consent

Not applicable, because this article does not contain any studies with human or animal subjects.

Trial Registration

Not applicable, because this article does not contain any clinical trials.

ORCID iD

Rea Mittal  <https://orcid.org/0000-0001-5083-5864>

Ethical Approval

Our institution does not require ethical approval for reporting individual cases or case series. Verbal informed consent was obtained from the patient(s) mother for their anonymized information to be published in this article.

References

1. Pitt-Hopkins-like syndrome 1 (Concept Id: C2750246). MedGen – NCBI. National Center for Biotechnology Information. <https://www.ncbi.nlm.nih.gov/medgen/413258>. Accessed February 25, 2021.
2. Orphanet: Pitt-Hopkins Like Syndrome. Orphanet encyclopedia. https://www.orpha.net/consor/cgi-bin/OC_Exp.php?lng=en&Expert=221150. Accessed February 25, 2021.
3. Poot M. Intragenic *CNTNAP2* deletions: a bridge Too Far? *Mol Syndromol*. 2017;8(3):118-130. doi:10.1159/000456021
4. Smogavec M, Cleall A, Hoyer J, et al. Eight further individuals with intellectual disability and epilepsy carrying bi-allelic *CNTNAP2* aberrations allow delineation of the mutational and phenotypic spectrum. *J Med Genet*. 2016;53(12):820-827. doi:10.1136/jmedgenet-2016-103880
5. Zweier C, de Jong EK, Zweier M, et al. *CNTNAP2* And *NRXN1* are mutated in autosomal-recessive Pitt-Hopkins-like mental retardation and determine the level of a common synaptic protein in *Drosophila*. *Am J Hum Genet*. 2009;85(5):655-666. doi:10.1016/j.ajhg.2009.10.004
6. Strauss KA, Puffenberger EG, Huentelman MJ, et al. Recessive symptomatic focal epilepsy and mutant contactin-associated protein-like 2. *N Engl J Med*. 2006;354(13):1370-1377. doi:10.1056/NEJMoa052773
7. Butterfield RJ, Foley AR, Dastgir J, et al. Position of glycine substitutions in the triple helix of COL6A1, COL6A2, and COL6A3 is correlated with severity and mode of inheritance in collagen VI myopathies. *Hum Mutat*. 2013;34(11):1558-1567. doi:10.1002/humu.22429
8. Fan Y, Liu A, Wei C, et al. Genetic and clinical findings in a Chinese cohort of patients with collagen VI-related myopathies. *Clin Genet*. 2018;93(6):1159-1171. doi:10.1111/cge.13230
9. Gregor A, Albrecht B, Bader I, et al. Expanding the clinical spectrum associated with defects in *CNTNAP2* and *NRXN1*. *BMC Med Genet*. 2011;12:106. Published 2011 Aug 9. doi:10.1186/1471-2350-12-106
10. Falsaperla R, Pappalardo XG, Romano C, et al. Intronic variant in *CNTNAP2* gene in a Boy With remarkable conduct disorder, Minor facial features, mild intellectual disability, and seizures. *Front Pediatr*. 2020;8:550. Published 2020 Sep 11. doi:10.3389/fped.2020.00550