

CASE REPORT

Trans-cervical carotid artery stenting associated with open surgical repair of carotid artery pseudoaneurysm

Tayyaub Mansoor¹  | Mohamed El Sherif² | Brian Fahy¹ | Aoife Kiernan¹ | Sean O Neill²

¹Royal College of Surgeons Ireland, Dublin, Ireland

²St James Hospital, Dublin, Ireland

Correspondence

Tayyaub Mansoor, Royal College of Surgeons Ireland, Dublin, Ireland.
Email: tayyaubmansoor@rcsi.ie

Funding information

No funding was received for this case report.

Abstract

Pseudoaneurysm post carotid artery endarterectomy is uncommon but with employment of a combined technique of trans-cervical carotid artery stenting with open repair can lead to a successful outcome.

KEYWORDS

carotid pseudoaneurysm, carotid stenting, endarterectomy, vein interposition graft

1 | INTRODUCTION

An 81-year-old lady presented with a left pulsatile neck mass 7 years after her initial carotid endarterectomy (CEA). We were able to employ a combined hybrid trans-cervical carotid stenting followed by open excision and repair for a successful outcome.

Pseudoaneurysms occur postoperatively after a carotid endarterectomy (CEA) with an incidence of 0.5%–1.5% and infection is thought to be a major cause with *Staphylococcus epidermidis* or *Staphylococcus aureus* as the most common organism implicated.¹ The risk of rupture, embolization, or compression of cranial nerves means that prompt intervention is advised. Presentation is bimodal with the majority presenting either before 2 months or after 6 months with cases reported up to 20 years postoperatively.^{2,3}

We report a case of a postoperative pseudoaneurysm 7 years after the initial CEA. Unlike previously reported cases, our case had a known occluded internal carotid artery prior to developing a pseudoaneurysm.

2 | CASE REPORT

An 81-year-old lady presented to clinic in March with a 2-month history of a pulsatile left neck mass, with associated dysphagia, and weight loss. There was mild pain with no overlying skin changes. Of note, she had a background of previous multiple strokes and of a left CEA performed in 2014 to treat a symptomatic carotid artery stenosis. She was known to have an occluded left common carotid artery extending to the circle of Willis in her CT angiogram and duplex ultrasound (US) in late 2019 when she presented with left hemispheric stroke. On examination, there was a palpable tender pulsatile mass measuring 2.5 × 3 cm. She complained of associated compressive symptoms of dysphagia that was contributing to malnutrition.

A duplex US was performed which demonstrated a vascularized mass with difficulty delineating the wall. It was decided at this point to perform a CT angiogram which demonstrated a left carotid pseudoaneurysm measuring 3.3 × 3.5 cm with patch disruption. The previously occluded left carotid system was now patent from the origin

This is an open access article under the terms of the Creative Commons Attribution-NonCommercial-NoDerivs License, which permits use and distribution in any medium, provided the original work is properly cited, the use is non-commercial and no modifications or adaptations are made.

© 2021 The Authors. *Clinical Case Reports* published by John Wiley & Sons Ltd.

of the common carotid artery to the circle of Willis, with occluded external carotid artery. The diameter of the internal carotid artery was noted to be 5 mm. her inflammatory markers were slightly elevated.

Our approach was to improve her general condition and optimize her for surgical intervention. We adopted the hybrid approach to treat this pseudoaneurysm. This was done with a trans-cervical carotid artery stenting followed simultaneously by open carotid pseudoaneurysm repair using interposition vein bypass. The patient was positioned supine with right side tilt and neck in extension in a hybrid operating theatre. A trans-cervical carotid artery stent approach was accessed initially by doing small vertical proximal carotid cutdown at the base of the neck and inserting a seven French hydrophilic sheath into the proximal left common carotid artery (CCA). The direct angiography revealed left carotid patch pseudoaneurysm with continuity of left internal carotid artery (ICA) intracranially. A bolus 5,000 intravenous unfractionated heparin was given. We placed two covered self-expandable Viabhan stents into the CCA and ICA (W. L. Gore & Associates) to temporarily seal the pseudoaneurysm. We performed negative suction while we deployed the stents using suction syringe from sheath combined with left proximal CCA clamping. The negative suction technique was used in order to facilitate retrograde flow from the ICA and reduce distal embolization during stent deployment (Figure 1). We removed the 7fr sheath with

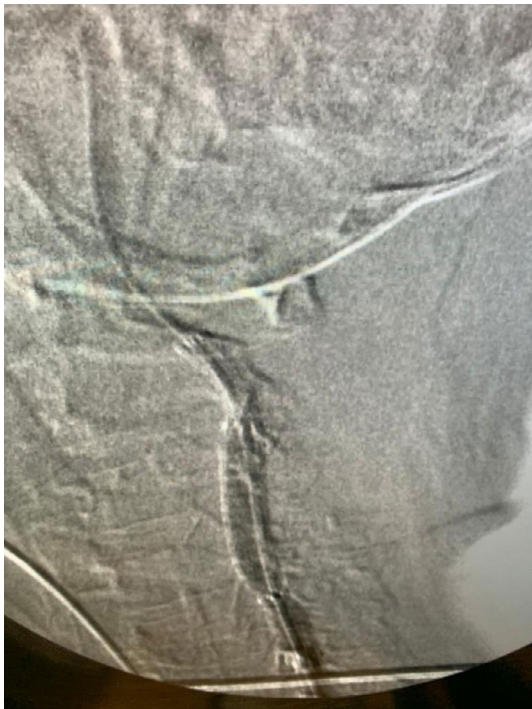


FIGURE 1 Deployment of Viabhan stent via trans-cervical approach

a purse string monofilament stitch to repair the carotid puncture site. At that time the left great saphenous vein was harvested from the right groin. We then started the open exploration of the carotid pseudoaneurysm. The initial carotid vertical incision was extended cranially as far as the mastoid process over the left carotid pseudoaneurysm. Dissection was performed carefully avoiding nerve injury. The pseudoaneurysm was exposed and revealed a disrupted Dacron graft with combined pus and blood clots noted. The bare metal stents inserted were visible at this point with no active bleeding (Figure 2). Distal ICA control was achieved (Figure 3). In our center, we routinely use the ICA stump pressure combined with retrograde ICA blood backflow to check the intracranial circulation prior to and after CCA clamping. This patient has intact right carotid arterial tree and circle of Willis with no obvious contralateral ICA stenosis. The stump pressure was 52 mmHg with good ICA blood backflow after CCA clamping. For these reasons, we decided to avoid using the carotid shunt in addition to maintaining the systolic blood pressure between (160–180 mmHg). The affected arterial segment was then excised along with the previously inserted stents with good ICA arterial backflow seen (Figures 4 and 5). In situ End-to-end anastomosis was performed between the CCA and the proximal end of the vein bypass followed by ICA anastomosis with distal end of the harvested vein (Figure 5). A sternocleidomastoid muscle flap was used to cover the interposition vein bypass as a secondary prevention of graft infection with good hemostasis. Surprisingly, there were no organisms grown in the tissue and the Dacron patch culture that was sent intraoperatively. Postoperatively, the patient recovered well and required 24 h monitoring in high dependency unit.

Dual anti-platelet was started as well as antibiotics with a plan to complete 48 h course. She continued to receive multidisciplinary input from physiotherapy, occupational therapy, and dietician to enhance recovery. A repeat CT angiogram showed a widely patent graft and left ICA (Figure 6). She had no residual symptoms or dysphagia on her 6 weeks routine follow-up course with patent interposition carotid bypass on the duplex scan.

3 | DISCUSSION

Pseudoaneurysm post carotid endarterectomy is uncommon and infection. The gold standard treatment is excision of pseudoaneurysm and infected patch with interposition vein graft repair. However, carotid artery ligation is required in up to 22.7% of cases and has an associated death or major stroke rate of 50%.⁴ A number of alternatives to saphenous vein grafts have been proposed. Fatima et al.

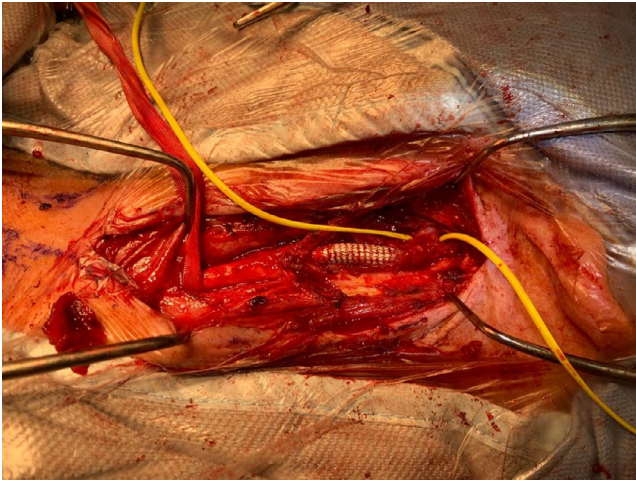


FIGURE 2 Exposed stent with Careful dissection performed until distal control is obtained

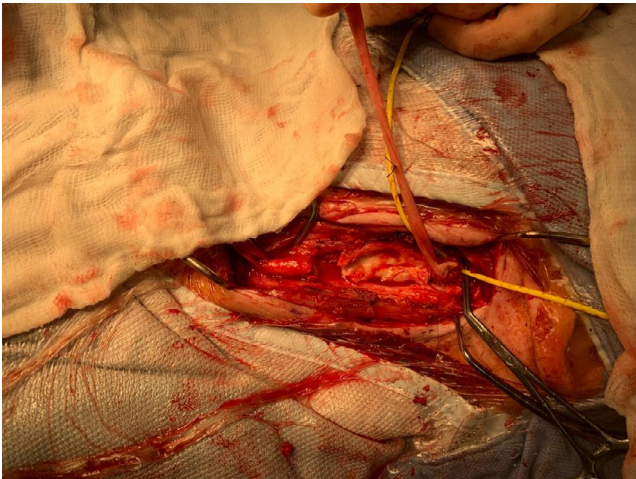


FIGURE 3 Distal and proximal control achieved of ICA with stent removed

reported an acceptable outcome with their experience with femoral vein interposition graft.⁵ They demonstrated excellent patency and good long-term survival of 82% at 5 years in their series of 24 patients treated with femoral vein interposition graft with 7% complaining of leg swelling and femoral nerve palsy that resolved in 3 months follow-up. They propose the femoral vein as an option in carotid size mismatch or in limited availability. Morasch et al report their experience with autologous superficial femoral artery and preference to use this as a conduit. In their series of six patients they reverse the arterial conduit for best size match with the carotid artery and used a Goretex interposition graft to repair the harvested segment. Although a small sample size, they reported high durability and low re-infection rates.⁶

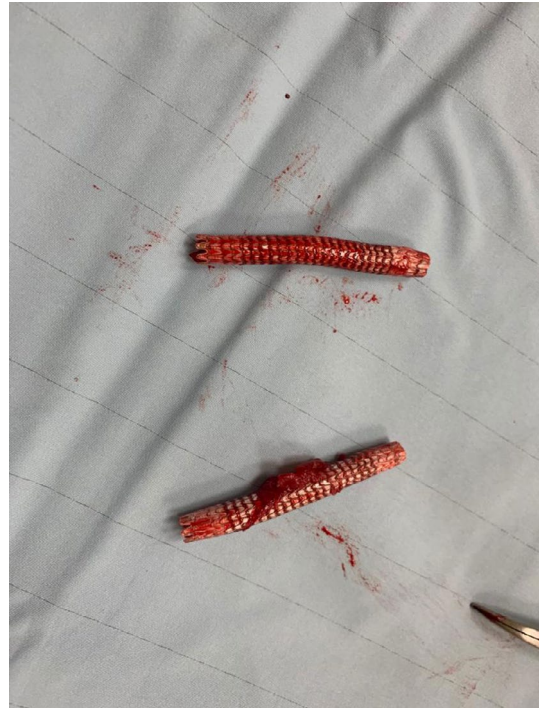

FIGURE 4 Infected pseudoaneurysm resected with debridement of infected tissue

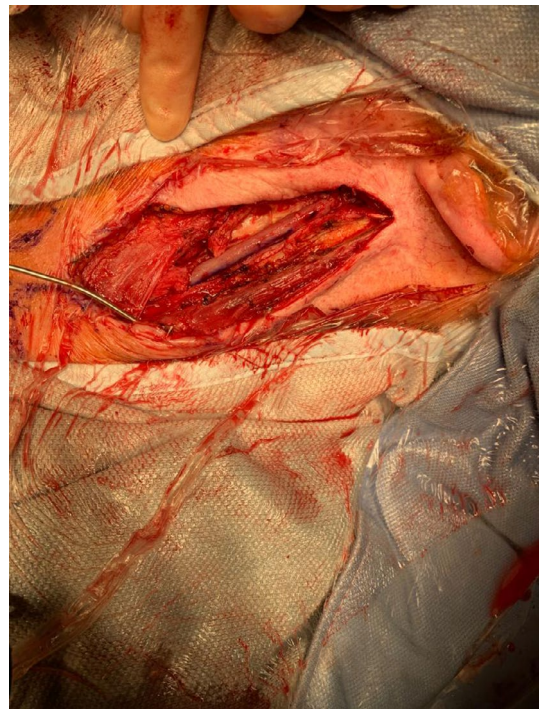


FIGURE 5 Interposition saphenous vein great performed after extraction of viabahn stents (A,B)

Endovascular stenting is an option that must be considered in the patients with high predicted peri-operative mortality. Endovascular repair has been successfully used to treat postoperative carotid artery pseudoaneurysm in

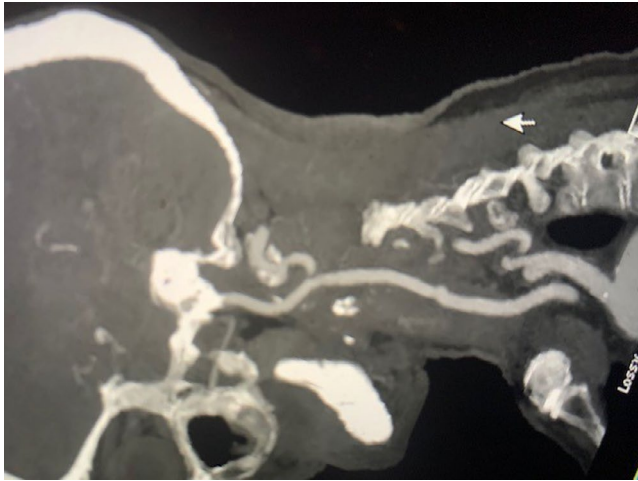


FIGURE 6 Post-operative CT angiography

the past. Marin et al have described a case of known infected pseudoaneurysm treated with good outcome with no re-infection at 1-year follow-up.^{7,8} While this will treat the immediate risk of pseudoaneurysm rupture and eliminate the risk of continued expansion, in the setting of an infected graft it is important to consider the risk of embolization and thrombosis peri-operatively and the risk of infection recurrence. A middle ground approach termed as the EndoVAC Hybrid repair has been described in detail. In this 3-stage treatment approach a stent is first deployed to treat the pseudoaneurysm. At a later point, surgical debridement is done followed by VAC therapy in combination with long-term antibiotics. In the study described by Wanhainen et al., there was no infection recurrence in their cohort of 16 patients at 5 years.⁹

In our patient, the CT scan had demonstrated that the pseudoaneurysm was very high in the neck. We had anticipated that there would be difficulty in gaining distal control and need for ligation if unsuccessful. But we felt that a completely conservative approach or endovascular approach may not be the best given her relatively good activity of daily living. We also wanted to avoid ligating the carotid artery as it measured 5 mm on CT scan and would be associated with high risk of neurological deficit. After our vascular MDT discussion, we considered an endovascular balloon to gain control but eventually agreed that a stent placement will provide more durability and leave the artery patent during dissection. After stent placement, when we had dissected down to the carotid artery the bare metal stent was fully visible. We were then able to perform dissection taking care to avoid nerve injury and safely get distal control. To our knowledge, there is no reported case describing a trans-cervical stent assisted carotid pseudoaneurysm repair.

Interestingly, our patient had a recently diagnosed occluded left carotid artery on a CT scan as of September 2019. Her initial presentation with a pulsatile mass neck in clinic was very unusual but given her history of CEA we had considered pseudoaneurysm as likely. The pathophysiology is likely inflammation secondary to infection causing the vessel to re-canalize and evolve into a pseudoaneurysm. To our knowledge, there have been no case reports describing a previously occluded CEA site re-canalizing and developing into a pseudoaneurysm.

ACKNOWLEDGEMENTS

I would like to acknowledge of St. James Hospital staff for all their hard work. Written patient consent was obtained prior to writing and submitting this article.

CONFLICT OF INTEREST

We report no conflict of interest.

AUTHOR CONTRIBUTIONS

TM: Conceptualisation, methodology, writing, revision, interpretation of data, analysis, MES: Conceptualisation, methodology, Analysis, interpretation of data, writing, revision, supervision, BF and AK: Review, revision, SON: Supervision, revision.

DATA AVAILABILITY STATEMENT

Data sharing not applicable to this article as no datasets were generated or analysed during the current study.

ORCID

Tayyab Mansoor  <https://orcid.org/0000-0001-9375-6314>

REFERENCES

1. Azouz V, Fahmy JN, Kornbau C, Petrinc D. Recurrent pseudoaneurysm after carotid endarterectomy. *J Vasc Surg Cases Innov Tech*. 2019;5(2):128-131.
2. Abdelhamid MF, Wall ML, Vohra RK. Carotid artery pseudoaneurysm after carotid endarterectomy: case series and a review of the literature. *Vasc Endovascular Surg*. 2009;43(6):571-577.
3. Naylor R. Management of prosthetic patch infection after CEA. *J Cardiovasc Surg*. 2016;57(2):137-144.
4. El-Sabroun R, Reul G, Cooley DA. Infected postcarotid endarterectomy pseudoaneurysms: retrospective review of a series. *Ann Vasc Surg*. 2000;14(3):239-247.
5. Fatima J, Federico VP, Scali ST, et al. Management of patch infections after carotid endarterectomy and utility of femoral vein interposition bypass graft. *J Vasc Surg*. 2019;69(6):1815-1823.
6. Naughton PA, Garcia-Toca M, Rodriguez HE, Pearce WH, Eskandari MK, Morasch MD. Carotid artery reconstruction for infected carotid patches. *Eur J Vasc Endovasc Surg*. 2010;40(4):492-498.

7. Lin PH, Bush RL, Lumsden AB. Successful stent-graft exclusion of a bovine patch-related carotid artery pseudoaneurysm. *J Vasc Surg*. 2003;38(2):396.
8. Hellmich B, Agueda A, Monti S, et al. 2018 update of the EULAR recommendations for the management of large vessel vasculitis. *Ann Rheum Dis*. 2020;79(1):19-30.
9. Thorbjørnsen K, Djavani Gidlund K, Björck M, Kragsterman B, Wanhainen A. Editor's choice - long-term outcome after EndoVAC hybrid repair of infected vascular reconstructions. *Eur J Vasc Endovasc Surg*. 2016;63(6):1665.

How to cite this article: Mansoor T, El Sherif M, Fahy B, Kiernan A, O Neill S. Trans-cervical carotid artery stenting associated with open surgical repair of carotid artery pseudoaneurysm. *Clin Case Rep*. 2021;9:e04944. <https://doi.org/10.1002/ccr3.4944>