

Mycobacterium marinum Infection After Exposure to Coal Mine Water

Moises A. Huaman,¹ Julie A. Ribes,^{1,2} Kristine M. Lohr,³ and Martin E. Evans¹

¹Divisions of Infectious Diseases, ²Department of Pathology and Laboratory Medicine, Clinical Microbiology Laboratory, ³Division of Rheumatology, University of Kentucky College of Medicine, Lexington

Mycobacterium marinum infection has been historically associated with exposure to aquariums, swimming pools, fish, or other marine fauna. We present a case of *M. marinum* left wrist tenosynovitis and elbow bursitis associated with a puncture injury and exposure to coal mine water in Illinois.

Keywords. coal mines; *Mycobacterium marinum*; water exposure.

CASE REPORT

A 55-year-old man with no prior medical problems presented for evaluation of chronic left wrist tenosynovitis and elbow bursitis. The patient had suffered a puncture injury of his left index finger with a metallic wire in a coal mine 18 months prior. Over a several month course, he developed progressive erythema and edema of his left index and middle fingers. He received steroid injections, surgical debridements, and short courses of empiric doxycycline and trimethoprim-sulfamethoxazole with partial improvement. Six months before presentation to our institution, the patient developed skin nodules ascending up his left ring finger, wrist, forearm, and elbow. A magnetic resonance imaging showed wrist extensor tenosynovitis. The patient underwent debridement of wrist extensor tendons and excisional biopsy of forearm and elbow nodules. Histopathology showed granulomatous inflammation. However, routine bacterial, fungal, and mycobacterial stains and cultures were negative.

On examination, nonpainful swelling of the patient's left wrist and elbow at prior surgical sites was noted (Figure 1A). Radiographs showed no bone abnormalities. A QuantiFERON-TB Gold test (QFT) was positive at 2.20 IU/L. Human

immunodeficiency virus enzyme-linked immunosorbent assay was negative. A chest radiograph was normal. A specimen obtained via wrist aspiration was incubated at 30°C showing mycobacterial growth at 3 weeks and pigment production after exposure to light (Figure 1B). Culture identification subsequently confirmed *Mycobacterium marinum*. The patient received repeat surgical debridement and was treated with 4 months of clarithromycin, ethambutol, and rifampin therapy, followed by an additional 5 months of clarithromycin and ethambutol. Good clinical response was noted after 4 months of surgical debridement and antibiotic therapy (Figure 1C).

Mycobacterium marinum cutaneous infection often follows contact with fresh or salt water in the setting of minor or even unnoticed skin trauma that allows inoculation of mycobacteria into the skin and superficial soft tissue layers, or more rarely within deeper structures such as tendons or bone. Thus, *M. marinum* has been traditionally associated with exposure to aquariums, swimming pools, or occupational and recreational injuries with fish or other marine fauna. However, this patient was most likely inoculated during traumatic injury in coal mines. On further questioning, the patient reported working as a pumper in the mines, and thus he had significant exposure to coal mine water. Furthermore, he denied any of the classic exposures associated with *M. marinum* infection. A review of 193 cases of cutaneous *M. marinum* infection reported in the literature between 1962 and 1996 revealed that only 1 case had been associated with skin injury in a coal mine [1]. Skin lesions caused by *M. marinum* are typically small nodules or ulcerations and commonly affect 1 upper extremity. Multiple skin lesions can occur and may follow an ascending sporothricoid distribution. Deep soft tissue infections such as tenosynovitis, arthritis, and osteomyelitis are less common [2]. Disseminated disease has been described in immunosuppressed patients [3].

QuantiFERON-TB Gold test measures the production of interferon- γ after challenge with 3 mycobacterial proteins: ESAT-6, CFP-10, and TB7.7. These proteins are not present in *Bacillus Calmette-Guerin* strains or most nontuberculous mycobacteria except *Mycobacterium kansasii*, *Mycobacterium szulgai*, and *M. marinum* [4]. Therefore, the positive QFT result in this patient was most likely related to *M. marinum* rather than *Mycobacterium tuberculosis* infection. Although the patient did have the risk factor for *M. tuberculosis* infection of working in coal mines, his chest radiograph did not show evidence of active pulmonary disease, and the patient reported no prior *M. tuberculosis* exposure. In addition, the patient had no evidence of pneumoconiosis or silicosis as an underlying risk factor for *M. tuberculosis* infection seen in coal miners. Because latent tuberculosis infection (LTBI) could not be excluded, the

Received 20 October 2015; accepted 15 December 2015.

Correspondence: M. A. Huaman, Division of Infectious Diseases, University of Kentucky College of Medicine, 740 South Limestone, K512, Lexington, KY 40536 (moises.huaman@uky.edu).

Open Forum Infectious Diseases®

© The Author 2015. Published by Oxford University Press on behalf of the Infectious Diseases Society of America. This is an Open Access article distributed under the terms of the Creative Commons Attribution-NonCommercial-NoDerivs licence (<http://creativecommons.org/licenses/by-nc-nd/4.0/>), which permits non-commercial reproduction and distribution of the work, in any medium, provided the original work is not altered or transformed in any way, and that the work is properly cited. For commercial re-use, please contact journals.permissions@oup.com. DOI: 10.1093/ofid/ofv205

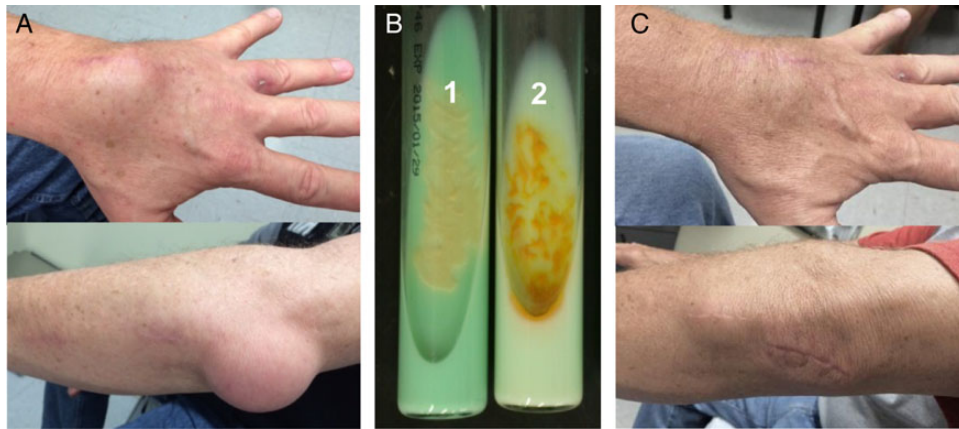


Figure 1. (A) Left wrist and elbow swelling due to *Mycobacterium marinum* infection. (B) Two tubes of Lowenstein Jensen medium were inoculated with the isolate and were grown in the dark. One of the tubes (tube 2) was unwrapped and exposed to direct light for 1 hour. Both tubes were reincubated for 24 hours and then assessed for pigment production. (C) The panel shows left wrist and elbow after surgical debridement and 4 months of antibiotic therapy for *M marinum*.

patient received 4 months of rifampin as part of *M marinum*/LTBI antibiotic regimen.

We show an association between exposure to coal mine water and acquisition of *M marinum* infection. To our knowledge, this is the second case of culture-confirmed *M marinum* infection associated with coal mine water exposure reported in the literature. The prior case described an *M marinum* cutaneous infection in a coal miner in Moravia, Czech Republic associated with the presence of *M marinum* in mine water [5]. Other cases of cutaneous lesions resembling *M marinum* infection were reported in Czech Republic miners, but bacteriologic confirmation was never obtained [6].

CONCLUSIONS

Exposure to coal mine water appears to be an underrecognized risk factor for developing *M marinum* infection. Studies are needed to explore this observation.

Acknowledgments

Potential conflicts of interest. All authors: No reported conflicts. All authors have submitted the ICMJE Form for Disclosure of Potential Conflicts of Interest.

References

1. Jernigan JA, Farr BM. Incubation period and sources of exposure for cutaneous *Mycobacterium marinum* infection: case report and review of the literature. *Clin Infect Dis* **2000**; 31:439–43.
2. Aubry A, Chosidow O, Caumes E, et al. Sixty-three cases of *Mycobacterium marinum* infection: clinical features, treatment, and antibiotic susceptibility of causative isolates. *Arch Intern Med* **2002**; 162:1746–52.
3. Ekerot L, Jacobsson L, Forsgren A. *Mycobacterium marinum* wrist arthritis: local and systematic dissemination caused by concomitant immunosuppressive therapy. *Scand J Infect Dis* **1998**; 30:84–7.
4. Cellestis. QuantiFERON-TB Gold (In-Tube Method) [package insert]. Victoria, Australia: **2006**.
5. Horacek J, Ulicna L. [*Mycobacterium balnei* in the water of mines as a causal agent of the verrucous tuberculosis of the skin. (Case report)]. *Cesk Dermatol* **1973**; 48:97–9.
6. Slosarek M, Kubin M, Pokorny J. Water as a possible factor of transmission in mycobacterial infections. *Cent Eur J Public Health* **1994**; 2:103–5.