



# Preoperative Assessment of Renal Sinus Invasion by Renal Cell Carcinoma according to Tumor Complexity and Imaging Features in Patients Undergoing Radical Nephrectomy

Ji Hoon Kim, Kye Jin Park, Mi-Hyun Kim, Jeong Kon Kim

All authors: Department of Radiology and Research Institute of Radiology, University of Ulsan College of Medicine, Asan Medical Center, Seoul, Korea

**Objective:** To identify the association between renal tumor complexity and pathologic renal sinus invasion (RSI) and evaluate the usefulness of computed tomography tumor features for predicting RSI in patients with renal cell carcinoma (RCC).

**Materials and Methods:** This retrospective study included 276 consecutive patients who underwent radical nephrectomy for RCC with a size of  $\leq 7$  cm between January 2014 and October 2017. Tumor complexity and anatomical renal sinus involvement were evaluated using two standardized scoring systems: the radius (R), exophytic or endophytic (E), nearness to collecting system or sinus (N), anterior or posterior (A), and location relative to polar lines (RENAL) nephrometry and preoperative aspects and dimensions used for anatomical classification (PADUA) system. CT-based tumor features, including shape, enhancement pattern, margin at the interface of the renal sinus (smooth vs. non-smooth), and finger-like projection of the mass, were also assessed by two independent radiologists. Univariable and multivariable logistic regression analyses were performed to identify significant predictors of RSI. The positive predictive value, negative predictive value (NPV), accuracy of anatomical renal sinus involvement, and tumor features were evaluated.

**Results:** Eighty-one of 276 patients (29.3%) demonstrated RSI. Among highly complex tumors (RENAL or PADUA score  $\geq 10$ ), the frequencies of RSI were 42.4% (39/92) and 38.0% (71/187) using RENAL and PADUA scores, respectively. Multivariable analysis showed that a non-smooth margin and the presence of a finger-like projection were significant predictors of RSI. Anatomical renal sinus involvement showed high NPVs (91.7% and 95.2%) but low accuracy (40.2% and 43.1%) for RSI, whereas the presence of a non-smooth margin or finger-like projection demonstrated comparably high NPVs (90.0% and 91.3% for both readers) and improved accuracy (67.0% and 73.9%, respectively).

**Conclusion:** A non-smooth margin or the presence of a finger-like projection can be used as a preoperative CT-based tumor feature for predicting RSI in patients with RCC.

**Keywords:** Renal cell carcinoma; Renal sinus invasion; Staging; Upstaging

## INTRODUCTION

Renal sinus invasion (RSI) is a principal route for the extrarenal extension of renal cell carcinoma (RCC) [1-3] and has prognostic significance for poor recurrence-free survival and overall survival after nephrectomy [4-6]. Furthermore,

RSI may have a worse prognosis than perinephric fat invasion, which is one of the pathologic features of the pT3a-stage disease [6]. In this regard, the preoperative evaluation of RSI is of interest for choosing between radical nephrectomy (RN) and nephron-sparing surgery and predicting prognosis after surgery [3,7].

**Received:** June 1, 2020 **Revised:** February 4, 2021 **Accepted:** February 22, 2021

**Corresponding author:** Kye Jin Park, MD, PhD, Department of Radiology and Research Institute of Radiology, University of Ulsan College of Medicine, Asan Medical Center, 88 Olympic-ro 43-gil, Songpa-gu, Seoul 05505, Korea.

• E-mail: kyejin629@gmail.com

This is an Open Access article distributed under the terms of the Creative Commons Attribution Non-Commercial License (<https://creativecommons.org/licenses/by-nc/4.0>) which permits unrestricted non-commercial use, distribution, and reproduction in any medium, provided the original work is properly cited.

Recent technical improvements have led to broader indications for nephron-sparing surgery in patients with RCC, even highly complex tumors and large tumors [8]. Because of its remarkable advantages for lowering the risk of chronic kidney disease (CKD) and cardiovascular disease while providing equivalent oncological outcomes to RN [9–11], partial nephrectomy (PN) is currently the standard treatment for patients with T1a tumors ( $\leq 4$  cm) [12,13] and the preferred option for T1b tumors ( $\leq 7$  cm) when technically feasible [14]. The choice between PN and RN is primarily made by considering multiple factors, including the expected volume of the remaining renal parenchyma, contralateral kidney function, anatomical tumor factors, and clinical staging [13]. In this regard, multi-phase contrast-enhanced computed tomography (CT) plays an important role in the detection, staging, and evaluation of anatomical anomalies of tumors.

High tumor complexity is associated with higher upstaging rates from clinical T1 to pathological T3a after PN, as well as higher perioperative complications [15,16]. Two nephrometry systems are commonly used to evaluate tumor complexity: the radius (R), exophytic/endophytic (E), nearness to collecting system or sinus (N), anterior or posterior (A), and location relative to polar lines (RENAL) nephrometry system, and the preoperative aspects and dimensions for anatomical classification (PADUA) system [17,18]. These two systems gather information about the relationship between the tumor and renal sinus, using the 'N component' for the RENAL score and 'renal sinus involvement' for the PADUA classification. However, the determination of RSI based on these systems may not be sufficient, because anatomical renal sinus involvement presenting with tumors bulging into the renal sinus does not necessarily indicate RSI [19], and it may lead to more PN-eligible patients undergoing RN.

Several tumor features have been suggested as significant predictors of RSI, and they include tumor size, necrosis, tumor extension into the sinus (direct contact with or bulging into the renal sinus), and irregular margins or shapes [5,20–24]. The diagnostic accuracy of the clinical staging of RCC has been reported to be 64.5–75.5% [25,26], with rates of 8–12% for the upstaging of cT1 to pT3a after PN [27,28]. Clinical staging is one of the important factors for choosing between PN and RN, and it can impact perioperative surgical outcomes such as positive resection margin [28], and accurate clinical staging of RCC is crucial. However, to the best of our knowledge, no studies have

investigated the association between tumor complexity and RSI, and only limited and small population-based studies have reported on the usefulness of CT-based tumor features for predicting RSI by RCC [5,20,21,29].

Therefore, the purpose of this study was to identify associations between renal tumor complexity and RSI for RCC  $\leq 7$  cm using the RENAL nephrectomy score and the PADUA classification [17,18]. In addition, we aimed to identify useful CT-based tumor features for predicting RSI in patients with RCC  $\leq 7$  cm.

## MATERIALS AND METHODS

### Patient Selection

Our Institutional Review Board approved this study and waived the requirement for written informed consent because of its retrospective nature (IRB No. 2017-1134). The records of our institution were retrospectively searched to identify patients who underwent RN for RCC with a tumor size of 7 cm or less between January 2014 and October 2017. The exclusion criteria were a tumor larger than 7 cm (beyond cT2 stage), presence of nodal or distant metastasis, renal vein thrombosis, incomplete CT protocols (lack of coronal reconstructed images or enhanced images), and recurrent RCC. Among 648 patients who underwent RN for RCC, 276 (mean age, 57.7 years; range, 29–80 years) were included in this study after the exclusion of 372 patients for the following reasons: tumor size of  $> 7$  cm ( $n = 260$ ), N1 or M1 disease ( $n = 14$ ), renal vein thrombosis ( $n = 24$ ), incomplete CT protocol ( $n = 72$ ), and nephrectomy for recurrent RCC ( $n = 2$ ) (Fig. 1).

Clinical and histopathologic data including age, sex, histologic subtype, Fuhrman or International Society of Urological Pathology category, and presence of pathologic RSI were recorded. Pathologic stages were determined using RN specimens according to the 2017 American Joint Committee on Cancer (AJCC) 8th classification [30] by the consensus of two pathologists who specialized in urological pathology. The details of the histopathological examinations and CT image acquisition are summarized in the Supplementary.

### Image Analysis for Tumor Complexity and Imaging Features

The RENAL scoring system and PADUA classification were used to evaluate the tumor complexity. These have been proposed as reproducible tools for determining the

anatomical complexity of tumors [17,18]. Based on the established criteria, including tumor size and anatomical information, renal masses were classified as low (4–6 for RENAL and 6–7 for PADUA), intermediate (7–9 for RENAL and 8–9 for PADUA), and high (10–12 for RENAL and 10–14 for PADUA) complexity masses, as previously suggested. Among the components, the proximity of the tumor to the collecting system or sinus ('N' component,  $\geq 7$  mm;  $> 4$  but  $< 7$  mm; or  $\leq 4$  mm) for the RENAL score, and renal sinus involvement (involved or not) for the PADUA classification were evaluated as markers of the relationship between the tumor and renal sinus fat for anatomical renal sinus invasion.

To evaluate their potential for predicting RSI, the following tumor features of each RCC were recorded: 1) enhancement pattern (homogeneous vs. heterogeneous), 2) shape (round vs. lobulated), 3) margin at the interface of the tumor and renal sinus fat (non-contact with renal sinus fat or smooth

margin vs. non-smooth margin); 4) sign of a finger-like projection (Fig. 2). Tumors with a nodular appearance and a smooth contour or those covered with a pseudocapsule were categorized as having a smooth margin, whereas those showing an irregular margin or budding appearance at the interface of the tumor and renal sinus fat in the axial and coronal images were categorized as a non-smooth margin. A finger-like projection was defined as a renal mass showing a focal "finger-like" invasion of the renal sinus fat. All images were independently evaluated by two radiologists (with 8 and 3 years of experience in interpreting cross-sectional imaging) who were blinded to the histopathologic results or clinical outcomes. Any discrepancies between the interpretations of the two readers were resolved at a consensus meeting, and consensus data were used for the univariable and multivariable analyses.

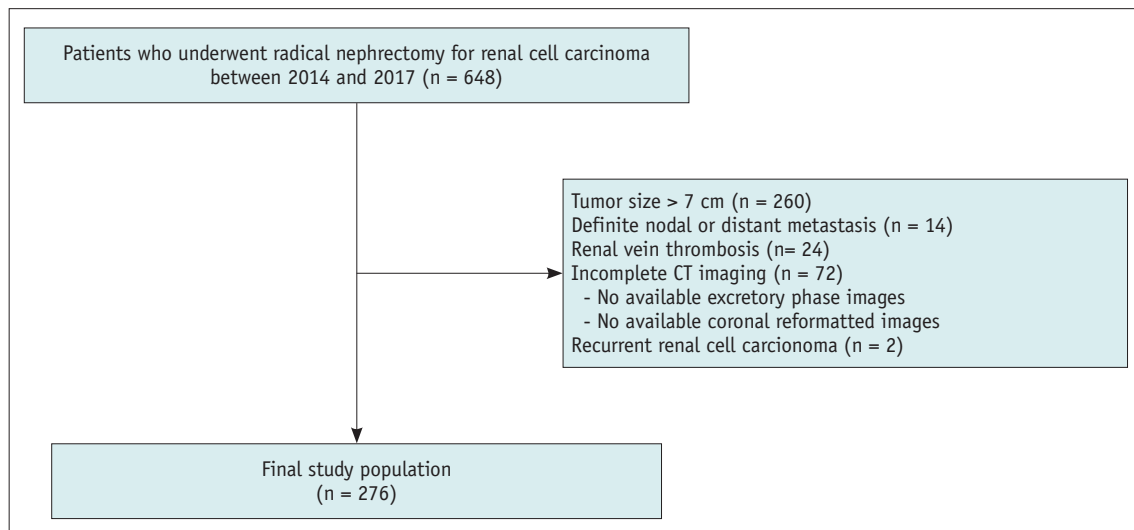


Fig. 1. Flow diagram for patient recruitment.

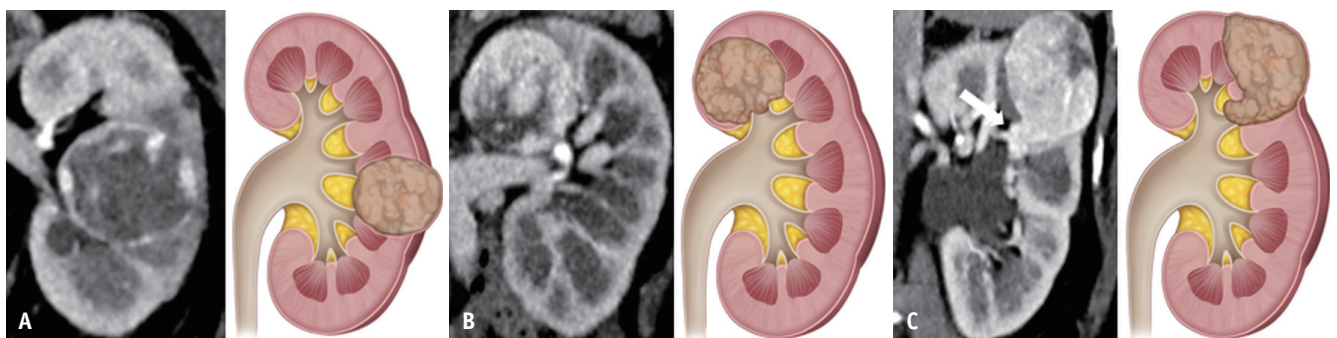


Fig. 2. Representative examples and graphical illustrations of tumor features of RCC. Coronal CT scans and graphical illustrations demonstrating the margin characteristics of RCC.

**A.** Smooth margin. The renal mass demonstrates a well-defined border completely covered by a pseudocapsule. **B.** Non-smooth margins. The renal mass shows a lobulated and disrupted pseudocapsule at the interface of the renal mass and renal sinus fat. **C.** Finger-like projections. The renal mass shows a focal "finger-like" protrusion (arrow) into the renal sinus fat. RCC = renal cell carcinoma

### Statistical Analysis

Comparisons between RCC patients with or without the presence of RSI were evaluated using chi-squared and Fisher's exact tests for categorical variables and *t* tests or Mann-Whitney U tests for continuous variables. Associations between renal complexity and the frequency of RSI were evaluated using the Cochran-Armitage test for trends.

Univariable and multivariable (to adjust for the tumor features and anatomical factors of the 'N' component of the RENAL score or 'renal sinus involvement' of the PADUA classification) logistic regression analyses were performed to identify the variables associated with RSI. Variables with  $p < 0.05$  in the univariable logistic regression analysis were entered into the multivariable logistic regression analysis while considering multicollinearity.

The sensitivity, specificity, positive predictive value (PPV), negative predictive value (NPV), and accuracy of significant

imaging findings were calculated. The inter-reader agreement for the tumor features was evaluated using Gwet's AC1, which is a more stable inter-rater reliability coefficient than Cohen's  $\kappa$  analysis [31], and the AC1 values were interpreted as follows: 0.00–0.20, poor; 0.21–0.40, fair; 0.41–0.60, moderate; 0.61–0.80, good; and 0.81–1.00, excellent. Statistical significance was set at  $p < 0.05$ . The statistical analyses were conducted using SPSS version 22 (IBM Corp.) and MedCalc Statistical Software version 19.2 (MedCalc Software Ltd).

## RESULTS

### Patient Characteristics

Of the 276 included patients, 81 (29.3%) had RSI. The baseline characteristics of the patients with and without RSI are summarized in Table 1.

**Table 1. Characteristics of the 276 Patients Included in the Study**

	RSI Absent (n = 195)	RSI Present (n = 81)	P
Mean age, years*	56.4 ± 11.5	60.7 ± 10.7	0.004
Sex			0.883
Male	127 (65.1)	52 (64.2)	
Female	68 (34.9)	29 (35.8)	
Mean lesion size, cm*	4.76 ± 1.53	5.42 ± 1.53	0.001
Histologic subtype			0.006
Clear cell	156 (80.0)	75 (92.6)	
Non-clear cell	39 (20.0)	6 (7.4)	
Fuhrman or ISUP grade			0.003
1 or 2	132 (67.7)	40 (49.4)	
3 or 4	63 (32.3)	41 (50.6)	
Tumor complexity			
Mean RENAL score*	8.34 ± 1.66	9.32 ± 1.23	< 0.001
Mean PADUA score*	9.71 ± 1.70	10.82 ± 1.15	< 0.001
Imaging features by consensus reading			
Enhancement pattern			0.018
Homogeneous	22 (11.3)	2 (2.5)	
Heterogeneous	173 (88.7)	79 (97.5)	
Shape			< 0.001
Round	93 (47.7)	17 (21.0)	
Lobulated	102 (52.3)	64 (79.0)	
Margin			< 0.001
No contact or smooth	131 (67.2)	16 (19.8)	
Non-smooth	64 (32.8)	65 (80.2)	
Finger-like projection			< 0.001
No	176 (90.3)	53 (65.4)	
Yes	19 (9.7)	28 (34.6)	

\*Data are presented as mean ± standard deviation. Otherwise, the data are number of patients with the percentage in the parentheses. ISUP = International Society of Urological Pathology, PADUA = preoperative aspects and dimensions used for an anatomical classification, RENAL = radius, exophytic or endophytic, nearness to collecting system or sinus, anterior or posterior, and location relative to polar lines, RSI = renal sinus invasion

**Tumor Complexity and CT Imaging Features for Predicting RSI**

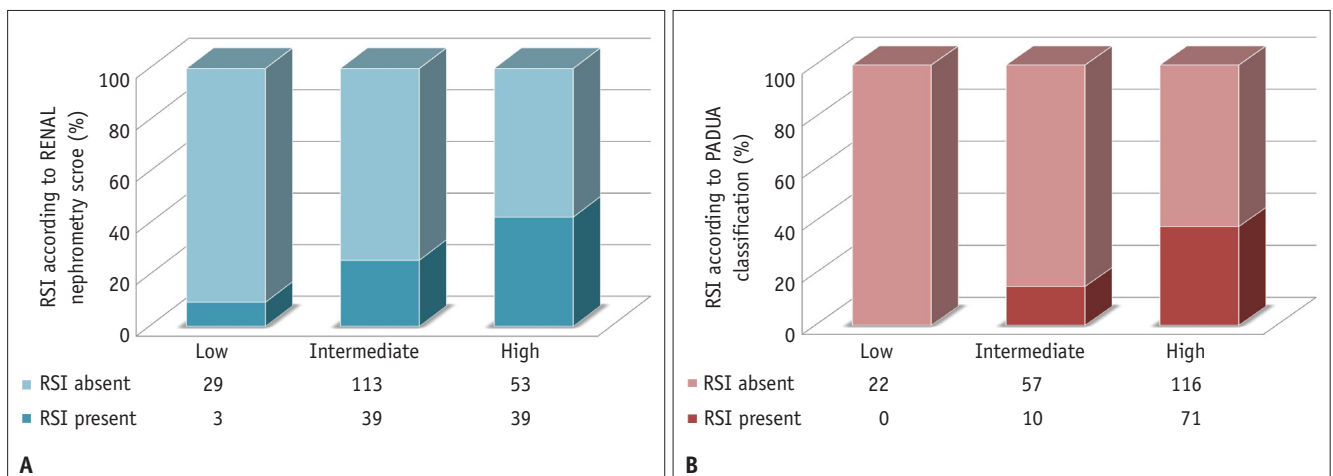
Tumors were classified into low (n = 32), intermediate (n = 152), and high (n = 92) complexity according to RENAL nephrometry, and low (n = 22), intermediate (n = 67), and high (n = 187) complexity according to the PADUA classification. As the complexity grade increased, the frequency of RSI also increased, with RSI rates of 9.4% (3/32), 25.7% (39/152), and 42.4% (39/92) (Fig. 3A) for the low, intermediate, and high RENAL scores ( $p < 0.001$ ) and 0.0% (0/22), 14.9% (10/67), and 38.0% (71/187) for the PADUA classification, respectively ( $p < 0.001$ ) (Fig. 3B). Regarding tumor features, heterogeneous enhancement (97.5% [79/81] vs. 88.7% [173/195];  $p = 0.018$ ), a lobulated shape (79.0% [64/81] vs. 52.3% [102/195];  $p < 0.001$ ), non-smooth margins (80.2% [65/81] vs. 32.8% [64/195];  $p < 0.001$ ), and finger-like projections (34.6% [28/81] vs. 9.7% [19/195];  $p < 0.001$ ) were significantly associated with RSI (Table 1).

Univariable analysis revealed that tumor size (odds ratio [OR] = 1.33,  $p = 0.002$ ), tumor near the renal sinus fat or collecting system  $\leq 4$  mm (OR = 5.30,  $p = 0.007$ ) according to the RENAL nephrometry score, tumors with renal sinus involvement (OR = 10.19,  $p = 0.002$ ) according to the PADUA classification, heterogeneous enhancement (OR = 5.02;  $p = 0.032$ ), lobulated shape (OR = 3.43;  $p < 0.001$ ), non-smooth margin (OR = 8.51;  $p < 0.001$ ), and a finger-like projection (OR = 4.89;  $p < 0.001$ ) were associated with pathologic RSI (Table 2). When variables of tumor size, anatomical renal sinus involvement, margin, and finger-like projection were entered into the multivariable analysis, a

non-smooth margin (adjusted OR = 5.55 or 5.88;  $p < 0.001$ ) and a finger-like projection (adjusted OR = 2.49 or 2.62,  $p < 0.012$ ) were significant independent predictors of RSI.

The sensitivity, specificity, PPV, NPV, and accuracy for predicting RSI are summarized in Table 3. When anatomical features between the tumor and renal sinus were evaluated using the 'N' component of the RENAL score or 'renal sinus involvement' of the PADUA classification, the NPVs were 91.7% (33/36) and 95.2% (40/42), respectively, while the accuracies were 40.2% (111/276) and 43.1% (119/276), respectively. For both readers, tumors with a non-smooth margin or finger-like projection showed lower NPVs (non-smooth margin; 89.0% [145/163] for reader 1 and 86.3% [120/139] for reader 2 and finger-like projection; 77.7% [174/224] for reader 1 and 75.0% [165/220] for reader 2) but higher accuracies (65.9–75.4% for both readers) than those with anatomical renal sinus involvement based on the 'N' component of the RENAL score or 'renal sinus involvement' of the PADUA classification. The presence of a non-smooth margin or a finger-like projection demonstrated comparable NPVs (91.3% [136/149] for reader 1 and 90.0% [117/130] for reader 2) and a higher accuracy (73.9% [204/276] for reader 1 and 67.0% [185/276] for reader 2) than anatomical renal sinus involvement.

The Gwet's AC1 values, which represent inter-reader agreements, are presented in Table 4. Inter-reader agreements were moderate for shape (AC1, 0.59; 95% CI, 0.50–0.69) and margin (AC1, 0.60; 95% CI, 0.50–0.69), substantial for the presence of finger-like projections (AC1, 0.78; 95% CI, 0.71–0.85), and good for the enhancement pattern (AC1, 0.91; 95% CI, 0.87–0.95).



**Fig. 3. Frequency of RSI according to tumor complexity using the RENAL nephrometry score (A) and PADUA classification (B).** PADUA = preoperative aspects and dimensions used for anatomical classification, RENAL = radius, exophytic or endophytic, nearness to collecting system or sinus, anterior or posterior, and location relative to polar lines, RSI = renal sinus invasion

**Table 2. Univariable and Multivariable Analysis for Evaluation of Renal Sinus Invasion in Renal Cell Carcinoma Using Consensus Reading Data**

	Univariable Analysis			Multivariable Analysis (RENAL) <sup>†</sup>			Multivariable Analysis (PADUA) <sup>‡</sup>		
	OR	95% CI	P	Adjusted OR	95% CI	P	Adjusted OR	95% CI	P
Tumor size	1.33	1.11–1.59	0.002	1.15	0.94–1.41	0.165	1.13	0.93–1.39	0.224
Nearness to the renal sinus fat or collecting system ≤ 4 mm (RENAL)	5.30	1.58–17.80	0.007*	2.06	0.54–7.79	0.288	-	-	-
Renal sinus involvement (PADUA)	10.19	2.40–43.27	0.002*	-	-	-	3.48	0.77–15.80	0.106
Heterogeneous enhancement <sup>‡</sup>	5.02	1.15–21.89	0.032*						
Lobulated shape <sup>‡</sup>	3.43	1.88–6.28	< 0.001*						
Non-smooth margin	8.51	4.56–15.89	< 0.001*	5.88	3.04–11.39	< 0.001*	5.55	2.87–10.74	< 0.001*
Finger-like projection	4.89	2.53–9.46	< 0.001*	2.62	1.28–5.35	0.008*	2.49	1.22–5.09	0.012*

\*Statistically significant, <sup>†</sup>Because both the nearness to the renal sinus fat or collecting system of RENAL nephrometry and renal sinus involvement of PADUA classification represent the anatomical relationship of the mass and renal sinus fat, two multivariable analyses using either feature were performed, <sup>‡</sup>Because of the collinearity of heterogeneous enhancement and lobulated shape with a non-smooth margin or a finger-like projection, two variables were not included for multivariable analyses. CI = confidence interval, OR = odds ratio, PADUA = preoperative aspects and dimensions used for an anatomical classification, RENAL = radius, exophytic or endophytic, nearness to collecting system or sinus, anterior or posterior, and location relative to polar lines

## DISCUSSION

In patients with RCC ≤ 7 cm, the preoperative prediction of RSI is of interest for stratifying patients into cT1 and cT3a stages to choose between nephron-sparing surgery or another option and achieve better perioperative oncological outcomes. In this study, we demonstrated that the frequency of RSI increased as the anatomical complexity score increased. In highly complex tumors, the observed frequencies of RSI were 42.4% using the RENAL score and 38.0% using the PADUA classification. Concerning the imaging features, multivariable analysis showed that a non-smooth margin and a finger-like projection were significant predictors of RSI. When evaluated according to anatomical involvement of the renal sinus using the nearness to the renal sinus or collecting system for the RENAL score or renal sinus involvement for the PADUA classification, the NPVs were high (91.7% and 95.2%, respectively) but the PPV and accuracy were low (PPVs, 32.5% and 33.8%; accuracies, 40.2% and 43.1%, respectively). By comparison, the presence of a non-smooth margin or finger-like projection demonstrated comparably high NPVs (91.3% for reader 1 and 90.0% for reader 2), higher PPVs (53.5% for reader 1 and 46.6% for reader 2), and accuracy (73.9% for reader 1 and 67.0% for reader 2). The inter-reader agreements for a non-smooth margin and finger-like projection were moderate to substantial (AC1 = 0.60, non-smooth margin, and 0.78 for a finger-like projection, respectively). Our findings may provide valuable information for determining the clinical stage and surgical techniques in patients with RCC.

Owing to recent improvements in surgical techniques, the role of nephron-sparing surgery has been extended to facilitate better postoperative renal function and a lower likelihood of CKD [8,14]. Tumors with sizes of ≤ 4 cm, as well as those with sizes of 4–7 cm (T1b), are increasingly regarded as candidates for nephron-sparing surgery. In this regard, the role of clinical staging is important, especially considering the upstaging rates from clinical T1 to pathologic T3a and the potential positive resection margin after surgery [15,27,28,32,33]. In our analyses, a higher anatomical complexity, based on large tumor sizes, endophytic properties, and closeness to renal sinus fat or collecting systems, represented a higher risk of RSI. However, the descriptors for RSI based on the RENAL score and PADUA classification demonstrated high NPV but high false-positive rates and low accuracy, which could have

**Table 3. Diagnostic Performance of Imaging Features for Predicting Renal Sinus Invasion**

	Sensitivity	Specificity	PPV	NPV	Accuracy
Nearness ≤ 4 mm (RENAL)	96.3 (78/81)	16.9 (33/195)	32.5 (78/240)	91.7 (33/36)	40.2 (111/276)
Renal sinus involvement (PADUA)	97.5 (79/81)	20.5 (40/195)	33.8 (79/234)	95.2 (40/42)	43.1 (119/276)
Size ≥ 4 cm	79.0 (64/81)	31.8 (62/195)	32.5 (64/197)	78.5 (62/79)	45.7 (126/276)
Non-smooth margin					
Reader 1	77.8 (63/81)	74.4 (145/195)	55.8 (63/113)	89.0 (145/163)	75.4 (208/276)
Reader 2	76.5 (62/81)	61.5 (120/195)	45.3 (62/137)	86.3 (120/139)	65.9 (182/276)
Finger-like projection					
Reader 1	38.3 (31/81)	89.2 (174/195)	59.6 (31/52)	77.7 (174/224)	74.3 (205/276)
Reader 2	32.1 (26/81)	84.6 (165/195)	46.4 (26/56)	75.0 (165/220)	69.2 (191/276)
Non-smooth margin or finger-like projection					
Reader 1	84.0 (68/81)	69.7 (136/195)	53.5 (68/127)	91.3 (136/149)	73.9 (204/276)
Reader 2	84.0 (68/81)	60.0 (117/195)	46.6 (68/146)	90.0 (117/130)	67.0 (185/276)

Data in parentheses represent the following: sensitivity = true positive cases/true positives + false negatives; specificity = true negatives/false positives + true negatives; PPV = true positives/true positives + false positives; NPV = true negatives/true negatives + false negatives; and accuracy = true positives + true negatives/all cases. NPV = negative predictive value, PADUA = preoperative aspects and dimensions used for an anatomical classification, PPV = positive predictive value, RENAL = radius, exophytic or endophytic, nearness to collecting system or sinus, anterior or posterior, and location relative to polar lines

led to the selection of more PN-eligible patients for RN, as shown in our analysis. In this regard, valid tools for improving the accuracy and reducing the false-positive rate of RSI are necessary to classify patients based on the optimal surgical method and best oncological outcome.

Several studies have described tumor features for predicting RSI based on cross-sectional imaging, including a tumor size greater than 5 cm, irregular tumor margin, tumor extension into the sinus, and tumor necrosis [4,5,29]. Likewise, our study demonstrated two significant imaging features for predicting RSI: a non-smooth margin and a finger-like projection. Of these, a finger-like projection of an RCC is a novel feature that has not, to our knowledge, been previously reported in other studies. In daily practice, we observed that some RCCs had a distinct feature of a focally protruding portion from the round or lobulated mass that was distinguishable from the vascular extension of the tumor. We refer to this feature as a finger-like projection. A similar term was used to describe the morphological features of RCC in pathology [19]. A finger-like tumor extension within a vascular space in renal sinus fat is a feature favoring RSI, and it was associated with the highest score for the pathologic features suggestive of pT3a, as well as a high consensus among expert pathologists [19]. Given the expanding nature of RCCs and the lack of a fibrous capsule impeding tumor growth into the vascular tissue [3], a finger-like projection could be useful as an important imaging predictor of RSI. In our analysis, this feature showed high specificity and an acceptable NPV for

**Table 4. Inter-Reader Agreement for the Imaging Features**

Imaging Features	Gwet's AC1	95% CIs
Enhancement pattern (homogeneous vs. heterogeneous)	0.91	0.87–0.95
Shape (round vs. lobulated)	0.59	0.50–0.69
Margin (smooth vs. non-smooth)	0.60	0.50–0.69
Finger-like projection	0.78	0.71–0.85

CI = confidence interval

both readers, with a substantial inter-reader agreement. We believe that this newly suggested imaging feature can be a useful marker to improve the diagnostic performance of RSI.

Preoperative RSI assessment for RCC should focus on improving NPV to reduce the risk of undertreatment, but the PPV and accuracy may be compromised. Because high-sensitivity readings for improving NPV can lead to a shift to radical surgery in patients who are eligible for nephron-sparing surgery, a balance between high NPV and acceptable accuracy is needed. If a non-smooth margin and a finger-like projection are taken into consideration when determining RSI, approximately 40% of patients could be reclassified as suitable for nephron-sparing surgery, which could lead to improved PPVs and accuracy. However, the PPV and accuracy appear suboptimal, particularly considering the high prevalence of RSI in the study cohort consisting of RN patients; therefore, further research will be necessary to improve the PPV and accuracy for the prediction of RSI.

This study had several limitations. First, there is the potential for selection bias because of the retrospective single-institution nature of the study. Second, we only

included patients undergoing RN, not those undergoing PN; therefore, the diagnostic performance for predicting RSI will not be the same for different clinical settings, including patients undergoing PN. For example, considering the high prevalence of highly complex tumors and high upstaging rate from cT1 to pT3a, the diagnostic performance for predicting RSI can be underestimated in the current study [15,27,28,32]. However, because RN specimens may permit more accurate pathologic staging, including a thorough evaluation of renal sinus fat, we chose patients who underwent RN. Furthermore, we only focused on the imaging features for predicting RSI, whereas other important features include perirenal fat invasion and renal vein or inferior vena cava invasion. However, considering RSI as a principal route for extrarenal extension and an indicator of a worse prognosis than perirenal fat invasion [6], the prediction of RSI should be extensively assessed. In addition, the moderate inter-reader agreement for non-smooth margins suggests that variability in the interpretation of CT-based tumor features by institutions and interpreting radiologists is still a concern.

In conclusion, the high complexity of RCC may reflect a greater chance of RSI and warrant a thorough evaluation of RSI. Anatomical renal sinus involvement, such as proximity to the renal sinus or invasion of the renal sinus, demonstrated low accuracy for predicting RSI despite the high NPVs. A non-smooth margin at the tumor-renal sinus interface and a finger-like projection into the renal sinus fat were both significant imaging features suggestive of RSI by RCC. Predicting RSI using these tumor features resulted in improved accuracy and PPVs while preserving the high NPVs, suggesting that CT-based tumor features are useful for evaluating RSI and determining the optimal surgical technique. A thorough evaluation of the relationship between the tumor and the renal sinus, especially for highly complex tumors, may improve decisions about preoperative staging and the optimal surgical technique.

## Supplement

The Supplement is available with this article at <https://doi.org/10.3348/kjr.2020.0984>.

## Conflicts of Interest

The authors have no potential conflicts of interest to disclose.

## Acknowledgments

We thank Seo Young Park, a statistician of Asan Medical Center, who helped improve manuscript.

## Author Contributions

Conceptualization: Kye Jin Park. Data curation: Ji Hoon Kim, Kye Jin Park. Formal analysis: Ji Hoon Kim, Kye Jin Park. Investigation: Ji Hoon Kim, Kye Jin Park. Methodology: Ji Hoon Kim, Kye Jin Park. Supervision: Mi-Hyun Kim, Jeong Kon Kim. Validation: Jeong Kon Kim. Visualization: Ji Hoon Kim. Writing—original draft: Ji Hoon Kim. Writing—review & editing: Kye Jin Park, Mi-Hyun Kim, Jeong Kon Kim.

## ORCID iDs

Ji Hoon Kim

<https://orcid.org/0000-0002-9280-414X>

Kye Jin Park

<https://orcid.org/0000-0001-8428-436X>

Mi-Hyun Kim

<https://orcid.org/0000-0003-4623-3259>

Jeong Kon Kim

<https://orcid.org/0000-0002-8101-8135>

## REFERENCES

- Bonsib SM. The renal sinus is the principal invasive pathway: a prospective study of 100 renal cell carcinomas. *Am J Surg Pathol* 2004;28:1594-1600
- Bonsib SM, Gibson D, Mhoon M, Greene GF. Renal sinus involvement in renal cell carcinomas. *Am J Surg Pathol* 2000;24:451-458
- Trpkov K, Grignon DJ, Bonsib SM, Amin MB, Billis A, Lopez-Beltran A, et al. Handling and staging of renal cell carcinoma: the International Society of Urological Pathology Consensus (ISUP) conference recommendations. *Am J Surg Pathol* 2013;37:1505-1517
- Kim C, Choi HJ, Cho KS. Diagnostic value of multidetector computed tomography for renal sinus fat invasion in renal cell carcinoma patients. *Eur J Radiol* 2014;83:914-918
- Bolster F, Durcan L, Barrett C, Lawler LP, Cronin CG. Renal cell carcinoma: accuracy of multidetector computed tomography in the assessment of renal sinus fat invasion. *J Comput Assist Tomogr* 2016;40:851-855
- Thompson RH, Leibovich BC, Cheville JC, Webster WS, Lohse CM, Kwon ED, et al. Is renal sinus fat invasion the same as perinephric fat invasion for pT3a renal cell carcinoma? *J Urol* 2005;174:1218-1221
- Bamias A, Escudier B, Sternberg CN, Zagouri F, Dellis A, Djavan B, et al. Current clinical practice guidelines for the



- treatment of renal cell carcinoma: a systematic review and critical evaluation. *Oncologist* 2017;22:667-679
8. Buffi NM, Saita A, Lughezzani G, Porter J, Dell'Oglio P, Amparore D, et al. Robot-assisted partial nephrectomy for complex (PADUA Score  $\geq 10$ ) tumors: techniques and results from a multicenter experience at four high-volume centers. *Eur Urol* 2020;77:95-100
  9. Kim SP, Campbell SC, Gill I, Lane BR, Van Poppel H, Smaldone MC, et al. Collaborative review of risk benefit trade-offs between partial and radical nephrectomy in the management of anatomically complex renal masses. *Eur Urol* 2017;72:64-75
  10. Kim SP, Thompson RH, Boorjian SA, Weight CJ, Han LC, Murad MH, et al. Comparative effectiveness for survival and renal function of partial and radical nephrectomy for localized renal tumors: a systematic review and meta-analysis. *J Urol* 2012;188:51-57
  11. Gershman B, Thompson RH, Boorjian SA, Lohse CM, Costello BA, Chevillet JC, et al. Radical versus partial nephrectomy for cT1 renal cell carcinoma. *Eur Urol* 2018;74:825-832
  12. Campbell S, Uzzo RG, Allaf ME, Bass EB, Cadeddu JA, Chang A, et al. Renal mass and localized renal cancer: AUA guideline. *J Urol* 2017;198:520-529
  13. Ljungberg B, Albiges L, Abu-Ghanem Y, Bensalah K, Dabestani S, Fernández-Pello S, et al. European association of urology guidelines on renal cell carcinoma: the 2019 update. *Eur Urol* 2019;75:799-810
  14. Mir MC, Derweesh I, Porpiglia F, Zargar H, Motttrie A, Autorino R. Partial nephrectomy versus radical nephrectomy for clinical T1b and T2 renal tumors: a systematic review and meta-analysis of comparative studies. *Eur Urol* 2017;71:606-617
  15. Gorin MA, Ball MW, Pierorazio PM, Tanagho YS, Bhayani SB, Kaouk JH, et al. Outcomes and predictors of clinical T1 to pathological T3a tumor up-staging after robotic partial nephrectomy: a multi-institutional analysis. *J Urol* 2013;190:1907-1911
  16. Tay MH, Thamboo TP, Wu FM, Zhaojin C, Choo TB, Ramaan L, et al. High R.E.N.A.L. Nephrometry scores are associated with pathologic upstaging of clinical T1 renal-cell carcinomas in radical nephrectomy specimens: implications for nephron-sparing surgery. *J Endourol* 2014;28:1138-1142
  17. Ficarra V, Novara G, Secco S, Macchi V, Porzionato A, De Caro R, et al. Preoperative aspects and dimensions used for an anatomical (PADUA) classification of renal tumours in patients who are candidates for nephron-sparing surgery. *Eur Urol* 2009;56:786-793
  18. Kutikov A, Uzzo RG. The R.E.N.A.L. nephrometry score: a comprehensive standardized system for quantitating renal tumor size, location and depth. *J Urol* 2009;182:844-853
  19. Williamson SR, Rao P, Hes O, Epstein JI, Smith SC, Picken MM, et al. Challenges in pathologic staging of renal cell carcinoma: an interobserver variability study of urologic pathologists. *Am J Surg Pathol* 2018;42:1253-1261
  20. Fukui S, Miyake M, Iida K, Onishi K, Hori S, Morizawa Y, et al. The preoperative predictive factors for pathological T3a upstaging of clinical T1 renal cell carcinoma. *Diagnostics* (Basel) 2019;9:76
  21. Ni D, Ma X, Li HZ, Gao Y, Li XT, Zhang Y, et al. Factors associated with postoperative renal sinus invasion and perinephric fat invasion in renal cell cancer: treatment planning implications. *Oncotarget* 2017;9:10091-10099
  22. Kim SY, Woo S, Hwang SI, Moon MH, Sung CK, Lee HJ, et al. Usefulness of resistive index on spectral Doppler ultrasonography in the detection of renal cell carcinoma in patients with end-stage renal disease. *Ultrasonography* 2014;33:136-142
  23. Hedgire SS, Elmi A, Nadkarni ND, Cao K, McDermott S, Harisinghani MG. Preoperative evaluation of perinephric fat invasion in patients with renal cell carcinoma: correlation with pathological findings. *Clin Imaging* 2013;37:91-96
  24. Kim J, Park JS, Heo JE, Elghiaty A, Jang WS, Rha KH, et al. Neutrophil-to-lymphocyte ratio predicts pathological renal sinus fat invasion in renal cell carcinomas of  $\leq 7$  cm with presumed renal sinus fat invasion. *Yonsei Med J* 2019;60:1021-1027
  25. Liu Y, Song T, Huang Z, Zhang S, Li Y. The accuracy of multidetector computed tomography for preoperative staging of renal cell carcinoma. *Int Braz J Urol* 2012;38:627-636
  26. El-Hefnawy AS, Mosbah A, El-Diasty T, Hassan M, Shaaban AA. Accuracy of multi-detector computed tomography (MDCT) in staging of renal cell carcinoma (RCC): analysis of risk factors for mis-staging and its impact on surgical intervention. *World J Urol* 2013;31:887-891
  27. Jeong SH, Kim JK, Park J, Jeon HJ, Yoon MY, Jeong CW, et al. Pathological T3a upstaging of clinical T1 renal cell carcinoma: outcomes according to surgical technique and predictors of upstaging. *PLoS One* 2016;11:e0166183
  28. Nayak JG, Patel P, Saarela O, Liu Z, Kapoor A, Finelli A, et al. Pathological upstaging of clinical T1 to pathological T3a renal cell carcinoma: a multi-institutional analysis of short-term outcomes. *Urology* 2016;94:154-160
  29. Sokhi HK, Mok WY, Patel U. Stage T3a renal cell carcinoma: staging accuracy of CT for sinus fat, perinephric fat or renal vein invasion. *Br J Radiol* 2015;88:20140504
  30. Amin MB, Edge SB. *AJCC cancer staging manual*, 8th ed. New York: Springer, 2017
  31. Wongpakaran N, Wongpakaran T, Wedding D, Gwet KL. A comparison of Cohen's Kappa and Gwet's AC1 when calculating inter-rater reliability coefficients: a study conducted with personality disorder samples. *BMC Med Res Methodol* 2013;13:61
  32. Koo KC, Kim JC, Cho KS, Choi YD, Hong SJ, Yang SC, et al. Oncological outcomes after partial vs radical nephrectomy in renal cell carcinomas of  $\leq 7$  cm with presumed renal sinus fat invasion on preoperative imaging. *BJU Int* 2016;117:87-93
  33. Fernando A, Fowler S, O'Brien T; British Association of Urological Surgeons (BAUS). Nephron-sparing surgery across a nation - outcomes from the British Association of Urological Surgeons 2012 national partial nephrectomy audit. *BJU Int* 2016;117:874-882