



European Association of Urology

Open Horizon

Clinically Significant Prostate Cancer Diagnosis Without Histological Proof: A Possibility in the Prostate-specific Membrane Antigen Era?

Joris G. Heetman^{a,*}, Lieke Wever^{a,b}, Leonor J. Paulino Pereira^a, Roderick C.N. van den Bergh^a

Article info

Article history:

Accepted June 25, 2022

Associate Editor:

Guillaume Ploussard

Keywords:

Prostate cancer
Prostate biopsy
Magnetic resonance imaging of the prostate
Prostate-specific membrane antigen
Positron emission tomography/computed tomography

Abstract

Magnetic resonance imaging (MRI) has resulted in a reduction in the number of patients indicated for prostate biopsy. Prostate-specific membrane antigen (PSMA) positron emission tomography/computed tomography (PET/CT) has recently shown additional value in detecting clinically significant prostate cancer (csPCa). Combining these imaging modalities allows such specific prediction of the presence of csPCa that the need for histological confirmation may be obsolete. We retrospectively analyzed PSMA PET/CT scans performed in the primary staging of PCa in the past 2 yr in our center ($n = 451$). All 74 patients with a PSMA ligand maximum standardized uptake value (SUVmax) of ≥ 16 had csPCa (grade group ≥ 2). Of the 185 patients with a combination of a Prostate Imaging-Reporting and Data System score ≥ 4 and SUVmax ≥ 8 , 98% had csPCa. A nomogram combining predictive factors should be developed to identify patients in whom biopsy could theoretically be avoided. Nevertheless, biopsy will remain indispensable in patients with indefinite risk of csPCa and can provide important additional information.

Patient summary: Using patient data from our center, we found that addition of a special type of scan based on prostate-specific membrane antigen could help in the diagnosis of clinically significant prostate cancer without the need for prostate biopsy. Direct therapy without biopsy confirmation of cancer might be possible for a highly select group of patients.

© 2022 The Author(s). Published by Elsevier B.V. on behalf of European Association of Urology. This is an open access article under the CC BY-NC-ND license (<http://creativecommons.org/licenses/by-nc-nd/4.0/>).

The introduction of magnetic resonance imaging (MRI) recently improved the pathway for the diagnosis of clinically significant prostate cancer (csPCa), resulting in recommendation of prostate MRI before a prostate biopsy [1]. However, this imaging technique cannot confirm csPCa without histological biopsy, with 17% of the biopsies performed for lesions with a Prostate Imaging-Reporting and Data System (PI-RADS) maximum score of 5 confirming nonsignificant PCa or benign tissue [2].

The PRIMARY trial has recently proved the added value of prostate-specific membrane antigen (PSMA) positron

emission tomography/computed tomography (PET/CT) in detecting csPCa lesions in the primary diagnostic setting by showing an improvement in the negative predictive value and sensitivity of MRI when combined [3]. Furthermore, the authors suggested a PRIMARY score for local activity on PSMA PET/CT [4]. Besides detecting csPCa not visible on MRI, prostatic lesions with a high maximum standardized uptake value (SUVmax) on PSMA PET/CT and a PI-RADS score ≥ 4 on MRI resulted in high probability of csPCa [5]. This raises the question of whether histological confirmation of suspected lesions is still needed if both



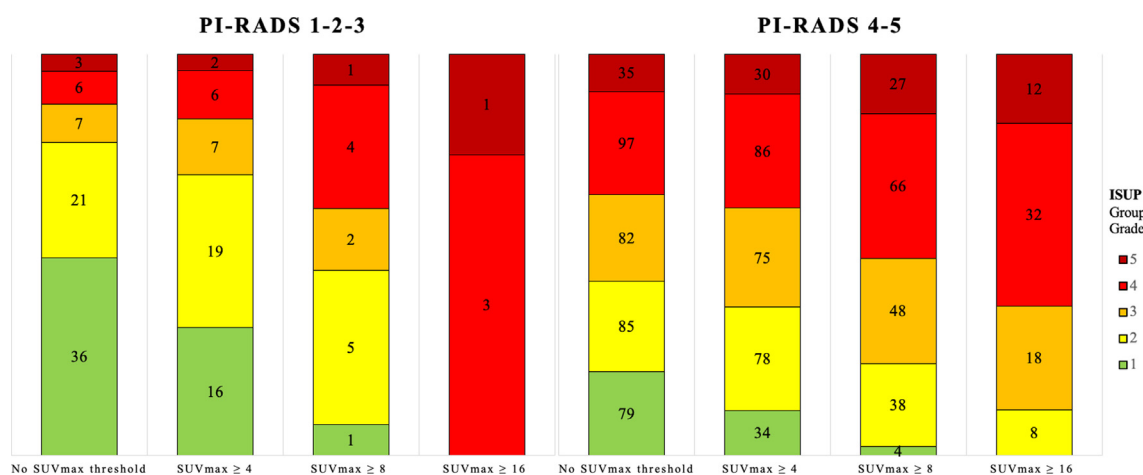


Fig. 1 – ISUP grade groups by prostate-specific membrane antigen SUVmax threshold for PI-RADS 1–3 and 4–5 groups. Numbers within the bars denote the number of patients. ISUP = International Society of Urological Pathology; PI-RADS = Prostate Imaging-Reporting and Data System; SUVmax = maximum standardized uptake value.

Table 1 – Baseline imaging characteristics

	Overall (n = 451)	ISUP group grade ≥2 (n = 336)	ISUP grade group ≥3 (n = 230)
Median age, yr (IQR)	70 (65–74)	71 (66–75)	71 (66–75)
Median PSA, ng/ml (IQR)	8.5 (5.5–15.5)	10.0 (6.4–17.6)	10.6 (6.4–19.6)
Median PSA density, ng/ml/ml (IQR)	0.19 (0.12–0.33)	0.24 (0.15–0.38)	0.27 (0.16–0.41)
MRI T stage, n (%)			
T0	42 (9)	23 (7)	8 (4)
T2	238 (53)	149 (44)	94 (41)
T3	161 (36)	154 (46)	120 (52)
T4	10 (2)	10 (3)	8 (4)
PI-RADS score, n (%)			
1	12 (3)	6 (2)	2 (1)
2	29 (6)	16 (5)	5 (2)
3	32 (7)	15 (4)	9 (4)
4	145 (32)	86 (26)	46 (20)
5	233 (52)	213 (63)	165 (73)
ISUP grade group, n (%)			
1	115 (25)	–	–
2	106 (24)	106 (32)	–
3	89 (20)	89 (26)	89 (39)
4	103 (23)	103 (31)	103 (45)
5	38 (8)	38 (11)	38 (17)
Median SUVmax, (IQR)	6.9 (4.2–12.2)	8.8 (5.4–14.9)	10.3 (6.4–17.1)

IQR = interquartile range; PSA = prostate-specific antigen; MRI = magnetic resonance imaging; PI-RADS = Prostate Imaging-Reporting and Data System; ISUP = International Society of Urological Pathology; SUVmax = maximum standardized uptake value.

imaging techniques are combined in an accurate “virtual biopsy” [6]. If the chance of csPCa is close to 100% and treatment with radical prostatectomy is planned, a prostate biopsy for histological confirmation could be seen as redundant. A case series of patients who refused prostate biopsy illustrated that this unusual diagnostic pathway might be optional [7]. This pathway for diagnosing csPCa without histological proof could be a future option to reduce the 1 million prostate biopsies performed in Europe each year [8]. Therapy without histological confirmation is already in practice for other malignancies such as renal cell carcinoma, for which histological proof is only used for radiologically indeterminate renal masses [9]. Omission of prostate biopsy in the diagnostic pathway results in a lower burden for the patient, as even the transperineal approach has complications and may be painful [10].

We hypothesize that it is only feasible to omit biopsy if the combination of prebiopsy parameters can highly specifically predict the presence of csPCa. Ideally, not only International Society of Urological Pathology (ISUP) grade group (GG) ≥2 but also GG ≥3 can be identified, because active therapy is generally recommended for all of these cases [1].

To test whether prediction of csPCa is indeed feasible with combined MRI information and PSMA PET/CT activity, we analyzed a prospectively maintained database of patients with MRI and PSMA PET/CT results available for initial staging, and biopsy-proven PCa diagnosed in the past 2 yr in our institution. Owing to an ongoing prospective trial in our center in which the ⁶⁸Ga-PSMA PET/CT is performed for patients starting active surveillance, our data set includes patients with low-, intermediate-, and high-risk PCa. Our center has extensive experience with both

^{68}Ga -PSMA PET/CT and MRI of the prostate. The analysis was performed using R v4.1.2 (R Foundation for Statistical Computing, Vienna, Austria); the *rpart* package was used to create a decision tree for SUVmax thresholds, in addition to the SUVmax of 4 suggested in the PRIMARY study as a threshold for csPCa [3].

A total of 451 patients were included in the analysis. The baseline characteristics are presented in Table 1. Figure 1 shows ISUP grade groups by SUVmax threshold for PI-RADS 1–3 and 4–5 groups. Of the 74 patients with SUVmax ≥ 16 , all had GG ≥ 2 and 89% had GG ≥ 3 disease. The combination of PI-RADS 4 or 5 with SUVmax ≥ 8 resulted in GG ≥ 2 rate of 98%. These results illustrate that PSMA activity on PET/CT is highly indicative of the presence of csPCa. On combination with other parameters, more accurate prediction of GG ≥ 3 may be possible.

In the PRIMARY trial, the specificity for detection of GG ≥ 2 was 50% for SUVmax ≥ 4 alone and 40% when combined with MRI. These specificity results are lower than the 57% and 70%, respectively, in our analysis [3]. The specificity increases to 96% and 97%, respectively, when a threshold of 8 is applied to our data. Unlike the PRIMARY trial, patients underwent PSMA PET/CT after their diagnosis of PCa, resulting in possible overestimation of the predictive accuracy [3].

Initiation of treatment for suspicion of PCa without histological confirmation remains controversial. Performing initial PSMA PET/CT in all patients to decide on the indication for biopsy would not be cost-effective. However, in a select group with high risk of csPCa, upfront PSMA may be performed and biopsy may be omitted if the clinical characteristics and imaging are highly suggestive. However, biopsy may provide more information than ISUP GG only, including specific tumor characteristics, any need for DNA testing, and useful data for planning radical or focal surgery.

Further research will focus on a model that combines prebiopsy parameters, possibly with the PRIMARY score [4], for accurate prediction of csPCa. Only then could treatment without histological confirmation be considered for selected patients.

Conflicts of interest: The authors have nothing to disclose.

References

- [1] Mottet N, van den Bergh RCN, Briers E, et al. EAU-EANM-ESTRO-ESUR-SIOG guidelines on prostate cancer—2020 update. Part 1: screening, diagnosis, and local treatment with curative intent. *Eur Urol* 2021;79:243–62. <https://doi.org/10.1016/j.eururo.2020.09.042>.
- [2] Kasivisvanathan V, Rannikko AS, Borghi M, et al. MRI-targeted or standard biopsy for prostate-cancer diagnosis. *N Engl J Med* 2018;378:1767–77. <https://doi.org/10.1056/NEJMoa1801993>.
- [3] Emmett L, Buteau J, Papa N, et al. The additive diagnostic value of prostate-specific membrane antigen positron emission tomography computed tomography to multiparametric magnetic resonance imaging triage in the diagnosis of prostate cancer (PRIMARY): a prospective multicentre study. *Eur Urol* 2021;80:682–9. <https://doi.org/10.1016/j.eururo.2021.08.002>.
- [4] Emmett LM, Papa N, Buteau J, et al. The PRIMARY score: using intra-prostatic PSMA PET/CT patterns to optimise prostate cancer diagnosis. *J Nucl Med*. In press. <https://doi.org/10.2967/jnumed.121.263448>.
- [5] Ptasznik G, Papa N, Kelly BD, et al. High PSMA PET SUVmax in PI-RADS 4 or men confers a high probability of significant prostate cancer. *BJU Int*. In press. <https://doi.org/10.1111/bju.15736>.
- [6] Murray JM, Wiegand B, Hadaschik B, Herrmann K, Kleesiek J. Virtual biopsy: just an AI software or a medical procedure? *J Nucl Med* 2022;63:511–3. <https://doi.org/10.2967/jnumed.121.263749>.
- [7] Meissner VH, Rauscher I, Schwamborn K, et al. Radical prostatectomy without prior biopsy following multiparametric magnetic resonance imaging and prostate-specific membrane antigen positron emission tomography. *Eur Urol*. In press. <https://doi.org/10.1016/j.eururo.2021.11.019>.
- [8] Kasivisvanathan V, Emberton M, Moore CM. There is no longer a role for systematic biopsies in prostate cancer diagnosis. *Eur Urol Open Sci* 2022;38:12–3. <https://doi.org/10.1016/j.euro.2022.01.006>.
- [9] Ljungberg B, Albiges L, Abu-Ghanem Y, et al. European Association of Urology guidelines on renal cell carcinoma: the 2022 update. *Eur Urol*. In press. <https://doi.org/10.1016/j.eururo.2022.03.006>.
- [10] Tan J-L, Papa N, Hanegbi U, et al. Predictors of erectile dysfunction after transperineal template prostate biopsy. *Investig Clin Urol* 2021;62:159–65. <https://doi.org/10.4111/icu.20200236>.

^a Department of Urology, Sint Antonius Hospital, Utrecht-Nieuwegein, The Netherlands

^b Department of Urology, Canisius Wilhelmina Hospital, Nijmegen, The Netherlands

* Corresponding author. Department of Urology, Sint Antonius Hospital, Koekoekslaan 1, 3435 CM Nieuwegein, The Netherlands. Tel. +31 883208872.

E-mail address: j.heetman@antoniusziekenhuis.nl (J.G. Heetman).