

ORIGINAL PAPER

doi: 10.5455/medarch.2021.75.204-208

MED ARCH. 2021 JUN; 75(3): 204-208

RECEIVED: MAY 13, 2021

ACCEPTED: JUN 20, 2021

1Eye Hospital Svjetlost, Sarajevo, Bosnia and Herzegovina

2University Eye Hospital Svjetlost, School of Medicine University of Rijeka, Zagreb, Croatia

3Eye Clinic, Clinical Center University of Sarajevo, Bosnia and Herzegovina

Corresponding author: Alma Biscevic, MD, PhD. Heinzelova 39, 10 000 Zagreb, Croatia. Tel. +387 60 31 94 712, fax: +387 33 762 771. E-mail: alma@svjetlost-sarajevo.ba, alma.biscevic@svjetlost.hr. ORCID ID: <http://www.orcid.org/0000-0002-6496-2853>.

Comparison of Flap Characteristics Created with Two Different Methods in Laser in Situ Keratomileusis (LASIK)

Melisa Ahmedbegovic-Pjano¹, Alma Biscevic^{1,2}, Amila Alikadic-Husovic³, Nita Bejdic¹, Maja Bohac²

ABSTRACT

Background: The creation of corneal flap is considered to be the most critical part of laser in situ keratomileusis (LASIK) surgery. Currently, flaps can be created with mechanical microkeratomers or femtosecond lasers. **Objective:** To analyze and compare flap characteristics created with two different methods for flap creation in Laser in situ keratomileusis (LASIK). **Methods:** This was a retrospective study. The thickness and morphology of the flap were compared between the two mechanical microkeratomers (group I – Moria M2, group II – Moria SBK One Use Plus) and femtosecond laser (group III – Ziemer Femto LDV). Central flap thickness was measured intraoperatively, while the flap profile was measured with anterior optical coherence tomography at two axes (90° and 180°) and 5 measuring points on the first day, the first week, and one month after the surgery. **Results:** Central flap thickness was 110.91±15.79 micrometers (µm) (80-164 µm) in group I, 98.08±13.33 µm (65-136 µm) in group II and 103.52±13.89 µm (66-138 µm) in group III. Anterior optical coherence tomography revealed a meniscus-shaped flap in all three groups at both axes (90° and 180°). The least variability in flap thickness was observed in group III (±6 µm). **Conclusion:** All three methods of flap creation provide good shape and thickness reproducibility. Ziemer Femto LDV femtosecond laser had the least variable flap thickness in a single flap. Mechanical microkeratomers had slightly lower performance.

Keywords: LASIK, refractive surgery, mechanical microkeratome, femtosecond laser, corneal flap.

1. BACKGROUND

The creation of the corneal flap is considered to be the most critical part of laser in situ keratomileusis (LASIK) surgery. Currently, flaps can be created with mechanical microkeratomers or femtosecond lasers. So far, there is no definitive evidence in the literature claiming one technology is better than the other and none of the existing microkeratomers provides perfectly reproducible and safe results (1).

The first manually handled microkeratome was designed in 1958 and was used for lamellar keratectomy and freezing keratomileusis (2). Automatic microkeratomers used nowadays can produce different shapes of flaps and each has unique characteristics that determine the size, thickness, and hinge of created flaps.

The femtosecond laser is based on the principle of non-linear absorption and photoionization principle, leading to photo disruption in the focal point. The results are the formation of a fast-spreading cloud of free ions and ionized molecules (plasma). A small volume of tissues is vaporized and form gas bubbles leading to disruption of tissue. The main feature of the femtosecond laser is that by using small energy it can achieve high power (3). In the last 20 years the creation of the flaps using this technology is becoming more popular, whereas studies are reporting superiority of custom flap formation and lower incidence of intraoperative complications (3, 4).

2. OBJECTIVE

To analyze and compare flap characteristics, focusing on thickness and morphology, created with two different methods for flap creation in Laser in situ keratomileusis (LASIK).

© 2021 Melisa Ahmedbegovic-Pjano, Alma Biscevic, Amila Alikadic-Husovic, Nita Bejdic, Maja Bohac

This is an Open Access article distributed under the terms of the Creative Commons Attribution Non-Commercial License (<http://creativecommons.org/licenses/by-nc/4.0/>) which permits unrestricted non-commercial use, distribution, and reproduction in any medium, provided the original work is properly cited.

3. MATERIALS AND METHODS

This was a retrospective, interventional, randomized study performed at University Eye Hospital Svjetlost in Zagreb. The study was approved by the Ethics Committee at the University Eye Hospital Svjetlost. The tenets of the Helsinki agreement were followed throughout (5). Informed consent was obtained from all patients after they were informed about the procedures, their risks and benefits.

PREOPERATIVE EXAMINATION AND INCLUSION CRITERIA

During the period of enrolment, at the department for Refractive surgery, 4032 candidates underwent examination for refractive surgery, of which 154 met all inclusion criteria for the study. Inclusion criteria were minimal age of 18 years, stable refraction, myopia between -0.50 and -7.50 diopters (D), astigmatism ≤ 2.0 D, with BCVA Log MAR 0.0. Ocular and exclusion criteria were those normally adopted in refractive surgery.

Patients were divided into 3 groups. In group 1 the flap was created with Moria M2 mechanical microkeratome (Moria, Anthony, France), in group 2 with Moria SBK One Use Plus mechanical microkeratome (Moria, Anthony, France), and group 3 by using Ziemer Femto LDV femtosecond laser (Ziemer Ophthalmic System AG, Port, Switzerland). All corneal ablations were performed using the Schwind Amaris750S excimer laser (Schwind Eye Tech Solutions, Kleinostheim, Germany).

MEASUREMENTS OF FLAP THICKNESS AND MORPHOLOGY

A central thickness of the flap was measured during the procedure with a hand pachymeter (Accutome Pachpen, Accutome Inc, Malvern, USA).

Before the flap creation, central corneal thickness was measured, and the same procedure was repeated on the stromal bed right after the flap was lifted. Every measurement was performed three times, and an average calculation was used for the study. Flap thickness was derived using the subtraction method.

After the procedure flap thickness was analyzed using anterior optic corneal tomography (Anterior Visante OCT, Zeiss Meditech, Jena, Germany).

Images were created on 0° and 90° axis. Perpendicular cuts showed clear margins of the flap due to higher reflectivity from the areas of corneal layering (zones between stromal bed and flap).

Flap thickness was measured using a semiautomatic computer program (Flap Tool) at five points in each meridian (10 measurements from each eye). The points were: 1. Central zone (± 0.5 millimeters (mm) from vertex), 2. Two paracentral points (± 1.5 mm to 2.0 mm from vertex), 3. Two peripheral points (± 3.5 mm to 4.0 mm from vertex).

POSTOPERATIVE EXAMINATIONS

The measurements were performed by the same examiner on day 1, day 7, and 1 month postoperatively. Results from 1 month after the surgery were analyzed in this study. At each visit, UDVA and SE were measured, along with slit-lamp examination, tonometry, anterior

optic corneal tomography, and corneal topography were performed.

STATISTICAL ANALYSIS

Statistical analysis was performed with SPSS for Windows (19.0, SPSS Inc, Chicago, Illinois, SAD) and Microsoft Excel (11.0, Microsoft Corporation, Redmond, WA, SAD). The comparison between the preoperative and postoperative periods was performed with the Wilcoxon signed-rank test. The value of $p < 0.05$ was considered statistically significant.

4. RESULTS

CENTRAL FLAP THICKNESS

The values of central flap thickness (CFT) are presented in Table 1. Manufacturers planned that CFT made with Moria M2 using 90 μm blade would be 110 μm , and in our study it was 110.91 ± 15.79 μm . When using 90 μm Moria SBK One Use Plus blade, the expected CFT was 100 μm , and in the study the value was 98.08 ± 13.33 μm . Planned CFT with Ziemer Femto LDV when using foil calibrated at 110 μm was exactly 110 μm , and the value in the study that we measured was 103.52 ± 13.89 μm .

There is a statistically significant difference in CFT between the groups ($p < 0.001$). The thickest flaps were in group I, and the thinnest were in group II. A comparison of the thickness between the groups is presented in Figure 1.

FLAP THICKNESS PROFILE ON THE 90° AXIS

Profile and flap thickness was measured at 5 spots on the 90° axis in all three groups.

In all groups, the values indicate that the created flaps are meniscus-shaped, where the thinnest area is in the center and the thickest one on the periphery, as presented in Figure 2. During the follow-up in the central flap thickness (p3) there was a statistically significant difference in three intervals ($p = 0.003$). By multiple testing, there was no significant difference (day one – week one $p = 0.714$, day one – month one $p = 0.054$, week one – month one $p = 0.090$).

In group II there was no statistically significant difference in CFT (p3) during follow-up in three different intervals ($p = 0.431$).

In group III there was a statistically significant difference in CFT during three intervals ($p = 0.003$). But multiple testing showed no significant difference (day one – week one $p = 0.081$, day one – month one $p = 0.099$, week one – month one $p = 0.135$).

FLAP THICKNESS PROFILE ON THE 180° AXIS

Profile and flap thickness was measured at 5 spots on the 180° axis in all three groups.

Same as on the perpendicular axis in all groups the values indicate that the created flap is in the shape of the meniscus, where the thinnest area is in the center and the thickest on the periphery, as presented in Figure 3.

In group I and group II there was no statistically significant difference during follow-up (group I $p = 0.055$ and group II $p = 0.148$). In group III there was a statistically significant difference in CFT-p3 ($p = 0.014$). After multiple testing, there was no significant difference (day

one – week one $p=0.186$, day one – month one $p=0.276$, week one – month one $p=0.99$.

The difference in flap profile between the Ziemer Femto group and microkeratome groups was statistically significant ($p<0.001$) in all points on both axes (90° and 180°); Ziemer Femto LDV had significantly higher change (thicker flap) on the periphery in comparison to the center of the flap. When comparing group I and group II there was a signifi-

METHOD	M2	MORIA SBK ONE USE PLUS	ZIEMER FEMTO LDV				
Number of eyes	100	98	100				
Minimum value (μm)	80	65	66				
Maximum value (μm)	164	136	138				
Mean (μm)	SD	110.91	15.79	98.08	13.33	103.52	13.89
Median (μm)	interquartile range	109.50	20.00	100.00	15.00	105.50	18.00

Table 1. Intraoperative central flap thickness values (SD – standard deviation, μ -micrometers)

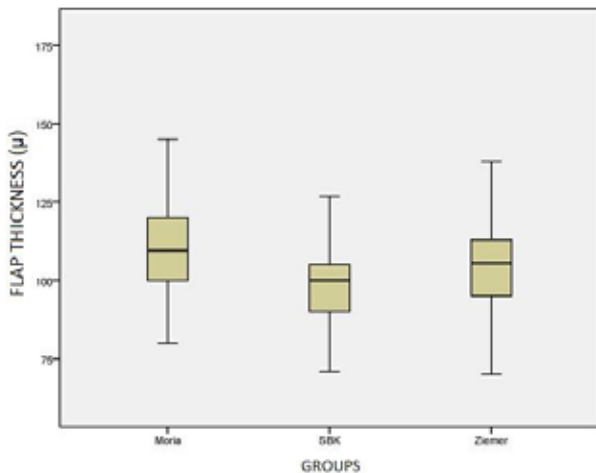


Figure 1. Comparison of central flap thickness in groups (Group I –Moria M2, Group 2 – SBK, Group III – Ziemer; μ -micrometers)

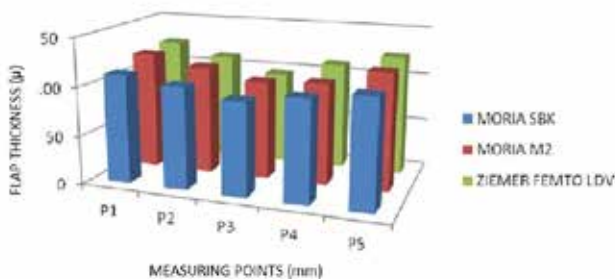


Figure 2. Flap thickness profile on 90° axis in all groups one month after surgery (P3 – center of the flap, P2 and P1 spots measured on 2 and 4 mm up, P4 and P5 spots measured 2 and 4 mm down. (mm –millimeters, μm - micrometers))

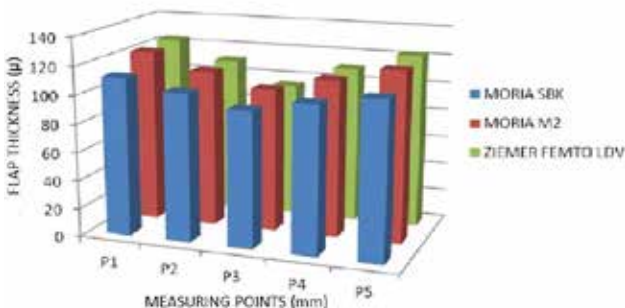


Figure 3. Flap thickness profile on the 180° axis in all groups one month after surgery (P3 – center of the flap, P2 and P1 spots measured on 2 and 4 mm to the right, P4 and P5 spots measured 2 and 4 mm to the left, mm –millimeters, μm - micrometers).

cant difference only in the P1 position on 90° ($p=0.009$). On the 180° axis, a statistically significant difference was on P1 and P5 ($p=0.003$, $p=0.005$), where flaps created with Moria M2 had higher change (thicker flap) in comparison to the center of the flap.

5. DISCUSSION

The technological advances in flap formation during the last few decades had the aim of making safer and more reproducible surgical methods. It is believed that femtosecond lasers create more precise and reproducible flaps, with predefined thicknesses with a predictable length of the hinge and steep border cuts for better position and stability of the flap on the stroma (6). Unlike femtosecond lasers most microkeratomes tend to form meniscus shape flaps, thicker on the periphery and thinner in the center. Moria SBK One Use Plus mechanical microkeratome uses linear motion, so the created flaps are most similar to femtosecond laser in uniformity and geometrical shape (7,8).

It is known that flap thickness and morphology do change in the first month after the surgery because of dehydration of the flap and the healing process, and after that, it remains stable.

In our study intraoperative central thickness of the flap measured with a manual pachymeter in all three groups was very similar to the planned thickness of the flap. But CFT differed in intraoperative manual pachymetry and post-operative measurement by optical coherent tomography. Measurements using optical coherent tomography are commonly lower in relation to manual pachymeter (9). Reasons for this are lower sensitivity of manual pachymetry, surgeon positions the tip of the pachymeter with the hand and it is very difficult to adjust it to the exact same position of measurement before and after creating the flap. Also, residual fluid at the top of the pachymeter and cornea can lead to imprecise measurements. Anterior optical coherent tomography is a non-invasive, non-contact metering method with high-resolution images on a predetermined meridian of the cornea, and provides more precise measurement than a manual pachymeter (10).

Flap thickness measurement using anterior OCT did not show a statistically significant difference within groups in the individual monitoring points ($p>0.05$). One month after the procedure, the central flap thickness in all three groups was lower than planned.

Zhou et al. (11) also reported flaps somewhat thinner using femtosecond laser compared to the planned 110 μm ($105 \pm 7 \mu\text{m}$), but with Moria M2 the flap reported was thicker than planned 110 μm ($119 \pm 16 \mu\text{m}$).

In another study, the flaps created were thicker than planned using Moria M2 mechanical microcircuits ($134 \pm 3 \mu\text{m}$) (12).

Zhai et al. compared the central flap thickness between Intralase femtosecond laser, Moria M2, and Moria SBK mechanical microkeratome, and in both microkeratome groups the flaps were thicker than planned (Moria M2 $118 \pm 13 \mu\text{m}$, Moria SBK $114 \pm 8 \mu\text{m}$) (8). Contrary to the results of our study, Zhang et al., using intraoperative subtraction pachymetry in Moria SBK One Use Plus report the CFT thicker than planned 100 μm ($110 \pm 7 \mu\text{m}$) (7).

Pietilä et al. reported similar results of CFT ($89 \pm 2 \mu\text{m}$) to planned 90 μm using Ziemer Femto LDV switch by intraoperative subtraction pachymetry (13). Contrary to previously reported results (6,11) in our study all three groups had a flap in the form of a meniscus with the highest variation of thickness at the very periphery.

Also, our results show that the progression of flap thickness from the center to the periphery is highest in the Ziemer Femto LDV femtosecond laser, which was not the case in other studies (6,11).

However, despite the unexpected shape of the meniscus in the Ziemer Femto LDV femtosecond laser, the difference in flap thickness at each measurement point was the smallest in group III. A potential explanation is in the application method of the viscous fluid in the study. The manufacturer's recommendation is one to two drops before the application, but the surgeon used three or more drops. There is a possibility that the distribution of the fluid on the cornea surface produced meniscus-shaped flaps since, the laser beam passed through a layer of liquid before penetrating corneal tissue. Moria M2 created the thickest and least reproducible flaps compared to the other two methods, comparable to literature (11,12).

The standard deviation for Moria M2 ranged $\pm 14 \mu\text{m}$ at points P1 and P5, with the Moria SBK One Use Plus ranged $\pm 12 \mu\text{m}$, and for Ziemer Femto LDV $\pm 6 \mu\text{m}$. Zhai and associates compared Moria M2, Moria SBK One Use Plus, and Intralase 60 kilohertz (kHz) femtosecond laser, and in all three groups obtained a nearly planar shape of the flap. The authors also report the highest variability of flap thickness on the periphery of the Moria M2 with deviations of up to $\pm 20 \mu\text{m}$, however, for Moria SBK, the greatest deviations were found in the center and ranged to $\pm 13 \mu\text{m}$ (11).

Although femtosecond lasers in most cases provide more reproducible flap thickness compared to mechanical microkeratomes, in some cases they can create flaps far thicker or thinner than planned. Patel and associates reported flaps up to 53 μm thicker than those planned with the use of Intralase femtosecond laser (9). In our study, Ziemer Femto LDV lasers, we often encountered central thinner flaps than planned, and the flap thickness ranged from 82 to 129 μm on the 90° axis, and 79 to 112 μm on the 180-degree axis. A similar trend was

observed with Moria SBK where the range of the CFT was from 81 to 110 μm on both axes.

Moria M2 presented the highest variability rate in CFT 80 to 133 μm on the 90° axis and 84 to 134 μm on the 180° axis. In the case that flaps are significantly thicker than planned the risks of ectasia are also increased especially for thinner corneas and/or higher refractive errors (14,15).

The creation of thinner rather than thicker layers may be desirable, but there is a limit when thin becomes too thin. Too thin flaps can lead to dissection within the epithelium or Bowman's membrane, the development of microfolds, post-operative instability (slip) of the flap, epithelial ingrowth and irregular astigmatism (16).

- **Author's contribution:** All authors were involved in all steps of preparation this article. Final proofreading was made by the first author.
- **Conflict of interest:** None declared.
- **Financial support and sponsorship:** No specific was funding was received for this study.

REFERENCES

1. Solomon KD, Donnenfeld E, Sandoval HP, et al. Flap Thickness Study Group. Flap thickness accuracy: Comparison of 6 microkeratome models. *J Cataract Refract Surg.* 2004;30(5):964–977.
2. Barraquer JL. The history and evolution of keratomileusis. *Int Ophthalmol Clin.* 1996;36(4):1-7.
3. Kim TI, Del Barrio JLA, Wilkins M, et al. Refractive surgery. 2019;393(10):2085-2098.
4. Kahuam-López N, Navas A, Castillo-Salgado C, et al. Femtosecond laser versus mechanical microkeratome use for laser-assisted in-situ keratomileusis (LASIK). *Cochrane Database of Systematic Reviews.* 2018;(2):CD012946.
5. Declaration of Helsinki. Ethical principles for medical research involving human subjects. <https://www.wma.net/policies-post/wma-declaration-of-helsinki-ethical-principles-for-medical-research-involving-human-subjects/> (date last accessed: 06. January 2020)
6. Lacaille M, Rambaud C, Crepy P, et al. Uniformity of the thickness of LASIK corneal flaps made by IntraLase FS 60 laser femtosecond (IntraLase, AMO USA) measured by OCT spectral domain (Heidelberg, Germany). *Acta Ophthalmologica.* 2013; 91(1): 0-0.
7. Zhang J, Zhang S-S, Yu Q, Wu J-X, Lian J-C. Comparison of corneal flap thickness using a FS200 femtosecond laser and Moria SBK microkeratome. *Int J Ophthalmol.* 2014;7(2):273-277.
8. Zhai CB, Tian L, Zhou YH, et al. Comparison of the flaps made by femtosecond laser and automated keratomes for sub – bowman keratomileusis. *Chin Med J.* 2013;126(13):2440-2444.
9. Patel SV, Maguire LJ, McLaren JW, et al. Femtosecond lasers versus mechanical microkeratome for LASIK: a randomized controlled study. *Ophthalmology.* 2007;114(8):1482-1490.
10. Abdelazeem K, Sharaf M, Saleh MGA, et al. Relevance of Swept-Source Anterior Segment Optical Coherence Tomography for Corneal Imaging in Patients With Flap-Related Complications After LASIK. *Cornea.* 2019;38(1):93-97.
11. Zhou Y, Zhang J, Tian L, Zhai C. Comparison of the Ziemer

Comparison of Flap Characteristics Created with Two Different Methods in Laser in Situ Keratomileusis (LASIK)

- FEMTO LDV femtosecond laser and Moria M2 mechanical microkeratome. *J Refract Surg.* 2012;28(3):189-194.
12. Eldaly ZH, Abdelsalam MA, Hussein MS, Nasser MA. Comparison of Laser In Situ Keratomileusis Flap Morphology and Predictability by WaveLight FS200 Femtosecond Laser and Moria Microkeratome: An Anterior Segment Optical Coherence Tomography Study. *Korean J Ophthalmol.* 2019;33(2):113-121.
 13. Pietilä J, Huhtala A, Mäkinen P, Uusitalo H. Flap characteristics, predictability, and safety of the Ziemer FEMTO LDV femtosecond laser with the disposable suction ring for LASIK. *Eye.* 2014;28(1):66-71.
 14. Ambrósio R Jr. Post-LASIK Ectasia: Twenty Years of a Conundrum. *Semin Ophthalmol.* 2019;34(2):66-68.
 15. Bohac M, Koncarevic M, Pasalic A, et al. Incidence and Clinical Characteristics of Post LASIK Ectasia: A Review of over 30,000 LASIK Cases. *Semin Ophthalmol.* 2018;33(7-8):869-877.
 16. Mimouni M, Vainer I, Assad N, et al. Incidence, Indications, and Outcomes of Eyes Needing Early Flap Lifting After LASIK. *Cornea.* 2018;37(9):1118-1123.