



Original Research

Lumbar Intradiscal Ozone Chemonucleolysis Applied Together with the Epidural Steroid Treatment

Mustafa Kilic,¹ Tulay Ercalik,² Burak Ozdemir,¹ Ilhan Yilmaz,¹ Ali Serdar Oguzoglu,³ Levent Aydin,¹ Balkan Sahin,¹ Adem Yilmaz,¹ Ahmet Murat Musluman,¹ Haci Mustafa Ozdemir⁴

¹Department of Neurosurgery, University of Health Sciences, Sisli Hamidiye Etfal Training and Research Hospital, Istanbul, Turkey

²Department of Physical Medicine and Rehabilitation, University of Health Sciences, Sisli Hamidiye Etfal Training and Research Hospital, Istanbul, Turkey

³Department of Neurosurgery, Suleyman Demirel University, Faculty of Medicine, Isparta, Turkey

⁴Department of Orthopaedics, University of Health Sciences, Sisli Hamidiye Etfal Training and Research Hospital, Istanbul, Turkey

Abstract

Objectives: Intradiscal ozone treatment is a minimally-invasive method that can be applied to patients who have low back pain and do not respond to conservative treatment. This retrospectively designed study aimed to evaluate its clinical efficacy, adverse effects, or complication rates.

Methods: Patients with lumbar degenerative disc disease (LDDD) who underwent intradiscal O₂-O₃ treatment between January 2016 and April 2018 were included in the study. Pain and disability levels were assessed at pre-injection, 1-month and 1-year post-injection periods using visual analog scale (VAS) and Oswestry Disability Index (ODI), respectively.

Results: A total of 520 patients (270 males and 250 females) with the mean age of 38.9±5.7 years included in the study. First-month and 1st-year post-injection VAS and ODI scores were significantly lower than pre-injection scores (p<0.001). Remarkable VAS score reduction (more than 50%) was found in 60.2% of patients at 1st month and in 52.9% of patients at the 1st year. No important side effects recorded.

Conclusion: Intradiscal ozone therapy applied together with the epidural steroid treatment, one of the percutaneous application techniques for the treatment of low back pain related to LDDD, has successful outcomes, clinical efficacy, and low rate of side effects, and thus, is one of the methods that should be considered before surgery when appropriate patients.

Keywords: Low back pain; ozone chemonucleolysis; percutaneous intradiscal treatment.

Please cite this article as "Kilic M, Ercalik T, Ozdemir B, Yilmaz I, Oguzoglu AS, Aydin L, et al. Lumbar Intradiscal Ozone Chemonucleolysis Applied Together with the Epidural Steroid Treatment. Med Bull Sisli Etfal Hosp 2021;55(2):203–209".

Low back pain is one of the most common causes of disability that causes economic loss by affecting social and work life.^[1] About 85% of all people experience low back pain at least once in their lifetime.^[2] Of the patients with low back pain, 10–15% has degenerative pathologies originating from specific nerve roots (lumbar disc

herniation [LDH], and spinal stenosis) while the remaining 85% are diagnosed as "non-specific low back pain.^[3]" While the majority of patients recover with conservative treatment or without treatment, 37–54% of patients still have pain after 1 year.^[4] Minimally invasive methods can be utilized for patients not responding to standard

Address for correspondence: Mustafa Kilic, MD. Saglik Bilimleri Universitesi Sisli Hamidiye Etfal Egitim ve Arastirma Hastanesi Norosirurji Klinigi, Istanbul, Turkey

Phone: +90 212 373 50 00 **E-mail:** kilicnrs@gmail.com

Submitted Date: May 19, 2020 **Accepted Date:** July 22, 2020 **Available Online Date:** July 02, 2021

©Copyright 2021 by The Medical Bulletin of Sisli Etfal Hospital - Available online at www.sislietfaltip.org

OPEN ACCESS This is an open access article under the CC BY-NC license (<http://creativecommons.org/licenses/by-nc/4.0/>).



conservative treatments to avoid or postpone surgery. Intradiscal ozone chemonucleolysis (IOC), one of such methods in use since the 1990s, is being performed at increasing rates due to its clinical efficacy, low side effects, and low cost.^[5]

Ozone is present naturally in the atmosphere and it is a strong oxidizing gas. Several studies have shown that it is safe in proper doses.^[6] It has anti-inflammatory, analgesic, and antiseptic properties. Its main mechanism of action is through reducing water retention by breaking the glycosaminoglycan chains in the nucleus pulposus, thereby reducing the volume of the herniated part by dehydration.^[7] Thus, the compression effect of disc hernia is reduced and the symptoms can be relieved. Another mechanism of action is reducing the inflammation around affected nerve root through its anti-inflammatory properties. The IOC is safely delivered as a mixture of O₂-O₃ at non-toxic doses (1–40 mg/mL). It is performed under the guidance of computerized tomography (CT) or fluoroscopy, and several authors recommend application of ozone in combination with periganglionic steroid and local anesthetics.^[6]

In this study, we aimed to retrospectively examine the data for a group of 520 patients who underwent intradiscal ozone treatment due to radicular or low back pain related to lumbar degenerative disc disease (LDDD) to evaluate the clinical efficacy, adverse effects, and complication rates of the treatment.

Methods

A total of 597 patients who underwent the intradiscal O₂-O₃ treatment between January 2016 and April 2018 were initially enrolled in the study. These patients had available records of pretreatment and 1-month post-treatment data. Among these, those with accessible through phone 1 year after the treatment were included in this study. The assessment of pain scores and disability was performed at pre-injection and 1-month and 1-year post-injection periods using visual analog scale (VAS) and Oswestry Disability Index (ODI), respectively. Written informed consent describing the injection, benefits, and complications was obtained from all patients before the procedure. The study was approved by the local ethics committee of Sisli Hamidiye Etfal Training and Research Hospital (17/04/2018, Number:1965).

Patients

Inclusion criteria for IOC were the presence of (1) axial and/or radicular low back pain persistence for at least last 3 months and unresponsive to previous conservative treatments (Patients with medical and physical therapy were

included, with the exception of any other interventional process procedures), (2) LDDD associated with clinical features based on the medical history, clinical examination, and lumbar magnetic resonance imaging (MRI) findings, (3) protrusion-level discopathy in MRI findings, and (4) VAS score of >4.

The exclusion criteria were determined as glucose-6-phosphate dehydrogenase (G6PDH) deficiency, pregnancy, hemorrhagic diathesis, systemic infection, motor deficit, history of lumbar surgery, calcification of discs, and bulging, extrusion, and sequestration in MRI findings.

Procedure

The IOC was performed under sterile aseptic conditions through fluoroscopic guidance (BV Pulsera, Philips Corp., Amsterdam, Netherlands). During the procedure patients were monitored continuously. A pillow was placed under the abdomen for flattening the lumbar lordosis in the prone position. The injection area was cleaned in accordance with the asepsis/antisepsis rules. After the determination of the level with fluoroscopy, access to inner part of the discs was achieved ipsilaterally with the 22 gauge 20 cm length spinal needle with an angle of about 30–45 degrees from 10 cm to 12 cm lateral of the midline through posterolateral approach under antero-posterior (AP) and lateral fluoroscopic controls. Turkozone blue S was used as ozone generator. A mixture of 5–10 mL of O₂-O₃ containing 40 mg/mL O₃ was administered intradiscally. In addition, a mixture of 1 cc methylprednisolone and 1 cc 0.05% bupivacaine was injected into the foraminal region (Fig. 1). All procedures were performed by an experienced neurosurgeon. After the procedure, vital signs were observed cautiously for 1 h. Patients were discharged with 3 days of home rest and antibiotherapy.

Assessment Parameters

Patients' demographic data and the pain and disability scores at pre-injection and 1-month controls were retrieved from the hospital records. Pain and disability scores were evaluated using VAS and ODI, respectively. The patients were called out for a follow-up visit 1 year after the IOC and VAS and ODI evaluations were carried out during the visit.

Statistical Analysis

Statistical analysis was performed with SPSS 15.0 for Windows. Descriptive statistics were expressed with numbers and percentages for categorical variables; mean, standard deviation, minimum, and maximum values for the numerical variables. Since parametric test conditions were not met in the dependent groups, Friedman Analysis was used for comparisons of multiple groups. Wilcoxon test

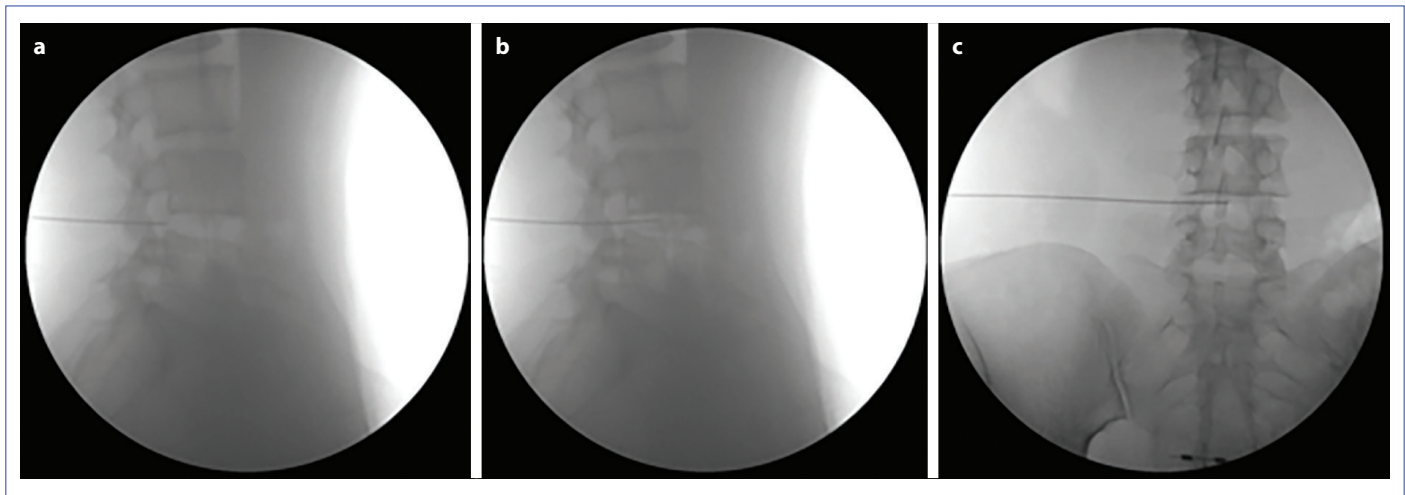


Figure 1. Intradiscal administration of intradiscal ozone chemonucleolysis through posterolateral approach under lateral (**a and b**) and antero-posterior (**c**) fluoroscopic controls.

was used for subgroup analyses. Statistical significance was accepted as $p < 0.05$.

Results

Medical records of 597 patients had been assessed. Of these, 542 patients had completed 1 year after the procedure and were accessible through phone call. Twenty-two patients were excluded because of having lumbar spinal surgery during that time. Remaining 520 patients were included in the final analyses of the study. There were 270 males and 220 females with the overall mean age of 38.9 ± 5.7 years. The procedure was applied at only single level for 401 patients and two levels for 119 patients. Descriptive parameters are summarized in Table 1.

Table 1. Descriptive parameters for patients		
	Mean \pm SD (Min-Max)	
	n	%
Age	38.9 \pm 5.5 (29–56)	
Gender		
Male	270	51.9
Female	250	48.1
Level of LDDD		
1	401	77.1
2	119	22.9
Interval		
L3–4	142	27.3
L4–5	236	45.4
L5–S1	70	13.5
L3–4+L4–5	19	3.7
L4–5+L5–S1	53	10.2

LDDD: Lumbar degenerative disc disease; SD: Standard deviation.

One-month and 1-year post-injection VAS and ODI scores were significantly lower than those with the pre-injection scores ($p < 0.001$ for both) (Table 2, Figs 2, 3). However, VAS and ODI scores at 1 year were significantly higher compared to 1-month scores ($p < 0.001$). Reduction in VAS scores by 50% or more was found in 60.2% and 52.9% of the patients at 1-month and 1-year after IOC assessments, respectively (Tables 3 and 4).

It was found that 17 patients had experienced hypotension and six patients had experienced hypoglycemia during the procedure. In these patients procedure was postponed and successfully performed 1 week later.

Interestingly, although an evaluation of the disc volumes had not been intended in our study, we have observed decreases in the dimensions of the herniation on some patients. Figure 4 shows the results of lumbar MRI, which

Table 2. Comparison of the VAS and ODI scores at different time points		
	Mean \pm SD	Min-Max
VAS		
Pre-injection	71.1 \pm 15.5	40–100
1-month post-injection	34.3 \pm 21.0	0–80
1-year post-injection	37.7 \pm 21.8	0–90
p	<0.001	
ODI		
Pre-injection	61.0 \pm 15.4	20–90
1-month post-injection	32.2 \pm 16.8	8–80
1-year post-injection	35.4 \pm 16.8	10–80
p	<0.001	

ODI: Oswestry Disability Index; SD: Standard deviation; VAS: Visual analog scale.

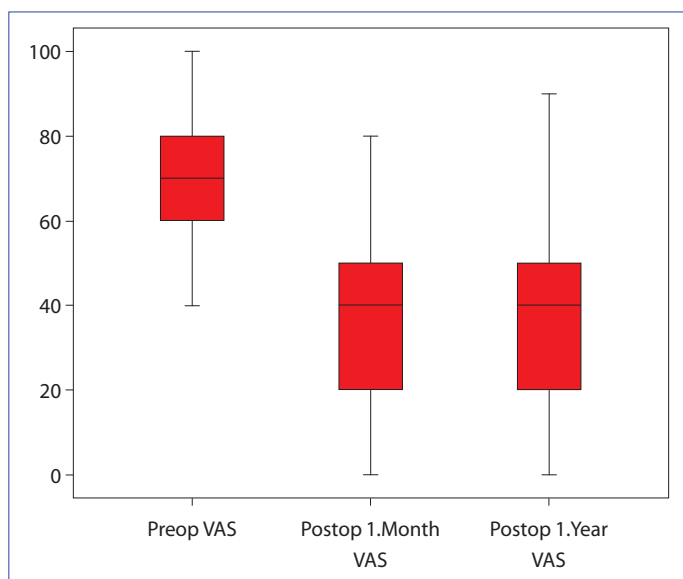


Figure 2. Changes in VAS scores during the study period.

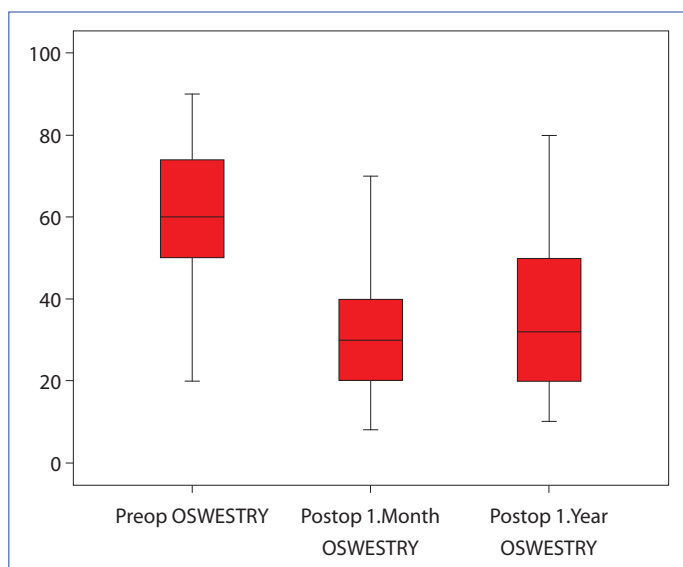


Figure 3. Changes in Oswestry scores during the study period.

were obtained during their follow-up for reasons other than this study and we were unexpectedly able to access. We include these results as an example of volume reduction and its effect on the pressure at nerve root in these patients.

Discussion

Minimally invasive percutaneous techniques are increasingly more preferred in the treatment of LDH-induced pain due to short-term hospitalization, fewer side effects, and elimination of post-operative scar formation, which is the most common cause of pain recurrence after surgery. Intradiscal O₂-O₃ therapy is one of those techniques and has good success rates similar to other chemo-nucleic treat-

Table 3. Changes in VAS and Oswestry

	n	%
Pre-op VAS-post-op 1 month VAS		
Decreasing	446	85.8
Increasing	0	0.0
Content	74	14.2
Pre-op VAS-pos-top 1 year VAS		
Decreasing	405	77.9
Increasing	0	0.0
Constant	115	22.1
Pre-op Oswestry-post-op 1 month Oswestry		
Decreasing	425	81.7
Increasing	9	1.7
Constant	86	16.5
Pre-op Oswestry-post-op 1 year Oswestry		
Decreasing	420	80.8
Increasing	27	5.2
Constant	73	14.0

ODI: Oswestry disability index; VAS: Visual analog scale.

Table 4. Ratios of patients with 50% and 80% or more improvement according to VAS and Oswestry

	n	%
VAS 1 month ≥%50	313	60.2
VAS 1 month ≥%80	126	24.2
VAS 1 year ≥%50	275	52.9
VAS 1 year ≥%80	104	20.0
ODI 1 month ≥%50	311	59.8
ODI 1 month ≥%80	39	7.5
ODI 1 year ≥%50	242	46.5
ODI 1 year ≥%80	21	4.0

ODI: Oswestry disability index; VAS: Visual analog scale.

ments. The advantages of this technique are less invasive and absence of allergic anaphylactic reaction risk. Another advantage of this technique is that ozone is an antiseptic and the risk of infection is very low.

It has been reported that the mechanism of LDH-associated radicular pain involves both mechanical and biochemical factors.^[4] It is thought that the efficacy of Internet of things (IOT) in LDH-induced low back pain is through the reduction of mechanical stress and the effects on downstream biochemical pathways. These effects include the disruption of inflammatory prostaglandin cascade, prevention of tissue hypoxia with increased O₂ concentration, repair of the damaged disc with activation of fibroblastic cells, and most importantly the reduction of mechanical pressure by reducing disc volume through preventing water retention.^[6]

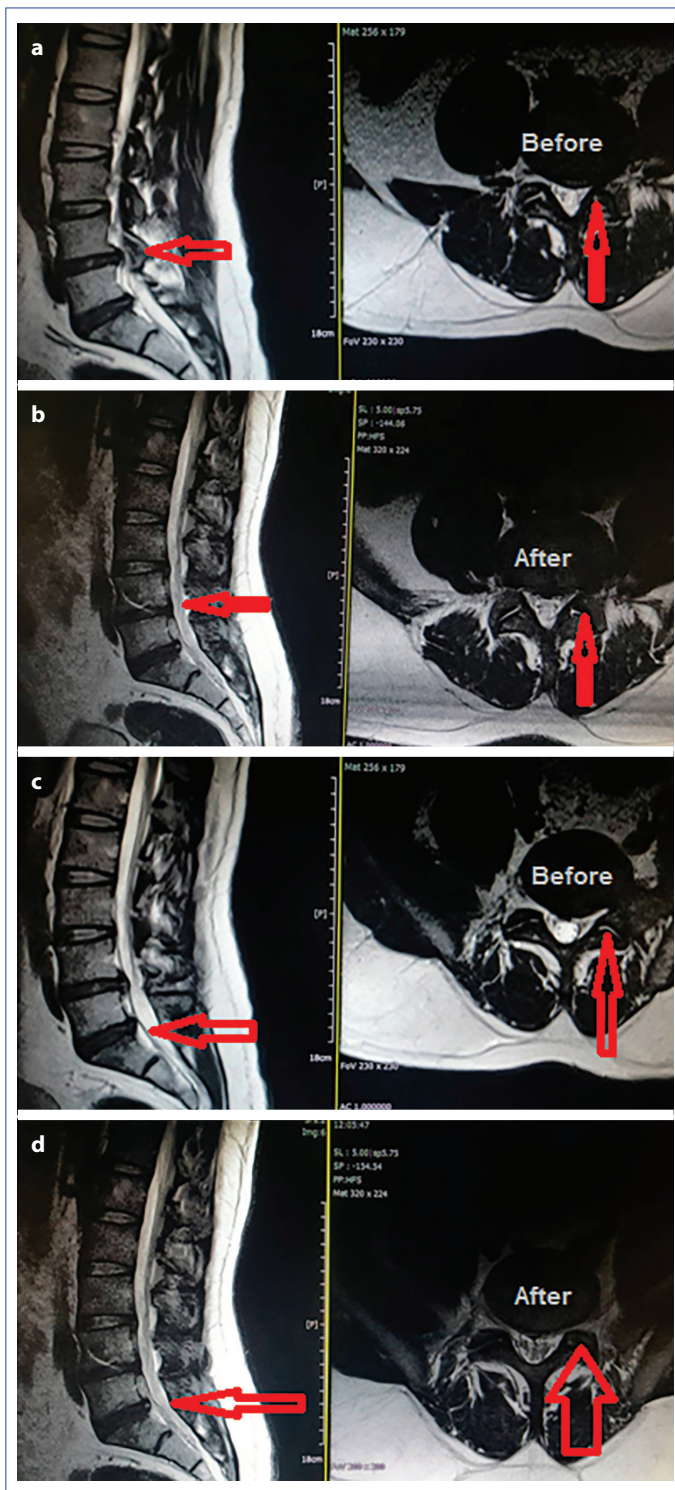


Figure 4. The magnetic resonance imaging images before (a) and after (b) the IOC procedure at level L4-L5 from the sagittal (left) and axial (right) views and before (c) and after (d) the intradiscal ozone chemonucleolysis procedure at level L5-S1 from the sagittal (left) and axial (right) views are shown as an example of the volume reduction and its effect on the pressure at nerve root.

In this retrospective study, pain and disability parameters were evaluated in short- and long-term after IOT and per-

iganglionic steroid administration. Our results have shown that this procedure was significantly beneficial and the side effects were low.

Several previous studies have reported successful short- and long-term outcomes with IOT.^[8-11] Success rates vary between 65% and 85% depending on factors associated with the study designs such as patient groups, administration techniques, outcome criteria used, and statistical differences.^[9,12,13] For example, success rate was found to be 85% in a study evaluating 2.900 patients by Muto et al., which was 66.4% at 1-month in our study. They considered a three-point reduction in the VAS score as a successful result; however, we used 50% reduction in the VAS scores as success criterion, which is much harder to achieve.^[10] Similarly, the modified MacNab criteria used as success criteria in other studies make a rough assessment on a scale of 4 points.^[12,14]

The previous studies revealed the data that could guide the selection of patients for IOT. A study evaluating the effect of disk morphology on success rate found that the best results were in bulging discs compared to the extrusion or protrusion.^[15] In the present study, we included only protruded discs, therefore, did not make such an assessment. In a retrospective study of 621 patients, Oder et al. investigated the relationship between the MRI findings and the presence of degenerative changes and the association between success rates and history of surgery, age, and gender in a retrospective study including 621 patients. The authors found that better outcomes were achieved in patients under the age of 50 years and inadequate response was obtained in patients with history of surgery.^[16] In our study, the patients were selected in accordance with these results and they had no previous surgery at same LDD level, and the mean age was 39 years. Thus, since patient selection for IOT in our clinic was performed in the light of this data, our results were foreseeable. In a previous study; the effect of having a spinal surgery on the results of intradiscal O_2-O_3 treatment was investigated. Although the results are better in patients who have not had surgery, very successful results have also been achieved in patients who have undergone spinal surgery.^[17]

In our study, along with the intradiscal O_2-O_3 administration to the patients, we administered periganlionic steroid and local anesthetics. While there are studies arguing that it is sufficient to administer intradiscal O_2-O_3 only, several other studies have proposed a combination therapy.^[11,12,14,18] The purpose of this application is to activate the anti-inflammatory processes on the nerve root for the achievement of analgesia and wellness earlier while influencing the mechanical processes through the intra-

discal effect. IOT also provides a longer duration of action through the reduction of mechanical stress by reducing the volume of the disc. In a randomized, prospective, and controlled trial, the addition of IOT to the periganglionic steroid treatment was shown to be more effective in the long-term (6 months).^[15] Our 1-month results were better than 1-year results, which confirm the additive effect of the combined application.

Buric et al. assessed the effect of IOT on disc volume with MRI in 108 patients and reported a volume reduction of 79%.^[8] Similarly, a significant volume reduction was detected in the 6-month assessment of 283 patients with CT.^[19] Muto et al. showed a 63% reduction in disk volume at month 18 while Bruno et al. reported a significant volume reduction at year 3.^[12,20] Due to the design of our study, evaluation of the disc volumes could not be done for the patients in our study but our serendipitous clinical observations confirmed this effect.

The overall rate of complications related with ozone treatment is 0.1%.^[5] Two meta-analyses reported that it is safe and effective.^[4,5] Procedure-related complications of IOT in lumbar discopathies have been reported in literature as case reports. Giudice et al. reported a case of bilateral vitreo-retinal hemorrhage due to high-volume application.^[21] In addition, cases of thunderclap headache due to intrathecal puncture, paraesthesia, and hypoesthesia have also been described.^[22,23] Corea et al. reported a case of vertebral stroke.^[23] Infections are rare due to the antiseptic nature of the ozone gas itself, a case of iatrogenic spondylodiscitis and a case of fetal septicemia were reported in the literature probably due to inadequate attention to asepsis/antiseptic rules.^[24-26] No major complications were observed in our series of 520 patients. Minor procedural complications such as hypotension and hypoglycemia were observed, and the treatments of these patients were successfully completed during the follow-up.

Conclusion

Percutaneous techniques are alternative treatment methods that should be considered before surgery in the treatment of LDDD-related low back pain, especially in young patients and the patients without neurological deficit. The IOT is one of such techniques and has been performed in a series of patients with successful results similar to the previous studies; no significant side effects have been observed. The retrospective design of the study and the absence of a control group for comparison are two limitations of this study. The homogeneous patient group, long-term follow-up, and the significant results are the strengths of this study. Further controlled studies on a larger group of

patients involving specific pathologies are needed to investigate the issues related to efficacy, optimal dosage, determination of volume, and application technique.

Disclosures

Ethics Committee Approval: The study was approved by the local ethics committee of Sisli Hamidiye Etfal Training and Research Hospital. (Date: 17/04/2018, Number:1965).

Peer-review: Externally peer-reviewed.

Conflict of Interest: None declared.

Authorship Contributions: Concept – M.K., T.E.; Design – M.K., T.E.; Supervision – H.M.O., A.Y.; Materials – M.K., T.E.; Data collection &/or processing – A.S.O., L.A.; Analysis and/or interpretation – B.S., A.M.M.; Literature search – T.E.; Writing – M.K.; Critical review – A.Y., A.M.M.

References

1. Bener A, Dafeeah EE, Alnaqbi K. Prevalence and correlates of low back pain in primary care: what are the contributing factors in a rapidly developing country. *Asian Spine J* 2014;8:227–36.
2. Goubert L, Crombez G, De Bourdeaudhuij I. Low back pain, disability and back pain myths in a community sample: prevalence and interrelationships. *Eur J Pain* 2004;8:385–94.
3. Foster NE. Barriers and progress in the treatment of low back pain. *BMC Med* 2011;9:108.
4. Magalhaes FN, Dotta L, Sasse A, Teixeira MJ, Fonoff ET. Ozone therapy as a treatment for low back pain secondary to herniated disc: a systematic review and meta-analysis of randomized controlled trials. *Pain Physician* 2012;15:E115–29.
5. Steppan J, Meaders T, Muto M, Murphy KJ. A metaanalysis of the effectiveness and safety of ozone treatments for herniated lumbar discs. *J Vasc Interv Radiol* 2010;21:534–48.
6. Giurazza F, Guarnieri G, Murphy KJ, Muto M. Intradiscal O2O3: rationale, injection technique, short- and long-term outcomes for the treatment of low back pain due to disc herniation. *Can Assoc Radiol J* 2017;68:171–7.
7. Murphy K, Elias G, Steppan J, Boxley C, Balagurunathan K, Victor X, et al. Percutaneous treatment of herniated lumbar discs with ozone: investigation of the mechanisms of action. *J Vasc Interv Radiol* 2016;27:1242–50.
8. Buric J, Rigobello L, Hooper D. Five and ten year follow-up on intradiscal ozone injection for disc herniation. *Int J Spine Surg* 2014;8:17.
9. Gallucci M, Limbucci N, Zugaro L, Barile A, Stavroulis E, Ricci A, et al, Masciocchi C. Sciatica: treatment with intradiscal and intraforaminal injections of steroid and oxygen-ozone versus steroid only. *Radiology* 2007;242:907–13.
10. Muto M, Ambrosanio G, Guarnieri G, Capobianco E, Piccolo G, Annunziata G, et al. Low back pain and sciatica: treatment with intradiscal-intraforaminal O(2)-O (3) injection. Our experience. *Radiol Med* 2008;113:695–706.

11. Zhang Y, Ma Y, Jiang J, Ding T, Wang J. Treatment of the lumbar disc herniation with intradiscal and intraforaminal injection of oxygen-ozone. *J Back Musculoskelet Rehabil* 2013;26:317–22.
12. Muto M, Andreula C, Leonardi M. Treatment of herniated lumbar disc by intradiscal and intraforaminal oxygen-ozone (O₂-O₃) injection. *J Neuroradiol* 2004;31:183–9.
13. Paoloni M, Di Sante L, Cacchio A, Apuzzo D, Marotta S, Razzano M, et al. Intramuscular oxygen-ozone therapy in the treatment of acute back pain with lumbar disc herniation: a multi-center, randomized, double-blind, clinical trial of active and simulated lumbar paravertebral injection. *Spine (Phila Pa 1976)* 2009;34:1337–44.
14. Andreula CF, Simonetti L, De Santis F, Agati R, Ricci R, Leonardi M. Minimally invasive oxygen-ozone therapy for lumbar disk herniation. *AJNR Am J Neuroradiol* 2003;24:996–1000.
15. Perri M, Marsecano C, Varrassi M, Giordano AV, Splendiani A, di Cesare E, et al. Indications and efficacy of O₂-O₃ intradiscal versus steroid intraforaminal injection in different types of disco vertebral pathologies: a prospective randomized double-blind trial with 517 patients. *Radiol Med* 2016;121:463–71.
16. Oder B, Loewe M, Reissegger M, Lang W, Ilias W, Thurnher SA. CT-guided ozone/steroid therapy for the treatment of degenerative spinal disease--effect of age, gender, disc pathology and multi-segmental changes. *Neuroradiology* 2008;50:777–85.
17. Kılıç M, Erçalık T. The effect of lumbar spinal surgery history on intradiscal O₂-O₃ treatment results in patients with lumbar disk herniation. *Sisli Etfal Hastan Tip Bul* 2019;53:148–53.
18. Bonetti M, Fontana A, Cotticelli B, Volta GD, Guindani M, Leonardi M. Intraforaminal O(2)-O(3) versus periradicular steroidal infiltrations in lower back pain: randomized controlled study. *AJNR Am J Neuroradiol* 2005;26:996–1000.
19. Lehnert T, Naguib NN, Wutzler S, Nour-Eldin NE, Bauer RW, Kerl JM, et al. Analysis of disk volume before and after CT-guided intradiscal and periganglionic ozone-oxygen injection for the treatment of lumbar disk herniation. *J Vasc Interv Radiol* 2012;23:1430–6.
20. Bruno F, Smaldone F, Varrassi M, Arrigoni F, Barile A, Di Cesare E, et al. MRI findings in lumbar spine following O₂-O₃ chemiodiscolysis: A long-term follow-up. *Interv Neuroradiol* 2017;23:444–50.
21. Lo Giudice G, Valdi F, Gismondi M, Prosdocimo G, de Belvis V. Acute bilateral vitreo-retinal hemorrhages following oxygen-ozone therapy for lumbar disk herniation. *Am J Ophthalmol* 2004;138:175–7.
22. Devetag Chalaupka F, Caneve G, Mauri M, Zaiotti G. Thunderclap headache caused by minimally invasive medical procedures: description of 2 cases. *Headache* 2007;47:293–5.
23. Ginanneschi F, Cervelli C, Milani P, Rossi A. Ventral and dorsal root injury after oxygen-ozone therapy for lumbar disk herniation. *Surg Neurol* 2006;66:619–20.
24. Corea F, Amici S, Murgia N, Tambasco N. A case of vertebrasilar stroke during oxygen-ozone therapy. *J Stroke Cerebrovasc Dis* 2004;13:259–61.
25. Gazzeri R, Galarza M, Neroni M, Esposito S, Alfieri A. Fulminating septicemia secondary to oxygen-ozone therapy for lumbar disc herniation: case report. *Spine (Phila Pa 1976)* 2007;32:E121–3.
26. Vanni D, Galzio R, Kazakova A, Pantalone A, Sparvieri A, Salini V, et al. Intraforaminal ozone therapy and particular side effects: preliminary results and early warning. *Acta Neurochir (Wien)* 2016;158:491–6.