

Short-term results of novel constrained total hip arthroplasty

Thomas Pace,^{1,2} Stephen Finley,¹
Rebecca Snider,¹ Jayme Looper,³
Stephanie Tanner¹

¹Department of Orthopedic Surgery, Greenville Health System, SC; ²University of South Carolina School of Medicine, West Columbia, SC; ³Department of Bioengineering, Clemson University, SC, USA

Abstract

Constrained acetabular components have only been recommended as a salvage option for the persistently unstable total hip arthroplasty (THA), due to limited range of motion and less than satisfactory component failure rates. This is a retrospective review of 137 patients with 154 consecutive primary constrained THAs performed between November 2003 and August 2007. We reviewed serial radiographs, postoperative complications, groin/thigh pain, and compared preoperative and postoperative Harris Hip Scores. With a mean follow-up of 6 years, there was 1.9% dislocation rate, 0% component failure rate, and 2.6% infection rate. Seven patients reported continued groin pain, and three had continued thigh pain. One patient showed radiographic evidence of 1 mm polyethylene wear. Radiographic review showed no evidence of osteolysis or stem subsidence. Harris Hip Scores improved from a mean of 68.8 (range 58-87) preoperatively to 98.9 (range 65-100) at final clinical assessment. This constrained acetabular prosthesis had a dislocation rate of less than 2%, with 0% component failure rate at a minimum of 2 years of follow-up suggesting this prosthesis may be a viable alternative for patients at risk for instability or those known to have recurrent instability.

Introduction

Instability following total hip arthroplasty (THA) is a well established complication. The historical rates quoted in the literature range widely from 0-10% for primary THA to 10-25% for revision arthroplasty.^{1,3} Approximately two thirds of unstable THAs may be rendered stable with conservative measures, but the persistently unstable hip poses a very difficult situation for the orthopaedic surgeon. If the etiology of the instability is identified, such as

component malposition, it should be addressed yielding success rates of 70-80%. The surgical success rates for recurrent instability of unknown etiology are even lower at 40-50%.⁴

Constrained acetabular liners are often used in this clinical scenario yielding short- to intermediate-term stability as high as 97% for recurrent dislocations of unknown etiology.⁵ Recent intermediate-term reports for traditional constrained components have documented persistent instability and increased implant failure rates in a number of patients causing caution and concern regarding their use and longevity.^{6,7} The limited range of motion (ROM) associated with implant constraint has been implicated in both aseptic loosening and catastrophic failure from impingement with increased interfacial stresses in addition to concerns for osteolysis and increased polywear from use of thin polyethylene liners, multiple polyethylene articulations, and ultra high molecular weight polyethylene (UHMWPE) liner use.^{8,9} The published ROM for the tripolar constrained acetabular components used most heavily in these studies [S-ROM® (DePuy, Warsaw, IN, USA); Osteonics Omnifit® (previously Osteonics Corporation, Allendale, NJ, USA and currently Stryker Orthopaedics, Mahwah, NJ, USA) and the Trident® (Stryker Orthopaedics, Mahwah, NJ, USA) had mean flexion of 82-102°.^{5,7,10}

The literature is sparse however, representing the newer constrained designs that tout increased ROM. Most recently Berend *et al.* published on a constrained component with ROM to 110° that resulted in 98.8% stability for the entire cohort, with only one dislocation yielding the cohort of recurrent dislocators 92% stable at short term follow-up.¹¹ Burroughs first described a novel liner design in 2001 that displayed up to 137° of flexion by placing recesses in the constraining polyethylene liner, thus decreasing impingement. The placement of the two recesses improves flexion, internal rotation, extension and external rotation to values that approximate standard THAs.¹²

Background for this study was initiated when the senior author noted a 9.8% rate of single and recurrent dislocation when using the Natural stem (Zimmer, Warsaw, IN, USA) for primary THAs. This tapered, titanium, collared, split tip, proximally porous ingrowth, uncemented femoral stem otherwise had a low rate of thigh pain, proximal femoral bone atrophy, and stem loosening. These results were equivalent amongst both older and younger patients. The senior author sought to address this instability concern using the novel constrained liner (Zimmer Longevity® constrained liner).¹²

In our institution, prior to the present study presented in the current manuscript, we used the same femoral stem implant design and

Correspondence: Thomas Pace, Department of Orthopedic Surgery, Greenville Health System, HSAB room 239, 701 Grove Road 29605-4210, SC, USA.

Tel.: +1.864.455.7912 - Fax: +1.864.455.8404.

E-mail: tpace@ghs.org

Key words: Arthroplasty; osteoarthritis; instability.

Contributions: TP, SF, BS, ST, data analysis and collection, manuscript writing/preparation; JL, manuscript writing/preparation.

Conflict of interest: the authors declare no potential conflict of interest.

Conference presentation: the paper was presented at: South Carolina Orthopaedic Association Annual Meeting, July 31st - August 3rd, 2014, Kiawah Island, SC, USA; Eastern Orthopaedic Association's Annual Meeting, October 22-25, 2014, Amelia Island, FL, USA.

Received for publication: 23 October 2014.

Revision received: 14 April 2015.

Accepted for publication: 5 June 2015.

This work is licensed under a Creative Commons Attribution NonCommercial 3.0 License (CC BY-NC 3.0).

©Copyright T. Pace *et al.*, 2015

Licensee PAGEPress, Italy

Orthopedic Reviews 2015; 7:5779

doi:10.4081/or.2015.5779

reported an unusually high primary hip dislocation rate of 6%. The femoral stem was functioning superbly with no aseptic stem revisions but the instability rate was concerning and thus the addition of the constrained liner to the otherwise well-functioning femoral stem. This study will present the short term results of 154 consecutive primary total hip arthroplasties performed by a single surgeon with this design of constrained prosthesis. The short term survival of this implant is excellent and does not exhibit the postulated modes of failure secondary to increased interfacial stress typical of earlier generations of constrained hip cups.

Materials and Methods

Institutional Review Board approval was obtained for this retrospective review of clinical records, outcomes and radiographs of 137 patients with 154 consecutive primary constrained hip arthroplasties performed by the senior author between November 2003 and August 2007. All arthroplasties were performed through a posterolateral approach, and bilater-

al procedures were staged. Mean patient age was 64 (range 34-89 years), with the majority under the age of 65. Seventy-three of the patients were male, and eighty-five procedures were conducted on right hips. Osteoarthritis was the principal diagnosis in 149 hips, avascular necrosis in four, and one THA was done for fracture. Primary constrained THA patients with a minimum of two years of clinical and radiographic follow-up were included. The average follow-up was 6 years (range 2-10 years). The arthroplasty components utilized in each patient were identical, consisting of a press fit porous titanium acetabular shell (Zimmer Epsilon®) and modular tapered proximal in-growth femoral stem (Zimmer Natural Hip™ stem; Figure 1A). All acetabular shells, except one, were secured with a minimum of 1 screw. The constrained liner (Zimmer Longevity® Constrained Liner) utilized is remarkable due to the polyethylene cutouts, leading to extended cup geometry only

between the 11 and 1 o'clock position as well as the 4 and 8 o'clock position (Figure 1B). The polyethylene liner was highly cross-linked ultra high molecular weight polyethylene (UHMWPE) with an introitus smaller than the femoral head. The liner couples with a constraining ring that decreases its ability to deform, increasing the force required to dislocate the femoral head from the constrained liner. This makes the component unique in that it is a constrained THA with recesses strategically positioned to provide significant improvements in flexion, internal rotation, extension and external rotation while maintaining femoral head constraint. Dependent upon acetabular cup abduction and anteversion, the reported ROM of this construct is 111-137° of flexion, 21-45° internal rotation at 90° of flexion and 34-49° external rotation at 0° flexion before prosthetic impingement. This concomitantly reports 243% increased torque to dislocation compared to fully circumferen-

tial constrained components.^{12,13}

All surgeries were performed by the primary author (TP) and surgeries through a posterolateral approach with spine anesthesia. No leg immobilization was utilized post operatively and physical therapy was continued on all patients for 3-6 weeks following surgery. Warfarin was given orally for deep vein thrombosis/pulmonary embolism (DVT/PE) prophylaxis beginning the night of surgery and once the International Normalized Ratio (INR) was 1.2 or greater and stable, continuing a low 2 mg fixed oral dose regimen for one month without routine warfarin monitoring for patients assessed to be standard risk and a higher adjusted dose regimen (INR 2.0) for those patients assessed to be higher risk for a venous thrombotic event (VTE).

Radiographs were examined for changes indicating loosening or osteolysis within the zones designated by Gruen *et al.* and DeLee and Charney.^{14,15} Stem subsidence was evalu-

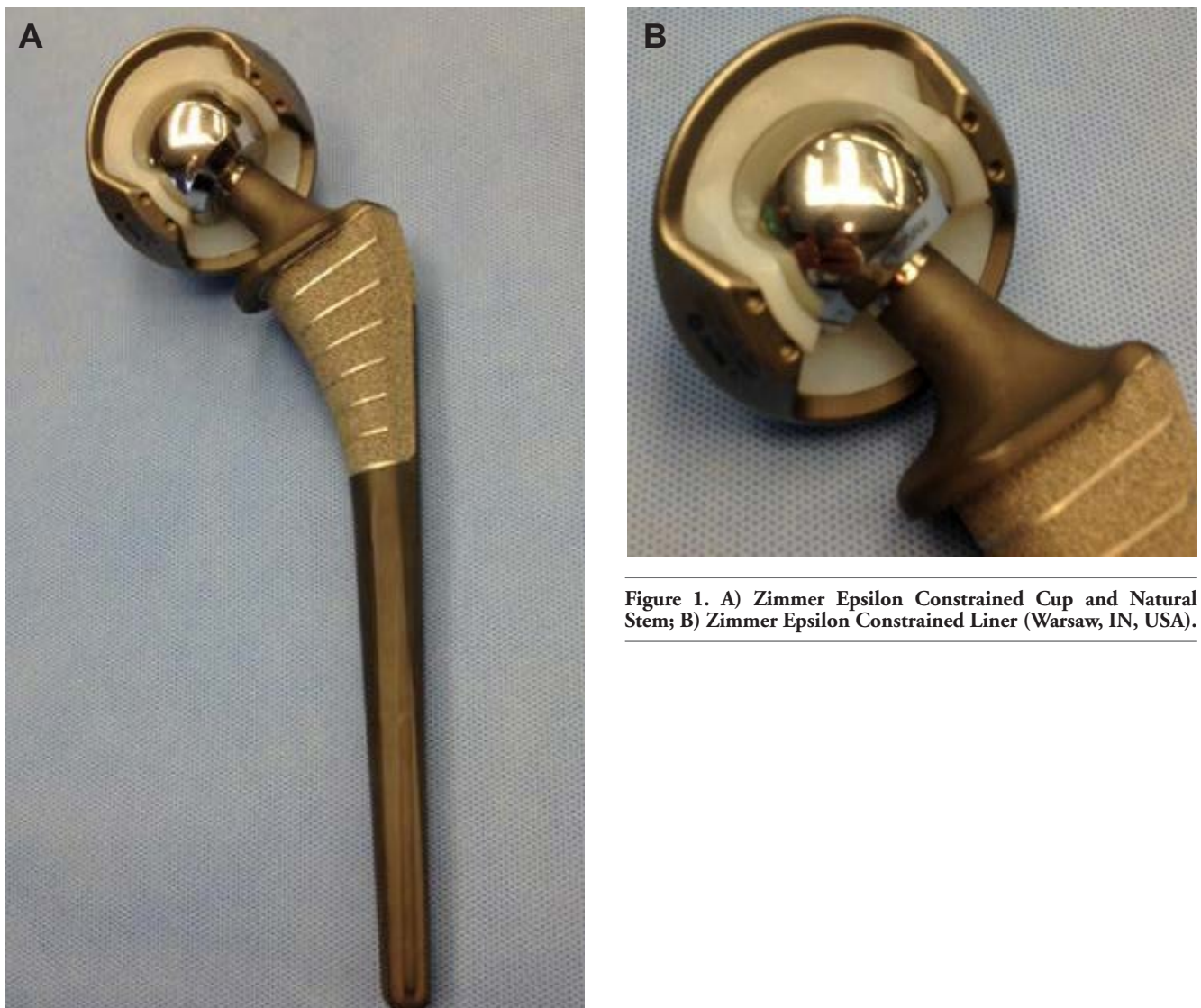

Figure 1. A) Zimmer Epsilon Constrained Cup and Natural Stem; B) Zimmer Epsilon Constrained Liner (Warsaw, IN, USA).

ated based on the measured distance from the greater trochanter to the lateral shoulder of the prosthesis, with change greater than 2 mm on sequential radiographs indicating subsidence.^{16,17} Pointed questioning was made regarding groin or thigh pain in addition to clicking or noise made by the hip with activity. Harris Hip Scores (HHS) were obtained on all hips prior to arthroplasty and at each yearly follow-up visit.

Results

The early survival of primary constrained total hip arthroplasties in this series is 99.4% for dislocation and 96.8% with revision for any reason denoting clinical failure. Five patients required revision, one due to multiple dislocations 4 months post primary surgery, three for fulminant deep infections, and one for persistent pain. Two acute post-op infections were treated with irrigation and debridement, retention of implants, and antibiotic suppression. The one recurrent dislocation that underwent revision surgery was less than 5 years from index surgery and did not have polyethylene wear analysis performed.

There were three additional patients who had dislocations that were closed reduced under anesthesia without subsequent evidence of instability. Three of the 4 dislocations were effectively reduced without operation by using the technique described by McPherson and et with the patient in the lateral position under fluoroscopy and conscious sedation.¹⁸

Seven patients (4.5%) reported continued groin pain, and three (1.9%) had continued thigh pain. With pointed questioning, sixteen patients (10.4%) reported asymptomatic positional clicking. There was a single non-displaced greater trochanter fracture that occurred after a fall from standing that healed uneventfully. One patient had asymptomatic 1 mm linear poly wear at 8.3 years not requiring any intervention. One patient had a non-fatal pulmonary embolism. There were no fatal PEs and one patient developed a symptomatic DVT without PE. Radiographic review revealed no evidence of osteolysis, or stem subsidence on anteroposterior and lateral radiographs. Calcar erosion was noted in 2 patients. Harris Hip Scores improved from a mean of 68.8 (range 58-87) preoperatively to 98.9 (range 65-100) at the last clinical assessment.

Discussion

Treatment of the unstable THA is problematic with disappointing results for revision surgery with both known and unknown etiologies. Constrained components are often used in revision settings for abductor deficiency, recurrent dislocations, instability of unknown etiology, intra-operative instability, or in the primary setting for neuromuscular and cognitive disorders. Except for a very sparse number of papers, the majority of the literature examine prior constrained components known to have significant limitations in range of motion and then only in the revision setting. (Table 1)^{4-9,11,12,16,17,19,20}

Among these studies Berend *et al.* reported 10-year follow-up on 667 constrained THAs, of which only 62 were primary arthroplasties. Overall, the dislocation rate was 17.5% but was 28.9% solely for the cohort of revisions done for recurrent instability. The overall long-term failure rate was 42.1%. The modes of failure were stratified into those attributable to failure of constraint (18.6% recurrent dislocation or component failure), failure due to increased constraint (10% aseptic loosening) and failure independent of constraint (13.5% infection, etc). It was noted that average time to failure due to the constrained component itself was 2.4 years.⁶ These results are less than satisfactory, but they are similar to results reported for non-constrained THAs in the revision setting for recurrent instability. Others report similar results for a similar tripolar constrained prosthesis previously used. Anderson reported 2.5 year follow-up on 21 similar constrained arthroplasties for recurrent instability and found 29% recurrence with an average of 10 months to recurrent dislocation. Non-progressive acetabular radiolucent lines were noted in four patients without associated clinical evidence of loosening.⁷

The tripolar components have fared better with Khan *et al.* demonstrating 97.1% stability at 2.7 years in 34 patients treated for recurrent instability. They used roentgen stereophotogrammetric analysis to demonstrate 1.06 mm of translation and 2.32° of rotation of acetabular components but excluded from this analysis the 4 patients revised for aseptic loosening of the cup (11.8%).⁵ Goetz *et al.* reported on a cohort of 56 patients treated with a constrained tripolar implant for recurrent disloca-

Table 1. Summary of literature review of novel and traditional constrained liners.

First author	Year	Prosthesis	Hips	Indication	Re-dislocation, %	Failure secondary to component, %	All revisions, %	Pre-op HHS	Post-op HHS	Length follow up, years
Berend ⁶	2005	Constrained tripolar	667	Mixed	17.5	10.9	42.1	-	-	10
Berend ⁶	2005	Constrained tripolar	128	Recurrent instability	28.9	-	-	-	-	10
Anderson ⁷	1994	Constrained tripolar	21	Recurrent instability	29	-	-	76	2.6	
Khan ⁵	2006	Constrained tripolar	34	Recurrent instability	2.9*	-	-	69	2.7	
Goetz ⁹	1998	Constrained tripolar	56	Recurrent instability	3.5	-	-	-	5.3	
Goetz ⁸	2004	Constrained tripolar	56	Recurrent instability	7	10	32	-	10	
Bremner ²⁰	2003	Constrained tripolar	101	Recurrent instability	6#	-	-	-	10.3	
Padgett ⁴	2004	Constrained tripolar	87	Recurrent instability	2.4	-	8.2	-	4.8	
Shrader ¹⁷	2003	Constrained tripolar	110	Instability and abductor deficiency [§]	0 [§]	3.6	8.2	62	76.4	-
Jones ¹⁶	2007	Constrained tripolar	81	-	1.2	1.2	-	-	2	
Guyen ¹⁹	2008	Constrained tripolar	389	Intraoperative or recurrent instability	0.7	7.9%	11	-	-	
Burroughs ¹²	2001	Novel	-	-	-	-	-	-	-	
Berend ¹¹	2006	Novel	81	Complex revision	1.2	-	-	-	0.75	
Pace	2013	Novel	129	Primary THA	1.9 [^]	0	2.6	68.8	98.9	5.3

HHS, Harris Hips Score; THA, total hip arthroplasty. *4/36 patients excluded for aseptic loosening of the cup (11.8%); #6% includes repeat dislocations, in addition to component failure; §only 79/110 were done for recurrent instability; ^the 3 dislocations did not require revision after closed reduction performed.

tion in 2 patients yielding 3.5% dislocation rate at 5.3 years. The 10.2-year follow-up was subsequently reported with an additional 2 dislocations, giving a 7% dislocation rate at intermediate follow-up. At the 10-year follow-up, they had also revised 3 femoral components (5%) and 2 acetabulums (4%) for aseptic loosening. One acetabulum was revised for osteolysis. Survival at 10.2 years was 90% with constrained component failure as the end point and 68% for all modes of failure.^{8,9} Bremner *et al.* presented 10.3-year follow-up on 101 tripolar constrained components and reported 6 dislocations/component failures (6%) and aseptic loosening in 6 acetabulums and 7 femoral stems with 2 hips showing pelvic osteolysis.¹⁸ Padgett *et al.* had a 2.4% dislocation rate at 4.8 years follow-up in 87 patients treated for recurrent dislocation, yet the tripolar design was still associated with an 8.2% revision rate with 2 revised for dislocation, 3 acetabular shells for

aseptic loosening and one liner for poly wear. There was no osteolysis found.⁴ Shrader *et al.* had no dislocations in 110 tripolar THAs performed for recurrent instability or abductor deficiency and had only 2 patients with subjective feelings of subluxation. Radiolucent lines were noted in 11 femoral stems and 15 acetabulums, with poly wear seen in 6 cups, yet only 4 required a revision for clinically loose components.¹⁷ Jones *et al.* had one dislocation and one avulsion of the cup from the pelvis in 81 tripolars at 2 year follow-up with 4 acetabulums and one femoral component showing radiolucent lines.¹⁶ Guyen *et al.* reviewed the failure of 43 tripolar implants in 34 patients performed at the Mayo Clinic. They stratified the modes of failure and found the average time to failure to be 2.4 years, with a total failure rate of 11% for the 389 tripolar constrained THAs performed there between 1997 and 2005.¹⁸

Table 1 summarizes reports using novel and traditional constraint implant designs with varying degrees of success with most of the component failures occurring before 2.5 years of follow up.^{4,16-20}

In 2001, Burroughs *et al.* published on a novel constrained liner that is similar to the component utilized in this study. They presented ROM and lever-out tests for this implant demonstrating significantly improved results over the components commonly in use.¹² Berend, presented a cohort of 81 similarly constrained THAs for complex revision and found 98.8% stability at 9 months.^{6,11} The prosthesis utilized had favorable mechanics based on use of a 36 mm non-skirted head in conjunction with a liner that is equatorially flat, increasing ROM to 110° of flexion compared to 90° with their previously used device as well as 30% increased lever-out strength. He did not report on findings of loosening but found that a *con-*

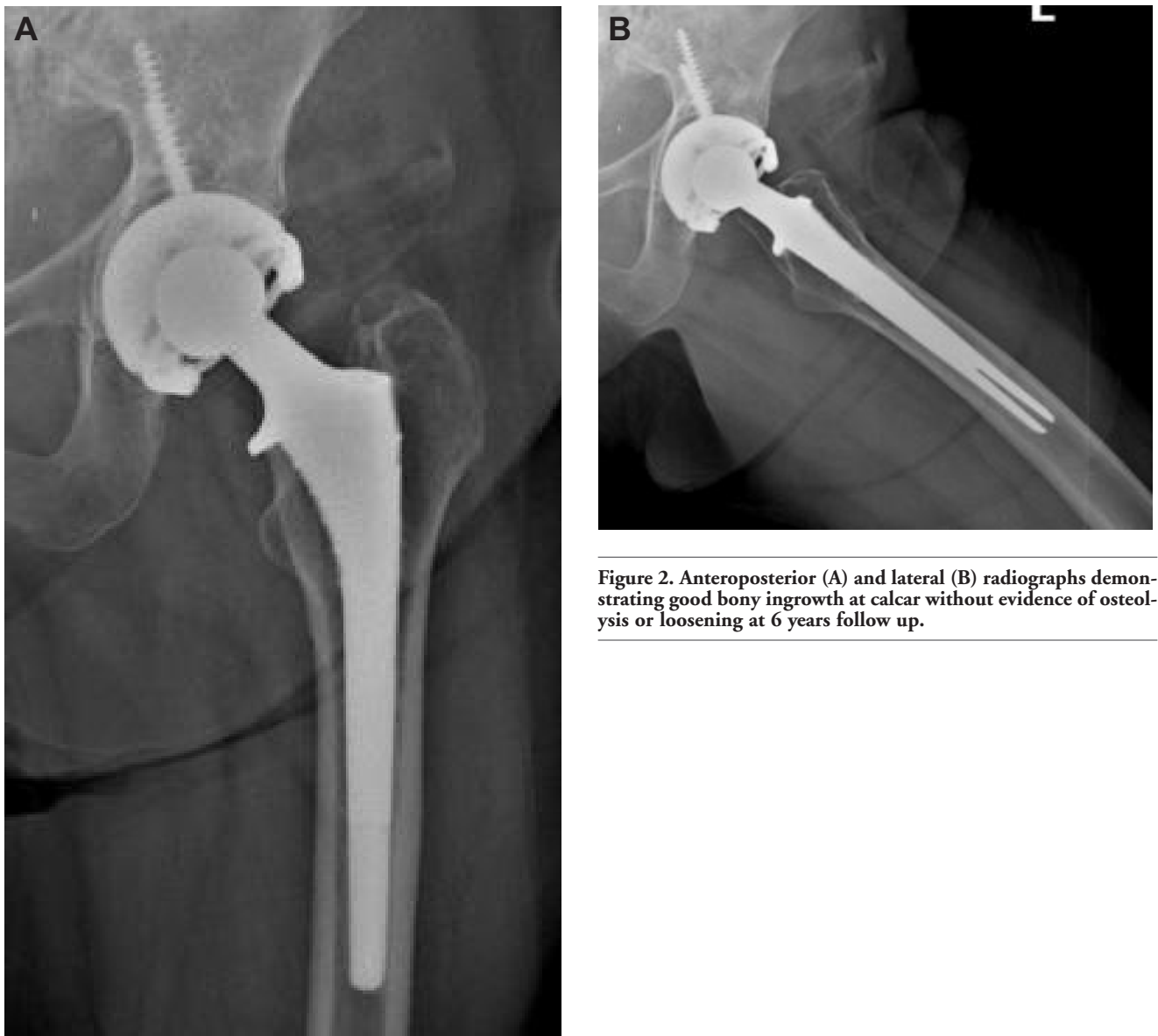

Figure 2. Anteroposterior (A) and lateral (B) radiographs demonstrating good bony ingrowth at calcar without evidence of osteolysis or loosening at 6 years follow up.

strained design can successfully achieve stability in difficult cases.¹¹

The short-term results in the current study are very promising with four dislocations (2.6%). One required revision surgery due to recurrent dislocations. The other three dislocations (1.9%) were closed reduced without subsequent instability. This is of interest as there are no reported or confirmed cases of closed reduction as previously described using a different constrained implant design¹⁸ of this implant found during the course of this literature search. The hip remained stable after closed reduction, indicating that the constraining mechanism was not sufficiently damaged to require imminent revision as recommended by Harman and Robertson.^{21,22} Furthermore, of the 154 implants, there were no revisions secondary to component failure. There is no radiographic evidence of aseptic cup loosening or osteolysis during early follow-up (Figure 2). This is clinically significant as the literature suggests the majority of constrained cup failures occur within two to three years of implantation. The use of highly cross-linked UHMWPE is an improvement over conventional UHMWPE with polywear and osteolysis.^{23,24} The favorable wear characteristics of highly cross-linked UHMWPE with larger heads make prosthetic longevity a more biomechanically feasible expectation.²⁴

The increased ROM gained from the recessed areas of the constrained liner likely further decreases impingement, resulting in

decreased interfacial stresses and lever-out phenomenon experienced by the implant.²⁵ The ability to use larger heads also provides a favorable head to neck ratio and increases the jump distance to further decrease the likelihood of significant impingement or dislocation.²⁶ The rate of positional hip clicking in this study was 10.4%. That could feasibly represent impingement of the neck on the constraining liner (Figure 3). This is quite similar to the 9.8% rate of dislocation using the same stem design with unconstrained cups.^{27,28} Patients in the current series with occasional positional clicking remain pain free without compromise in the function of their arthroplasties.

The incidence of groin and thigh pain (4.5% and 1.9%, respectively), which approximates the published incidence for primary THAs, is not felt to be secondary to the constrained implant design. Even with these findings, the Harris Hip scores still averaged 98.9, reflecting the improvement that can be expected in a primary THA.^{29,30}

The current findings were for both young and old patients, average age 64, with a primary diagnosis mostly of osteoarthritis of the hip that underwent primary constrained THA. This provides an opportunity to examine the natural history of this implant in moderately good bone stock. The report does not reveal the anticipated increased failure rate previously documented in constrained liners used primarily in revision settings.^{5,6,8,9}

Conclusions

Because the body of literature on constrained liners focuses largely on use of implants with limited ROM, significant impingement, and in complex revision settings, the conclusions from this report can't be overly broad. The results indicate it is possible to achieve excellent short-term results without the complications of aseptic loosening and constrained liner failure. The incidence of positional clicking of 10.4% is concerning as a possible source of secondary debris and likely indicative of mild impingement of the neck against the liner.

The problem of instability and dislocation after primary hip arthroplasty continues to be a challenge. Larger head sizes are not always good options in patients with small native head diameters. Adding a constrained liner to a well-established total hip bearing design is not an unreasonable consideration in patients considered higher risk for instability following primary total hip arthroplasty. Based on these results one could expect reasonable stability but should consider a less bulky neck-stem taper junction for the stem design and monitor for possible adverse effects of ring and neck contact.

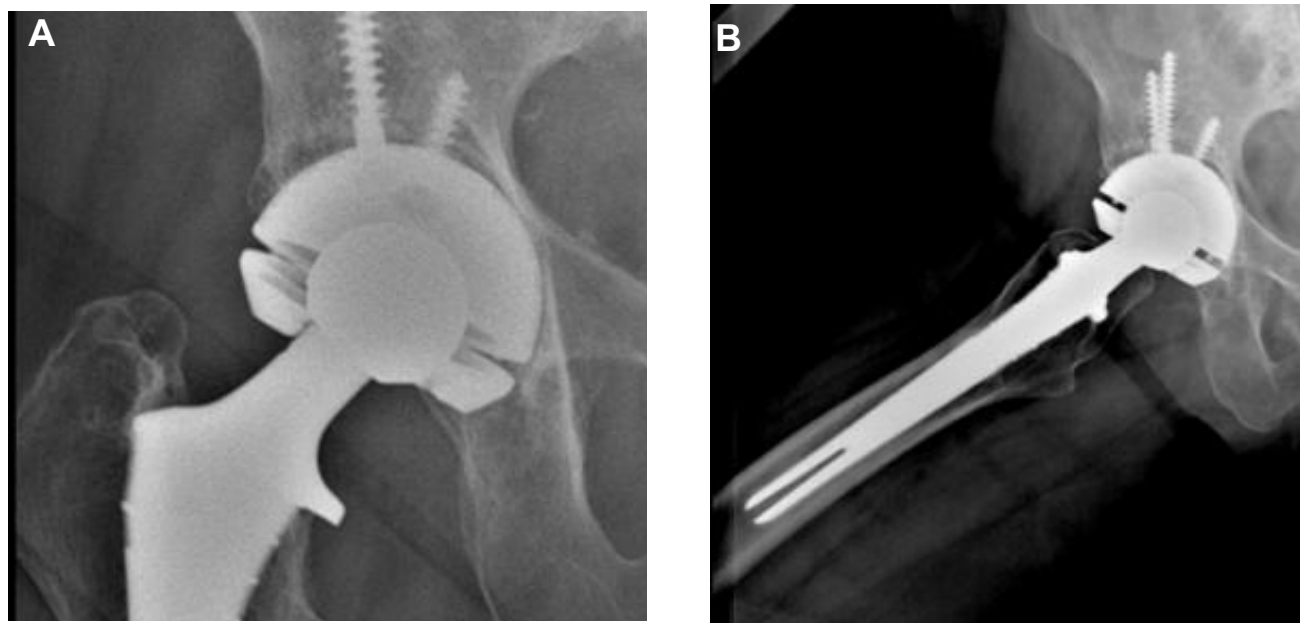


Figure 3. Anteroposterior (A) radiograph demonstrating slight notching in a total hip arthroplasty femoral component neck in a patient that reported clicking. B) Lowenstein lateral radiograph of the same patient, demonstrating neck-ring contact.

References

1. Berry DJ. Unstable total hip arthroplasty: detailed overview. *Instr Course Lect* 2001;50:265-74.
2. Bouchard SM, Stewart KJ, Pedersen DR, et al. Design factors influencing performance of constrained acetabular liners: finite element characterization. *J Biomech* 2006;39:885-93.
3. Cooke CC, Hozack W, Lavernia C, et al. Early failure mechanisms of constrained tripolar acetabular sockets used in revision total hip arthroplasty. *J Arthroplasty* 2003;18:827-33.
4. Padgett DE, Warashina H. The unstable total hip replacement. *Clin Orthop Relat Res* 2004;420:72-9.
5. Khan RJ, Fick D, Alakeson R, et al. A constrained acetabular component for recurrent dislocation. *J Bone Joint Surg Br* 2006;88B:870-6.
6. Berend KR, Lombardi AV Jr, Mallory TH, et al. The long-term outcome of 755 consecutive constrained acetabular components in total hip arthroplasty examining the successes and failures. *J Arthroplasty* 2005;20:93-102.
7. Anderson MJ, Murray WR, Skinner HB. Constrained acetabular components. *J Arthroplasty* 1994;9:17-23.
8. Goetz DD, Bremner BR, Callaghan JJ, et al. Salvage of a recurrently dislocating total hip prosthesis with use of a constrained acetabular component. A concise follow-up of a previous report. *J Bone Joint Surg Am* 2004;86:2419-23.
9. Goetz DD, Capello WN, Callaghan JJ, et al. Salvage of a recurrently dislocating total hip prosthesis with use of a constrained acetabular component. A retrospective analysis of fifty-six cases. *J Bone Joint Surg Am* 1998;80:502-9.
10. Smith R, Saint Paul MN, Bert JM. Use of constrained polyethylene acetabular component liners in revision THA: long term follow up in 38 cases. *Proceedings of the AAOS Annual Meeting* 2004;5:416.
11. Berend KR, Lombardi AV Jr, et al. A constrained device with increased range of motion prevents early dislocation. *Clin Orthop Relat Res* 2006;447:70-5.
12. Burroughs BR, Golladay GJ, Hallstrom B, Harris WH. A novel constrained acetabular liner design with increased range of motion. *J Arthroplasty* 2001;16:31-6.
13. D'Lima DD, Urquhart AG, Buehler KO, et al. The effect of the orientation of the acetabular and femoral components on the range of motion of the hip at different head-neck ratios. *J Bone Joint Surg Am* 2000;82:315-21.
14. Gruen TA, McNeice GM, Amstutz HC. Modes of failure of cemented stem-type femoral components: a radiographic analysis of loosening. *Clin Orthop Relat Res* 1979;141:17-27.
15. DeLee JG, Charnley J. Radiological demarcation of cemented sockets in total hip replacement. *Clin Orthop Relat Res* 1976;121:20-32.
16. Jones SA, John A, Mahesen M, et al. Omnifit acetabular component: a solution to preventing and treating dislocation. *J Orthop Surg (Hong Kong)* 2007;15:167-9.
17. Shrader MW, Parvizi J, Lewallen DG. The use of a constrained acetabular component to treat instability after total hip arthroplasty. *J Bone Joint Surg Am* 2003;85:2179-83.
18. McPherson EJ, Costigan WM, Gerhardt MB, Norris LR. Closed reduction of dislocated total hip with S-ROM constrained acetabular component. *J Arthroplasty* 1999;14:882-5.
19. Guyen O, Lewallen DG, Cabanela ME. Modes of failure of osteonics constrained tripolar implants: a retrospective analysis of forty-three failed implants. *J Bone Joint Surg Am* 2008;90:1553-60.
20. Bremner BR, Goetz DD, Callaghan JJ, et al. Use of constrained acetabular components for hip instability: an average 10-year follow-up study. *J Arthroplasty* 2003;18:131-7.
21. Harman MK, Hodge WA, Banks SA. Closed reduction of constrained total hip arthroplasty. *Clin Orthop Relat Res* 2003;414:121-8.
22. Robertson WJ, Mattern CJ, Hur J, et al. Failure mechanisms and closed reduction of a constrained tripolar acetabular liner. *J Arthroplasty* 2009;24:322.e5-11.
23. D'Angelo F, Murena L, Zatti G, Cherubino P. The unstable total hip replacement. *Indian J Orthop* 2008;42:252-9.
24. Geller JA, Malchau H, Bragdon C, et al. Large diameter femoral heads on highly cross-linked polyethylene: minimum 3-year results. *Clin Orthop Relat Res* 2006;447:53-9.
25. Yang C, Goodman SB. Outcome and complications of constrained acetabular components. *Orthopedics* 2009;32:115.
26. Beaulé PE, Schmalzried TP, Udomkiat P, Amstutz HC. Jumbo femoral head for the treatment of recurrent dislocation following total hip replacement. *J Bone Joint Surg Am* 2002;84:256-63.
27. Pace TB, Karegeannes JC, Palmer MJ, et al. Clinical and radiographic evaluation of a commercially pure cancellous-structured titanium press-fit total hip prosthetic stem: ten-year follow-up of the natural hip femoral stem. *Adv Orthop Surg* 2014 [In press].
28. Parsons C, Batson R, Reighard S, et al. Clinical outcomes assessment of three similar hip arthroplasty bearing surfaces. *Orthop Rev (Pavia)* 2014;6:5334.
29. Brown TE, Larson B, Shen F, Moskal JT. Thigh pain after cementless total hip arthroplasty: evaluation and management. *J Am Acad Orthop Surg* 2002;10:385-92.
30. Robbins GM, Masri BA, Garbuz DS, Duncan CP. Evaluation of pain in patients with apparently solidly fixed total hip arthroplasty components. *J Acad Orthop Surg* 2002;10:86-94.