

# Stump Incorporation for Anterior Cruciate Ligament Reconstruction: A Step Towards a More Anatomical Reconstruction



Walid Reda, M.D., Ph.D., and Ahmed Khedr, M.D., Ph.D.

**Abstract:** In most anterior cruciate ligament (ACL) tears, the tear is at the femoral side leaving a robust stump attached to the tibia. Stump-preserving ACL reconstruction carries the advantage of rapid reinnervation and revascularization of the graft. In this technique, the femoral tunnel is created after exposing the femoral footprint. The ACL tibial stump is split and the tip of the ACL tibial guide is introduced through this split to reach the center of the tibial footprint. The tibial tunnel is then created and the ACL stump is bored to allow the passage of the graft. After the passage of the graft inside the stump and femoral and tibial fixation, 1 or 2 sutures are used to suture the graft to the stump by a suture passing device (Expressw II; Depuy Mitek, Raynham, MA). This technique, in addition to preservation of the mechanoreceptors and vascular channels for revascularization and reinnervation of the graft, allows preservation of the shape and surface area of the wide tibial origin of the ACL.

In addition to its role in resisting anterior translation and abnormal anterior lateral rotation of the tibia over the femur, the anterior cruciate ligament (ACL) is responsible for multiple functions in the knee, including proprioception, because it has mechanoreceptors in the subsynovial tissue.<sup>1</sup> In many cases with a torn ACL, the tibial attachment is well preserved.<sup>2</sup> This stump provides a source of reinnervation and blood supply for the graft and enhances proliferation of fibroblasts.<sup>3,4</sup> In this technique, we aim to provide a simple way of performing ACL reconstruction, meanwhile preserving the wide tibial attachment that cannot be maintained by other methods of ACL reconstruction.

## Surgical Technique

### Patient Positioning

All patients are operated on in the supine position after the application of a thigh tourniquet. The patients are examined under anesthesia (Lachman test, pivot shift, stress varus, and valgus tests).

### Diagnostic Arthroscopy

The standard anterolateral, anteromedial, and far anteromedial portals are developed. The knee is examined by arthroscopy. Concomitant meniscal injuries are treated by meniscectomy or meniscal repair.

### Graft Preparation

The semitendinosus and gracilis tendons are harvested from the same leg using a Pigtail Tendon Peeler (Depuy Mitek, Raynham, MA). A six-strand graft is prepared using No. 2 Ethibond sutures (Ethicon, Somerville, NJ) and the graft size is measured. The graft is prepared before drilling the femoral and tibial tunnels. This prevents drilling a larger size tunnel, which is not necessary to accommodate the graft. In addition, this preserves as much tissue in the stump as possible.

### Creating the Femoral Tunnel

The procedure starts with exposing the ACL femoral footprint by a motorized shaver (Fig 1A). The femoral tunnel is developed in the center of the femoral

*From the Department of Orthopedics, Faculty of Medicine, Kasralainy Hospital, Cairo University, El Manial, Cairo, Egypt.*

*The authors report that they have no conflicts of interest in the authorship and publication of this article. Full ICMJE author disclosure forms are available for this article online, as [supplementary material](#).*

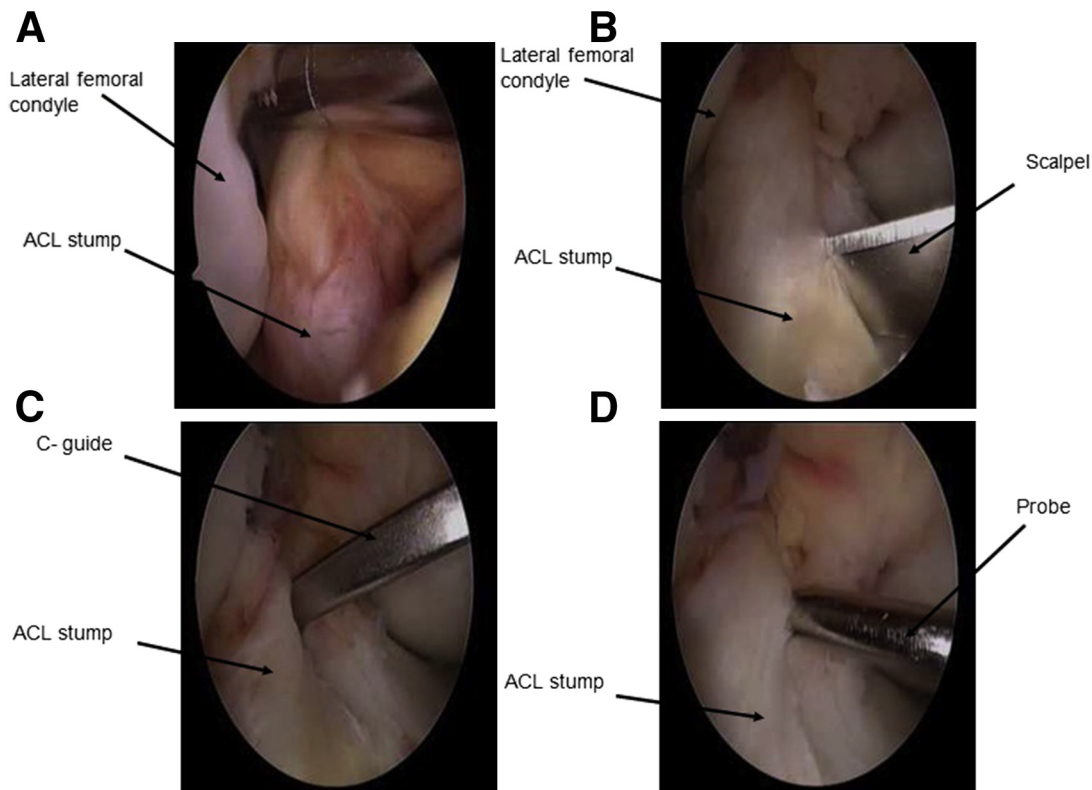
*Received November 8, 2016; accepted May 11, 2017.*

*Address correspondence to Ahmed Khedr, M.D., Ph.D., Department of Orthopedics, Faculty of Medicine, Kasralainy Hospital, Cairo University, 4 Hosni Metwali Street, Elharam, Giza, Egypt. E-mail: [ahmedkhedr@kasralainy.edu.eg](mailto:ahmedkhedr@kasralainy.edu.eg)*

© 2017 by the Arthroscopy Association of North America

2212-6287/161096/\$36.00

<http://dx.doi.org/10.1016/j.eats.2017.05.007>



**Fig 1.** Arthroscopic view of the right knee from the anterolateral portal. (A) A shaver introduced from the anteromedial portal is used to shave the remnants of the femoral stump. (B) A number 11 blade is used to split the tibial ACL stump longitudinally. (C) The tip of a tip aiming C-guide is placed in the center of the tibial stump. (D) A probe is used to feel the site of exit of the guide pin into the joint before reaming. (ACL, anterior cruciate ligament.)

footprint. A guide pin (Bayonet Point Pin w/Eyelet; Depuy Mitek) is inserted through the femur and then the tunnel is drilled by a proper-size reamer (Acorn Reamers; Depuy Mitek) from the far anteromedial portal while the knee is in 120° flexion. The tunnel is cleaned by a motorized shaver to remove any debris.

### Creating the Tibial Tunnel

The ACL stump is then assessed. We do not shave any of the tibial remnants, but instead we use a number 11 blade to split the stump longitudinally (Fig 1B). A short tip aiming C-guide (Tip Aiming Arm; Depuy Mitek) is used with the tip placed in the center of the stump passing through the split (Fig 1C). The guide pin (Bayonet Point Pin w/Eyelet; Depuy Mitek) is passed until it is felt to hit the tip of the C-guide. The tip of the guide pin can be visualized by arthroscopy. If visualization of the tip of the guide pin is difficult due to the stump, a probe is used to feel the site of exit of the guide pin to make sure that it is in the center of the tibial footprint (Fig 1D). A 6-mm reamer (Acorn Reamer; Depuy Mitek) is used to create the tibial tunnel. The reamer is passed through the tibia until a release of resistance is felt once the joint surface is breached. We then proceed to larger reamer diameters in 1 mm increments till reaching the desired tibial tunnel size.

Again, a probe can be used to feel the site of the tunnel. Excessive drilling or reaming into the joint should be avoided. Excessive drilling or reaming in the tissue of the stump should be avoided not to damage the stump. When a release of resistance is felt, a careful arthroscopic assessment should be made to visualize the reamer. If visualization is difficult, a probe can be used to palpate the tip of the reamer. A metallic sensation indicates that the reamer has penetrated into the joint and the surgeon can proceed to the next step even if the reamer is not visualized. A motorized shaver is then inserted through the tibial tunnel from the anteromedial surface of the tibia to inside the joint to bore a tunnel through the ACL stump for the passage of the graft. The tissues that have been shaved are in the central part of the ACL stump, whereas the subsynovial tissue with high density of mechanoreceptors is preserved. This allows the passage of the graft smoothly through the stump.

### Shuttling the ACL Graft

We then pass a shuttling loop through the femoral tunnel. A ring forceps or a grasper is introduced through the tibial tunnel to pass the shuttling loop through the knee joint, the bored tunnel inside the ACL stump, and the tibial tunnel (Fig 2A).

### Graft Fixation

The graft is fixed proximally and distally by 2 biodegradable screws (Absolute absorbable interference screw; Depuy Mitek). Once the graft is secured with the screws, a grasper is introduced into the joint and used to tension the stump over the graft. A No. 2 Vicryl suture is used to suture the graft to the ACL stump by Expressw II (Depuy Mitek) (Fig 2B). Both ends of the suture are retrieved by a ring forceps from the anteromedial portal and tied by a sliding knot that is secured by 2 half hitches. Tension is maintained during suture passage and knot tying to prevent buckling of the stump in the notch (Fig 2 C and D). In some cases, we use 2 Vicryl stitches for this purpose. If needed, a basket is used to trim the excess tissues of the stump to prevent impingement. The knee can now be fully extended to test for impingement. The pearls and pitfalls of the technique are shown in Table 1. The technique is shown in Video 1.

### Closure

A drain is put in the knee joint. The portals are closed by 3-0 monocryl. The subcutaneous tissue in the donor site of the graft is closed by Vicryl 0 and the skin is closed by monocryl 3-0.

### Postoperative Protocol

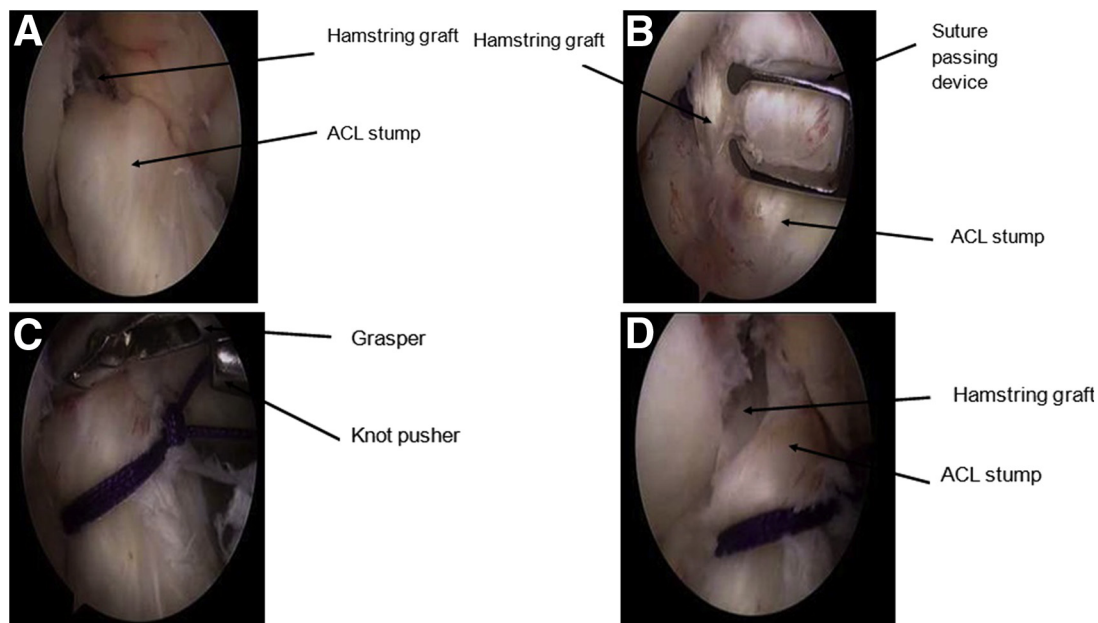
After the operation, the patients are instructed to achieve full extension in the first 24 hours. Physiotherapy program then includes a graduated strength, endurance, and proprioceptive training. At 12 weeks,

jogging is allowed in a straight line on a flat surface. Return to sports is not allowed before 6 months.

### Discussion

The aim of this technique is to provide a simple, reproducible technique for stump retaining ACL reconstruction with preservation of the subsynovial mechanoreceptors and blood vessels. The hallmark of our technique is splitting the ACL stump that allows a more anatomical position of the graft. Also, boring the stump to create a room for the reconstructed graft is essential, preventing overstuffing of the ACL in the notch. Suturing of the stump to the graft prevents buckling of the stump in the notch and synovial leakage inside the tibial tunnel. This technique also allows preservation of the shape and surface area of the wide tibial origin of the ACL. The advantages and disadvantages of our technique are summarized in Table 2.

Adachi et al.<sup>5</sup> designed a study with 40 patients who underwent ACL augmentation and compared them with 40 patients who underwent ACL reconstruction. The augmentation group was superior in terms of joint stability and position sense. Lee et al.<sup>6</sup> reported better functional outcome and proprioception in patients with stump >20% in length compared with those with stump <20% in length. Zhang et al.<sup>7</sup> compared tibial tunnel widening in a randomized controlled trial on remnant preserving and remnant removing patients. Tibial tunnel widening was significantly less in the remnant preserving group. The authors proposed that



**Fig 2.** Arthroscopic view of the right knee from the anterolateral portal. (A) The hamstring graft is first shuttled through the stump. (B) A suture passing device (Expressw II; Depuy Mitek, Raynham, MA) is used to pass No. 2 Vicryl sutures through the graft and stump. (C) While a grasper is used to tension the stump, a sliding knot followed by 2 half hitches are tied. (D) The final appearance of the ACL after the knot is tied. (ACL, anterior cruciate ligament.)

**Table 1.** Pearls and Pitfalls of Reconstruction of ACL Injury by Hamstring Graft Using a Stump Preserving Technique

	Pearls	Pitfalls
Graft preparation	<ul style="list-style-type: none"> <li>• Six-strand hamstring graft</li> </ul>	<ul style="list-style-type: none"> <li>• Do not create the tunnels before preparing the graft. Creating larger tunnels is not necessary and will damage more stump tissue</li> </ul>
Creating the femoral tunnel	<ul style="list-style-type: none"> <li>• Shave the femoral footprint</li> <li>• Create the femoral tunnel in the center of the femoral footprint</li> </ul>	
Creating the tibial tunnel	<ul style="list-style-type: none"> <li>• Split the tibial stump by a number 11 blade longitudinally</li> <li>• Use a tip aiming C-guide with its tip placed in the center of the stump. If the stump makes visualization of the tip of the guide pin difficult, use a probe to feel it</li> <li>• Create the tibial tunnel by a 6-mm reamer; increase the increments by 1 mm till reaching the desired tibial tunnel size. Use a probe to feel the reamer</li> <li>• Bore a tunnel for the hamstring graft in the stump by a motorized shaver</li> </ul>	<ul style="list-style-type: none"> <li>• Do not ream inside the stump to visualize the reamer. Use a probe to feel the tip of the guidewire or reamer in the joint while reaming the tibial tunnel. Feeling a metallic sensation is sufficient to indicate reaching the joint. Excessive reaming or drilling in the tissue of the stump will damage it</li> <li>• Do not try to pass the graft through the stump without creating enough room by a shaver. The tissues that are shaved are in the central part of the ACL stump, whereas the subsynovial tissue with high density of mechanoreceptors is preserved</li> </ul>
Shuttling the ACL graft	<ul style="list-style-type: none"> <li>• Shuttle the hamstring graft through the tibial tunnel, ACL stump, knee joint, and finally the femoral tunnel</li> </ul>	
Graft fixation	<ul style="list-style-type: none"> <li>• Fix the graft proximally and distally by biodegradable screws</li> <li>• Use a suture passing device (Expressw II; Depuy Mitek, Raynham, MA) to pass No. 2 Vicryl suture through the stump and graft</li> <li>• Retrieve both ends of the suture by a ring forceps from the anteromedial portal</li> <li>• Tension the stump by a grasper</li> <li>• Tie the suture by a sliding knot and 2 half hitches</li> <li>• Extend the knee to test for impingement</li> </ul>	<ul style="list-style-type: none"> <li>• Avoid overstuffing the notch. This can be done by tensioning the stump to the ACL graft before suturing them together and by trimming the excess tissue after testing extension</li> </ul>

ACL, anterior cruciate ligament.

the remnant provided a source of blood supply to the graft and allowed rapid healing of the graft to the bone—this was an assumption by the authors but was not proven by the study—which decreased micro-motion between the graft and bone and thus prevented tibial tunnel widening. Trocan et al.<sup>8</sup> reported a significant difference between biopsies obtained from the ACL stump and normal ACL. Biopsies obtained from the ACL stump had more CD34<sup>+</sup> fibrocytes (CD34 is a nonspecific marker for endothelial cells, fibroblasts, and fibrocytes) and stellate stromal cells and showed angiogenesis in the ligament and synovium. Gohil et al.<sup>9</sup> conducted a randomized prospective study involving a group with ACL reconstruction with minimal debridement and a group with ACL reconstruction with standard debridement. The study showed that there was a significantly earlier higher signal in the midsubstance of the ACL graft in the minimal debridement group, indicating revascularization.

In this technique, the graft is passed within the stump. We hypothesize that the graft heals to the stump. This compensates for minor errors in the site of the tibial tunnel. In stump sacrificing ACL surgeries, once the tibial tunnel is reamed the point of fixation of the graft

to the joint surface cannot be changed. However, in this technique, we assume that the graft heals to the stump that will form the new ACL regardless of the exact site of the tibial tunnel. Thus, the shape and surface area of the tibial footprint of the reconstructed ACL are as the native ACL. Although a semitendinosus gracilis autograft can reproduce the size of the femoral footprint, the size of the tibial footprint cannot be reproduced by semitendinosus gracilis autograft, semitendinosus autograft, or by bone–patellar tendon–bone autograft.<sup>10</sup> We also assume that our technique can enhance revascularization of the graft and preserves the mechanoreceptors function. This is because we create a tunnel inside the substance of the stump leaving the subsynovial tissue where the mechanoreceptors and subsynovial vessels are present.<sup>1</sup> In addition, we believe that stump preservation guards against tunnel widening. When the graft is encased within the stump all-around and sutured to it, synovial fluid cannot reach the tunnel. Synovial fluid trickling into the tunnel causes tunnel widening.<sup>11</sup> We also claim that tensioning and suturing the remnants to the ACL will add to the strength of the graft and promote better remodeling. However, this technique carries an increased risk of impingement especially in patients

**Table 2.** Advantages, Disadvantages, and Limitations of Suturing the ACL Graft to the Stump Using Our Technique

Advantages	<ul style="list-style-type: none"> <li>• Simple, reproducible technique for stump preserving ACL reconstruction</li> <li>• Preservation of the subsynovial mechanoreceptors and blood vessels because only the central part of the stump is shaved to bore the tunnel for the graft</li> <li>• Preservation of the shape and surface area of the tibial footprint</li> <li>• Compensates for minor errors in tibial tunnel placement</li> <li>• Avoiding overstuffing of the notch</li> </ul>
Disadvantages and limitations	<ul style="list-style-type: none"> <li>• Impingement can happen especially in patients with a narrow notch</li> <li>• Prolonged operative time compared with stump sacrificing surgery</li> <li>• We assume that early revascularization happens when this technique is used. However, this was not proven by the current study</li> </ul>

ACL, anterior cruciate ligament.

with a narrow notch. Nevertheless, the operative time is prolonged when compared with remnant sacrificing ACL reconstruction.

Lee et al.<sup>12</sup> proposed a stump preserving technique with distally attached hamstring graft. However, they placed the guide pin for the tibial tunnel in line with the ACL remnant and lateral to the posterior cruciate ligament. In our technique, the stump was split to ensure a more anatomical position of the tibial tunnel. In addition, an additional incision was needed at the lateral femoral condyle for the proximal tie, but in our technique, no incisions are needed in the thigh. Ahn et al.<sup>13</sup> proposed another technique for stump preservation using hamstring graft. They proposed that the ACL stump is usually scared at the posterolateral part of the footprint. This scared tissue was debrided and 3 sutures were used to apply traction on the stump. This helped them in localizing the proper site of the tibial tunnel. In our technique, we relied on splitting of the stump to localize the site of the tibial tunnel.

In conclusion, this technique provides a simple way for stump preservation. We are now in the process of accessing proprioception and isokinetic testing for patients operated on with this technique. We are looking forward to comparing the postoperative stability and proprioception in patients treated by this technique to patients treated with stump sacrificing surgeries.

## References

1. Duthon VB, Barea C, Abrassart S, Fasel JH, Fritschy D, Ménétrey J. Anatomy of the anterior cruciate ligament. *Knee Surg Sports Traumatol Arthrosc* 2006;14:204-213.
2. Muneta T, Koga H, Ju Y-J, Horie M, Nakamura T, Sekiya I. Remnant volume of anterior cruciate ligament correlates preoperative patients' status and postoperative outcome. *Knee Surg Sports Traumatol Arthrosc* 2013;21:906-913.
3. Vavken P, Murray MM. The potential for primary repair of the ACL. *Sports Med Arthrosc* 2011;19:44-49.
4. Dhillon MS, Bali K, Vasistha RK. Immunohistological evaluation of proprioceptive potential of the residual stump of injured anterior cruciate ligaments (ACL). *Int Orthop* 2010;34:737-741.
5. Adachi N, Ochi M, Uchio Y, Sumen Y. Anterior cruciate ligament augmentation under arthroscopy. A minimum 2-year follow-up in 40 patients. *Arch Orthop Trauma Surg* 2000;120:128-133.
6. Lee B-I, Kwon S-W, Kim J-B, Choi H-S, Min K-D. Comparison of clinical results according to amount of preserved remnant in arthroscopic anterior cruciate ligament reconstruction using quadrupled hamstring graft. *Arthroscopy* 2008;24:560-568.
7. Zhang Q, Zhang S, Cao X, Liu L, Liu Y, Li R. The effect of remnant preservation on tibial tunnel enlargement in ACL reconstruction with hamstring autograft: A prospective randomized controlled trial. *Knee Surg Sports Traumatol Arthrosc* 2014;22:166-173.
8. Trocan I, Ceausu RA, Jitariu AA, Haragus H, Damian G, Raica M. Healing potential of the anterior cruciate ligament remnant stump. *In Vivo* 2016;30:225-230.
9. Gohil S, Annear PO, Breidahl W. Anterior cruciate ligament reconstruction using autologous double hamstrings: A comparison of standard versus minimal debridement techniques using MRI to assess revascularisation. A randomised prospective study with a one-year follow-up. *J Bone Joint Surg Br* 2007;89:1165-1171.
10. Iriuchishima T, Shirakura K, Yorifuji H, Aizawa S, Fu FH. Size comparison of ACL footprint and reconstructed auto graft. *Knee Surg Sports Traumatol Arthrosc* 2013;21:797-803.
11. Höher J, Möller HD, Fu FH. Bone tunnel enlargement after anterior cruciate ligament reconstruction: Fact or fiction? *Knee Surg Sports Traumatol Arthrosc* 1998;6: 231-240.
12. Lee B-I, Min K-D, Choi H-S, Kim J-B, Kim S-T. Arthroscopic anterior cruciate ligament reconstruction with the tibial-remnant preserving technique using a hamstring graft. *Arthroscopy* 2006;22:340.e1-340.e7.
13. Ahn JH, Lee YS, Ha HC. Anterior cruciate ligament reconstruction with preservation of remnant bundle using hamstring autograft: Technical note. *Arch Orthop Trauma Surg* 2009;129:1011-1015.