

# Definitive Radiotherapy for Penoscrotal Extramammary Paget's Disease: A Case Report with Long-Term Follow-Up

Clinical Medicine Insights: Case Reports  
Volume 14: 1–4  
© The Author(s) 2021  
Article reuse guidelines:  
sagepub.com/journals-permissions  
DOI: 10.1177/11795476211009251



Gen Suzuki<sup>1,2</sup>, Kazutaka Machida<sup>1</sup>, Akito Asato<sup>1</sup>, Sho Seri<sup>1</sup>, Chika Ikemoto<sup>3</sup>, Hideya Yamazaki<sup>2</sup>, Kei Yamada<sup>2</sup> and Tetsuya Katsumori<sup>1</sup>

<sup>1</sup>Department of Radiology, Saiseikai Shiga Hospital, Ritto, Shiga, Japan. <sup>2</sup>Department of Radiology, Kyoto Prefectural University of Medicine, Kamigyo-ku, Kyoto, Japan. <sup>3</sup>Department of Dermatology, Saiseikai Shiga Hospital, Ritto, Shiga, Japan.

**ABSTRACT:** Penoscrotal extramammary Paget's disease (EMPD) is a rare intraepithelial adenocarcinoma in older male patients, and no effective nonsurgical treatment strategies are currently available. The aim of this study was to report the usefulness of external radiotherapy (RT) for penoscrotal EMPD in an inoperable elderly patient. This report presents the treatment of an 89-year-old man with widespread penoscrotal EMPD. A multidisciplinary treatment team decided on radical RT. The patient received a radiation dose of 61.8 Gy in 30 fractions through electron and photon beams. His treatment tolerance was good, and no severe toxicity had been observed up to the last follow-up. At 6.5 years after the RT, the patient showed no evidence of recurrence. Definitive RT resulted in excellent disease control and minimal toxicity; thus, it could be a promising nonsurgical therapeutic option for penoscrotal EMPD, even in extremely elderly individuals.

**KEYWORDS:** Radiotherapy, aged, 80 and over, Paget disease, extramammary, skin neoplasms

**RECEIVED:** February 3, 2021. **ACCEPTED:** March 22, 2021.

**TYPE:** Case Report

**FUNDING:** The author(s) disclosed receipt of the following financial support for the research, authorship, and/or publication of this article: This work was supported by JSPS KAKENHI Grant No. JP18K07638 (Grant-in-Aid for Scientific Research).

**DECLARATION OF CONFLICTING INTERESTS:** The author(s) declared no potential conflicts of interest with respect to the research, authorship, and/or publication of this article.

**CORRESPONDING AUTHOR:** Gen Suzuki, Department of Radiology, Kyoto Prefectural University of Medicine, 465 Kajicho Kawaramachi Hirokoji, Kamigyo-ku, Kyoto 602-8566, Japan. Email: gensuzu@koto.kpu-m.ac.jp

## Introduction

Extramammary Paget's disease (EMPD) is a rare neoplasm of the skin that generally affects the anogenital area. Complete surgical removal of the localized disease is the chosen treatment for EMPD.<sup>1</sup> Surgical excision carries the risk of anesthesia-related complications and functional decline, making it difficult to indicate, especially in the elderly. Nonsurgical interventions have also been investigated currently, with varied results.<sup>2</sup>

Radiotherapy (RT) has been suggested as a less invasive and potentially curative treatment, with a lower risk of adverse effects,<sup>2-5</sup> but the existing published evidence has several limitations. Most articles report small-scale retrospective studies, referring to patients treated with large heterogeneities in terms of RT dose and technique. Moreover, many reports lack long-term observations after treatment and therefore lack information about the true effects of definitive RT.<sup>6-8</sup>

Herein, we present the case of an elderly patient with penoscrotal EMPD treated with definitive RT who attained long-term complete response without serious toxicity.

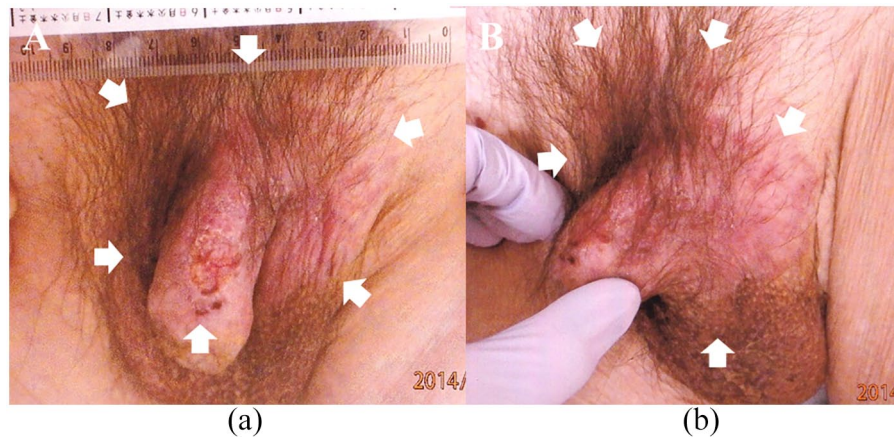
## Case Report

An 89-year-old man presented with an erythematous patch on his penoscrotal skin. He first noticed the skin lesion 5 years before the consultation, expanding gradually. Topical moisturizing creams did not improve the lesion. On local examination, an erythematous patch of 8 cm in the penoscrotal region was observed (Figure 1a and b). He did not report any itching or

tenderness. A skin biopsy revealed the invasion of Paget's cells into the dermis (Figure 2a and b). Neither regional lymphadenopathy nor distant metastases were detected on computed tomography. A discussion with the patient and his family revealed their preference for a nonsurgical treatment strategy because of the patient's age. We decided to administer electron beam therapy, which could eradicate a tumor with minimal adverse reactions in normal tissue such as the rectum and bladder. Informed consent was obtained from the patient and his family.

RT was delivered conventionally (2.2 Gy/day, 5 fractions/week) using a single anterior 6 MeV electron beam (Figure 3a). To reduce the risk of skin recurrence by minimizing the skin-sparing effect of the electron and photon beams, a 10 mm tissue-equivalent bolus was added to the skin surface during the RT. Clinical target volume included 2 cm margins for the clinically visible disease. The tumor response in the irradiation field was observed to be inhomogeneous at the completion of administration of 19.8 Gy in 9 fractions; thus, in a subsequent RT, an additional dose of 42 Gy at 2 Gy per fraction was delivered using a single anterior 4 MV photon beam using a uniform 10 mm thickness bolus (Figure 3b). Eventually, the patient received a total dose of 61.8 Gy in 30 fractions. The skin over the treatment area was mildly hyperpigmented, but it was otherwise unaffected. The tumor completely disappeared after the completion of the RT. As of 6.5 years after the treatment, the tumor had not recurred and no severe late adverse events were observed (Figure 4).





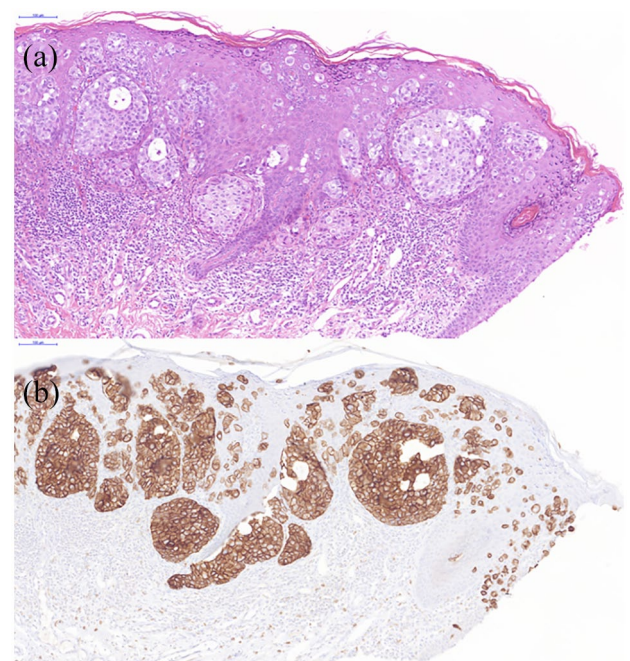
**Figure 1.** (a, b) Disease presentation before radiotherapy, which shows an erythematous patch to the penoscrotal region (white arrows).

## Discussion

EMPD is rare malignant tumor arising in areas rich in apocrine glands. Male genital involvement is infrequent and accounts for only 14% of all EMPD cases.<sup>9</sup> One typical observation is a slowly expanding erythematous plaque that can have associated erosions with scattered white plaques, giving the classic “strawberries and cream” appearance.<sup>10</sup>

Although a multitude of case series, case reports, and retrospective studies have been published, offering various treatment protocols, the existing evidence is insufficient for developing clear management guidelines, probably because of the rarity of the disease, making controlled comparative clinical trials challenging. Despite a recent Cochrane review citing insufficient evidence to direct a given therapy for EMPD, the most common modality is surgical excision.<sup>1</sup> However, EMPD tends to display a multifocal growth with subclinical extension into seemingly normal-appearing skin, thus creating issues when attempting to obtain clear surgical margins. As a result, even a wide local excision results in positive margins at a rate between 40% and 75%.<sup>11</sup> In addition, many older patients may be unwilling or unable to tolerate an extensive surgery given the risk of functional impairment and cosmetic disfigurement.

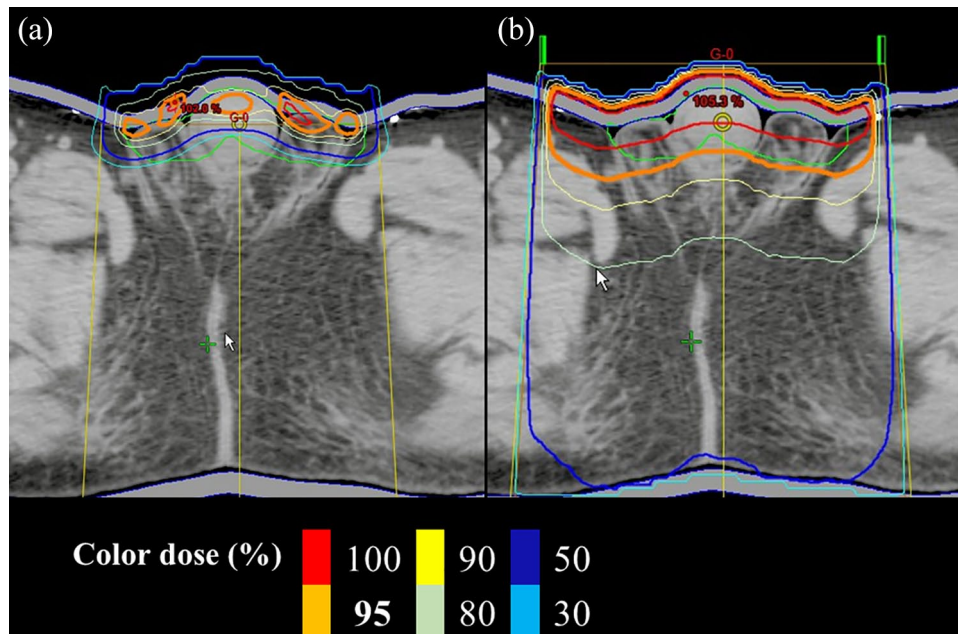
For patients who are not surgical candidates, alternative treatment modalities, such as topical chemotherapy, photodynamic therapy, and RT may be beneficial. Each approach carries varying levels of evidence as to its effectiveness and tolerability.<sup>2</sup> The role of RT in the management of EMPD is somewhat poorly understood, as the literature is mostly composed of case reports or small case series. However, some review showed that RT plays a central role as a primary definitive treatment for inoperable patients.<sup>2-5</sup> In a recent review that included 12 studies (4 cohort studies and 8 cases series) with a total of 67 patients, the treatment results of RT were evaluated.<sup>2</sup> Although the interpretation of this analysis may be difficult because the radiation fields, doses, and schedules were not standardized between patients; the complete response rate was 97%, which is comparable with the reported rate for surgery and higher than that for other nonsurgical modalities.<sup>2</sup>



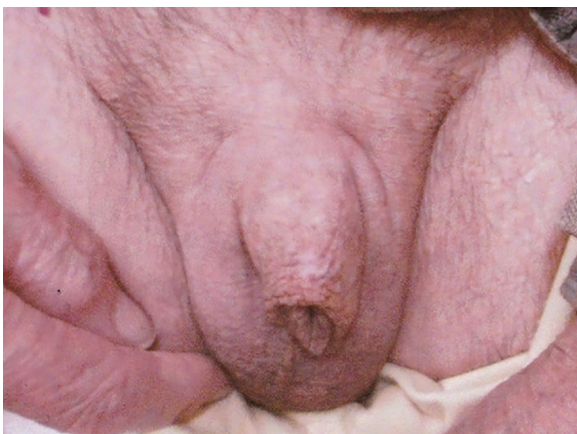
**Figure 2.** (a) Skin and left scrotum involvement of the extramammary Paget's disease with an invasive component (hematoxylin-eosin staining, original magnification  $\times 20$ ), (b) the Paget's cells are positive for CAM 5.2 (original magnification  $\cdot 20$ ).

These results show that RT can be an ideal therapeutic modality for treating extensive lesions such as that in our patient.

From our literature review, we have clarified that in the curative setting, irradiation doses of 60 to 70 Gy in the conventional fraction should be used, with surgical fields including the disease or tumor bed plus a margin of 2 to 5 cm.<sup>5</sup> Meanwhile, irradiation of the genital area represents a dosimetric challenge because of the irregular shape of the target and the difficulty in obtaining a homogeneous dose distribution while sparing the nearby critical structures such as the bladder and rectum. In our patient, the heterogeneity of the response of the tumor tissue to the electron beam was clear, so we had to change to a photon beam that can irradiate the lesion with a more uniform dose during the treatment course. Electron beam therapy should be



**Figure 3.** Axial CT image with color overlays shows radiation dose distribution: (a) dose distribution of the 6 MeV electron beam plan using a uniform 10 mm thickness bolus, and (b) dose distribution of the 4 MV photon beam plan using a uniform 10 mm thickness bolus.



**Figure 4.** Macroscopic appearance of the patient's extramammary Paget's disease after radiotherapy.

delivered perpendicular to the skin surface, and owing to the irregular shape of the genital region, the dose distribution might be nonuniform, with areas of hot/cold spots. Electron beam therapy targets superficial tissues while sparing deeper structures and thus can be an appropriate therapy for cutaneous malignancies, such as EMPD.<sup>6</sup> However, radiation oncologists should carefully observe the reaction of the tumor tissue during the treatment period, especially when treating the genital area. In the future, advanced technologies such as intensity-modulated RT could be beneficial for improving the dose distribution when irradiating the genital area.

The available information is inadequate regarding the long-term follow-up of patients with EMPD. Snast et al. reported that 34% of patients who achieved complete remission during a mean follow-up of 60 months after RT experienced disease recurrence.<sup>1</sup> Disease recurrence remains a

concern regardless of treatment method, as EMPD may recur up to 15 years after the initial diagnosis.<sup>11,12</sup> These findings imply that patients with EMPD require both longer and closer follow-up. Nonetheless, many reports had short follow-ups, which were insufficient to determine the true effect of RT.<sup>6-8</sup> Our patient experienced a durable response to RT, with no evidence of disease at >6 years of follow-up. Furthermore, no serious late toxicities occurred.

Although precise guidelines for the treatment of EMPD are difficult to define owing to the rarity of the disease and the lack of long-term follow-up information, RT may significantly contribute to the therapeutic management of inoperable penoscrotal EMPD, even in the elderly.

### Acknowledgements

We would like to thank Dr. Masamichi Banba for helping us to obtain the pictures.

### Author Contributions

GS designed the study and prepared the manuscript. KM, AA, SS, and CI contributed to the data acquisition. HY, KY, and TK supervised the study. All authors have read and approved the final manuscript.

### Research Ethics and Patient Consent

This case report is a retrospective medical record review. Written informed consent was obtained from the patient's family before initiating the treatment.

### Consent for Publication

Written informed consent was obtained from the patient's legal guardian for the publication of this case report and any

accompanying images. A copy of the written consent is available for review by the editor-in-chief of this journal.

## REFERENCES

1. Edey KA, Allan E, Murdoch JB, Cooper S, Bryant A. Interventions for the treatment of Paget's disease of the vulva. *Cochrane Database Syst Rev.* 2019;6:CD009245.
2. Snast I, Sharon E, Kaftory R, et al. Nonsurgical treatments for extramammary Paget disease: a systematic review and meta-analysis. *Dermatology.* 2020;236:493-499.
3. Tagliaferri L, Casà C, Macchia G, et al. The role of radiotherapy in extramammary Paget disease: a systematic review. *Int J Gynecol Cancer.* 2018;28:829-839.
4. Tolia M, Tsoukalas N, Sofoudis C, et al. Primary extramammary invasive Paget's vulvar disease: what is the standard, what are the challenges and what is the future for radiotherapy? *BMC Cancer.* 2016;16:563.
5. Piras A, Sanfratello A, Boldrini L, et al. Paget's disease of scrotum and penis case report of a re-irradiation and review of the literature. *Dermatol Ther.* 2020;33(6):e13890.
6. Valle L, Deig C, Wright R, High W. An advanced case of extramammary Paget disease: safe and effective treatment in an inoperable elderly patient using extensive en face electron irradiation. *JAAD Case Rep.* 2019;5:72-74.
7. Sarkar A, Saha SC, Sikka P, Kumari N, Dey P, Rai B. Invasive Vulval Paget's disease treated with primary radiotherapy: a rare case report and literature review. *Gynecol Oncol Rep.* 2020;34:100674.
8. Mammino JR, Daze RP, Mammino J. Fungal masquerader: a case report of extramammary Paget's disease treated with radiotherapy. *Cureus.* 2019;11(10):e5937.
9. Simonds RM, Segal RJ, Sharma A. Extramammary Paget's disease: a review of the literature. *Int J Dermatol.* 2019;58:871-879.
10. Lam C, Funaro D. Extramammary Paget's disease: summary of current knowledge. *Dermatol Clin.* 2010;28:807-826.
11. Kanitakis J. Mammary and extramammary Paget's disease. *J Eur Acad Dermatol Venereol.* 2007;21:581-590.
12. Shepherd V, Davidson EJ, Davies-Humphreys J. Extramammary Paget's disease. *BJOG An Int J Obstet Gynaecol.* 2005;112:273-279.