

Epithelial ingrowth—Islands in the clear sea

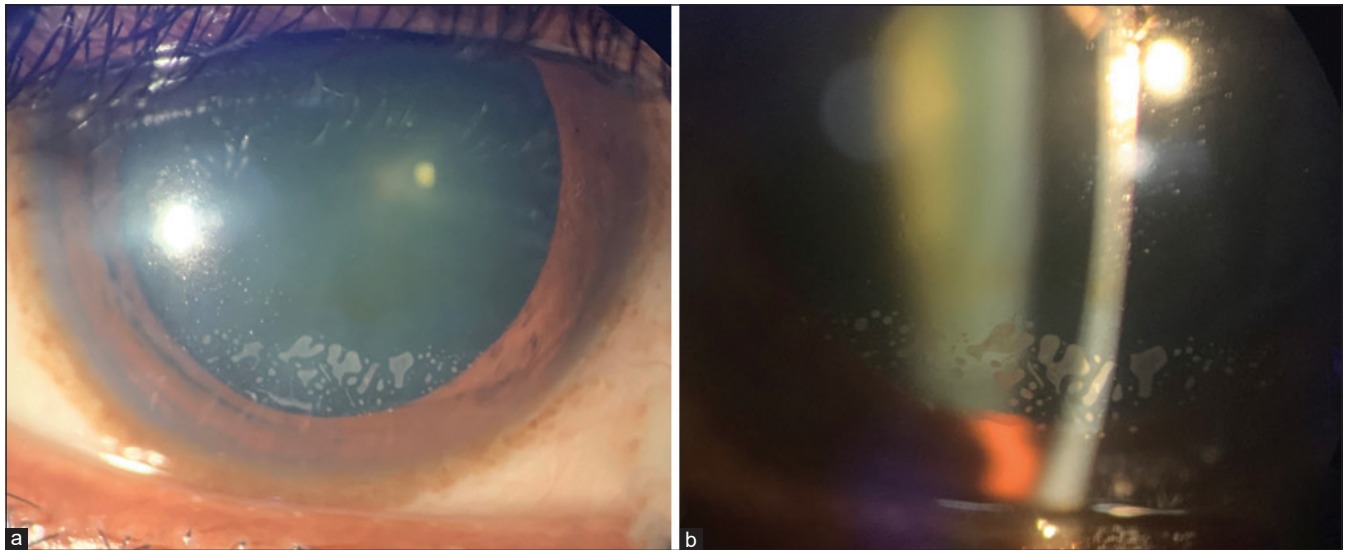


Figure 1: (a and b) Grade 2 epithelial ingrowth in right eye

This is a case of 34-year-old female with epithelial ingrowth at the edge of lasik flap in right eye [Fig. 1a and b] who underwent microkeratome-assisted lasik 6 years ago. As the patient is asymptomatic, with 20/20 uncorrected visual acuity and the ingrowth non-progressive, she has been under observation.

Epithelial basement membrane dystrophy, recurrent corneal erosions, increased age, diabetes, similar history in other eye, button-hole, dislocated flap are few risk factors.^[1-3] Progressive, threatening visual axis, symptomatic (grade 3,4 Probst–Machot classification^[4]) cases require treatment. Complete removal of epithelial cells from stromal bed and undersurface of flap with tight adherence of flap is necessary to prevent recurrences.^[3]

Declaration of patient consent

The authors certify that they have obtained all appropriate patient consent forms. In the form the patient(s) has/have given his/her/their consent for his/her/their images and other clinical information to be reported in the journal. The patients understand that their names and initials will not be published and due efforts will be made to conceal their identity, but anonymity cannot be guaranteed.

Financial support and sponsorship

Nil.

Conflicts of interest

There are no conflicts of interest.

**Pavani M Penugondla, Srinivasa S Sastry,
Sreenivasa P Rao**

Department of Cornea and Refractive Surgery,
Sreenetralaya Eye Hospital, Secunderabad, Telangana, India

Correspondence to: Dr. Pavani M Penugondla,
Department of Cornea and Refractive Surgery,
Sreenetralaya Eye Hospital, SBI Colony, Kothapet,
Hyderabad - 500 035, Telangana, India.
E-mail: murthy.pavani@gmail.com

References

1. Ting DSJ, Srinivasan S, Danjoux J. Epithelial ingrowth following laser *in situ* keratomileusis (LASIK): Prevalence, risk factors, management and visual outcomes. *BMJ Open Ophthalmol* 2018;3:e000133.
2. Asano-Kato N, Toda I, Hori-Komai Y, Takano Y, Tsubota K. Epithelial ingrowth after laser *in situ* keratomileusis: Clinical features and possible mechanisms. *Am J Ophthalmol* 2002;134:801-7.
3. Narvaez J, Chakrabarty A, Chang K. Treatment of epithelial ingrowth after LASIK enhancement with a combined technique of mechanical debridement, flap suturing, and fibrin glue application. *Cornea* 2006;25:1115-7.
4. Krachmer JH, Mannis MJ, Holland EJ, Neff KD, Probst LE. LASIK complications. In: Krachmer JH, Mannis MJ, Holland EJ, editors. *Cornea: Surgery of the Cornea and Conjunctiva*. 3rd ed. St. Louis, MO: Mosby; 2011. p. 1861-82io.

This is an open access journal, and articles are distributed under the terms of the Creative Commons Attribution-NonCommercial-ShareAlike 4.0 License, which allows others to remix, tweak, and build upon the work non-commercially, as long as appropriate credit is given and the new creations are licensed under the identical terms.

Access this article online	
Quick Response Code:	Website: www.ijo.in
	DOI: 10.4103/ijo.IJO_221_20

Cite this article as: Penugondla PM, Sastry SS, Rao SP. Epithelial ingrowth—Islands in the clear sea. *Indian J Ophthalmol* 2020;68:3036.