

Intraoral Oncocytic Mucoepidermoid Carcinoma - A Rare Case Report and Review of the Literature

Pawat Sripodok, Sopee Poomsawat, Rachai Juengsomjit, Theerachai Kosanwat

Department of Oral and Maxillofacial Pathology, Faculty of Dentistry, Mahidol University, Bangkok, Thailand

Abstract

Rationale: Oncocytic mucoepidermoid carcinoma (OMEC) is a rare variant of mucoepidermoid carcinoma (MEC). The parotid gland is the most common site of OMEC, whereas intraoral OMEC is infrequent. **Patient Concerns:** A 55-year-old male presented with an asymptomatic mass at the palate for 20 years. **Diagnosis:** Incisional biopsy showed classic MEC. **Treatment:** The patient underwent partial maxillectomy under general anaesthesia. The excised specimen revealed sheets of oncocytes additional to the tumour cells found in the incisional biopsy. Additional special stain and immunohistochemical stain confirmed the diagnosis of OMEC. **Outcomes:** The patient was followed up for 3 years with no recurrence. **Take-away Lessons:** The diagnosis of OMEC needs to be differentiated from other salivary gland tumours containing oncocytes. Moreover, the conventional grading system applied to OMEC may not correlate with their behavior and may need further review.

Keywords: Carcinoma, immunohistochemistry, mucoepidermoid, oncocyte, salivary glands

INTRODUCTION

Mucoepidermoid carcinoma (MEC) is the most common malignant salivary gland neoplasm, occurring over a wide age range with the mean age in the sixth decade of life.^[1] The histopathological features of MEC consist of three types of cells, namely mucinous, intermediate, and squamous cells.^[2] In addition to these cells, other cell types including clear cell, spindle cell, goblet cell, and oncocyte may be found.^[3]

Oncocytic MEC (OMEC) is characterized when MEC is predominant with oncocytes. Seventy-seven cases of OMECs have been reported, most of these cases occurred in the parotid gland,^[2,4] whereas only eight well-documented cases originated from intraoral minor salivary glands.

Hereby, we present an additional case of OMEC of the palate of a Thai patient. To confirm the diagnosis, special stains and immunohistochemical stains were applied. Details from prior reports of intraoral OMECs are also summarized in this article.

CASE REPORT

A 55-year-old male was referred to our institute for the management of an asymptomatic mass of the palate. The

patient reported that the mass was present for over 20 years and the mass expressed a clear fluid at times. The patient had no associated systemic disease with the tumour. Extraoral examination revealed no facial abnormality or regional lymphadenopathy. Intraoral examination revealed a submucosal mass, rubbery in consistency [Figure 1a]. Nearby teeth showed normal responses to the vitality test and mobility test.

Periapical radiograph showed no significant bony abnormalities [Figure 1b], whereas T2-weighted magnetic resonance imaging demonstrated a heterogeneous mass with a well-defined margin. In the coronal plane [Figure 1c], the tumour invaded the floor of the right nasal cavity and the medial wall of the maxillary sinus.

Address for correspondence: Dr. Pawat Sripodok, Department of Oral and Maxillofacial Pathology, Faculty of Dentistry, Mahidol University, 6, Yothi Road, Ratchatewi District, Bangkok 10400, Thailand.
E-mail: pawat.sri@mahidol.ac.th

Received: 30-04-2021

Last Revised: 11-10-2021

Accepted: 14-10-2021

Published: 01-02-2022

This is an open access journal, and articles are distributed under the terms of the Creative Commons Attribution-NonCommercial-ShareAlike 4.0 License, which allows others to remix, tweak, and build upon the work non-commercially, as long as appropriate credit is given and the new creations are licensed under the identical terms.

For reprints contact: WKHLRPMedknow_reprints@wolterskluwer.com

How to cite this article: Sripodok P, Poomsawat S, Juengsomjit R, Kosanwat T. Intraoral oncocytic mucoepidermoid carcinoma - A rare case report and review of the literature. *Ann Maxillofac Surg* 2021;11:313-6.

Access this article online

Quick Response Code:



Website:
www.amsjournal.com

DOI:
10.4103/ams.ams_115_21

Incisional biopsy revealed that the tumour mass contained mucus-secreting cells, epidermoid cells, and intermediate cells arranged in islands, cords, and sheets. Varying-sized cystic spaces were found within the mass, and mucins were found within these spaces. Therefore, the diagnosis of MEC was given.

The patient underwent a partial maxillectomy under general anaesthesia [Figure 2]. The tumour was removed, and the resultant defect was reconstructed with a buccal fat pad flap and skin graft from the upper thigh. An immediate surgical obturator was inserted [Figure 3a], and the patient was referred to a maxillofacial prosthodontist for further prosthetic rehabilitation.

The excised specimen [Figure 3b] primarily consisted of sheets of numerous oncocytes, occupying approximately 70% of the tumour mass [Figure 4a]. A small area of conventional MEC features was also observed [Figure 4b]. To confirm the diagnosis, mucicarmine, phosphotungstic acid haematoxylin (PTAH), and immunohistochemical staining using antibodies against AE1/AE3, and p63 were applied [Figure 5a-d]. Since cystic spaces occupied more than 25%, no pronounced nuclear atypia, necrosis, anaplasia, or perineural invasion were identified and the tumour was categorized as low-grade. The margins of the specimen were tumour free, and the patient was followed up for 3 years with no recurrence.

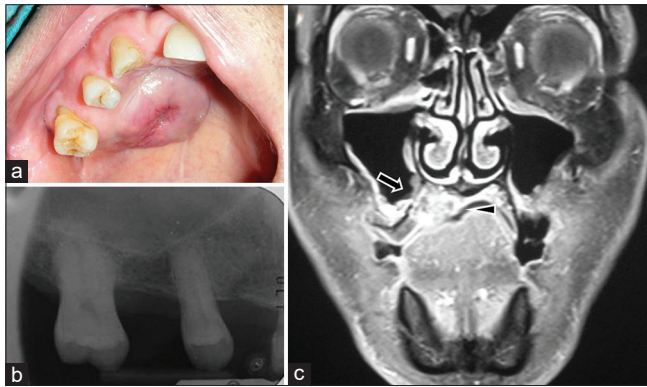


Figure 1: (a) A mass at the palate with an ulcer at the center. (b) Periapical film shows no bony abnormality. (c) Magnetic resonance imaging shows the tumour invades the floor of the nasal cavity (arrowhead), and medial wall of the maxillary sinus (arrow)

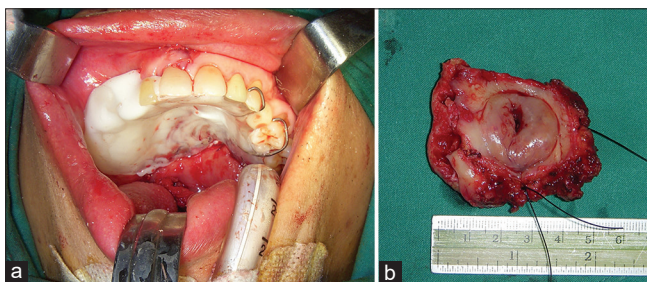


Figure 3: Postoperative images of partial maxillectomy. (a) Immediate surgical obturator. (b) Specimen after tumour surgical resection

DISCUSSION

To date, the parotid gland (54 cases)^[2,5-8] is the most common site of OMEC, followed by the intraoral minor salivary glands (eight cases),^[2-4,8,9] submandibular gland (four cases),^[10] and sublingual gland (three cases).^[2,8] OMEC has also been reported in other locations including the lacrimal gland, bronchus, trachea, and neck.^[2] The age distribution ranged from 13 to 72 years, with an average of 51.4 years, whereas the male-to-female ratio was 1:1.5.

Histopathologically, OMEC demonstrates features of traditional MEC with predominant oncocytes.^[2] These cells are polygonal-shaped, centrally located round nuclei with prominent nucleoli and abundant granular eosinophilic cytoplasm. Ultrastructural studies have shown that these granules are remarkable hyperplasia of mitochondria.^[4] PTAH staining and immunohistochemical staining with anti-mitochondrial antibodies can be used to confirm these mitochondria.^[6]

Till now, the percentage of oncocytic cells necessary to diagnose OMEC has not been specified. Different authors used a different cutoff threshold for the definition of OMEC, ranging from 50% to 75%.^[2,5,8,9] The percentage of oncocytic components in our case is consistent with previous studies.

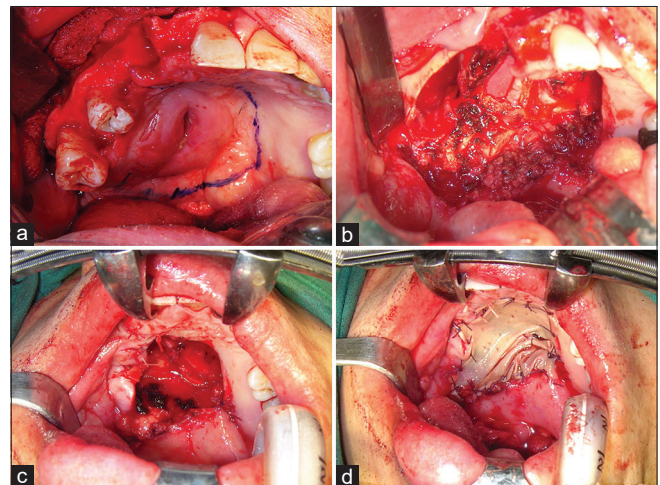


Figure 2: Intraoperative images of partial maxillectomy under general anaesthesia. (a) Surgical outline. (b and c) Tumour removal and reconstruction with buccal fat pad. (d) Skin graft placement

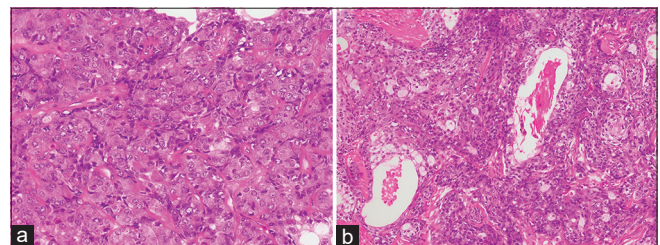


Figure 4: H and E stain (a) Sheets of oncocytes are presented in the tumour. (b) Mucous cells, intermediate cells, and epidermoid cells, with various sizes of cystic spaces

When MEC elements are scarce, the diagnosis of OMEC becomes challenging, as other tumours can also be composed of oncocytes.^[2] OMEC should be differentially diagnosed from its mimics, especially Warthin's tumour, pleomorphic adenoma, and oncocytoma as these entities are benign. Distinct histopathological characteristics such as lymphoid stroma in Warthin's tumour, and epithelial and myoepithelial/stromal components in pleomorphic adenoma^[1] can be used to separate

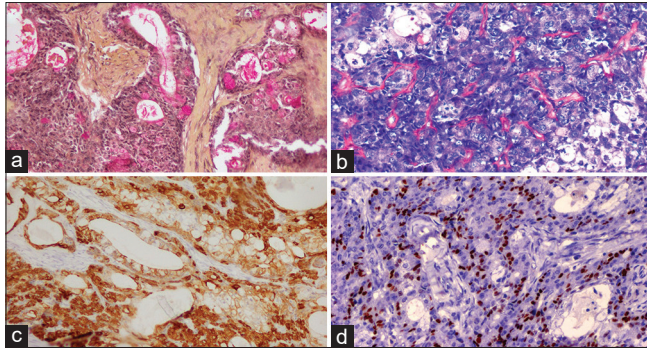


Figure 5: (a) Mucous cells are highlighted in pink color by Mucicarmine. (b) Cytoplasmic granules are stained by blue color from PTAH. (c) Both oncocytic and nononcocytic tumour cells are strongly positive for AE1/AE3. (d) Tumour cells show nuclear positivity to p63

them from OMEC. Other malignant neoplasms, in particular, acinic cell carcinoma, salivary duct carcinoma, and oncocytic carcinoma can also have oncocytes in their components.^[2,4] Antibody directed against p63 have proved to be helpful, as OMEC generally showed nuclear positivity to p63 in a diffuse pattern, whereas oncocytoma and oncocytic carcinoma exhibited a peripheral pattern.^[2,7] Acinic cell carcinoma and salivary duct carcinoma exhibited a peripheral pattern for p63.^[2,3] However, diffuse p63 activity was not seen in all OMECs; in these instances, genetic profiling should be conducted. MECs are known to hold CRTC1-MAML2 or CRTC3-MAML2 gene fusion.^[8]

The problem arises for pathologists when dealing with small specimens from the incisional biopsy. If the specimen is primarily composed of oncocytes, misdiagnosis may be the result. Published cases were initially misidentified because there were insufficient representative mucous cells. Consequently, they were favoured as oncocytoma^[6,9] and Warthin's tumour.^[7] Recently, a series of cases were retrospectively reclassified as OMEC while their original diagnoses were other benign and malignant tumours containing oncocytes.^[8] This validates that an overwhelming amount of oncocytes can be deceiving. Surgeons should be aware that if the pathological results are unclear or contradict the clinical presentation, re-biopsy should be considered.

Table 1: Intraoral oncocytic mucoepidermoid carcinoma reported in the English-language literature

Author/year	Age (year)/sex	Site	Histological grading (system)	Oncocytic components (%)	Additional stains	Original diagnosis	Treatment	Outcome (m)
Weinreb et al./2009 ^{[2]*}	57/female	Palate	Low (AFIP) Intermediate (BW)	>50	Mucicarmine (+), p63 (+)	-	Surgical excision ^o	-
Kwon et al./2010 ^[3]	44/male	Retromolar area	High (AFIP, BW)	-	AMA (+), CK (+), EMA (+), p63 (+), Ki-67 (+)	OMEC	Partial mandibulectomy	4 NED
Behera et al./2016 ^[9]	60/female	Palate	Low (AFIP)	-	CK (+), EMA (+), CEA (+), S-100 (+), Ki-67 (6%)	FNA: Oncocytoma	Surgical excision	-
Kumar et al./2017 ^[4]	43/female	Palate	Low (-)	-	Mucicarmine (+)	Classic MEC	Hemi-maxillectomy	-
Skálová et al./2020 ^[8]	13/female	Palate	Low (AFIP) Intermediate (BW)	>75	p63 (+), Ki-67 (1%–10%)	OMEC	Surgical excision ^o	184 NED
	51/female	Palate	Intermediate (AFIP, BW)	>75	p63 (+), Ki-67 (1%–10%)	Oncocytic neoplasm	Surgical excision ^o	48 NED
	72/male	Tongue	Intermediate (AFIP) High (BW)	>75	p63 (+), Ki-67 (30%)	Myoepithelial carcinoma	Surgical excision ^o	20 DOD, lymph node metastasis
	56/male	Base of Tongue	Low (AFIP) Intermediate (BW)	>75	p63 (+), Ki-67 (1%–10%)	Oncocytoma	Surgical excision ^o	6 NED
Presented case	55/male	Palate	Low (AFIP, BW)	70	Mucicarmine (+), PTAH (+), AE1/AE3 (+), p63 (+) S-100 (-), SMA (-), Ki-67 (-)	Classic MEC	Partial maxillectomy	36 NED

*Weinreb et al.^[2] reported 12 cases of OMECs. Only 1 case was intraoral, but they did not specify the data of each case except the usage of mucicarmin and immunohistochemistry for p63. ^oThe authors reported series of cases but did not state which case(s) was further treated with radiotherapy. -: Not known, NED: No evidence of disease, DOD: Dead of disease. AFIP: AFIP grading system, BW: Brandwein grading system, MEC: Mucoepidermoid carcinoma, OMEC: Oncocytic MEC, AMA: Antimitochondrial antibody, CK: Cytokeratin, EMA: Epithelial membrane antigen, CEA: Carcinoembryonic antigen, SMA: Smooth muscle actin, FNA: Fine-needle aspiration

MEC has been histologically categorized by various groups, sharing three grades with different criteria. Low- and moderate-grade MECs were usually treated with surgical excision, whereas high-grade MEC was further managed with radiotherapy with or without chemotherapy.^[8] The majority of OMECs were categorized as low grade, followed by moderate grade and high grade. Till now, there have been recurrences in four patients, of which three cases were low grade.^[2,5] These occasions may infer that current grading systems may not match up to the tumour's nature. Thus, the treatment of this variant may need further reviews. Nevertheless, long-term follow-up is recommended as there was one instance of recurrence up to 96 months.^[2]

For intraoral OMECs, [Table 1], the most common site was palate (six cases), tongue (two cases), and retromolar area. They appeared to be low-to-intermediate-grade tumours. However, there was one occurrence of lymph node metastasis from a high-grade tumour, which is the sole case that resulted in a patient's death from the disease. The tumour was originally diagnosed as myoepithelial carcinoma but later reclassified as OMEC by utilizing MAML2 gene fusion, retrospectively.^[8] Overall, intraoral OMECs tend to have a good prognosis and can be treated like traditional MEC. Regardless, the role of radiotherapy as a regimen is still inconclusive. Due to the limited studies, the behavior of intraoral OMEC is still indefinite, and more information is required to shed light on this tumour.

CONCLUSION

Diagnosis of OMEC conventionally is not difficult if the presence of mucous cells is obvious. Additional investigations should be considered if the existence of oncocytes is overwhelming, as these cells can mislead the diagnosis. The available grading scheme may not correlate with OMEC and may affect the treatment approach. Due to rare occurrences, we believe that it is important to mention this variant, as it remains unknown whether the oncocytic variant acts uniquely from the classic MEC.

Declaration of patient consent

The authors certify that they have obtained all appropriate patient consent forms. In the form, the patient has given his consent for his images and other clinical information to be reported in the journal. The patient understands that

name and initials will not be published and due efforts will be made to conceal identity, but anonymity cannot be guaranteed.

Acknowledgements

The authors would like to thank the staff of the Department of Oral and Maxillofacial Pathology, Department of Oral and Maxillofacial Surgery, Faculty of Dentistry, Mahidol University. The authors are grateful to Assistant Professor Dr. Boworn Klongnoi for the clinical images and information.

Financial support and sponsorship

Nil.

Conflicts of interest

There are no conflicts of interest.

REFERENCES

1. El-Naggar AK, Chan JK, Grandis JR, Takata T, Slootweg PJ. WHO Classification of Head and Neck Tumours. Lyon: International Agency for Research on Cancer; 2017. p. 163-4.
2. Weinreb I, Seethala RR, Perez-Ordoñez B, Chetty R, Hoschar AP, Hunt JL. Oncocytic mucoepidermoid carcinoma: Clinicopathologic description in a series of 12 cases. *Am J Surg Pathol* 2009;33:409-16.
3. Kwon H, Lim W, Choi Y, Nam J, Han C, Kim J, *et al.* High-grade oncocytic mucoepidermoid carcinoma of the minor salivary gland origin: A case report with immunohistochemical study. *Oral Surg Oral Med Oral Pathol Oral Radiol Endod* 2010;109:e72-7.
4. Kumar R, Natarajan S, Sneha KS, Chitra NS, Boaz K, Manaktala N. Oncocytes in mucoepidermoid carcinoma of the palate: Diagnostic challenges. *Case Rep Dent* 2017;2017:1-4.
5. Jahan-Parwar B, Huberman RM, Donovan DT, Schwartz MR, Ostrowski ML. Oncocytic mucoepidermoid carcinoma of the salivary glands. *Am J Surg Pathol* 1999;23:523-9.
6. Deveci MS, Deveci G, Günhan O, Finci R. Oncocytic mucoepidermoid carcinoma of the parotid gland: Report of a case with DNA ploidy analysis and review of the literature. *Pathol Int* 2000;50:905-9.
7. Qayoom S, Singh AK, Chakrabarti D, Singh HP, Singh US. Oncocytic mucoepidermoid carcinoma (OMEC) of the parotid gland in a 12-year-old patient: A diagnostic challenge on cytology. *Diagn Cytopathol* 2020;49:60-4.
8. Skálová A, Agaimy A, Stanowska O, Baneckova M, Ptáková N, Ardighieri L, *et al.* Molecular profiling of salivary oncocytic mucoepidermoid carcinomas helps to resolve differential diagnostic dilemma with low-grade oncocytic lesions. *Am J Surg Pathol* 2020;44:1612-22.
9. Behera S, Kar A, Rath G, Biswal P, Dutta G, Burma S, *et al.* Oncocytic variant of mucoepidermoid carcinoma of palate with extensive clear cell change: A rare case at unusual site. *Asian J Pharm Health Sci* 2016;6:1426-8.
10. Avila RE, Samar ME, Ferraris R, Rosa FG. Oncocytic mucoepidermoid carcinoma of the submandibular salivary gland: A challenging differential diagnosis of a very rare tumor. *Ann Clin Case Rep* 2019;4:1-5.