

Ductal adenocarcinoma of the prostate or seminal vesicle adenocarcinoma: An multi-disciplinary team (MDT) case report and literature review

Hao Ning^{a,b}, Yufeng Song^a, Haihu Wu^{a,b}, Dexuan Gao^{a,b}, Jiaju Lyu^{a,b,*}

^aDepartment of Urology, Shandong Provincial Hospital, Cheeloo College of Medicine, Shandong University, Jinan, China;

^bDepartment of Urology, Shandong Provincial Hospital Affiliated to Shandong First Medical University, Jinan, China

Abstract

We introduced a 61-year-old male with ductal adenocarcinoma of the prostate who underwent a tortuous diagnosis and treatment. Multi-disciplinary team meetings organized by our hospital have shown great value in the whole process. The patient presented with gross hematuria accompanied by frequent urination initially, and was diagnosed with ductal adenocarcinoma of the prostate involving right seminal vesicle gland and urethra by urethroscopy biopsy. The clinical stage of tumor was T3bN0M0. After 4 cycles of neoadjuvant chemotherapy, the tumor shrank significantly and the patient underwent a laparoscopic radical prostatectomy. But the patient declined to continue chemotherapy postoperatively. After 10 months, the serum prostatic specific antigen increased to 0.05 ng/mL, and multiple metastases were found in the patient's bilateral lungs. However, an unexpected diagnosis of seminal vesicle adenocarcinoma was put forward from another hospital after supplementary pathologic immunohistochemical examination. Then, after careful discussion and demonstration by our multi-disciplinary team experts, we insisted on the diagnosis of ductal adenocarcinoma of the prostate and suggested that the original regimen of chemotherapy should be continued. Up-to-date, 14 months after the operation, the patient continues to survive while undergoing ongoing active treatment as recommended.

Keywords: Ductal adenocarcinoma; Multi-disciplinary team; Neoadjuvant chemotherapy; Prostate cancer; Seminal vesicle adenocarcinoma; Surgery

1. Introduction

Prostate cancer (PCa) is a common malignant tumor of the male genitourinary system.^[1,2] The main pathologic type of primary PCa is acinar adenocarcinoma of the prostate (AAP), accounting for more than 90% of cases.^[3] Ductal adenocarcinoma of the prostate (DAP) is second only to AAP, accounting for about 0.5%-3.2% of cases.^[4] Due to occult or atypical clinical symptoms, it is difficult to detect DAP at an early stage. At the time of diagnosis, these patients usually have late stage disease and correspondingly poor prognosis.^[5] This paper reports on one case of DAP which was diagnosed and treated by a multidisciplinary team (MDT) in our hospital with the aim of improving clinician understanding of DAP and introducing the value of the MDT model in these complex cases.

2. Case report

A 61-year-old male was admitted to our hospital in May 2020 due to gross hematuria for 2 weeks accompanied by frequent urination. Urethroscopy (Fig. 1) found cauliflower-like tumors on the right side of the posterior urethra extending from the seminal caruncle to the bladder neck. The pathology diagnosis of the biopsy was a papillary tumor highly suspicious for DAP involving the urethra. Immunohistochemical (IHC) staining was positive for prostatic specific antigen (PSA) and P504S, and the Ki67 index was 10%.

Serum PSA level was in the normal range (3.04 ng/mL). Digital rectal examination (DRE) revealed that the prostate was enlarged and firm in texture, with poor range of motion between the prostate and the anterior wall of the rectum. Magnetic resonance imaging (MRI) (Fig. 2) demonstrated a prostate volume of approximately 5.0 × 4.6 × 3.9 cm. A focus of abnormal signal measuring 4.8 × 3.6 cm was primarily located in the central glandular area, involving the right peripheral zone and the right seminal vesicle gland, locally compressing the posterior wall of the bladder, and surrounding the urethra. No abnormalities were identified on whole body bone scan.

Considering the rarity and complexity of advanced DAP, we convened an MDT meeting, including urology, radiology, pathology, and oncology, to determine a clear diagnosis and a preliminary treatment plan. The MDT committee members agreed that DAP should be considered as the most probable diagnosis, based on the following: (1) the history of hematuria

*Corresponding Author: Jiaju Lyu, Department of Urology, Shandong Provincial Hospital, Shandong University, 324 Jingwuweiqi Road, Jinan, 250021, China. E-mail address: kyoto2310@sina.com (J. Lyu).

HN and YS contributed equally to this work.

Current Urology, (2022) 16, 107–113

Received November 16, 2021; Accepted January 6, 2022.

<http://dx.doi.org/10.1097/CU9.0000000000000084>

Copyright © 2022 The Authors. Published by Wolters Kluwer Health, Inc. This is an open access article distributed under the terms of the Creative Commons Attribution-Non Commercial-No Derivatives License 4.0 (CCBY-NC-ND), where it is permissible to download and share the work provided it is properly cited. The work cannot be changed in any way or used commercially without permission from the journal.

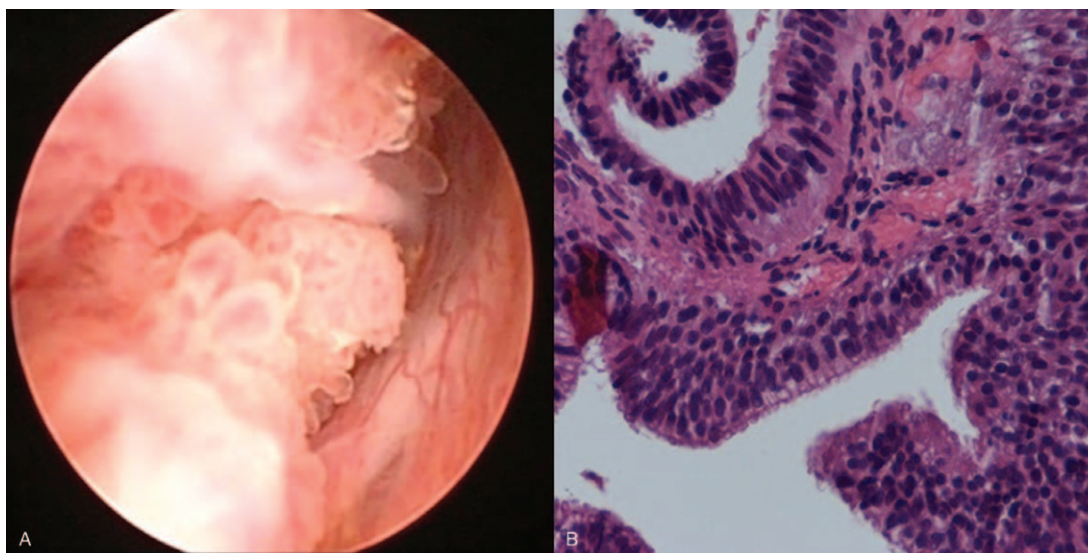


Figure 1. Cauliflower-like tumor of posterior urinary tract (A) and biopsy with HE staining (B) ($\times 40$).

and DRE and imaging results were consistent with a prostate malignant tumor; (2) positive staining for PSA expression in the biopsy pathology confirmed a prostatic origin; (3) the tumor was papillary in morphology. The tumor stage was determined to be T3bN0M0 due to invasion of the seminal vesicle. Moreover, the extent of the focus was large, with part of the border with the posterior wall of the bladder and the anterior wall of the rectum being unclear. Although surgical excision was the best therapeutic option, it was considered difficult at that time, with a high risk of a positive margin and tumor recurrence. Therefore, before proceeding with the next stage of treatment, it was deemed appropriate to first use neoadjuvant therapy to reduce the bulk of the tumor. Finally, after discussion among MDT experts, the patient was advised to receive 4 to 6 cycles of neoadjuvant chemotherapy of docetaxel combined with cisplatin (DP), supplemented by androgen-deprivation therapy (ADT).

The patient began to receive neoadjuvant therapy in July 2020. Three months later, after 4 cycles of neoadjuvant chemotherapy, the lesion decreased in size to 3.5×3.3 cm (Fig. 3). The serum PSA level decreased to 0.072 ng/mL and serum testosterone decreased to 0.29 ng/mL. Reexamination by DRE revealed that the prostate was smaller and slightly softer in texture, and the range of motion between the prostate and the rectum was increased. In order to evaluate the efficacy of neoadjuvant therapy, we convened a second MDT meeting. MDT experts assessed that the patient had achieved a state of partial remission after neoadjuvant therapy and qualified for radical surgery.

In October 2020, the patient underwent laparoscopic radical prostatectomy and bilateral pelvic lymph node dissection. Final postoperative pathology was a diagnosis of DAP (Fig. 4A), with local mucinous adenocarcinoma (Fig. 4B), involving the right seminal vesicle gland. No cancer cells were detected in the resection margins or five resected lymph nodes. We again convened an MDT meeting to decide upon the postoperative plan. It was noted that postoperative pathology was consistent with the initial diagnosis based on biopsy, but only 4 cycles of chemotherapy had been completed before the operation. During this third MDT meeting discussion, it was recommended that the initial DP regimen should be continued for 3 to 4 additional

cycles combined with ADT, and during postoperative follow-up, attention should be paid to serial serum PSA levels and imaging.

However, the patient declined to continue chemotherapy postoperatively and only maintained ADT. Up to 6 months after operation, serum PSA remained at an undetectable level, and no local recurrence or metastasis was found in MRI. Nevertheless, after 10 months, serum PSA increased to 0.05 ng/mL, and multiple spherical nodules were found in the bilateral lungs on chest CT imaging (Fig. 5). These nodules were considered to be new metastases due to moderate enhancement.

Postoperative supplementary pathologic IHC staining was conducted in our hospital to determine individualized treatment. Results were negative for PSA, prostate specific acid phosphatase (PSAP), and carbohydrate antigen 125 (CA125). Additionally, expression of androgen receptor (AR), P504S, CK7, CK20, and carcinoembryonic antigen (CEA) were all positive. Inconsistent with preoperative biopsy results, both PSA and PSAP were negative, leading to new uncertainty about origin of the tumor. Subsequently, the patient sought a second opinion at another hospital, where supplementary IHC staining was negative for PSA, MUC6, PAX2, and PAX8. Ki67 staining was positive, but only 1% of cells. Quite unexpectedly, the other hospital gave a pathologic diagnosis of seminal vesicle adenocarcinoma (SVA) involving the prostate. PET-CT also indicated multiple metastases in bilateral lungs. Genetic testing suggested that chemotherapeutic drugs including taxanes, platinum, pyrimidine analogues and vinblastine should be recommended. The final recommended treatment was the FOLFOX regimen (oxaliplatin/folic acid/5-Fu), which is usually used for gastrointestinal cancer.

In order to further explore the diagnosis and treatment of the tumor, we held a fourth MDT meeting. The main points supporting a diagnosis of SVA put forward by the other hospital included: (1) the tumor is centered in the seminal vesicle gland, and no cancer is found in the prostate. (2) The tumor has an adenocarcinoma structure, commonly find with papillary, flaky or mucinous differentiation, and near the seminal vesicle with precancerous lesions. (3) IHC staining is positive for CEA, but negative for PSA and PSAP. The other hospital concluded that all

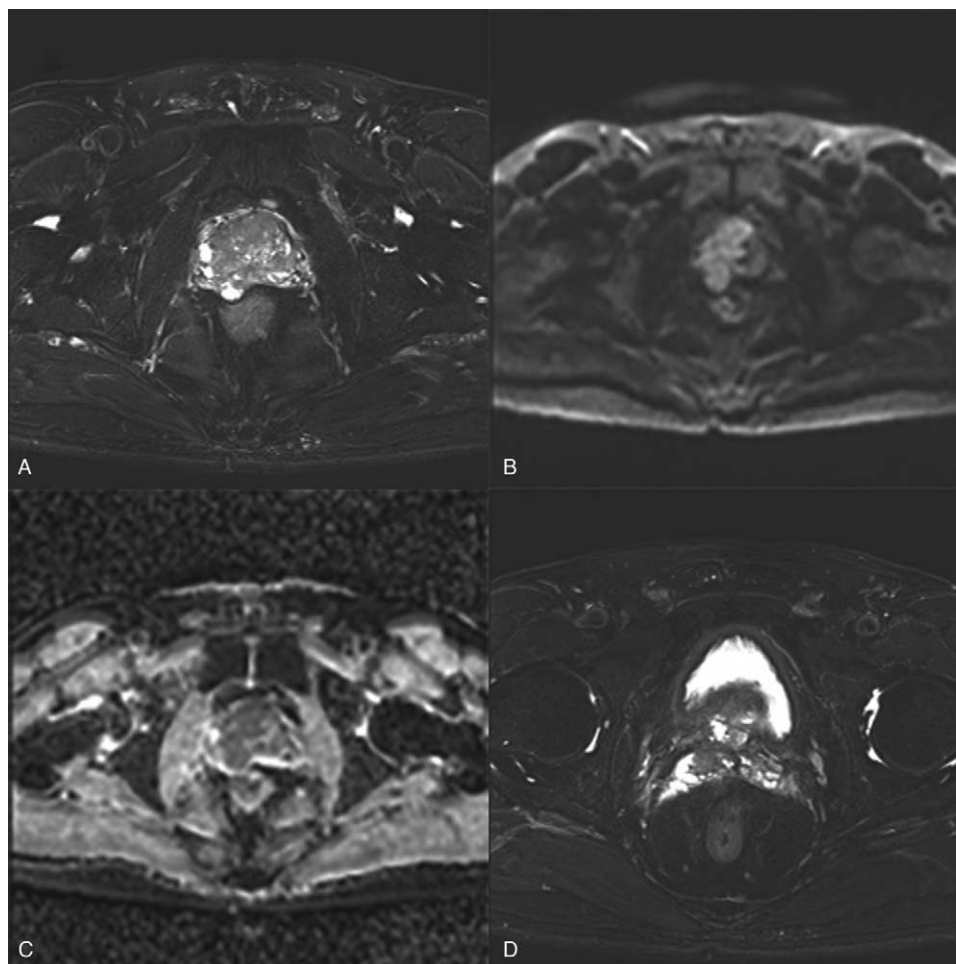


Figure 2. Obvious abnormal signal foci of the prostate seen on MRI T2-weighted fat suppression sequence imaging (A), diffusion-weighted imaging (B), and apparent diffusion coefficient imaging(C), also involving the right seminal vesicle gland (D).

criteria for a diagnosis of SVA could be met except for the visible tumor found in the prostate. Therefore, a diagnosis of SVA was given.

After careful discussion, our MDT committee still held its own view. Radiology experts argued that the initial MRI images clearly showed that the main body of the tumor was located within the prostate and only part of the right seminal vesicle gland is involved. Pathology experts acknowledged that although postoperative pathology IHC results were negative for PSA and PSAP, the preoperative biopsy stained positive for PSA, and therefore a prostatic origin could not be ruled out. Chemotherapy may also be responsible for the loss of tumor cell antigens. In addition, most SVAs stain negative for CK20 and positive for CK7, CA125, and MUC6, which were not consistent with this case. Negative expression of PAX2 and PAX8 also did not indicate a seminal vesicle origin. Oncology experts believed that postoperative discovery of lung metastases could be related to the patient’s refusal to continue chemotherapy, and DP chemotherapy, which has known efficacy, should be continued. Finally, after integrating the opinions of experts from various disciplines, the fourth MDT meeting reached consensus on a diagnosis of DAP and recommended that the patient should be treated with a DP chemotherapy regimen as soon as possible.

Up-to-date, 14 months after the operation, the patient continues to survive while undergoing ongoing active treatment.

3. Discussion

PCa mainly occurs in older men aged 60–80 years old.^[1,2] Primary PCa includes AAP, DAP, intraductal carcinoma, urothelial carcinoma, squamous cell carcinoma, and basal cell carcinoma.^[3,4] DAP, as the second most common subtype,^[5] was first reported by Melicow and Patcher in 1967.^[6]

It has been confirmed that most DAP tumors originate from large ducts in and around the prostatic urethra, while a few may originate from secondary ducts in the peripheral zone. Both types can occur simultaneously.^[7] The first mostly grows in an exogenous form, a cauliflower-like or polypoid mass protruding from the surface of the urethra which can be seen under endoscopy. Hematuria is a common initial symptom and may be accompanied by lower urinary tract symptoms such as dysuria, frequent or urgent urination. The second type usually shows infiltrative growth into the interior of the prostatic glands. Examination by DRE can identify an enlarged prostate with firm texture, but clinical symptoms are relatively concealed. DAP has a stronger metastatic tendency than AAP, is more prone to visceral metastasis (such as lung and liver), and tends to have a

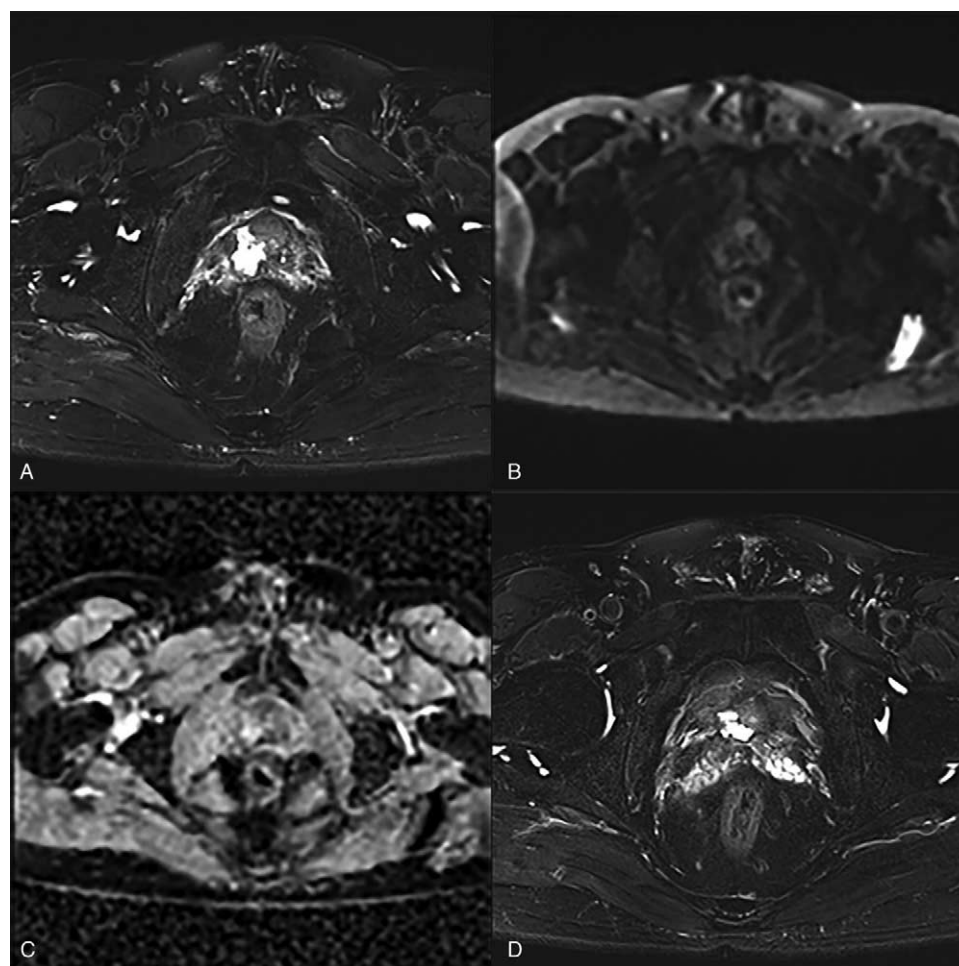


Figure 3. Significant reduction of abnormal signal focus after neoadjuvant therapy seen on MRI T2-weighted fat suppression sequence imaging (A), diffusion-weighted imaging (B), and apparent diffusion coefficient imaging(C), including the part of the right seminal vesicle gland (D).

worse prognosis.^[5,8,9] The case described in this paper is consistent with these clinical manifestations of DAP, including lung metastasis.

The serum PSA level of patients with DAP may be normal or only increased slightly,^[1] as in this case, which may be related to the poor secretory function of ductal epithelium. Morgan et al.^[10] found that the average PSA level in patients with DAP is significantly lower than that in patients with AAP, and the probability of a normal PSA is more than twice as likely that of AAP. MRI findings for DAP and AAP are similar. Polycystic changes may be seen more often in DAP, but it is usually difficult to differentiate them by imaging. PET-CT is of special value in preoperative systemic assessment, postoperative monitoring and follow-up, which can identify metastatic lesions not found by ordinary imaging or bone scan.^[9]

Histopathology is the gold standard for the diagnosis of DAP. The morphology may be papillary, cribriform, solid, or prostatic intraepithelial neoplasia-like structure. The main histological features are that the tumor epithelial cells are high columnar pseudostratified epithelium, with slender and oval nucleus and obvious nucleoli, while typical AAP tumor epithelial cells are cube-shaped.^[2,11] The profile of IHC staining can be similar to AAP. Prostate tissue specific markers such as PSA and PSAP are usually positive. However, the above markers have been

reported to be negative in both subtypes.^[12–14] P504S testing is also often used to improve the diagnostic accuracy of PCa, but it can also be expressed in other tumors such as renal cell carcinoma.^[15] The value of Ki67 in DAP is often higher than that of AAP tumors with the same Gleason Score, which represents a higher degree of malignancy.^[16]

This case was difficult to distinguish from SVA, a rare tumor of the male reproductive system. The key point lies in the lack of evidence of tumor origin. In recent years, the main agreed criteria for the diagnosis of primary SVA are as follows^[17]: (1) the primary tumor is located in the seminal vesicle gland and there is no prostate tumor; (2) undifferentiated carcinoma of the seminal vesicle can secrete mucin, while undifferentiated carcinoma of the prostate does not; (3) IHC staining must be negative for PSA and PASP, and IHC staining positive for CA125 or an elevated serum CA125 level can strongly indicate SVA, but in tumors with low or moderate differentiation CA125 may be negative. In addition, the IHC staining profile of SVA consists of MUC6 positive, CK7 positive, and CK20 negative results.^[17–19] Positive staining for PAX2 and PAX8 expression can indicate malignant tumors derived from mesonephric duct-derived reproductive organs such as the seminal vesicle or vas deferens.^[20] This case does not meet the above criteria, except negative for PSA and PSAP and locally mucinous adenocarcinoma. Therefore, all of

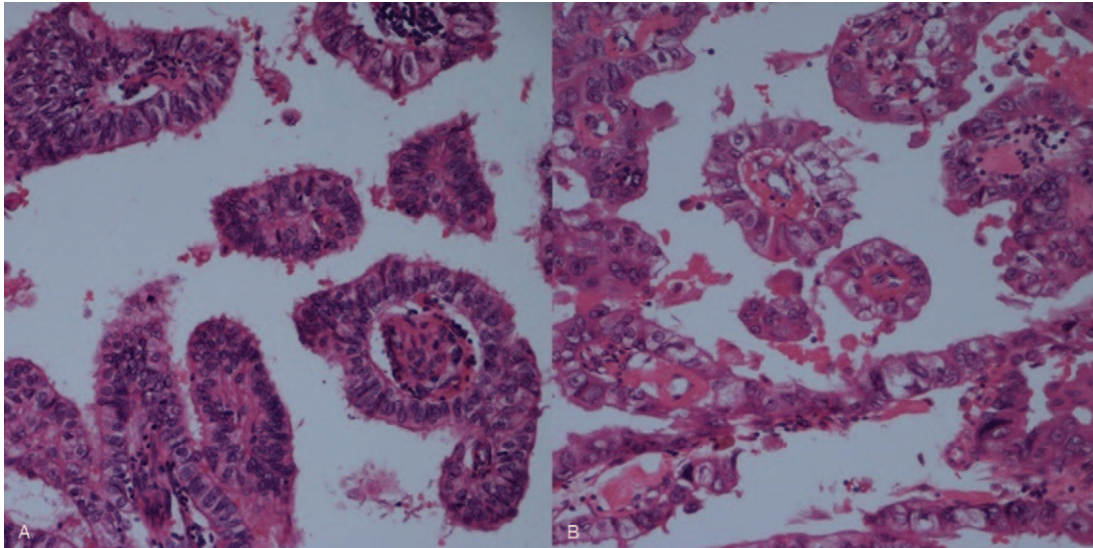


Figure 4. Postoperative pathologic microscopic view: the tumor showed papillary structure with stratified columnar epithelium and morphologically resembled ductal adenocarcinoma of the prostate (A), and mucus secretion was seen in some of the cells (B).

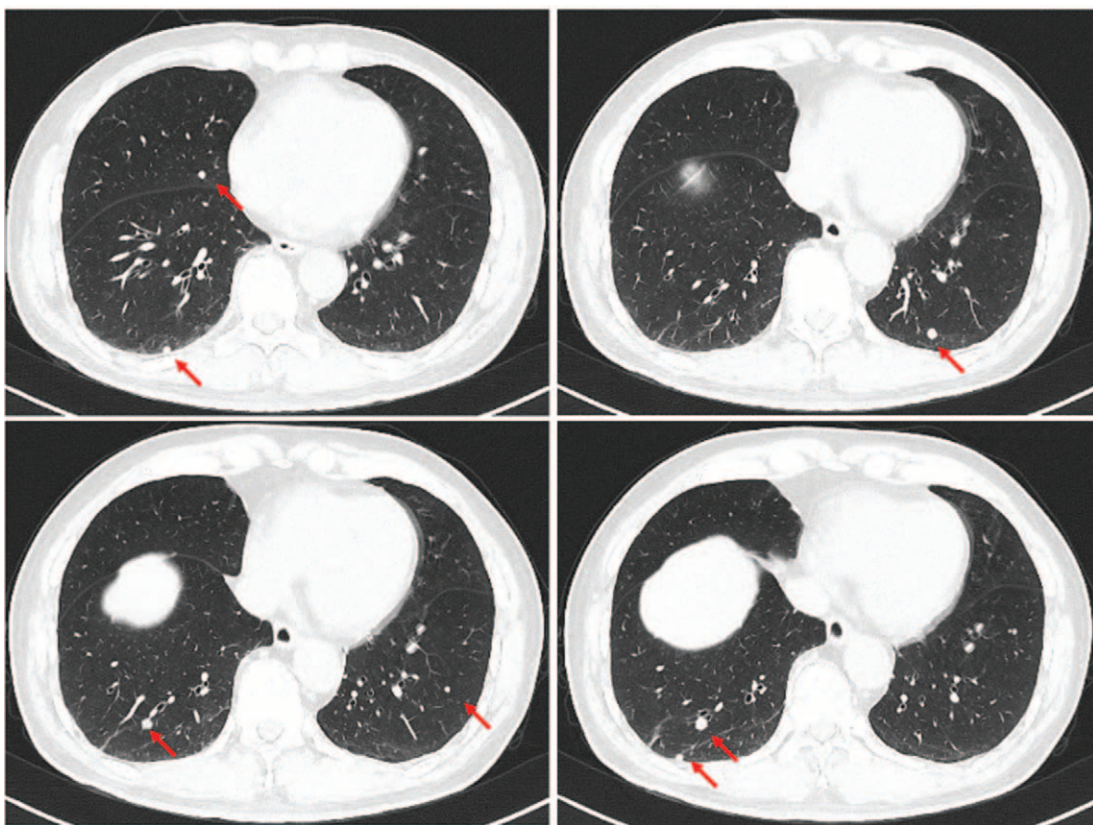


Figure 5. Multiple metastases (red arrows) of bilateral lungs on enhanced chest CT imaging.

the experts from our MDT committee agreed that the evidence for a final diagnosis of DAP was more convincing.

Thus far, there are no clear guidelines for the treatment of DAP. Usually, the treatment protocol for AAP with the same Gleason Score is used for DAP, with active radical surgical excision being the preferred option. Studies have shown that

surgical treatment can achieve a longer survival time than radiotherapy or systemic chemotherapy, especially in patients with non-metastatic DAP.^[1,21] Other studies have shown that radiotherapy can effectively reduce the risk of death in DAP patients without lymph node or distant metastases, and cancer-specific mortality is similar to that of patients undergoing radical

surgery.^[3,22] Importantly, compared with AAP, DAP is more invasive, has a shorter progression-free survival time and a higher cancer-specific mortality, regardless of metastasis status or surgery.^[5,21,23–25] Therefore, patients with DAP should be advised to receive multimodal comprehensive treatment.

Currently, it is generally believed that DAP may be less responsive to ADT than AAP, although ADT may still be effective.^[7] It has been reported that radical prostatectomy combined with ADT can achieve a longer progression-free survival in the treatment of advanced metastatic DAP.^[26] Docetaxel has been used in standard chemotherapy for advanced AAP. Some cases have reported that docetaxel can also benefit metastatic DAP patients,^[27] but there are also reports of poor efficacy.^[9] Kamiyama et al.^[28] described two DAP patients who did not respond to docetaxel, both of which responded well to a gemcitabine combined with cisplatin regimen. This patient received a neoadjuvant chemotherapy DP regimen recommended by the MDT committee which achieved a significant therapeutic effect, providing an important reference for the formulation of treatment plans for patients with advanced DAP.

It should be noted that the value of serial PSA measurement is limited in terms of prediction of recurrence or metastasis.^[1,7,11] Some studies have shown that patients with DAP who maintain low PSA levels may also have local recurrence or metastasis.^[8] For this reason, clinicians should pay attention to imaging examinations in the long-term management of DAP patients.^[8] PET-CT imaging is worth consideration for inclusion as an option during follow-up.^[9] Furthermore, for complex and refractory cases, it must be recognized that the MDT model is of great value in customizing individualized treatment regimens and should therefore be promoted more widely.

Acknowledgments

The authors thank all the radiology, pathology, oncology, and related MDT staff for their cooperation.

Statement of ethics

This study was approved by the Institutional Review Board of the Ethics Committee of Shandong Provincial Hospital, with an approval number (SWYX: No. 2022-009). The patient has given written consent for the publication of this manuscript. All procedures performed in study involving human participants were in accordance with the ethical standards of the institutional and national research committee and with the 1964 Helsinki declaration and its later amendments or comparable ethical standards.

Conflict of interest statement

JL is an Associate Editor of Current Urology.

Funding source

None.

Author contributions

JL contributed to the conception of the study and manuscript revision;
HN contributed significantly to follow-up and manuscript preparation;

YS performed the data analyses and wrote the manuscript;
HW and DG helped perform the analysis with constructive discussions.

All authors read and approved the final manuscript.

References

- [1] Bronkema C, Arora S, Keeley J, et al. Impact of treatment modality on overall survival in localized ductal prostate adenocarcinoma: A national cancer database analysis. *Urol Oncol* 2021;39(6):366.e311–366.e318.
- [2] Liu T, Wang Y, Zhou R, et al. The update of prostatic ductal adenocarcinoma. *Chin J Cancer Res* 2016;28(1):50–57.
- [3] Chierigo F, Borghesi M, Wurnschimmel C, et al. Survival after radical prostatectomy vs. radiation therapy in ductal carcinoma of the prostate. *Int Urol Nephrol* 2022;54(1):89–95.
- [4] Humphrey PA, Moch H, Cubilla AL, et al. The 2016 WHO classification of tumours of the urinary system and male genital organs-part b: Prostate and bladder tumours. *Eur Urol* 2016;70(1):106–119.
- [5] Bronkema C, Arora S, Sood A, et al. Rare histological variants of prostate adenocarcinoma: A national cancer database analysis. *J Urol* 2020;204(2):260–266.
- [6] Melicow MM, Pachter MR. Endometrial carcinoma of prostatic utricle (uterus masculinus). *Cancer* 1967;20(10):1715–1722.
- [7] Seipel AH, Delahunt B, Samaratunga H, et al. Ductal adenocarcinoma of the prostate: Histogenesis, biology and clinicopathological features. *Pathology* 2016;48(5):398–405.
- [8] Bergamin S, Eade T, Kneebone A, et al. Ductal carcinoma of the prostate: An uncommon entity with atypical behaviour. *Clin Oncol (R Coll Radiol)* 2019;31(2):108–114.
- [9] Martorana E, Micali S, Pirola GM, et al. Management and therapeutic response of a prostate ductal adenocarcinoma: A still unknown tumour? *Urologia* 2016;83(3):163–167.
- [10] Morgan TM, Welty CJ, Vakar-Lopez F, et al. Ductal adenocarcinoma of the prostate: Increased mortality risk and decreased serum prostate specific antigen. *J Urol* 2010;184(6):2303–2307.
- [11] Zhou M. High-grade prostatic intraepithelial neoplasia, PIN-like carcinoma, ductal carcinoma, and intraductal carcinoma of the prostate. *Mod Pathol* 2018;31(5):S71–S79.
- [12] Leite KRM, Mitteldorf C, Srougi M, et al. Cdx2, cytokeratin 20, thyroid transcription factor 1, and prostate-specific antigen expression in unusual subtypes of prostate cancer. *Ann Diagn Pathol* 2008;12(4):260–266.
- [13] Chuang AY, DeMarzo AM, Veltri RW, et al. Immunohistochemical differentiation of high-grade prostate carcinoma from urothelial carcinoma. *Am J Surg Pathol* 2007;31(8):1246–1255.
- [14] Gong Y, Caraway N, Stewart J, et al. Metastatic ductal adenocarcinoma of the prostate: Cytologic features and clinical findings. *Am J Clin Pathol* 2006;126(2):302–309.
- [15] Kourda N, Mlika M, Derouiche A, et al. The utility of alpha-methyl CoA racemase (P504S) expression as a marker of renal cell carcinomas. *Tunis Med* 2010;88(9):651–654.
- [16] Seipel AH, Wiklund F, Wiklund NP, et al. Histopathological features of ductal adenocarcinoma of the prostate in 1,051 radical prostatectomy specimens. *Virchows Arch* 2013;462(4):429–436.
- [17] Navallas M, Vargas HA, Akin O, et al. Primary seminal vesicle adenocarcinoma. *Clin Imaging* 2011;35(6):480–482.
- [18] Ormsby AH, Haskell R, Jones D, et al. Primary seminal vesicle carcinoma: An immunohistochemical analysis of four cases. *Mod Pathol* 2000;13(1):46–51.
- [19] Martinez-Penuela A, Rosario Mercado M, Aldave J, et al. Primary adenocarcinoma of the seminal vesicles. *Arch Esp Urol* 2009;62(8):671–673.
- [20] Posenato I, Calio A, Segala D, et al. Primary seminal vesicle carcinoma. The usefulness of PAX8 immunohistochemical expression for the differential diagnosis. *Hum Pathol* 2017;69:123–128.
- [21] Knipper S, Preisser F, Mazzone E, et al. Contemporary comparison of clinicopathologic characteristics and survival outcomes of prostate ductal carcinoma and acinar adenocarcinoma: A population-based study. *Clin Genitourin Cancer* 2019;17(3):231–237.e2.
- [22] Patel M, Bimali M, Howie C, et al. The role of radiotherapy among patients with prostate ductal adenocarcinoma. *Clin Genitourin Cancer* 2021;19(1):e41–e50.
- [23] Chow K, Bedo J, Ryan A, et al. Ductal variant prostate carcinoma is associated with a significantly shorter metastasis-free survival. *Eur J Cancer* 2021;148:440–450.

- [24] Bardoscia L, Triggiani L, Sandri M, et al. Non-metastatic ductal adenocarcinoma of the prostate: Pattern of care from an urooncology multidisciplinary group. *World J Urol* 2021;39(4):1161–1170.
- [25] Jang WS, Shin SJ, Yoon CY, et al. Prognostic significance of the proportion of ductal component in ductal adenocarcinoma of the prostate. *J Urol* 2017;197(4):1048–1053.
- [26] Cui Y, Miao C, Xu A, et al. Acinar with ductal and mucinous adenocarcinoma of prostate cancer complicated with lung metastasis: A case report and literature review. *Ann Palliat Med* 2021;10(2):2366–2370.
- [27] Fujiwara R, Kageyama S, Tomita K, et al. Metastatic prostatic ductal adenocarcinoma successfully treated with docetaxel chemotherapy: A case report. *Case Rep Oncol* 2015;8(2):339–344.
- [28] Kamiyama Y, Mitsuzuka K, Watanabe M, et al. Chemotherapy with gemcitabine and cisplatin for advanced ductal adenocarcinoma of the prostate: Clinical courses of two patients. *Tohoku J Exp Med* 2015;237(4):317–321.

How to cite this article: Ning H, Song Y, Wu H, Gao D, Lyu J. Ductal adenocarcinoma of the prostate or seminal vesicle adenocarcinoma: An multi-disciplinary team (MDT) case report and literature review. *Curr Urol* 2022;16(2):107–113. doi: 10.1097/CU9.0000000000000084