

Prepectoral Breast Reconstruction: A Technical Algorithm

Benjamin Liliav, MD*†‡
 Pranjal Patel, DO§
 Alice K. Jacobson, MS, PA-C*

Summary: Despite falling out of favor in the 1970s, prepectoral breast reconstruction has resurfaced in the recent years as a safe and effective alternative to subpectoral/partial subpectoral breast reconstruction in carefully selected patients. This article outlines an algorithmic technical approach to prepectoral breast reconstruction for new patients and revision patients. (*Plast Reconstr Surg Glob Open* 2019;7:e2107; doi: 10.1097/GOX.0000000000002107; Published online 13 February 2019.)

BACKGROUND

Although not novel, prepectoral breast reconstruction is one of the most recent advancements in the field of prosthetic breast reconstruction. Conventionally, breast reconstruction has been performed subpectorally with either total or partial muscle coverage of breast implants due to higher complication rates observed in patients after prepectoral breast reconstruction before acellular dermal matrix (ADM) usage. Although subpectoral implant-based reconstruction (IBR) results in good to excellent aesthetic outcomes, elevation of the pectoralis muscle causes the patient significant postoperative pain and can lead to widened cleavage and unsightly animation deformities. With recent advancements in techniques and use of ADMs, fat grafting, and optimally filled cohesive prosthetic devices, prepectoral breast reconstruction has regained its popularity.¹⁻⁶ It has also been shown to be a safe alternative to subpectoral breast reconstruction in appropriately chosen candidates because it eliminates animation deformities, decreases postoperative pain related to muscle trauma, and short hospital stays.^{4,5,7,8} Numerous techniques for ADMs placement in prepectoral IBR have been described; some techniques involve inseting the ADM to the pectoralis muscle in vivo although others involve wrapping the ADM around the prosthetic device ex vivo on a back table.³ However, to date, there has not

been any proposed algorithm to outline specific details and application of these techniques. As more surgeons perform prepectoral breast reconstruction, a safe and effective guideline describing when to use each ADM inseting technique is paramount. This article aims to outline a technical algorithm to prepectoral reconstruction in new and revision patients. In addition, we describe sequential suture technique in detail. This technique was used in our series of prepectoral patients with excellent outcomes.

PREPECTORAL BREAST RECONSTRUCTION

Many techniques for prepectoral IBR have been described in the literature. The reconstruction can be done in 2 stages where a tissue expander (TE) is placed initially with subsequent exchange for a permanent implant. Alternatively, the direct-to-implant (DTI) reconstruction approach can be used.^{2,9} Careful patient selection is important for operative success. Preoperatively, patient characteristics such as metabolic disease (diabetes mellitus), body mass index, smoking status, history of radiation, and oncologic factors are important variables affecting success of subcutaneous reconstruction. Intraoperatively, the skin flap is assessed for vascularity to determine whether it can sustain the tension status postimplant placement directly under it.^{10,11}

Flap Assessment Before Reconstruction

If assessment shows a poorly perfused flap, either an immediate submuscular reconstruction or a delayed prepectoral IBR may be performed. To increase operative success of prepectoral reconstruction on a poorly perfused skin flap, the procedure can be delayed for fat grafting to improve the flap.¹⁰

However, if the flap is found to be well perfused, then immediate prepectoral reconstruction may be attempted. Regardless of a 2-stage or single-stage reconstruction, the type of mastectomy incision determines operative technique for ADM insertion (Fig. 1).

Disclosure: The authors have no financial interest to declare in relation to the content of this article. The Article Processing Charge was paid for by the authors.

From the *Eastern Maine Medical Center, Bangor, Maine; †University of New England College of Medicine, Biddeford, Maine; ‡University of Vermont Medical Center, Burlington, Vt.; and §Drexel University-Hahnemann University Hospital, Philadelphia, Pa.

Received for publication October 9, 2018; accepted November 27, 2018.

Copyright © 2019 The Authors. Published by Wolters Kluwer Health, Inc. on behalf of The American Society of Plastic Surgeons. This is an open-access article distributed under the terms of the Creative Commons Attribution-Non Commercial-No Derivatives License 4.0 (CCBY-NC-ND), where it is permissible to download and share the work provided it is properly cited. The work cannot be changed in any way or used commercially without permission from the journal. DOI: 10.1097/GOX.0000000000002107

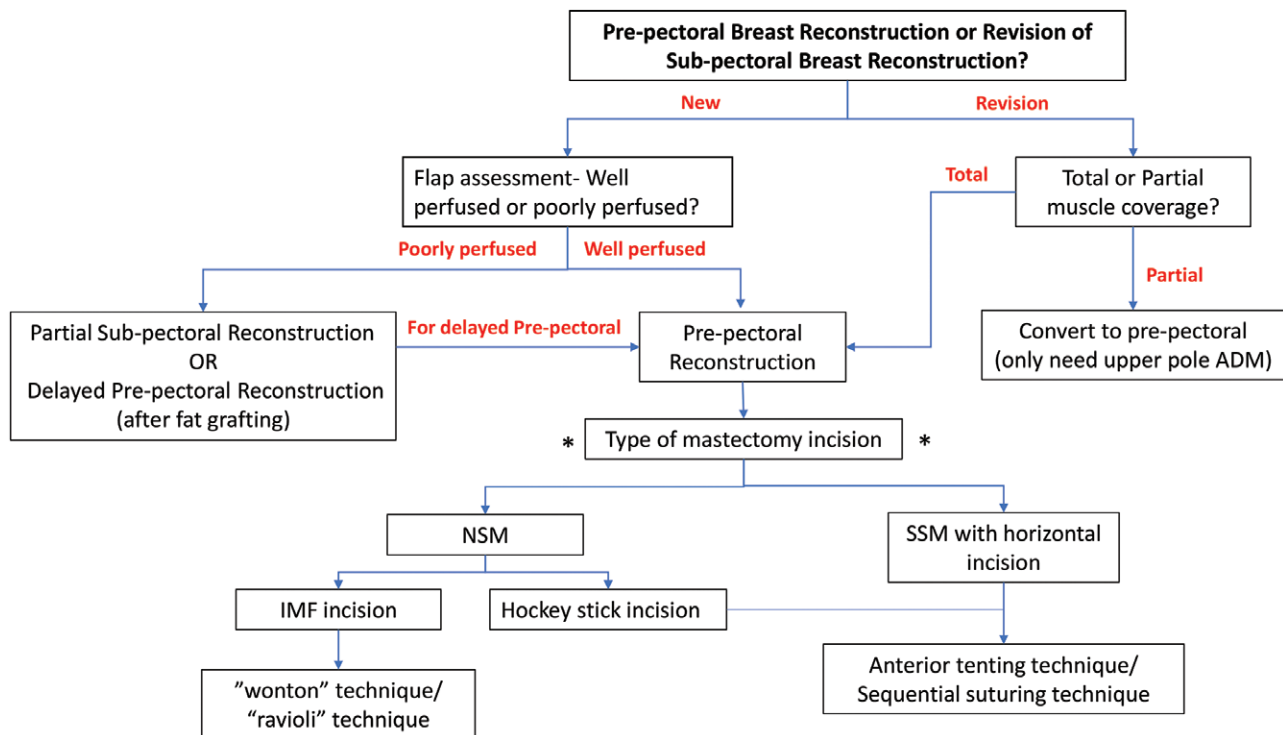


Fig. 1. Prepectoral reconstructive approach to new or revision patients. *Point of decision making with regard to ADM inseting technique. NSM indicates nipple-sparing mastectomy; SSM, skin-sparing mastectomy.

For Nipple-Sparing Mastectomy, Through an Inframammary Fold Incision

Due to the limited work space in nipple-sparing mastectomy pockets when inframammary fold (IMF) incision is used, reconstruction can be best done through ex vivo ADM-prosthetic construct. This involves wrapping the implant/TE with ADM on a back table before placing the implant in breast pocket and tacking it down to the pectoralis muscle. The ex vivo ADM-prosthetic construct may be achieved either through “wonton” or “ravioli” technique.^{3,12}

In short, the implants/TEs are individually wrapped with ADM on a separate mayo stand. The “wonton” technique involves placing the implants/TEs in the center of the ADM with the port side down for TE and the dome side down for the implants. Careful markings are made on the ADM to indicate the 12 o’clock position. The 2 opposite corners of the ADM are sutured together with 2-0 polydioxanone suture (PDS), and the edges are brought together in a running stitch fashion (Fig. 2). This creates a fully wrapped TE/implant.³ Next, the wrapped TE/implant is placed in the pocket above the pectoralis muscle, with the TE port/implant dome facing upward.³ The device is then tacked down to the pectoralis muscle at 12 o’clock, 3 o’clock, and 9 o’clock using the parachute technique. Once the device is secured to its position, it is finally suture to the pectoralis muscle at the 6 o’clock position.

The “ravioli” technique involves using 2 pieces of extra thick ADM to completely wrap the TE/implant. The 2 pieces of ADM are cut to the size of the TE/implant

with 1 piece covering the anterior and the other covering the posterior surface of the TE/implant. The 2 pieces are then sutured around the TE/implant with 2-0 PDS in a running baseball stitch fashion (Fig. 4).^{3,12} The ADM device construct is then placed above the pectoralis muscle with anterior side (port side/dome of the implant) facing upward and sutured directly to the pectoralis major muscle with interrupted sutures in the superior, medial, lateral, and inferior borders of the breast. If TEs were used, then they are filled with air just enough to collapse the dead space in the pocket and allow for safe skin closure. Two drains are placed in each breast pocket.

For Nipple-Sparing Mastectomy, Through Hockey Stick Incision or Skin-Sparing Mastectomy, Through a Horizontal Breast Incision

Both the hockey stick and transverse incision allow for increased work space and control over the borders of the breast pocket. Hence, in vivo techniques are more frequently used to perform reconstruction. The concept behind these techniques is to provide anterior coverage for the prosthetic device without using the pectoralis muscle.³ This can be done via anterior tenting technique or sequential suturing technique. Both provide excellent anterior coverage for the prosthetic.

The anterior tenting technique involves using a piece of extra thick ADM measured per the size of the TE/implant. The ADM is inset first to the IMF, leaving approximately 3 cm cuff along the pectoralis major muscle (Fig. 5). The TE/implant is then placed directly onto the pectoralis major muscle, and the ADM is draped over the

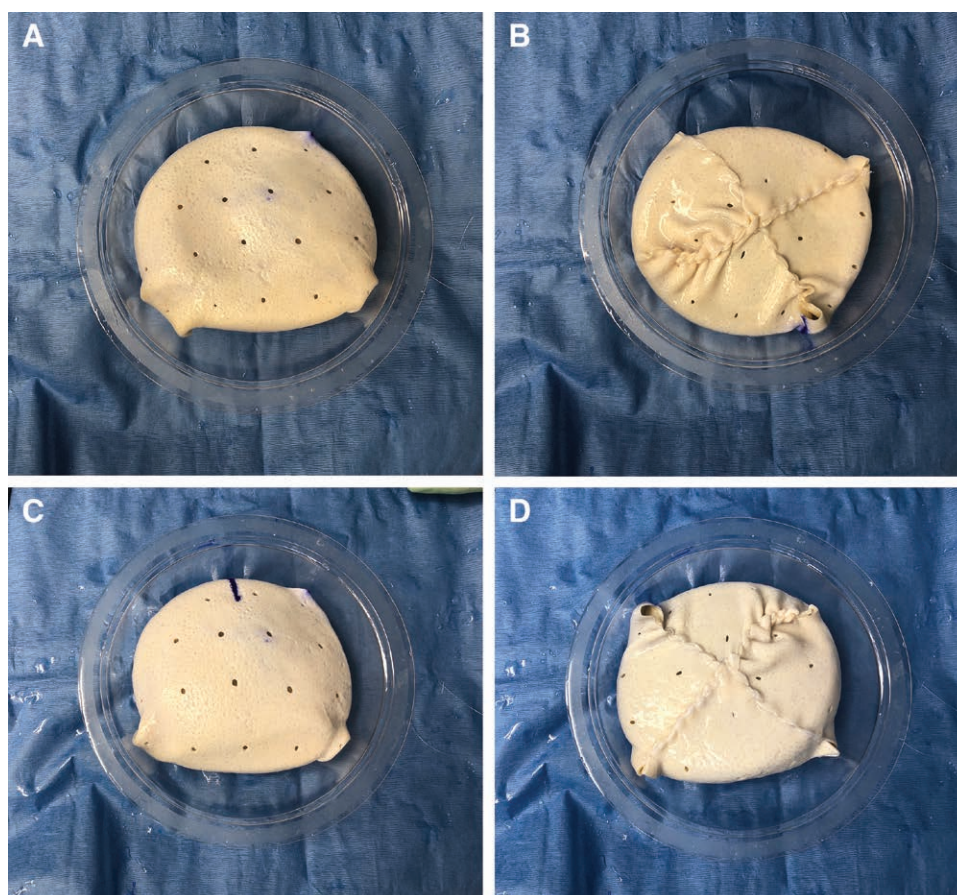


Fig. 2. TE wrapped with ADM ex vivo using “wonton” technique. A, Right breast ADM device complex anterior surface. B, Right breast ADM device complex posterior surface. C, Left breast ADM device complex anterior surface. D, Left breast ADM device complex posterior view.

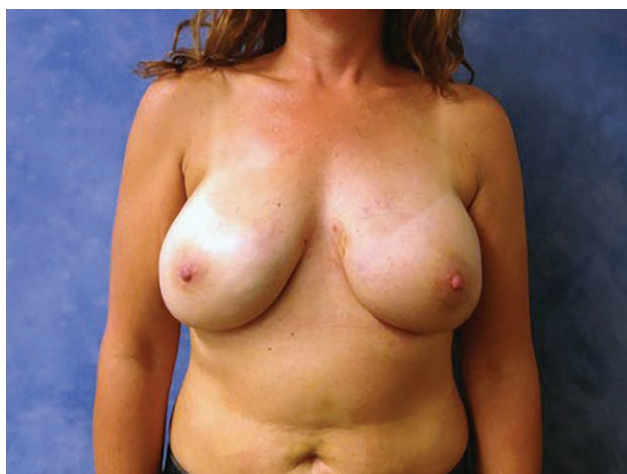

Fig. 3. Forty-six-year-old woman who underwent immediate 2-stage prepectoral breast reconstruction via “wonton” technique after bilateral nipple-sparing mastectomy. Picture taken 6-week status post stage 2 prepectoral breast reconstruction.

device. The ADM is sutured to the pectoralis muscle superiorly, medially, and laterally in a running baseball stitch fashion using 2-0 PDS covering the entire anterior surface of the device.³

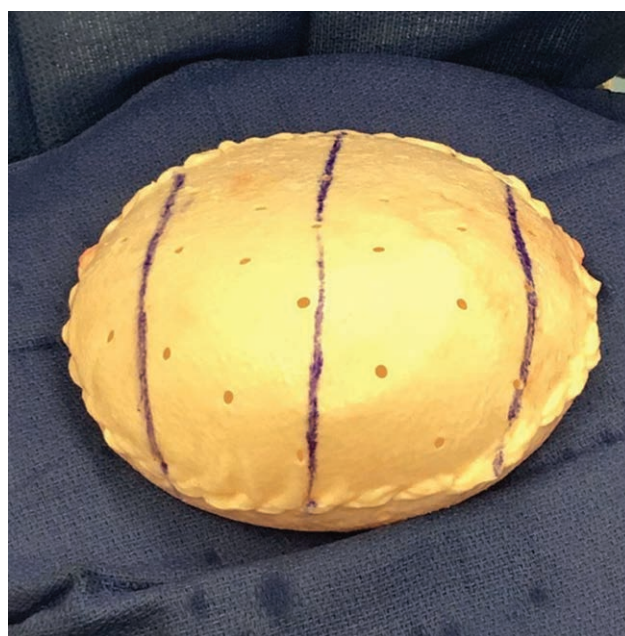

Fig. 4. “Ravioli” technique-2 ADMs covering anterior and posterior surface of prosthetic device. (Adapted with permission from Sigalove.³ Copyright 2018 by the American Society of Plastic Surgeons.)

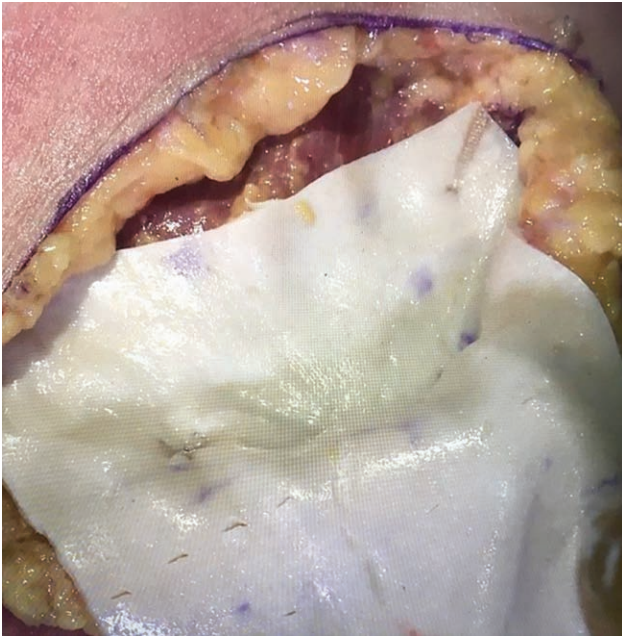

Fig. 5. Anterior tenting technique-cuff along the IMF. (Adapted with permission from Sigalove.³ Copyright 2018 by the American Society of Plastic Surgeons.)

The sequential suturing technique is the primary technique used in our practice for anterior coverage. It involves inseting the ADM on top of the pectoralis muscle with a series of interrupted running sutures leaving an opening on the lateral aspect to place the TE (Fig. 6). Doing several interrupted running sutures versus just a single running suture decreases the incidence of device displacement as a result of dehiscence of ADM from the pectoralis muscle. Post mastectomy, through the horizontal incision, the pectoralis major is exposed with retraction (Fig. 7A). The ADM is sized and placed over pectoralis major. The ADM is sutured to the pectoralis major in a running stitch fashion using 2-0 PDS. For the right chest, the ADM is first sutured clockwise from the 12 o'clock position to the 4 o'clock position. Then with another run of 2-0 PDS is made in clockwise direction from 4 o'clock to 7 o'clock

and finally counterclockwise from the 12 o'clock position to the 11 o'clock position. This allows for the TE/implant to be placed from the lateral aspect between 7 o'clock and 11 o'clock position. For the left chest, the ADM is placed and sutured to the chest wall in the counterclockwise direction starting from the 12 o'clock position to the 8 o'clock position (Fig. 7C). Next, the suture is run counterclockwise from 8 o'clock to 5 o'clock, and the final run is made clockwise from the 12 o'clock position to the 1 o'clock position. The TEs/implants are placed under the ADM with port side/dome of the implant facing up, and above the pectoralis muscle through the lateral opening between 1 and 5 o'clock position (Fig. 7D-F). The TEs/implants are placed using super sterile technique described above. Once the TE is placed and positioned correctly, the lateral aspect of the ADM is sutured in a running fashion counterclockwise from 11 o'clock to 7 o'clock on the right chest, and clockwise from 1 o'clock to 5 o'clock on the left chest. If used, the TEs are filled with air. If a DTI approach is used, then this concludes the reconstruction. Finally, 2 drains are placed for each side.

FOR REVISION PATIENTS (CONVERT FROM SUBPECTORAL TO PREPECTORAL IBR)

Because partial submuscular and submuscular approaches often result in intractable pain, loss of pectoralis muscle function, animation deformity, implant malposition, capsular contracture, and low patient satisfaction, many patients present requesting revision of their reconstruction.^{7,13} Depending on the type of subpectoral IBR performed, different revision options are available for these patients (Fig. 1).

Assuming the revision patients being considered for conversion to prepectoral reconstruction have been carefully assessed for successful outcomes, the next step would be an intraoperative assessment of the skin flap to confirm that the skin is viable, well perfused, and of appropriate thickness.^{10,11}

Revision for Partial Muscle Coverage With Lower Pole ADM

Given the skin flap is well perfused, and initial reconstruction was done with partial muscle coverage and lower

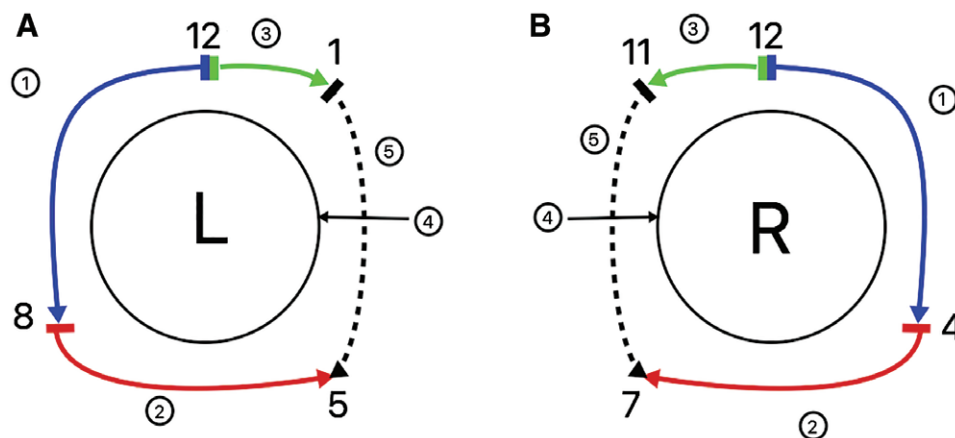


Fig. 6. An illustration of the sequential suture technique for left (A) and right (B) chest.

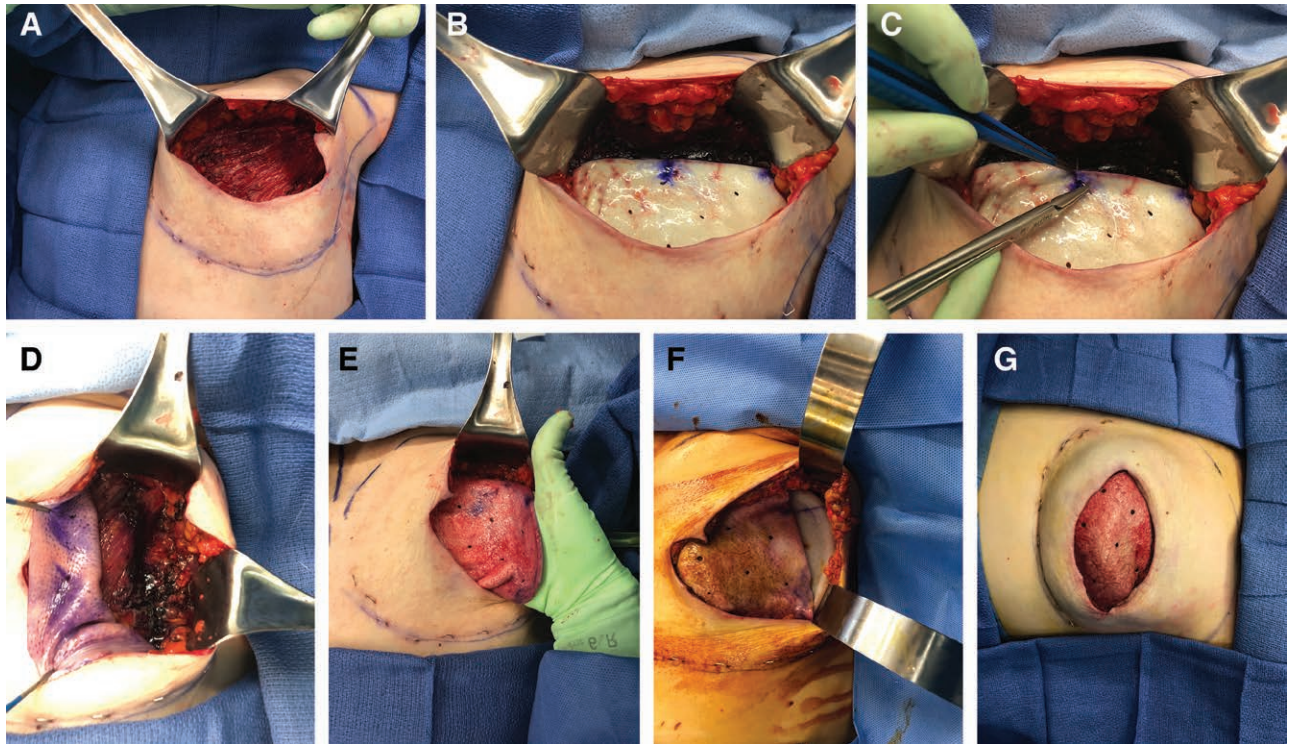


Fig. 7. Prepectoral breast reconstruction using sequential suturing technique on unilateral left-sided skin-sparing mastectomy. A, The breast pocket immediate post mastectomy and after hemostasis. B, ADM marked at the 12 o'clock position and placed inside the breast pocket. C, First suture started at 12 o'clock position. D, Lateral opening with ADM pulled up. E, Placement of the TE through the lateral opening. F, Uninflated TE placed on top of the pectoralis muscle and under the ADM via lateral opening. G, TE inflated with air after closing the lateral border.

pole ADM, as long as the IMF is in good position, conversion is performed by adding an upper pole ADM to provide total coverage for the implant.¹⁴ The pectoralis muscle is dissected off the subcutaneous tissue and separated from the lower pole ADM. The muscle is then tacked down to the chest wall using 2-0 vicryl.¹³ The preexisting lower pole ADM creates the lower pocket. An upper pole

ADM is then inset to the pectoralis muscle superiorly in a running fashion using 2-0 PDS. Implant is then inserted through the opening between the upper and lower pole ADM, and the opening is closed in a running fashion with 2-0 vicryl (Fig. 9).

Revision for Total Muscle Coverage

Given the skin flap is well perfused, and the initial reconstruction was done with total muscle coverage, the conversion is performed based on the original mastectomy incision. The pectoralis muscle is dissected off the subcutaneous tissue and tacked down to the chest wall.¹³ An IMF incision limits access to the breast pocket, especially the superior pole. Therefore, the ex vivo techniques

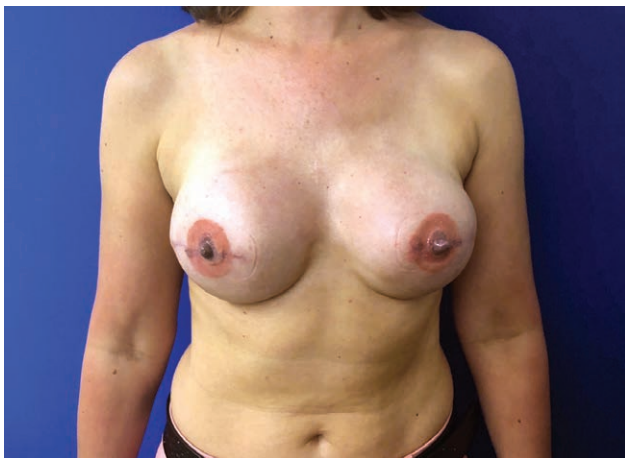

Fig. 8. Forty-five-year-old woman who underwent immediate 3-stage prepectoral breast reconstruction via sequential suture technique after bilateral skin-sparing mastectomies. Picture was taken 6-week status post stage 3 breast reconstruction.

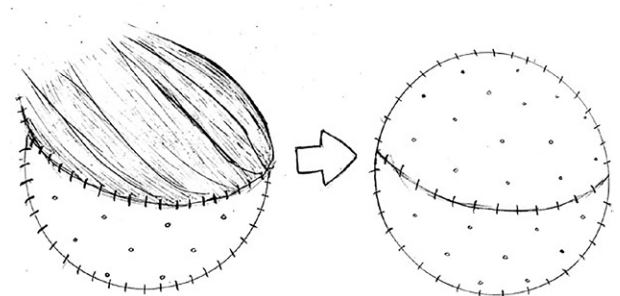


Fig. 9. Illustration depicting conversion of a partial muscle coverage with lower pole ADM to prepectoral reconstruction.

(“wonton” or “ravioli” technique) are better suited in this setting. The horizontal and hockey stick incisions allow for better access to the breast pocket. In these revision cases, the in vivo techniques (anterior tenting or sequential suture technique) are more useful due to better access and control over the creation of breast pocket and boundaries..³

POSTOPERATIVE MANAGEMENT

Postoperatively drains are removed when they have <30mL of output for 3 consecutive days.² If the reconstruction is being done in 2 stages, then at the time of any drain removal, a range of 30–60mL of air is added to the TEs to collapse any dead space in the pocket. At 3 weeks postoperatively, the air is exchanged for saline. Tissue expansion to the desired volume is usually able to be achieved at the time, or alternatively may require 1 additional office visit. Stage II breast reconstructions, with exchange for the permanent implant, are performed at 5 months postoperatively.

OTHER CONSIDERATIONS

The ADM inseting techniques listed above can be done for single-stage or 2-stage prepectoral IBR. The benefits of performing a DTI prepectoral IBR are decreased operative time, cost, and morbidity associated with numerous surgeries.^{12,15} The benefits for 2-stage reconstruction are the ability for the patient to test drive varying sizes before committing to final implant size, and reduced risk of nipple loss or necrosis in nipple-sparing mastectomies.^{2,16} TE expanders should also be used in patients undergoing delayed prepectoral reconstruction as the skin and subcutaneous tissue may recoil during the healing period. Performing a single-stage reconstruction in this setting may increase risk of subcutaneous flap necrosis because of increased tension.

Some disadvantages of prepectoral breast reconstructions are implant visibility and rippling. However, this can be mitigated with proper use of fat grafting.^{6,8,17} In the setting where fat grafting may be difficult, using extra thick ADM is beneficial as it acts as a replacement of pectoralis muscle without the contractility.^{7,10,18}

Additionally, prepectoral IBR with ADM has been shown to be safe and effective in carefully selected patients with history of radiation or those that plan to undergo postmastectomy radiation therapy. The use of fat grafting early on is shown to decrease radiation-related complications through revascularization.^{19,20}

CONCLUSIONS

Prepectoral IBR is becoming more popular in the field of breast reconstruction. Given the lack of muscle involvement, the complications associated with pectoralis muscle elevation such as postoperative pain, animation deformity, and widened cleavage are avoided. The success of this approach can be attributed to optimally filled cohesive implants, ADMs, and fat grafting. In addition, well perfused mastectomy skin flaps, and careful patient selection.^{1–6} Last but not least, selecting the appropriate surgical technique

for ADM placement is crucial for obtaining a successful reconstruction.

The algorithm proposed in this article helps new surgeons embarking on prepectoral reconstruction know which ADM inseting technique to use and when. In our practice, we have done 105 prepectoral breast reconstructions using this algorithm, 21 of which were reconstruction revisions. This helped our practice streamline the prepectoral reconstructive process by improving intraoperative efficiency. Finally, these techniques can be utilized for both new and revision breast patients successfully.

Benjamin Liliav, MD

Webber West, Suite 443

417 State Street

Bangor, ME 04401

E-mail: bliliav@yahoo.com

REFERENCES

1. Nahabedian MY, Glasberg SB, Maxwell GP. Introduction to “prepectoral breast reconstruction.” *Plast Reconstr Surg*. 2017;140:4S–5S.
2. Nahabedian MY, Cocilovo C. Two-stage prosthetic breast reconstruction: a comparison between prepectoral and partial subpectoral techniques. *Plast Reconstr Surg*. 2017;140:22S–30S.
3. Sigalove S. Options in acellular dermal matrix-device assembly. *Plast Reconstr Surg*. 2017;140:39S–42S.
4. Sigalove S, Maxwell GP, Sigalove NM, et al. Prepectoral implant-based breast reconstruction: rationale, indications, and preliminary results. *Plast Reconstr Surg*. 2017;139:287–294.
5. Storm-Dickerson T, Sigalove N. Prepectoral breast reconstruction: the breast surgeon’s perspective. *Plast Reconstr Surg*. 2017;140:43S–48S.
6. Maxwell GP, Gabriel A. Bioengineered breast: concept, technique, and preliminary results. *Plast Reconstr Surg*. 2016;137:415–421.
7. Reitsamer R, Peintinger F. Prepectoral implant placement and complete coverage with porcine acellular dermal matrix: a new technique for direct-to-implant breast reconstruction after nipple-sparing mastectomy. *J Plast Reconstr Aesthet Surg*. 2015;68:162–167.
8. Vidya R, Iqbal FM. A guide to prepectoral breast reconstruction: a new dimension to implant-based breast reconstruction. *Clin Breast Cancer*. 2017;17:266–271.
9. Jones G, Yoo A, King V, et al. Prepectoral immediate direct-to-implant breast reconstruction with anterior AlloDerm coverage. *Plast Reconstr Surg*. 2017;140:31S–38S.
10. Sbitany H. Important considerations for performing prepectoral breast reconstruction. *Plast Reconstr Surg*. 2017;140:7S–13S.
11. Bertozzi N, Pesce M, Santi P, et al. Tissue expansion for breast reconstruction: methods and techniques. *Ann Med Surg (Lond)*. 2017;21:34–44.
12. Downs RK, Hedges K. An alternative technique for immediate direct-to-implant breast reconstruction—a case series. *Plast Reconstr Surg Glob Open*. 2016;4:e821.
13. Highton L, Johnson R, Kirwan C, et al. Prepectoral implant-based breast reconstruction. *Plast Reconstr Surg Glob Open*. 2017;5:e1488.
14. Nahabedian MY, Spear SL. Acellular dermal matrix for secondary procedures following prosthetic breast reconstruction. *Aesthet Surg J*. 2011;31(7_Suppl):38S–50S.
15. Clemens MW, Srinivasa D, Garvey PB, et al. Abstract: direct-to-implant versus two-staged expander-implant reconstruction: comparison of risks and patient-report outcomes from a prospective, multi-center study. *Plast Reconstr Surg Glob Open*. 2016;4(9 Suppl):138–139.

16. Bernini M, Calabrese C, Cecconi L, et al. Subcutaneous direct-to-implant breast reconstruction: surgical, functional, and aesthetic results after long-term follow-up. *Plast Reconstr Surg Glob Open*. 2015;3:e574.
17. Becker H, Lind JG, Hopkins EG. Immediate implant-based prepectoral breast reconstruction using a vertical incision. *Plast Reconstr Surg Glob Open*. 2015;3:e412.
18. Sbitany H, Sandeen SN, Amalfi AN, et al. Acellular dermis-assisted prosthetic breast reconstruction versus complete submuscular coverage: a head-to-head comparison of outcomes. *Plast Reconstr Surg*. 2009;124:1735–1740.
19. Gabriel A, Maxwell GP. Prepectoral breast reconstruction in challenging patients. *Plast Reconstr Surg*. 2017;140:14S–21S.
20. Rozen WM, Ashton MW. Radiotherapy and breast reconstruction: oncology, cosmesis and complications. *Gland Surg*. 2012;1:119–127.