

Received: 2017.06.19  
Accepted: 2017.12.05  
Published: 2018.01.28

## Fournier's Gangrene: Clinical Presentation of 13 Cases

Authors' Contribution:  
Study Design A  
Data Collection B  
Statistical Analysis C  
Data Interpretation D  
Manuscript Preparation E  
Literature Search F  
Funds Collection G

ABCDEF 1 **Bolesław Kuzaka**  
ADEF 2,3 **Marta M. Wróblewska**  
ABDE 1 **Tomasz Borkowski**  
ABDE 4 **Dariusz Kawecki**  
ABD 5 **Piotr Kuzaka**  
D 4 **Grażyna Młynarczyk**  
ABDEF 1 **Piotr Radziszewski**

1 Department of General, Oncological and Functional Urology, Medical University of Warsaw, Warsaw, Poland  
2 Department of Dental Microbiology, Medical University of Warsaw, Warsaw, Poland  
3 Department of Microbiology, Central Clinical Hospital in Warsaw, Warsaw, Poland  
4 Department of Medical Microbiology, Medical University of Warsaw, Warsaw, Poland  
5 Individual Medical Practice, Warsaw, Poland

**Corresponding Author:** Marta Wróblewska, e-mail: [marta.wroblewska@wum.edu.pl](mailto:marta.wroblewska@wum.edu.pl)  
**Source of support:** Departmental sources

**Background:** Fournier's gangrene (FG) is a fulminant form of infective, polymicrobial, necrotizing fasciitis of the perineal, genital, and perianal regions. It commonly affects men, but women and children may also develop this type of tissue necrosis.





**Material/Methods:** This study is a retrospective analysis of the management of 13 cases of Fournier's gangrene, diagnosed from among about 45 000 patients (men, women, and children) treated in the Department of General, Oncological, and Functional Urology (Medical University of Warsaw) from 1995 to 2013. All patients with Fournier's gangrene underwent adequate surgical debridement of the necrotic tissues. Additional procedures (suprapubic cystostomy and orchiectomy) were necessary in 10 out of 13 (77.0%) patients. Seven out of 13 (53.8%) patients required subsequent reconstructive surgery of the scrotum.

**Results:** All 13 patients were males, with a median age of 59.6 years (range: 42–68 years). The average hospital stay was 31.9 days (range: 16–46 days). None of our patients died due to Fournier's gangrene. Bacteriological cultures of samples from the wounds showed polymicrobial flora, including the following genera of aerobes and anaerobes: *Escherichia*, *Proteus*, *Klebsiella*, *Moraxella*, *Gemella*, *Enterococcus*, *Streptococcus*, *Staphylococcus*, *Bacteroides*, *Pseudoflavonifractor*, *Parabacteroides*, *Porphyromonas*, *Prevotella*, *Peptoniphilus*, *Peptostreptococcus*, *Actinomyces*, *Collinsella*, and *Lactobacillus*.

**Conclusions:** Favorable outcome of FG treatment with low morbidity and no mortality can be achieved with rapid diagnosis, urgent surgical debridement of all necrotic tissues, and broad-spectrum empirical antimicrobial therapy, usually with combined antibiotics, against aerobic and anaerobic bacteria. Prevention of uroseptic shock by treating localized infection is compulsory.

**MeSH Keywords:** **Debridement • Fasciitis, Necrotizing • Fournier's Gangrene • Sepsis**

**Full-text PDF:** <https://www.medscimonit.com/abstract/index/idArt/905836>

 2459  2  6  41



## Background

Some urological conditions have serious or life-threatening consequences and require immediate surgical and medical intervention. These medical emergencies include Fournier's gangrene, which was first reported in 1764 by Bauriène [1]. He described a case of scrotal gangrene in a 45-year-old man, an army butcher, due to traumatic injury in the genital region and the left thigh from the horn of an ox, 4 days before clinical diagnosis was made. Bauriène stated that in cases of scrotal gangrene, radical surgical debridement of all infected and necrotic tissues is required. However, the testicles are not always affected, and in these cases, to safeguard the male reproductive system they must not be resected [1–3].

However, the disease was named after Jean-Alfred Fournier (1832–1914), a Parisian venereologist who reported in 1883 a compiled series of 5 otherwise healthy young men who suffered from a rapidly progressive gangrene of the penis and scrotum without any apparent cause [4]. More than 1700 cases of necrotizing fasciitis have been reported in the literature from 1950 to 1999 [5].

As we now know, Fournier's gangrene may occur due to insufficient or lack of blood supply in the affected area and a concomitant infection. Most patients are men in their 60s or 70s and often suffer from other concomitant illnesses [6–10].

According to the majority of authors, the most important predisposing factors are: diabetes mellitus, alcoholism, atherosclerosis, peripheral arterial disease, trauma or injury, Raynaud's phenomenon, malnutrition, medical immunosuppression (e.g., chemotherapy, steroids, and malignancy), HIV infection, leukemia, liver diseases, and debilitating illness [6–8,11]. Multiple predisposing factors predict a poor prognosis and correlate significantly with mortality [12,13]. The reported overall mortality rate is around 20–40%, but it can be as high as 70–80%, particularly if sepsis is present at the time of hospital admission [2,7,8,14–16].

Necrosis of the tissues in the affected areas (predominantly in the genital region), intense pain, and tenderness are the main symptoms of this disorder. Inflammation begins with the appearance of a black spot, called Brodie's sign [17]. From this moment, the necrotic inflammation spreads briskly, moving along the fascial planes and stretching into the surrounding areas (perineum, scrotum, hypogastrium, and sometimes affecting the region from the thigh up to the diaphragm) causing rapid deterioration of the patient's general condition [2,8,11]. The male-to-female ratio is 10: 1 [5].

The aim of this study was to present 13 cases of Fournier's gangrene treated over 18 years in a university-affiliated urology

department. The analysis includes the most common species of bacteria isolated from the site of infection, evaluation of the disease outcome, identification of the associated risk factors and prognostic indicators of FG, effectiveness of therapeutic procedures, complications, and mortality.

## Material and Methods

Among about 45 000 patients hospitalized in our department between 1995 and 2013, we diagnosed and treated 13 cases of Fournier's gangrene. Characteristics of these patients (all males) are listed in Table 1. Immediately after admission, all patients were subjected to surgical resection of all necrotic tissues. Prior to surgery, all patients underwent intensive intravenous fluid replacement and were treated with parenteral broad-spectrum triple antimicrobial therapy, using a third-generation cephalosporin combined with metronidazole and/or an aminoglycoside, with dose adjustment according to renal function.

Surgical procedures consisted of adequate and urgent debridement of all necrotic tissues, wound drainage, and diversion of urine via a suprapubic catheter. At the time of surgery, swabs, pus, and occasionally samples of necrotic tissue were collected and sent for microbiological examination. Identification of microorganisms and susceptibility testing were performed using standard microbiological techniques. Susceptibility results were interpreted in accordance with the guidelines (up to 2011 – CLSI: Clinical and Laboratory Standards Institute; later, EUCAST: European Committee on Antimicrobial Susceptibility Testing). No blood cultures were done in these patients.

After obtaining the results of microbiological examination, antibiotic adjustment was made where necessary. After containment of the infection and debridement of the wound, urinary diversion was removed and reconstruction using skin grafts was performed if required.

## Results

All 13 (100%) patients were males. The median age was 59.6 years (range: 42–68 years). Diabetes mellitus was present in 4 out of 13 (30.8%) patients, including 2 insulin-dependent diabetics (15.4%) and 2 patients (15.4%) with type II diabetes. The mean hospital stay of the 13 patients included in the study was 31.9 days (range: 16–46 days). None of these patients had septic shock on admission and did not require intensive therapy or administration of vasopressors. Auxiliary surgical procedures (apart from debridement of the necrotic tissue) were necessary in 8 (61.5%) patients. Percutaneous (suprapubic) cystostomy was done in 8 (61.5%) patients, while

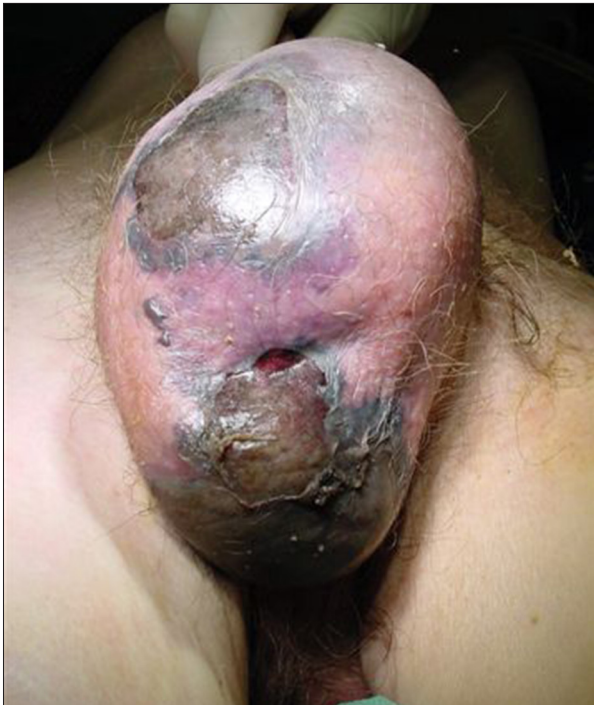**Table 1.** Characteristics of patients suffering from Fournier's gangrene\*.

| No | Patient's initials /year of admission | Age | Hospital stay (days) | Therapeutic procedures apart from debridement and antimicrobials | Accompanying diseases                                                                                  | Outcome                                                                                                       |
|----|---------------------------------------|-----|----------------------|------------------------------------------------------------------|--------------------------------------------------------------------------------------------------------|---------------------------------------------------------------------------------------------------------------|
| 1  | KT<br>1995                            | 67  | 30                   | None                                                             | Haemorrhoids                                                                                           | Granulation of the wound                                                                                      |
| 2  | SM<br>1999                            | 68  | 46                   | Orchidectomy                                                     | Alcoholism; nicotineism                                                                                | Scrotoplasty; subcutaneous hiding of the testicle                                                             |
| 3  | SK<br>2000                            | 51  | 30                   | None                                                             | Insulin-dependent diabetes                                                                             | Granulation of the wound                                                                                      |
| 4  | KZ<br>2000                            | 63  | 28                   | Twice necrectomy                                                 | Insulin-dependent diabetes                                                                             | Scrotoplasty                                                                                                  |
| 5  | PS<br>2006                            | 42  | 41                   | Suprapubic cystostomy                                            | Postalcoholic epilepsy; HBsAg(+)                                                                       | Scrotoplasty                                                                                                  |
| 6  | LI<br>2007                            | 58  | 28                   | None                                                             | None                                                                                                   | Resutura vulneris                                                                                             |
| 7  | WK<br>2007                            | 67  | 16                   | Suprapubic cystostomy; orchidectomy; debridement                 | Neglected patient; Staghorn calculi of the kidney                                                      | Wound suture                                                                                                  |
| 8  | JJ<br>2008                            | 64  | 34                   | Suprapubic cystostomy                                            | Stroke (3 episodes). generalised arteriosclerosis; atrial fibrillation                                 | Scrotoplasty                                                                                                  |
| 9  | KA<br>2008                            | 55  | 24                   | Suprapubic cystostomy                                            | Arterial hypertension<br>Tuberculosis;<br>spondyloarthritis;<br>glucose intolerance                    | Granulation of the wound                                                                                      |
| 10 | BL<br>2009                            | 54  | 34                   | Suprapubic cystostomy                                            | Type II diabetes                                                                                       | Wound resuture                                                                                                |
| 11 | KB<br>2013                            | 59  | 44                   | Suprapubic cystostomy                                            | None                                                                                                   | Scrotoplasty                                                                                                  |
| 12 | SR<br>2013                            | 64  | 29                   | Suprapubic cystostomy                                            | Type II diabetes                                                                                       | Scrotoplasty                                                                                                  |
| 13 | WBA<br>2013                           | 74  | 45                   | Suprapubic cystostomy                                            | Neglected patient, poor hygiene, schizophrenia, chronic circulatory insufficiency; atrial fibrillation | Reconstruction of urethra and end-to-end anastomosis; scrotoplasty; plastic surgery of the penis and perineum |

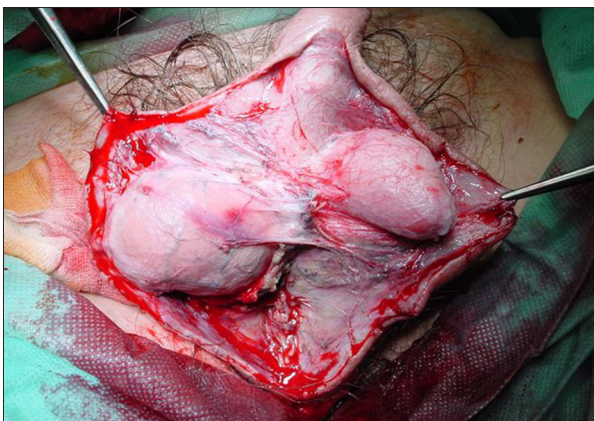
\* In the studied group of 13 patients with FG the period from appearance of first clinical symptoms till hospital admission ranged from 3 to 14 days.

orchidectomy was performed in 2 (15.3%) patients. There was no need for penis amputation in any of the 13 patients with FG. The source of infection was identified only in 4 (30.7%) patients as perirectal and gluteal abscesses. None of the patients in the studied group died of FG. Figures 1–6 demonstrate the clinical course of the disease in selected patients.

A list of cultured microbial strains is shown in Table 2. In total, 38 bacterial strains were cultured, representing 18 genera. Most of them were obligate anaerobes and facultative anaerobes, such as enteric rods of the *Enterobacteriaceae* family. The typical fecal anaerobic flora of *Bacteroides* spp. and *Parabacteroides* spp. was isolated from about half of the patients. In cases with the presence of gas-forming microorganisms, necrotizing



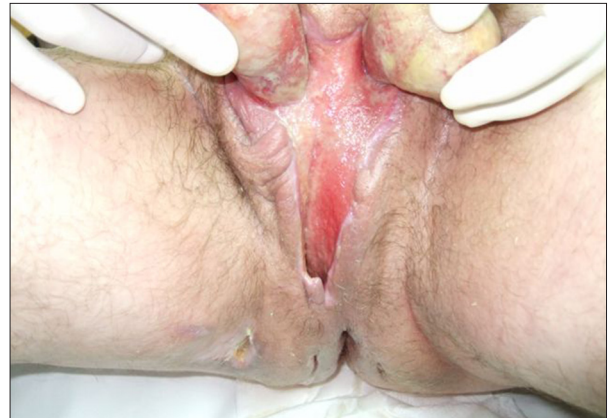**Figure 1.** Patient no. 1. Photograph of Fournier's gangrene of the scrotum taken on admission. The photograph shows erythematous scrotum and necrotic areas.



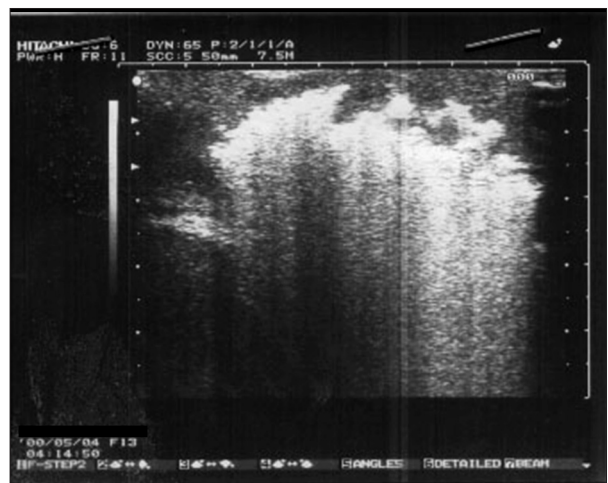
**Figure 2.** Patient no. 1. Image of the surgical wound after emergency surgical debridement of the necrotic tissues.

fasciitis typically presented with crepitations caused by subcutaneous air.

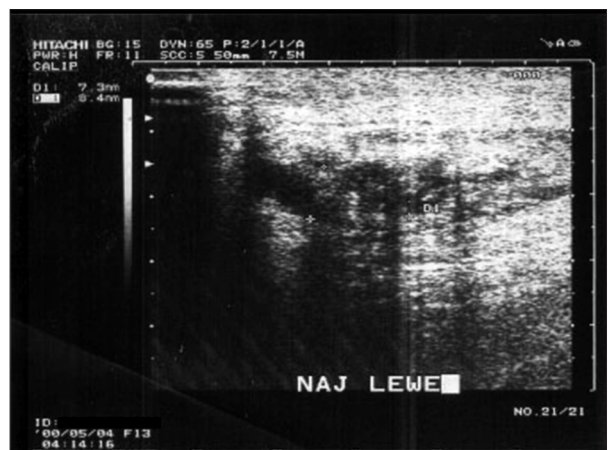A mixed bacterial flora was isolated from clinical specimens sent for microbiological culture from 10 patients, while in the remaining 3 patients a single species was isolated: *Klebsiella pneumoniae*, *Staphylococcus haemolyticus*, and *Lactobacillus acidophilus*. The co-existence of strict anaerobes and *Escherichia coli* was particularly common.



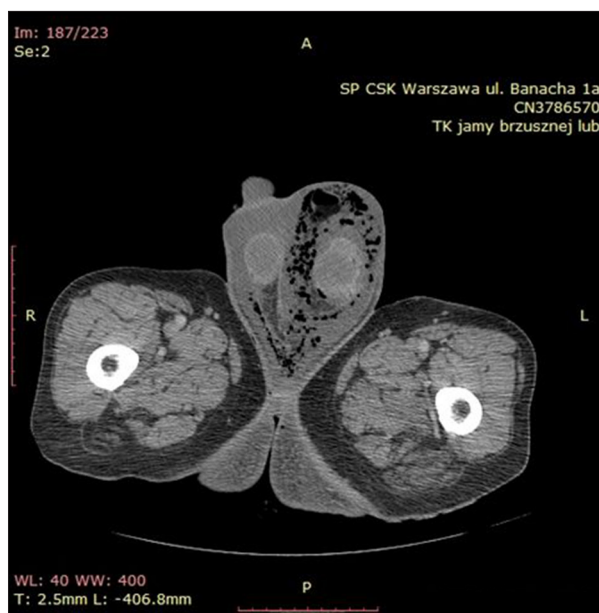
**Figure 3.** Patient no. 1. Photograph taken 3 months after treatment.



**Figure 4.** Patient no. 2. Ultrasound scan of the scrotum. A large subcutaneous reservoir of gas with an irregular surface and strong acoustic reflections from the gas bubbles.



**Figure 5.** Patient no. 2. Ultrasound scan: section of the left epididymis. Reflections of acoustic waves from small gas bubbles with acoustic shadows.



**Figure 6.** Patient no. 3. Computed tomography scan of Fournier's gangrene. CT image shows gas in the subcutaneous area and circumferentially surrounding the left testicle.

## Discussion

Necrotizing fasciitis is a rapidly progressive inflammatory infection of the fascia, with secondary necrosis of the subcutaneous tissues. Fournier's gangrene is a form of necrotizing fasciitis that is localized in the scrotum and perineal area [2,8,11]. Sepsis develops in >40% of patients [18]. Early diagnosis, proper management of the predisposing factors, and aggressive surgical debridement can improve clinical outcome [9,12,19].

Fournier's gangrene is a serious urologic emergency with a high mortality rate, which ranges from 20% to as high as 70% to 80% [2,7–9,14–16]. However, in our series there was no mortality. The disease is much more frequent among males (in our study all 13 patients with FG were males). FG is rarely seen in children, but pediatric cases have been reported from resource-poor countries where poor hygiene is prevalent and in immunocompromised children [20]. It can be difficult to diagnose these infections in the early stages, but they rapidly progress and require aggressive treatment to combat the associated high morbidity and mortality.

Several authors state that the most important parameters that predict outcome of FG are hemostatic abnormalities at presentation with this disease and renal failure [10,21]. Diabetes mellitus is reported to be present in 20–70% of patients with FG and chronic alcoholism in 25–50% of FG patients, with some authors reporting increased mortality in patients with diabetes [2,6,8]. As mentioned previously, among the 13 patients in the present study, 4 were diabetic (30.8%): 2 were insulin-dependent (15.4%) and 2 had type II diabetes (15.4%).

Necrotizing fasciitis can occur as a complication of a variety of surgical procedures or medical conditions. Cases of scrotal or penile necrotizing fasciitis can also be idiopathic. As Thwaini et al. reported, the most common sources of infection are the foci in the gastrointestinal tract (30–50%), followed by the genitourinary tract (20–40%) and cutaneous injuries (20%) [2]. In our patients, the source of infection was identified in only 4 (30.8%) patients, and these were perirectal and gluteal abscesses. In the remaining patients, the source of infection remained unknown.

FG may arise from several sources (e.g., anorectal, urogenital, or gynecological). The most common anorectal sources of FG are perianal abscesses, but there can be other causes as well, such as abdominoperineal resection, anal intercourse, rectal biopsy, anal dilatation, hemorrhoidectomy, herniorrhaphy, rectosigmoid malignancy, appendicitis, diverticulitis, sigmoid-vesical fistula, perforated colonic carcinoma, pancreatitis with retroperitoneal fat necrosis, and perforated duodenal ulcer [9,10,12,22–25]. Urogenital factors include an indwelling catheter, traumatic catheterization in case of longstanding urethral stricture, urethral calculi, prostatic biopsy, bladder carcinoma, epididymitis, balanitis, urinary extravasation, circumcision, vasectomy, insertion of penile prosthesis, penile erosion, TVT (tension-free vaginal tape) procedure, hydrocele aspiration, delayed rupture of ileal neobladder, intracavernosal cocaine injection, and genital piercing, as well as perineal trauma and human bites or scratches [2,25]. FG in women can originate from an infected Bartholin's gland, septic abortion, episiotomy wound, coital injury, or genital mutilation [2].

The differential diagnosis of Fournier's gangrene includes many conditions, such as cellulitis, acute epididymitis, orchitis, strangulated hernia, scrotal abscess, streptococcal necrotizing fasciitis, vascular occlusion syndromes, herpes simplex virus infection, gonococcal balanitis, pyoderma gangrenosum, allergic vasculitis, polyarteritis nodosa, necrolytic migratory erythema, warfarin necrosis, and ecthyma gangrenosum [2,16,26].

Cultures from the wounds of FG patients commonly show polymicrobial flora – mainly aerobes and obligate anaerobes – which is a characteristic feature of this disease [18,27]. Addison et al. reported that an average of 4 microorganisms were cultured per patient, while Yanar et al. reported that in 75% of 35 patients with FG, at least 2 bacteria were cultured from the lesions [6,27]. The polymicrobial etiology of Fournier's gangrene typically includes *Staphylococcus aureus*, *Streptococcus* spp., *Klebsiella* spp., *Escherichia coli*, and obligate anaerobic bacteria (e.g., *Bacteroides* spp.), but involvement of *Clostridium* spp. is now less common [16,28–31]. Yanar et al. reported that *E. coli* was the most common bacterium, accounting for 43% of the isolates [6].

**Table 2.** Facultative anaerobic and strictly anaerobic bacteria isolated from FG patients (n=38)\*.

|                                                              | Species                                   | No of isolates | % of isolates (N=38) |
|--------------------------------------------------------------|-------------------------------------------|----------------|----------------------|
| Gram-negative bacilli<br>(family <i>Enterobacteriaceae</i> ) | <i>Escherichia coli</i>                   | 5              | 13.2                 |
|                                                              | <i>Proteus mirabilis</i>                  | 1              | 2.6                  |
|                                                              | <i>Klebsiella pneumoniae</i>              | 1              | 2.6                  |
| Gram-negative cocci                                          | <i>Moraxella lacunata</i>                 | 1              | 2.6                  |
| Gram-positive cocci                                          | <i>Gemella morbillorum</i>                | 1              | 2.6                  |
|                                                              | <i>Enterococcus faecalis</i>              | 1              | 2.6                  |
|                                                              | <i>Streptococcus gallolyticus</i>         | 1              | 2.6                  |
|                                                              | <i>Streptococcus constellatus</i>         | 1              | 2.6                  |
|                                                              | Coagulase-negative staphylococci          | 3              | 8.0                  |
| Strictly anaerobic Gram-negative bacilli                     | <i>Bacteroides fragilis</i>               | 3              | 8.0                  |
|                                                              | <i>Bacteroides caccae</i>                 | 1              | 2.6                  |
|                                                              | <i>Pseudoflavonifractor capillosus</i> ** | 1              | 2.6                  |
|                                                              | <i>Bacteroides ovatus</i>                 | 1              | 2.6                  |
|                                                              | <i>Bacteroides thetaiotaomicron</i>       | 1              | 2.6                  |
|                                                              | <i>Bacteroides uniformis</i>              | 1              | 2.6                  |
|                                                              | <i>Parabacteroides distasonis</i>         | 2              | 5.4                  |
|                                                              | <i>Parabacteroides merdae</i>             | 1              | 2.6                  |
|                                                              | <i>Porphyromonas asaccharolytica</i>      | 1              | 2.6                  |
|                                                              | <i>Prevotella intermedia/disiens</i>      | 1              | 2.6                  |
|                                                              | <i>Prevotella bivia</i>                   | 1              | 2.6                  |
| Strictly anaerobic Gram-positive cocci                       | <i>Peptoniphilus asaccharolyticus</i>     | 2              | 5.4                  |
|                                                              | <i>Peptostreptococcus</i> spp.            | 3              | 8.0                  |
| Strictly anaerobic Gram-positive rods                        | <i>Actinomyces naeslundii</i>             | 1              | 2.6                  |
|                                                              | <i>Collinsella aerofaciens</i>            | 1              | 2.6                  |
|                                                              | <i>Lactobacillus acidophilus/jensenii</i> | 1              | 2.6                  |
|                                                              | <i>Lactobacillus fermentum</i>            | 1              | 2.6                  |
| <b>Total</b>                                                 |                                           | <b>38</b>      | <b>100.0</b>         |

\* Most specimens contained more than one species of bacteria; \*\* previously: *Bacteroides capillosus*.

Blood cultures in FG patients are usually negative. Fournier's gangrene is rare in Poland, and also in our hospital [24,32,33]. The anaerobic fecal flora predominated in microbiologic cultures. In most cases, a mixed flora was isolated, confirming reports in the literature.

The precise role of the individual components in the pathogenic processes is difficult to determine. Microbial isolates cultured from FG skin lesions may be a part of normal skin flora colonizing the wound. The most common microbes recovered from wound cultures were *Acinetobacter* species according to data from investigators in Saudi Arabia [34].

Moreover, it is possible that rapidly growing bacteria overgrow the slow growers (e.g., many anaerobes) and suppress them. The typical isolation of multiple aerobic and anaerobic bacteria in most cases of FG suggests the possibility of a synergistic interaction among these different species. They secrete a variety of toxins and metabolites that cause tissue necrosis and rapid spread of the infection, as well as severe cardiovascular impairment. It is believed that in the course of FG, obliterative endarteritis of the subcutaneous arteries results in gangrene of the overlying skin [11]. If not treated, the host inflammatory reaction can contribute to multi-organ failure and death [35]. It is believed that FG involves an imbalance

between host immunity and the virulence of the causative microorganisms [8].

Due to the predominance of obligate anaerobes, the use of metronidazole is recommended [2]; this is especially important because these bacteria are resistant to aminoglycosides and most of them are also resistant to cephalosporins. However, metronidazole should not be used alone because it is inactive against all aerobes and facultative anaerobes. In triple therapy, a combination of amoxicillin and aminoglycoside can be used as they are highly bactericidal against many bacteria. The infection is usually community-acquired; therefore, the bacteria involved usually do not possess the acquired determinants of antimicrobial resistance. At present, it is recommended that (in certain circumstances) classical triple therapy be replaced with newer groups of antibiotics, such as piperacillin-tazobactam. Clindamycin may also be used because it suppresses toxin production. In patients with previous hospitalizations and prolonged antibiotic therapy, carbapenems, linezolid, daptomycin, and tigecycline may be used [13]. Strict cooperation is necessary between clinicians and microbiologists to optimize management of patients with FG.

In the majority of FG patients treated in our hospital, there were predisposing factors (e.g., diabetes mellitus and alcoholism). However, in our group of FG patients, we achieved good results of treatment due to emergency surgical intervention, with extensive and adequate surgical necrectomy of all devitalized tissues, proper drainage, intensive treatment of septic shock, and a broad-spectrum triple antibiotic regimen of aminoglycoside, metronidazole, and ampicillin or cephalosporin, as recommended in the literature [5,8]. An important part of therapy of FG is also good local hygiene, with wound dressings changed twice daily, and administration of analgesics and antipyretics. In the treatment of FG, it is essential to closely monitor patients for early signs of development of ARDS (acute respiratory distress syndrome) and renal failure, as well as detection and early treatment of other possible complications. Due to extensive tissue loss and concomitant sepsis, these patients have increased metabolic needs, which are best treated with parenteral nutrition. With these precautions in mind, we started administration of this regimen immediately on admission of the patient to the ward. Upon admission, all patients were immediately treated according to the updated guidelines [35].

## References:

- Bauriène H: Sur une plaie qui s'est terminée par la sphacèle de la scrotum. *J Méd Chir Pharm*, 1764; 20: 251–56 [in French]
- Thwaini A, Khan A, Malik A et al: Fournier's gangrene and its emergency management. *Postgrad Med J*, 2006; 82(970): 516–19
- Kuzaka B, Dybowski: Towards zero mortality in Fournier's gangrene. Editorial. *Cent Eur J Urol*, 2013; 66(3): 335
- Fournier JA: Gangrene foudroyante de la verge. *Sem Méd*, 1883; 4: 589–97 [in French]
- Eke N: Fournier's gangrene: A review of 1726 cases. *Br J Surg*, 2000; 87(6): 718–28
- Yanar H, Taviloglu K, Ertekin C et al: Fournier's gangrene: Risk factors and strategies for management. *World J Surg*, 2006; 30(9): 1750–54

In FG patients, multiple debridements are often needed, which may result in significant loss of skin and soft tissue, requiring reconstructive surgery [5,10,11,36]. Several authors reported that an average of 3–3.5 procedures were required per patient [10,37]. In a group of 41 patients with FG, >53% needed reconstructive surgery [7]. Koukouras et al. reported the colostomy rate was 55.5%, the cystostomy rate was 37.7%, and the orchiectomy rate was 26.6% [38]. A study from Japan examined 379 patients, showing that early intervention (within 2 hospital days) can cut the mortality rate in half compared with later intervention [39]. Broad-spectrum antimicrobial therapy, aggressive debridement of necrotic tissue, and comprehensive management of these patients are the mainstays in treatment of these severely ill patients [40].

Hippocrates circa 500 BC wrote “Many were attacked by the erysipelas all over the body when the exciting cause was a trivial accident...flesh, sinews, and bones fell away in large quantities...there were many deaths.” [41].

The favorable outcome of treatment of all 13 FG patients reported in this study is a result of close cooperation among anesthesiologists, urologists, and plastic surgeons. We confirm that a multidisciplinary approach in diagnosis and management of this disease can lead to good outcome with reduced or no mortality.

## Conclusions

- The disease is much more frequent among males (all patients in our study were males).
- Mixed flora was characteristic, with predominance of obligate anaerobes.
- Fast and radical excision of necrotic tissue and broad-spectrum antibiotic therapy probably contributed to the lack of mortality.
- Orchiectomy is rarely necessary in FG patients.
- Penis amputation usually may be omitted (in our series of 13 patients with FG, there was no need for amputation of the penis in any of the patients).
- Subsequent reconstructive surgery allows the closure of even extensive skin defects.

## Conflict of interest

None.

7. Chen SY, Fu JP, Wang CH et al: Fournier gangrene: A review of 41 patients and strategies for reconstruction. *Ann Plast Surg*, 2010; 64(6): 765–69
8. Mallikarjuna MN, Vijayakumar A, Patil VS, Shivswamy BS: Fournier's gangrene: Current practices. *ISRN Surg*, 2012; 2012: 942437
9. Sarvestani AS, Zamiri M, Sabouri M: Prognostic factors for Fournier's gangrene: A 10-year experience in Southeastern Iran. *Bull Emerg Trauma*, 2013; 1(3): 116–22
10. Ersoz F, Sari S, Arikan S et al: Factors affecting mortality in Fournier's gangrene: Experience with fifty-two patients. *Singapore Med J*, 2012; 53: 537–40
11. Chennamsetty A, Khourdaji I, Burks F, Killinger KA: Contemporary diagnosis and management of Fournier's gangrene. *Ther Adv Urol*, 2015; 7(4): 203–15
12. Aridogan IA, Izol V, Abat D et al: Epidemiological characteristics of Fournier's gangrene: A report of 71 patients. *Urol Int*, 2012; 89(4): 457–61
13. D'Arena G, Pietrantonio G, Buccino E et al: Fournier's gangrene complicating hematologic malignancies: A case report and review of literature. *Mediterr J Hematol Infect Dis*, 2013; 5(1): e2013067
14. García Marín A, Turégano Fuentes F, Cuadrado Ayuso M et al: Predictive factors for mortality in Fournier's gangrene: A series of 59 cases. *Cir Esp*, 2015; 93(1): 12–17
15. Stephens B, Lathrop J, Rice W, Gruenberg J: Fournier's gangrene: Historic (1764–1978) versus contemporary (1979–1988) differences in etiology and clinical importance. *Am Surg*, 1993; 59: 149–54
16. Kearney D: Fournier's gangrene: diagnostic and therapeutic considerations. In: *Gangrene – current concepts and management options*. Vitin A (ed.). InTech. 2011, [www.intechopen.com](http://www.intechopen.com)
17. Fajdic J, Bukovic D, Hrgovic Z et al: Management of Fournier's gangrene. Report of 7 cases and review of the literature. *Eur J Med Res*, 2007; 12: 169–72
18. Martinschek A, Evers B, Lampl L et al: Prognostic aspects, survival rate, and predisposing risk factors in patients with Fournier's gangrene and necrotizing soft tissue infections: evaluation of clinical outcome of 55 patients. *Urol Int*, 2012; 89: 173–79
19. Markiewicz S, Skrobisz J, Kwiatek-Markiewicz S: Treatment of Fournier's gangrene. *Wiad Lek*, 2013; 66(3): 256–59
20. Bakshi C, Banavali S, Lokeshwar N et al: Clustering of Fournier (male genital) gangrene cases in a pediatric cancer ward. *Med Pediatr Oncol*, 2003; 41(5): 472–74
21. Laor J, Palmer LS, Tolia BM et al: Outcome prediction in patients with Fournier's gangrene. *J Urol*, 1995; 154(1): 89–92
22. Buła G, Podwińska E, Skrzydło M et al: Fournier's gangrene – serious complication of perianal abscess. *Wiad Lek*, 2005; 58(1–2): 28–31
23. Bednarek M, Drożdż W: A rare case of the extensive Fournier's gangrene developed in the course of a perianal abscess. *Przegl Lek*, 2008; 65(9): 410–12
24. Mazur A, Karbowski M: Fournier's gangrene – a case report. *Wiad Lek*, 2013; 66(3): 260–61
25. Sroczynski M, Sebastian M, Rudnicki J et al: A complex approach to the treatment of Fournier's gangrene. *Adv Clin Exp Med*, 2013; 22(1): 131–35
26. Pais VM: Fournier gangrene differential diagnoses. 2015, <http://emedicine.medscape.com/article/2028899-differential>
27. Addison WA, Livengood CH, Hill GB: Necrotizing fasciitis of vulvar origin in diabetic patients. *Obst Gynecol*, 1984; 63(4): 473–79
28. Ersay A, Yilmaz G, Akgun Y, Celik Y: Factors affecting mortality of Fournier's gangrene: Review of 70 patients. *ANZ J Surg*, 2007; 77: 43–48
29. Kuo CF, Wang WS, Lee CM et al: Fournier's gangrene: ten-year experience in a medical center in northern Taiwan. *J Microbiol Immunol Infect*, 2007; 40: 500–6
30. Ferreira PC, Reis JC, Amarante JM et al: Fournier's gangrene: A review of 43 reconstructive cases. *Plast Reconstr Surg*, 2007; 119(1): 175–84
31. Goyette M: Group A streptococcal necrotizing fasciitis Fournier's gangrene – Quebec. *Can Comm Dis Rep*, 1997; 23(13): 101–3
32. Kuzaka B, Jardonowski R, Dobroński P: Fournier's gangrene. Case report. *Urol Pol*, 1998; 51(1): 93–100
33. Życzkowski M, Bogacki R, Bryniarski P et al: Gangrene of the penis, scrotum and perineum. *Cent Eur J Urol*, 2013; 66(3): 336–40
34. Katib A, Al-Adawi M, Dakkak B, Bakhsh A: A three-year review of the management of Fournier's gangrene presented in a single Saudi Arabian institute. *Cent Eur J Urol*, 2013; 66(3): 331–34
35. Grabe M, Bartoletti R, Bjerklund Johansen TE et al: Guidelines on urological infections. European Association of Urology (EAU). 2015, [uroweb.org/wp-content/uploads/EAU-Guidelines-Urological-Infections-v2.pdf](http://www.uroweb.org/wp-content/uploads/EAU-Guidelines-Urological-Infections-v2.pdf)
36. Karian LS, Chung SY, Lee ES: Reconstruction of defects after Fournier gangrene: A systematic review. *Eplasty*, 2015; 15: e18
37. Chawla SN, Gallop C, Mydło JH: Fournier's gangrene: an analysis of repeated surgical debridement. *Eur Urol*, 2003; 43(5): 572–75
38. Koukouras D, Kallidonis P, Panagopoulos C et al: Fournier's gangrene, a urologic and surgical emergency: Presentation of a multi-institutional experience with 45 cases. *Urol Int*, 2011; 86: 167–72
39. Sugihara T, Yasunaga H, Horiguchi H et al: Impact of surgical intervention timing on the case fatality rate for Fournier's gangrene: An analysis of 379 cases. *BJU Int*, 2012; 110: E1096–100
40. Vargas AH, Carbonell J, Osorio D, García HA: Evaluation of Fournier's necrosis in a high complexity hospital. *Arch Esp Urol*, 2011; 64: 948–52
41. Descamps V, Aitken J, Lee M: Hippocrates on necrotizing fasciitis. *Lancet*, 1994; 344: 556