

## CASE REPORT

# Life-threatening pneumonitis after first-line treatment with osimertinib for primary T790M mutated non-small cell lung cancer

Maik Häntschel<sup>1</sup> , Johannes Niebling<sup>2</sup>, Almut Häring<sup>2</sup>, Max-Felix Häring<sup>2</sup>, Thorben Groß<sup>1</sup>, Marius Horger<sup>3</sup>, Reimer Riessen<sup>4</sup>, Michael Haap<sup>4</sup>, Richard A Lewis<sup>5</sup>, Michael Böckeler<sup>1</sup> & Jürgen Hetzel<sup>1</sup>

1 Department of Internal Medicine VIII, Medical Oncology and Pneumology, Eberhard Karls University, Tübingen, Germany

2 Department of Internal Medicine II, Oncology, Hematology, Clinical Immunology and Rheumatology, Eberhard Karls University, Tübingen, Germany

3 Department of Radiology, University Hospital and Comprehensive Cancer Center Tübingen, Eberhard Karls University, Tübingen, Germany

4 Department of Internal Medicine, Medical Intensive Care Unit, Eberhard Karls University, Tübingen, Germany

5 NPARU, University of Worcester, Worcester, UK

## Keywords

Epithelial growth factor receptor; interstitial lung disease; side effect; pneumonitis; tyrosine kinase inhibitor.

## Correspondence

Maik Häntschel, Universitätsklinikum Tübingen, Medizinische Klinik VIII, Otfried-Müller-Str. 10, 72076 Tübingen, Germany.  
Tel: +49 7071 29-82711  
Fax: +49 7071 29-4475  
Email: maik.haentschel@med.uni-tuebingen.de

Received: 19 March 2020;

Accepted: 20 April 2020.

doi: 10.1111/1759-7714.13476

Thoracic Cancer **11** (2020) 2044–2047

## Abstract

Epithelial growth factor receptor (EGFR) directed tyrosine kinase inhibitor (TKI) treatment is the standard approach in patients with advanced, *EGFR*-mutated non-small cell lung cancer (NSCLC). Although benefit/risk ratio is favorable for these TKI and side effects are manageable in the vast majority of patients, severe and even life-threatening side effects have been reported. TKI-induced interstitial lung disease (ILD) has been reported for single cases in modest severity, predominantly in *EGFR*-TKI pretreated patients. Here, we report a case of successful stabilization of a life-threatening ILD in a de novo T790M mutated NSCLC during first-line treatment with osimertinib. As osimertinib will be used more often in many *EGFR*-positive NSCLC patients in the future, this potentially life-threatening side effect should receive special attention, especially in first-line treatment.

## Introduction

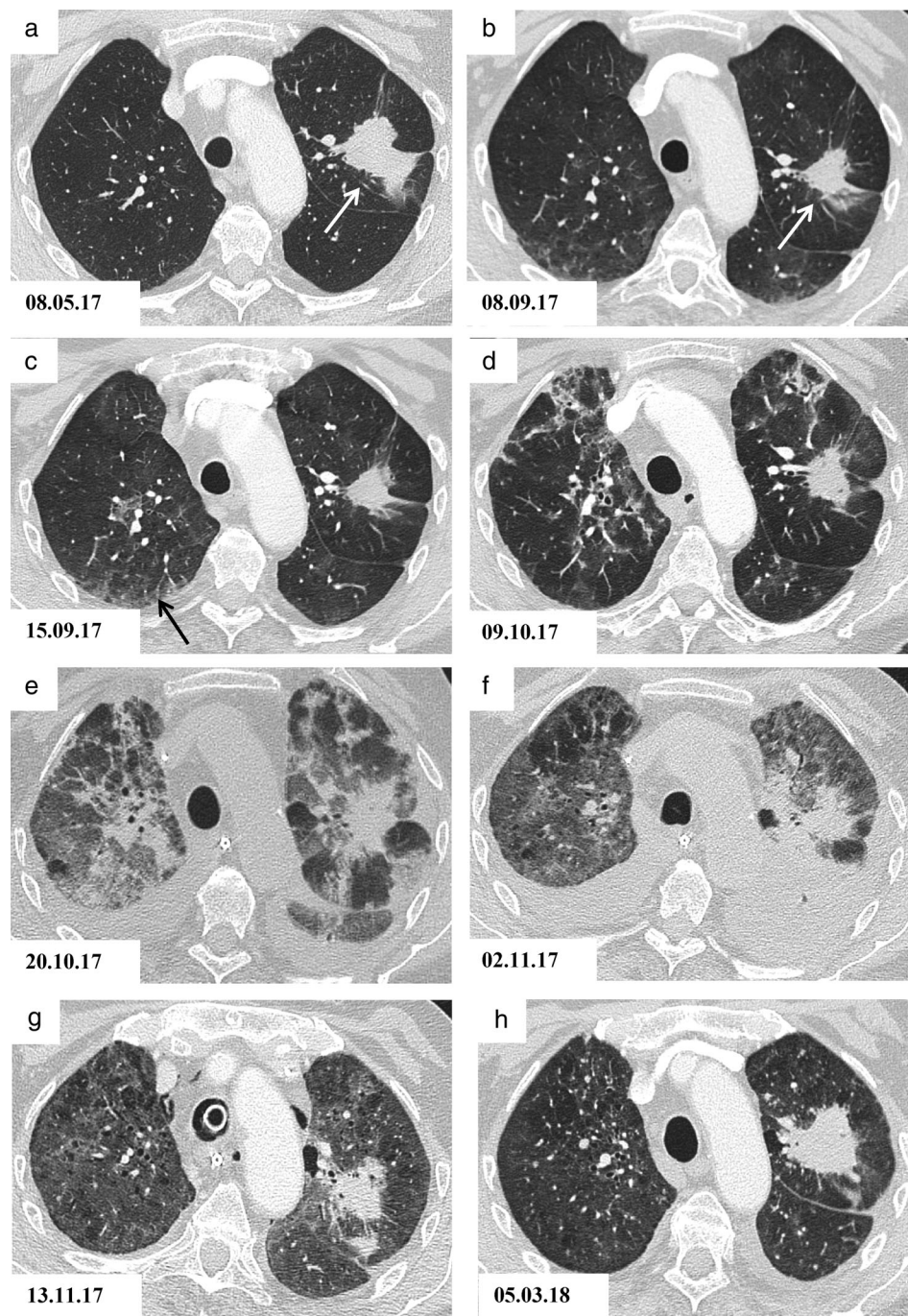
Interstitial lung disease (ILD) is a known side effect of epithelial growth factor receptor (EGFR) directed treatment with tyrosine kinase inhibitors (TKI).<sup>1–6</sup> In rare cases, ILD may be a serious and potentially life-threatening event.<sup>7–9</sup> With increasing numbers of *EGFR*-TKI treated patients, this serious side effect becomes increasingly relevant. Incidence and severity of TKI induced ILD varies between different TKIs and between initial and re-exposure to an *EGFR*-directed treatment<sup>8</sup> or after preceding PD-L1 directed treatment.<sup>10–13</sup> In contrast to acquired T790M mutation, data on side effects for patients with de novo/primary T790M mutated non-small cell lung cancer (NSCLC) is limited. We present a case of acute pneumonitis with resultant respiratory

failure and need for mechanical ventilation after first line-treatment with the TKI osimertinib in a primary T790M mutated NSCLC patient.

## Case report

A 79 year-old non-smoker, with no pre-existing pulmonary disease, was diagnosed with NSCLC of the left upper lung complicated by adrenal and bone metastases (Fig 1a, white arrow). Molecular genetic analysis at first diagnosis revealed both an *EGFR* mutation p.L858R in exon 21 and a p.T790M mutation in exon 20 (but no other molecular alteration relevant for treatment). First-line treatment with osimertinib was initiated using a standard dose of 80 mg per day (as an off label application at that time). Initial lung function showed a normal diffusion capacity and a

**Figure 1** High-resolution computed tomography (HRCT) scan of the thorax showing subsequent pulmonary changes. (a) Before osimertinib treatment; (b) after four months of osimertinib treatment, no clinical symptoms; (c) ongoing treatment with osimertinib, onset of dyspnea; (d) osimertinib treatment was stopped due to severe hypoxia; (e) no osimertinib, mechanical ventilation, high dose steroid treatment; (f) ongoing mechanical ventilation due to severe hypoxia, steroid treatment; (g) ongoing steroid treatment, with a slow improvement; and (h) no tumor treatment, tumor progression. White arrows mark the primary tumor, black arrows mark pulmonary infiltrates.



mild pulmonary restriction with a vital capacity (VC) of 75% of predicted value.

Osimertinib led to a partial remission of NSCLC after three months without any obvious clinical or radiological side-effects (Fig 1b, white arrow). However, one week later, the patient presented to another hospital with sudden onset of mild dyspnoea. CT scan excluded pulmonary embolism, but showed new, predominantly subpleural, and

bipulmonary opacities (Fig 1c, black arrows). The patient received no further investigation or treatment and osimertinib treatment was continued. Dyspnea worsened over the subsequent three weeks, and the patient re-presented to the same hospital with severe hypoxemia and progressive pulmonary infiltrations (Fig 1d). He rapidly developed acute respiratory failure requiring mechanical ventilation, and was subsequently transferred to our hospital.

Tests showed a slight elevation of infection parameters. Serology, blood cultures and bronchoalveolar lavage failed to reveal any causal pathogen. Transbronchial biopsy for histopathological evaluation could not be performed due to gross persisting hypoxemia under mechanical ventilation with an inspiratory oxygen concentration requirement of up to 90%. Other than osimertinib there had been no change in medication in the preceding four months.

We considered osimertinib-induced acute pneumonitis to be the first differential diagnosis in the absence of any other obvious or potential alternative, and osimertinib treatment was immediately stopped. High dose prednisolone with 500 mg over three days, followed by 100 mg per day for 14 days was given (Fig 1e).<sup>14</sup> However, impaired oxygenation persisted over the next two weeks in parallel with persisting pulmonary infiltrates (Fig 1f), and the patient required tracheostomy. Steroid treatment was continued leading to stabilization and subsequent slow improvement in the lung impairment (Fig 1g), resulting in successful weaning and decannulation 47 days after intubation. Steroid treatment was tapered slowly, and stopped after a further eight weeks. The patient's condition continued to improve, although he continued to have severe restrictive pulmonary impairment (VC 37% of the predicted value) and critical care polyneuropathy.

Follow-up at three and five months (Fig 1h) after stopping osimertinib showed accelerating tumor growth, although the patient's condition further improved to an ECOG performance status of 1–2. Following three months (six cycles) of second-line treatment with carboplatin and gemcitabine the disease stabilized. Subsequent relapse treatment with pemetrexed was initiated which has stabilized tumor activity until now, over two years after first diagnosis.

## Discussion

Although TKI treatment leads to benefits in terms of progression-free and overall survival in *EGFR*-mutated NSCLC patients,<sup>15–17</sup> it is necessary to be aware of potential side effects. Based on previous reports and our experience, we suggest routine clinical and lung function evaluation if respiratory symptoms develop in such patients. In case of a severe TKI-associated ILD, osimertinib treatment should be stopped immediately. In our patient, transient mechanical ventilation and high dose steroid treatment achieved stabilization in this life-threatening situation.

## Disclosure

The authors state that they have no conflict of interest.

## References

- Ohe Y, Imamura F, Nogami N *et al*. Osimertinib versus standard-of-care EGFR-TKI as first-line treatment for EGFRm advanced NSCLC: FLAURA Japanese subset. *Jpn J Clin Oncol* 2019; **49** (1): 29–36.
- Nie KK, Zou X, Geng CX *et al*. AZD9291-induced acute interstitial lung disease. *Chin Med J* 2016; **129** (12): 1507–8.
- Lee H, Lee HY, Sun JM *et al*. Transient asymptomatic pulmonary opacities during Osimertinib treatment and its clinical implication. *J Thorac Oncol* 2018; **13** (8): 1106–12.
- Ding PN, Lord SJ, GebSKI V *et al*. Risk of treatment-related toxicities from EGFR tyrosine kinase inhibitors: A meta-analysis of clinical trials of Gefitinib, Erlotinib, and Afatinib in advanced EGFR-mutated non-small cell lung cancer. *J Thorac Oncol* 2017; **12** (4): 633–43.
- Mezquita L, Varga A, Planchard D. Safety of osimertinib in EGFR-mutated non-small cell lung cancer. *Expert Opin Drug Saf* 2018; **17** (12): 1239–48.
- Oh DK, Ji WJ, Kim WS *et al*. Efficacy, safety, and resistance profile of osimertinib in T790M mutation-positive non-small cell lung cancer in real-world practice. *PLOS One* 2019; **14** (1): e0210225.
- Yoo SH, Ryu JA, Kim SR *et al*. Afatinib-induced acute fatal pneumonitis in metastatic lung adenocarcinoma. *Korean J Family Med* 2016; **37** (6): 351–5.
- Suh CH, Park HS, Kim KW, Pyo J, Hatabu H, Nishino M. Pneumonitis in advanced non-small-cell lung cancer patients treated with EGFR tyrosine kinase inhibitor: Meta-analysis of 153 cohorts with 15,713 patients: Meta-analysis of incidence and risk factors of EGFR-TKI pneumonitis in NSCLC. *Lung Cancer* 2018; **123**: 60–9.
- Yi L, Fan J, Qian R, Luo P, Zhang J. Efficacy and safety of osimertinib in treating EGFR-mutated advanced NSCLC: A meta-analysis. *Int J Cancer* 2019; **145** (1): 284–94.
- Takakuwa O, Oguri T, Uemura T *et al*. Osimertinib-induced interstitial lung disease in a patient with non-small cell lung cancer pretreated with nivolumab: A case report. *Mol Clin Oncol* 2017; **7** (3): 383–5.
- Mamesaya N, Kenmotsu H, Katsumata M, Nakajima T, Endo M, Takahashi T. Osimertinib-induced interstitial lung disease after treatment with anti-PD1 antibody. *Invest New Drugs* 2017; **35** (1): 105–7.
- Fujiwara Y, Goto Y, Kanda S *et al*. Efficacy and safety of osimertinib in a Japanese compassionate use program. *Jpn J Clin Oncol* 2017; **47** (7): 625–9.
- Oshima Y, Tanimoto T, Yuji K, Tojo A. EGFR-TKI-associated interstitial pneumonitis in Nivolumab-treated patients with non-small cell lung cancer. *JAMA Oncol* 2018; **4** (8): 1112–5.
- Lai YC, Lin PC, Lai JI *et al*. Successful treatment of erlotinib-induced acute hepatitis and acute interstitial pneumonitis with high-dose corticosteroid: A case report and literature review. *Int J Clin Pharmacol Ther* 2011; **49** (7): 461–6.

- 15 Soria JC, Ohe Y, Vansteenkiste J *et al.* Osimertinib in untreated EGFR-mutated advanced non-small-cell lung cancer. *N Engl J Med* 2018; **378** (2): 113–25.
- 16 Mok TS, Cheng Y, Zhou X *et al.* Improvement in overall survival in a randomized study that compared Dacomitinib with Gefitinib in patients with advanced non-small-cell lung cancer and EGFR-activating mutations. *J Clin Oncol* 2018; **36** (22): 2244–50.
- 17 Ramalingam SS, Vansteenkiste J, Planchard D *et al.* Overall survival with Osimertinib in untreated, EGFR-mutated advanced NSCLC. *N Engl J Med* 2020; **382** (1): 41–50.