

CASE REPORT

Surgical treatment and intraoperative spinal cord monitoring in scoliosis associated with chronic inflammatory demyelinating polyneuropathy: A case report

DAISUKE KUDO¹, NAOHISA MIYAKOSHI¹, MICHIO HONGO¹, YUJI KASUKAWA¹, YOSHINORI ISHIKAWA¹, AKIKO MISAWA² & YOICHI SHIMADA¹

¹Department of Orthopedic Surgery, Akita University Graduate School of Medicine, Akita, Japan, and

²Department of Orthopedic Surgery, Akita Prefectural Center on Development and Disability, Akita, Japan

Abstract

There has been only one reported case of neuromuscular scoliosis following chronic inflammatory demyelinating polyneuropathy (CIDP). However, no cases of scoliosis that were treated with surgery secondary to CIDP have been previously described. A 16-year-old boy with CIDP was consultant due to the progression of scoliosis with the coronal curve of 86° from T8 to T12. Posterior correction and fusion with segmental pedicle screws were performed under intraoperative spinal cord monitoring with transcranial electric motor-evoked potentials. Although the latency period was prolonged and amplitude was low, the potential remained stable. Coronal curve was corrected from 86° to 34° without neurological complications. We here describe scoliosis associated with CIDP, which was successfully treated with surgery under intraoperative spinal cord monitoring.

Key words: *Chronic inflammatory demyelinating polyneuropathy, intraoperative spinal cord monitoring, scoliosis, transcranial electric motor-evoked potentials*

Introduction

Chronic inflammatory demyelinating polyneuropathy (CIDP) is an autoimmune disease that involves the myelin sheath of the peripheral nerves. CIDP is characterized by the occurrence of symmetrical weakness in both proximal and distal muscles. The condition is associated with impaired sensation, absent or diminished tendon reflexes, increased cerebrospinal fluid protein levels, signs of demyelination in nerve conduction studies, and demyelination in nerve biopsy specimens. Symptoms of these polyneuropathies progressively increase for more than 2 months, and the symptoms can be relapsing or chronic and progressive (1).

Scoliosis that is caused by neuropathy has been reported to occur in patients with Charcot–Marie–Tooth

disease (2,3) and Guillain–Barré syndrome (4,5). There has been only one reported case of neuromuscular scoliosis following CIDP (6). However, no cases of scoliosis that were treated with surgery secondary to CIDP have been previously described. We report the first case of scoliosis that was associated with CIDP and that was successfully treated with surgery using intraoperative spinal cord monitoring.

Case report

A 16-year-old boy consulted our scoliosis clinic from the department of pediatrics because of the progression of scoliosis. He had been diagnosed with retardation of locomotor development at the age of 1 year. He had no familial history of neuromuscular disorders. A nerve

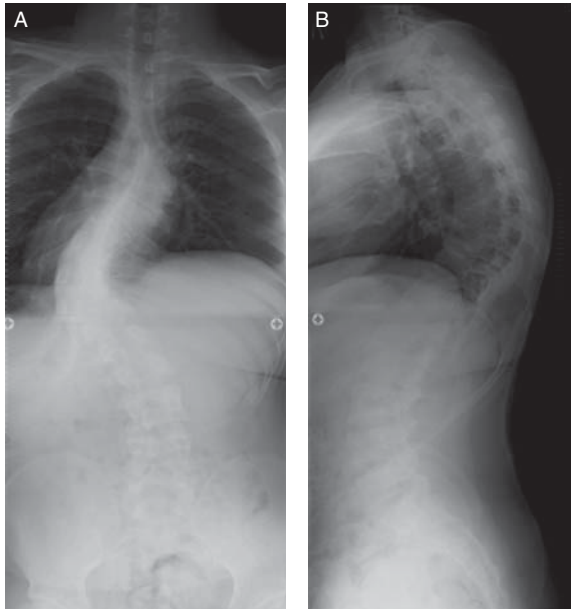


Figure 1. Preoperative plain radiographs show a left convex coronal curve of 86° from T8 to T12 (A) and thoracic kyphosis of 67° from T5 to T12 (B).

conduction study revealed reduced motor nerve conduction velocity and conduction block. A muscle biopsy revealed neurogenic change. At the age of 2 years, a nerve biopsy obtained from the sural nerve revealed demyelination, and he was diagnosed with CIDP. At the age of 14 years, he was diagnosed with scoliosis.

A physical examination demonstrated muscle weakness in the extremities and the absence of deep tendon reflexes in all extremities. He was unable to stand on one leg, and he required two crutches for walking. Plain radiographs showed an 86° left convex coronal curve from T8 to T12 and a 67° thoracic kyphosis from T5 to T12 (Figure 1). The correction rate of 31% on a lateral bending radiograph was considered a stiff curve. The spinal deformity was classified as type 1A+ according to the Lenke classification (7). Three-dimensional computed tomography revealed a wedge deformity of the vertebral body, although rotational deformation was mild (Figure 2).

He underwent posterior correction and fusion with pedicle screws from T4 to L2, and a sublaminar flexible ultra-high-molecular-weight polyethylene cable was used at levels at which screw insertion was considered to be dangerous. Intraoperative spinal cord monitoring with transcranial electric motor-evoked potentials (TCE-MEP) was performed under general anesthesia with propofol without neuromuscular blocking agents. Corkscrew stimulation electrodes were positioned at C3 and C4, and five serial anodal electrical stimuli of 450 V were applied at a pulse width of 50 μ s at intervals

of 2 ms. The TCE-MEP was recorded with surface electrodes that were placed on both abductor hallucis muscles and the right abductor pollicis muscle. Potential waves were not recorded during the initial recording period of 100 ms (Figure 3A), but leg potentials were recorded after the recording period was extended 4-fold to 400 ms. During this period, the latency period prolonged to 232 ms. Subsequently, during surgery, the potential remained stable (Figure 3B). Neurological complications did not occur. The coronal curve and kyphosis were corrected from 86° to 34° (correction rate was 60%) and from 67° to 50° , respectively, at the 2-year follow-up (Figure 4). Written informed consent was obtained from the patient and his parents for publication of this case report and accompanying images. A copy of the written consent is available for review by the Editor-in-Chief of this journal.

Discussion

CIDP was first described by Austin as a corticosteroid-responsive chronic polyneuropathy (8). Its prevalence is estimated at 0.5 per 100,000 children (9) and 1 to 2 per 100,000 adults (10,11). Kararizou et al. reported that CIDP was a frequent cause of neuropathy in teenagers; 9 of 45 patients with peripheral nervous disorders who were aged 13 to 19 presented with CIDP in their study (12). However, there has been only one case of neuromuscular scoliosis following CIDP (6), and no cases of scoliosis

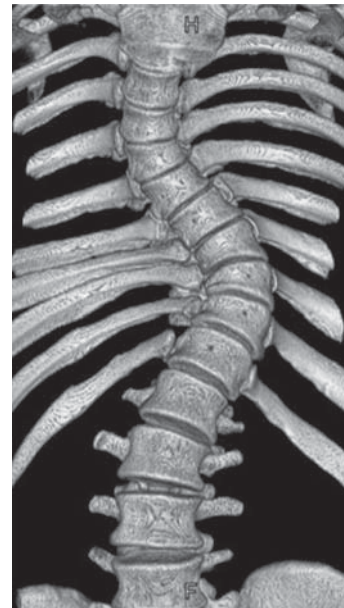

Figure 2. Three-dimensional computed tomography reveals a wedge deformity of the vertebral body, although the rotational deformity was mild.

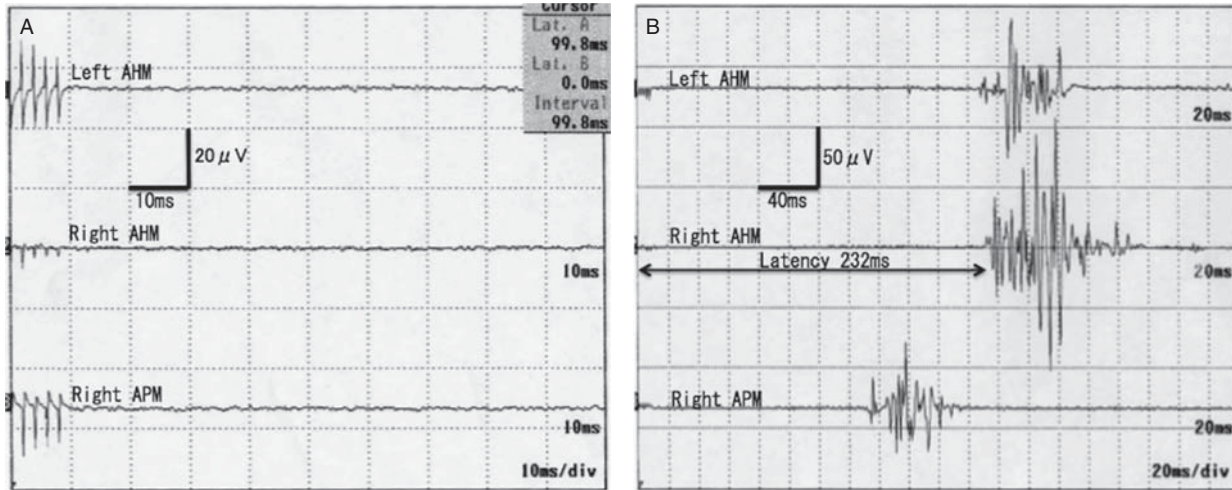


Figure 3. The transcranial electric motor-evoked potentials were recorded with surface electrodes that were placed on both abductor hallucis muscles (AHM) and the right abductor pollicis muscle (APM). No patterns were recorded during the recording period of 100 ms (A), but leg potentials were recorded when the recording period was extended to 400 ms. The latency period was prolonged to 232 ms (B).

that were treated with surgery secondary to CIDP have been previously described.

Some researchers have reported scoliosis in patients with polyneuropathies, such as Charcot–Marie–Tooth disease and Guillain–Barré syndrome. The prevalence of scoliosis in patients with Charcot–Marie–Tooth disease has been reported to be 15% to 30% (2,3), and scoliosis has been reported in only two cases of Guillain–Barré syndrome (4,5). In the present case, because a left convex sharp curve and hyperkyphosis with a wedge deformity of the apex vertebral body are uncommon in adolescent idiopathic scoliosis, we considered that a neurological factor that was caused by CIDP might have influenced the development of the

spinal deformity. As there have been no reports of neuromuscular scoliosis that was treated with surgery secondary to CIDP to the best of our knowledge, this is the first report on this type of clinical case.

One of the serious concerns for the surgical treatment of scoliosis is the risk of neurological complications. The incidence of surgery-related neurological complications in idiopathic scoliosis has been reported to be 0.26% to 1.75% (13,14). However, the risk of surgery-related neurological complications has been reported to be relatively higher in patients with neuromuscular scoliosis with an incidence of 4.0% to 4.6% (15,16). Compound muscle action potentials in patients with demyelinating disease show reduced motor nerve conduction velocities, prolonged distal motor latencies, prolongation or absence of F-waves, and conduction block or temporal dispersion (17). However, it is very important to use intraoperative spinal cord monitoring in order to prevent neurological complications in patients with severe spinal deformities and/or delicate neural tissues. Traditionally, somatosensory cortical evoked potentials are unreliable and non-specific in neuromuscular scoliosis surgery (18), while somatosensory spinal evoked potentials are satisfactory and have good specificity and sensitivity (19). To date, few studies have reported on the use of TCE-MEP during surgery for neuromuscular scoliosis, and it seems to be no established technique for measurement and analysis of TCE-MEP in this setting. DiCindio et al. reported that, although TCE-MEP measurement was not indicated in 19 of 39 patients with cerebral palsy because of risk of epilepsy, TCE-MEP could be recorded in a fairly high percentage of such patients (20). Langeloo et al. reported

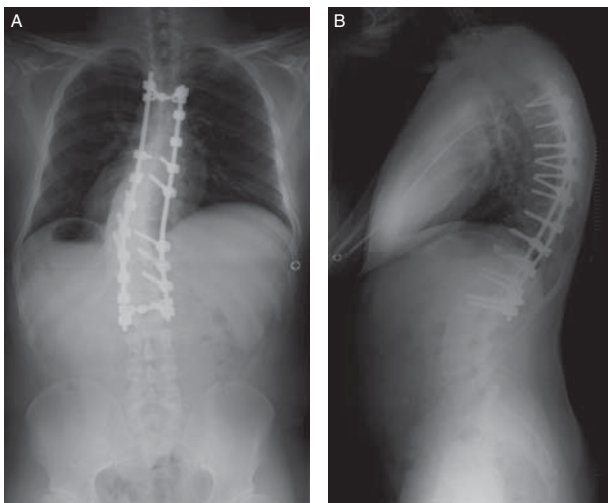


Figure 4. Postoperative antero-posterior (A) and lateral (B) radiographs that were conducted 2 years after the surgery show the corrected coronal curve (86° to 34° with a correction rate of 60%) and the corrected kyphosis (67° to 50°).

that TCE-MEP was reproducible and useful for assessment of paralyzed extremities, although the amplitudes that were recorded were low (21). In our case, despite the long latency period and low amplitudes, TCE-MEPs could be continuously recorded in a stable manner once they appeared. However, when using TCE-MEP at standard measuring ranges in patients with neuromuscular disorders, we need to pay attention to the extremely prolonged distal latencies. Thus, in this case, TCE-MEP was useful for intraoperative spinal cord monitoring in spite of the polyneuropathy.

Conclusions

We describe for the first time scoliosis that was treated with surgery secondary to CIDP. During the surgical correction and fixation in this case, intraoperative spinal cord monitoring was performed. Despite the prolonged latency and low amplitudes, TCE-MEP could be recorded successfully in a stable manner.

Declaration of interest: The authors report no conflicts of interest. The authors alone are responsible for the content and writing of the paper.

References

- Köller H, Kieseier BC, Jander S, Hartung HP. Chronic inflammatory demyelinating polyneuropathy. *N Engl J Med*. 2005;352:1343–56.
- Karol LA, Elerson E. Scoliosis in patients with Charcot-Marie-Tooth Disease. *J Bone Joint Surg Am*. 2007;89:1504–10.
- Horacek O, Mazanec R, Morris CE, Kobesova A. Spinal deformities in hereditary motor and sensory neuropathy: a retrospective qualitative, quantitative, genotypical, and familial analysis of 175 patients. *Spine*. 2007;32:2502–8.
- Edwards MR, Panteliadis P, Lucas JD. Neuromuscular scoliosis as a sequelae of Guillain-Barré syndrome. *J Pediatr Orthop B*. 2010;19:95–7.
- Berman AT, Tom L. The Guillain-Barré syndrome in children. Orthopedic management and patterns of recovery. *Clin Orthop Relat Res*. 1976;116:61–5.
- Nirupam N, Sharma S, Aneja S, Kumar A. Childhood chronic inflammatory demyelinating polyneuropathy associated with acquired scoliosis: a case report. *J Child Neurol*. 2012;27:804–6.
- Lenke LG, Betz RR, Harms J, Bridwell KH, Clements DH, Lowe TG, et al. Adolescent idiopathic scoliosis: a new classification to determine extent of spinal arthrodesis. *J Bone Joint Surg Am*. 2001;83:1169–81.
- Austin JH. Recurrent polyneuropathies and their corticosteroid treatment; with five-year observations of a placebo-controlled case treated with corticotrophin, cortisone, and prednisone. *Brain*. 1958;81:157–92.
- Connolly AM. Chronic inflammatory demyelinating polyneuropathy in childhood. *Pediatr Neurol*. 2001;24:177–82.
- McLeod JG, Pollard JD, Macaskill P, Mohamed A, Spring P, Khurana V. Prevalence of chronic inflammatory demyelinating polyneuropathy in New South Wales, Australia. *Ann Neurol*. 1999;46:910–13.
- Lunn MP, Manji H, Choudhary PP, Hughes RA, Thomas PK. Chronic inflammatory demyelinating polyneuropathy: a prevalence study in south east England. *J Neurol Neurosurg Psychiatry*. 1999;66:677–80.
- Kararizou E, Karandreas N, Davaki P, Davou R, Vassilopoulos D. Polyneuropathies in teenagers: a clinicopathological study of 45 cases. *Neuromuscul Disord*. 2006;16:304–7.
- Winter RB. Neurologic safety in spinal deformity surgery. *Spine*. 1997;22:1527–33.
- Coe JD, Arlet V, Donaldson W, Berven S, Hanson DS, Mudiya R, et al. Complications in spinal fusion for adolescent idiopathic scoliosis in the new millennium. A report of the Scoliosis Research Society Morbidity and Mortality Committee. *Spine*. 2006;31:345–9.
- Modi HN, Suh SW, Yang JH, Cho JW, Hong JY, Singh SU, et al. Surgical complications in neuromuscular scoliosis operated with posterior-only approach using pedicle screw fixation. *Scoliosis*. 2009;4:11.
- Master DL, Son-Hing JP, Poe-Kochert C, Armstrong DG, Thompson GH. Risk factors for major complications after surgery for neuromuscular scoliosis. *Spine*. 2011;36:564–71.
- Research criteria for diagnosis of chronic inflammatory demyelinating polyneuropathy (CIDP) Report from an Ad Hoc Subcommittee of the American Academy of Neurology AIDS Task Force. *Neurology*. 1991;41:1718.
- Ashkenaze D, Mudiya R, Boachie-Adjei O, Gilbert C. Efficacy of spinal cord monitoring in neuromuscular scoliosis. *Spine*. 1993;18:1627–33.
- Tucker SK, Noordeen MH, Pitt MC. Spinal cord monitoring in neuromuscular scoliosis. *J Pediatr Orthop B*. 2001;10:1–5.
- DiCindio S, Theroux M, Shah S, Miller F, Dabney K, Brislin RP, et al. Multimodality monitoring of transcranial electric motor and somatosensory-evoked potentials during surgical correction of spinal deformity in patients with cerebral palsy and other neuromuscular disorders. *Spine*. 2003;28:1851–5.
- Langeloo DD, Journée HL, Polak B, de Kleuver M. A new application of TCE-MEP: spinal cord monitoring in patients with severe neuromuscular weakness undergoing corrective spine surgery. *J Spinal Disord*. 2001;14:445–8.