

Video electroencephalogram telemetry in temporal lobe epilepsy

Jayanti Mani

Department of Brain and Nervous System, Kokilaben Dhirubhai Ambani Hospital, Andheri West, Mumbai, Maharashtra India, Department of Medicine Lokmanya Tilak Memorial Medical College and Municipal Hospital, Mumbai, Maharashtra, India

Abstract

Temporal lobe epilepsy (TLE) is the most commonly encountered medically refractory epilepsy. It is also the substrate of refractory epilepsy that gives the most gratifying results in any epilepsy surgery program, with a minimum use of resources. Correlation of clinical behavior and the ictal patterns during ictal behavior is mandatory for success at epilepsy surgery. Video electroencephalogram (EEG) telemetry achieves this goal and hence plays a pivotal role in pre-surgical assessment. The role of telemetry is continuously evolving with the advent of digital EEG technology, of high-resolution volumetric magnetic resonance imaging and other functional imaging techniques. Most of surgical selection in patients with TLE can be done with a scalp video EEG monitoring. However, the limitations of the scalp EEG technique demand invasive recordings in a selected group of TLE patients. This subset of the patients can be a challenge to the epileptologist.

Key Words

Temporal lobe epilepsy, video electroencephalogram, presurgical evaluation

For correspondence:

Dr. Jayanti Mani, Department of Brain and Nervous System, Kokilaben Dhirubhai Ambani Hospital, 2nd Floor, Four Bungalows, Andheri West, Mumbai - 400 054, Maharashtra, India. E-mail: jayanti.mani@gmail.com

Ann Indian Acad Neurol 2014;17 (Supplement 1):S45-9

Introduction

Temporal lobe epilepsy (TLE), especially mesial temporal lobe epilepsy (mTLE) is the most common form of focal epilepsy in humans (Tandon 1989). The pathological substrate of mTLE is usually hippocampal sclerosis, the most frequent epileptogenic lesion encountered in patients with medically refractory epilepsy. The disabling seizures associated with mTLE that are generally resistant to antiepileptic drugs can be abolished in most patients by surgical treatment. The benefits of surgery for TLE have been well-demonstrated in terms of seizure control, cognitive function and quality-of-life.

Video Electroencephalogram (EEG) Telemetry in TLE

One of the main goals of pre-surgical evaluation in refractory epilepsy is the localization of the epileptogenic zone that has to be resected surgically. The gold standard for surgical localization is the electroencephalographic pattern recorded

during a habitual seizure. The electroclinical correlation during typical ictal behavior is the critical part of the pre-surgical evaluation. Most candidates for epilepsy surgery can be adequately investigated by a continuous scalp EEG recording over several hours to capture interictal and ictal EEG. The procedure involves continuous recording of synchronous scalp EEG and video over a period of 24 hours to 7 days, with the aim of recording interictal EEG and clinical seizures with corresponding ictal EEG. The advent of digital technology has allowed easy recording, retrieval and reformatting of large amounts of EEG and clinical data. Medications are gradually withdrawn with the aim of recording habitual seizures. The clinical semiology and the electrophysiological data provide independent lateralizing and localizing information during a seizure.

The purposes of video EEG telemetry assessment are:

- To confirm that the individual has true epileptic seizures (4-10% of patients in surgical programs have co-morbid psychogenic non-epileptic seizures; if untreated before surgery, non-epileptic attacks often become more florid and present a major management problem)
- To characterize electroclinical features and to establish whether these are concordant with other data magnetic resonance imaging (MRI, functional imaging, psychometry)
- To demonstrate epileptogenicity of the presumed pathological substrate of refractory epilepsy
- To identify other potential epileptogenic foci.

Access this article online

Quick Response Code:



Website:

www.annalsofian.org

DOI:

10.4103/0972-2327.128653

Electrode Placements in TLE

Standard EEG with 10-20 system provides limited coverage of the temporal regions detecting only about 58% of temporal spikes or interictal epileptiform discharges (IEDs). Additional electrodes help in increasing this yield.

Low anterior temporal scalp electrodes

Low anterior temporal electrodes as described by Daniel Silverman (T1 and T2, are placed at the junction of posterior one-third and anterior two-thirds of a line connecting the outer canthus of the eye and the tragus). These are often used to record from the anterior-basal areas of the temporal lobes.^[1,2]

Sphenoidal electrodes

The tip of the fluoroscopically placed sphenoidal depth electrodes (SP) lie at the superficial end of the foramen ovale. In principle, sphenoidal electrodes have an advantage over laterally placed scalp electrodes in detecting inferiorly directed mesial temporal discharges. However, the net added yield from sphenoidal electrodes in TLE EEG evaluation is relatively low, perhaps 5-10%.^[3,4] Hence whether SP should be used routinely in the pre-surgical evaluation of people with refractory epilepsy has remained controversial. They may be considered in patients with mTLE with poor yield of scalp interictal discharges or in bilateral mTLE. In this selected patient group, sphenoidal electrodes may provide unique localizing information, thus sparing them unnecessary invasive electrophysiology prior to surgery.

Interictal EEG in TLE

The interictal abnormalities on scalp EEG in TLE are:

1. Regional temporal polymorphic slowing (either theta or delta)
2. Temporal intermittent rhythmic delta activity (TIRDA)
3. Regional temporal IEDs that is often restricted to the anterior temporal areas.

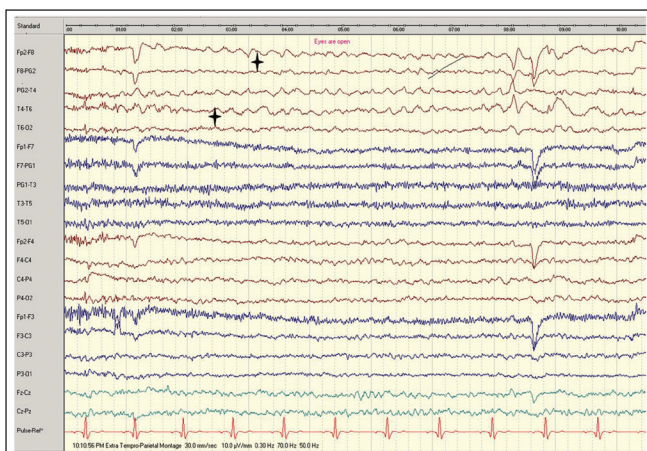


Figure 1: Bipolar anterior to posterior montage with 10-20 system showing 1-1.5 Hz temporal intermittent rhythmic delta activity over the right temporal region (stars) with maximal amplitude over anterior temporal region

TIRDA

Trains of rhythmic delta activity lasting 4-20 s and is observed in up to 25% of patients with TLE who are being evaluated for surgery. TIRDA is associated with TLE and more specific to mTLE and often associated with epileptiform discharges.^[5,6] TIRDA is considered to be an epileptiform equivalent in TLE [Figure 1].

Polymorphic delta activity on the other hand, could indicate a structural pathology if prolonged. It is seen in equal frequency in both TLE and extra TLE [Figure 2].^[6]

IEDs

The morphology and distribution of IEDs as well as the semiology help to differentiate between mTLE and lateral or neocortical temporal lobe epilepsy (nTLE).^[7]

The IEDs remain lateralized to the temporal regions in both syndromes. While in mTLE, IEDs are dominant over the anterior mesial temporal areas (T1/2, A1/2, F7/8 and T3/4) [Figure 3], patients with nTLE tend to have more lateral and posterior temporal IEDs (T5/6) [Figure 4] or widespread temporally distributed discharges. Although mesial temporal IEDs can infrequently occur in nTLE, the converse is unlikely, that is, mTLE patients usually do not have neocortical IEDs. Interictal discharges in the TLE associated with tumors, also show an increased tendency for bilateral expression of IEDs.^[8] However, typical anterior temporal spikes can also be seen in extratemporal epilepsy (AKA temporal plus syndrome).

Approximately, 30% of patients with unilateral TLE on other evaluation parameters show bitemporal IEDs.^[9,10] Many of these patients have a good post-operative outcome despite the bilaterality of the IEDs. However, greater degree of bilateral IEDs trends towards lesser post-operative seizure outcomes.^[11,12]

In addition to the interictal discharges the lateralization of ictal onset also predicts surgical outcomes in patients with bilateral

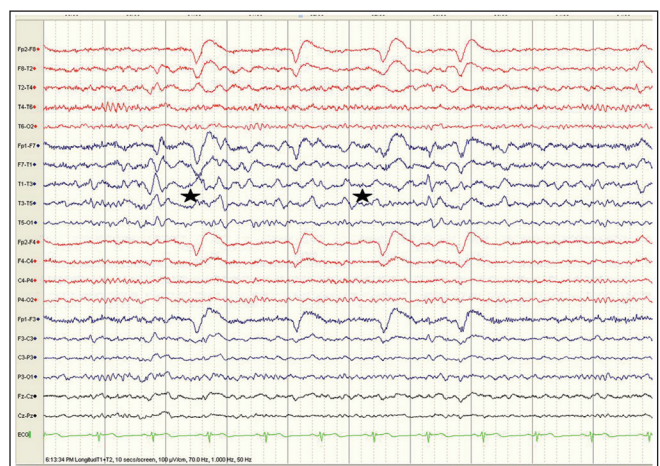


Figure 2: Bipolar anterior to posterior montage with 10-20 system showing 1-1.5 Hz temporal intermittent polymorphic delta activity over the left right temporal region (stars) intermixed with spikes with maximal amplitude over anterior temporal region

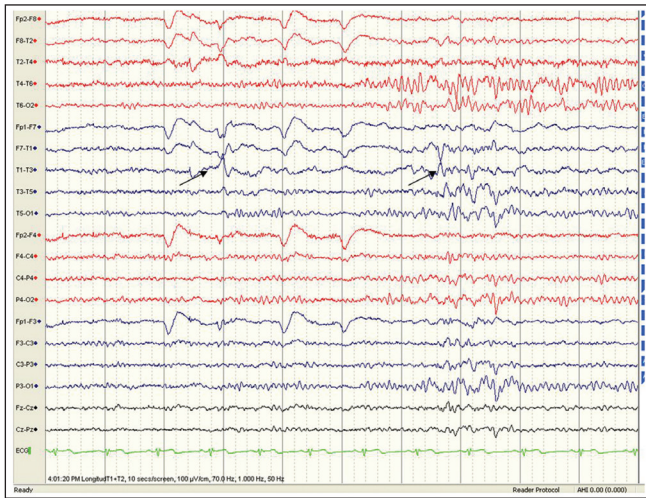


Figure 3: Typical electroencephalogram in a patient with left mesial temporal lobe epilepsy showing theta-delta activity over the right temporal region and right anterior temporal spikes (arrows) with phase reversal across F7 and T3 electrodes

temporal IEDs. Patients with bilateral IEDs who also have bilateral ictal onset show very poor outcome with surgery (only 12% seizure-free), while those with bilateral IEDs but unilateral seizure onset have a much better outcome (40-56%).^[13] Hence, a prolonged and repeated Video EEG recordings to capture several seizures may be desired to demonstrate consistency of ictal laterality in TLE with bilateral IEDs. The presence of bisynchronous IEDs in unilateral TLE is predictive of higher incidence for generalized seizures, but such patients still have favorable surgical outcome.^[14]

Sleep can increase the frequency of interictal spikes. Since IEDs are more prevalent in the non-rapid eye movement sleep than in wakefulness, yield of IEDs was better on overnight sleep EEGs obtained during the pre-surgical evaluation. The localization of interictal discharges however are better in the awake than in the sleep record.^[15]

Seizure Semiology in TLE

The seizures in TLE are typically complex partial, with or without simple partial onset. The semiologic features of TLE are highly varied. Various sensory phenomena or *auras* associated with mTLE. These include viscerosensory symptoms such as a rising epigastric sensation and experiential phenomena such as fear, *déjà* and *jamais vu*, orolimentary automatisms are common, occurring in approximately 70% of cases of limbic (hippocampal) seizures compared with 10% of patients with extra-limbic seizures. They often involve the hands (fumbling, picking and fidgeting) or mouth (chewing, lip smacking, swallowing). Less common automatisms associated with temporal lobe seizures include vocalizations, ictal speech and affective behaviors (out of context fear). Rarely behavioral phenomena, such as, crying (dacrystic), laughing (gelastic) and so-called “leaving behaviors,” for example, running out of the house have been observed.

Certain motor behaviors like late and sustained head and eye version, contralateral arm dystonia are features typical of but

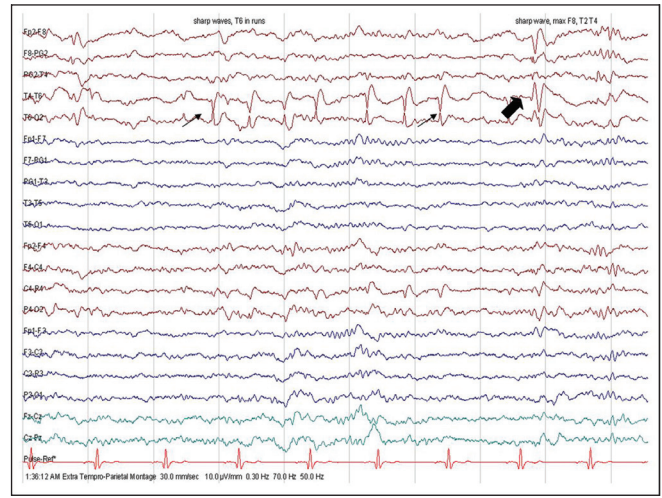


Figure 4: Scalp electroencephalogram in a patient with a right temporal lobe epilepsy due to posterior temporal neocortical dysplasia showing theta-delta activity over the right temporal region and right posterior temporal spikes (light arrows) with phase reversal across T6 electrode. A single anterior temporal spike is seen in the 8th s (solid arrow)

Table 1: Lateralization of semiologic features in TLE

Feature	Hemisphere	Incidence %	PPV %
Forced late head version	Contralateral	25-50	94
Early head version	Ipsilateral	25	
Focal clonic	Contralateral	30	95
Eye deviation	Contralateral	Rarely isolated	High if occipital
Hemidystonia	Contralateral	67	83
Asymmetric clonic ending	Ipsilateral	70 of secondarily generalized seizures	93
Sign of four	Contralateral to extended limb	70 generalized TL 31 generalized ET	89
Postictal aphasia	Dominant		90
Post ictal paresis	Contralateral	5 of CPS	100

Adapted from So EL. Value and limitations of seizure semiology in localizing seizure onset. J Clin Neurophysiol. 2006, 23:353-7. TLE = Temporal lobe epilepsy, CPS = Complex partial seizure, TL = Temporal lobes, PPV = Positive predictive values, ET = Extratemporal

not exclusive to TLE. They also have a strong lateralizing value for Temporal lobe seizures [Table 1].

Post ictal dysphasia in TLE has a strong lateralization to the dominant temporal lobe. Dysphasia is more common after dominant temporal rather than frontal lobe seizures.

Postictal aphasia is a very reliable lateralizing sign (80-90%)^[16,17] but specific postictal language testing must be utilized by the EMU in order to detect this phenomenon. Anomia and paraphasic errors are easy to demonstrate during seizures.^[16,18] Ictal speech preservation reliably predicts seizures of the non-dominant hemisphere origin.^[18] Seizures of non-dominant hemispheric origin, however, may interfere with speech function on the basis of postictal confusion.

Seizure semiology has some limitations in lateralizing and localizing the seizure origin. Many semiologic features have high positive predictive values; however, each feature has some potential to falsely localize the seizure onset.^[16] False localization should be suspected if the onset of clinical seizures occurs earlier than the onset of ictal EEG discharge.

TLE seizure semiology in children

The semiology of TLE in childhood seems to be influenced by age-related mechanisms. Ictal features in young children do not seem to provide many localizing or lateralizing clues to the ictal origin. Young preschool children often manifest an arousal type of reaction as the initial event with an eye opening, sitting up, or axial jerking. Some exhibit epileptic spasms resembling "infantile spasms."^[19,20] Most of the studies in young children describe an initial motor features such as tonic, dystonic and clonic movements bilaterally. They tend to be symmetrical and more typical of secondarily generalized seizures.^[21]

Ictal EEG in TLE

In majority (approximately 90%) with unilateral TLE (unilateral MRI abnormality and IEDs), the ictal lateralization corresponds to interictal IEDs and slowing. Ictal rhythms can be variable even within the same patient. Lateralization at the onset can be observed in only a third of unilateral TLE.^[22] Ictal EEG may not aid in differentiating the anterior from posterior lateral TLE.^[23]

Ebersole and Pacia classified the ictal rhythms in TLE into three types.^[24] Typical ictal surface EEG with high interrater concordance consists of a rhythmic 5-9 Hz theta activity that slowly evolves and remains localized to the temporal or sub-temporal regions, which is termed type 1 ictal rhythm [Figure 5]. This pattern is most specific for hippocampal seizures. A lower frequency of 2-5 Hz irregular ictal rhythm with widespread temporal distribution is termed as "type 2 rhythm" (Figure 6) and is often associated with neocortical seizures. Diffuse ictal EEG changes or attenuation without clear lateralization (type 3 rhythm) can be seen both in hippocampal and temporal neocortical seizures. The overlap in EEG findings between mTLE and nTLE in limbic seizures does not allow confident distinction between the two by ictal EEG alone.^[25,26]

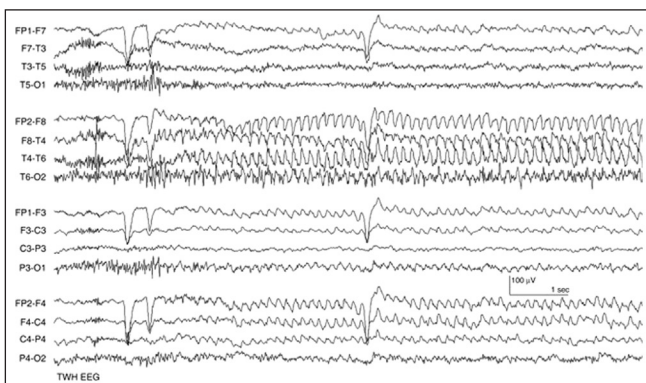


Figure 5: Ebersole ictal pattern type I involving the right temporal region (arrows) in one of the complex partial seizures recorded during continuous video (LFF = 1 Hz; HFF = 70 Hz) (LFF = Low-frequency filter, HFF = High frequency filter)

Comparison of surface and depth recordings of ictal patterns in mTLE

Correlating studies comparing surface EEG with simultaneous subdural electrodes (SEs) and depth electrodes demonstrate that most subclinical electrical seizures confined to the hippocampus do not result in surface EEG changes. When the seizure spreads from mesial temporal to the inferolateral temporal structures, type I surface rhythm is observed. Type 2 rhythms are often neocortical, with seizures starting as fast activity of 20-40 Hz on SEs that are either not detectable on surface EEG or are seen as "attenuation patterns" followed by asynchronous theta-delta activity over the temporal regions. Type 3 ictal rhythm occurs when seizures are confined to the hippocampus or spreads rapidly to the contralateral hippocampus, where there is little synchronization of the electrical activity over the inferior lateral temporal structures for expression on to the surface EEG.

Post Ictal EEG

Postictal EEG adds critical information particularly when seizure onset is unclear, or ictal changes are marred by the muscle artifacts. The accuracy of postictal findings for lateralization has a higher degree of interrater reliability particularly in TLE than extratemporal seizures.^[27] Postictal EEG findings include polymorphic lateralized delta activity, background suppression and postictal spikes 57%, 29% and 25%, respectively.^[28,29]

Postictal spikes are most sensitive for lateralization but may be affected by seizures spreading to the contralateral temporal lobe. In about a third, there may be no distinctive postictal change.

Limitations of Scalp Video EEG Recording

A majority of patients with lesional unilateral TLE especially mesial temporal sclerosis on MRI can be identified for surgery on the basis of scalp video EEG and non-invasive evaluation. However, there are a few limitations inherent with the scalp technique. Epileptiform activity from the remote cortical structures like the amygdale and the hippocampus may not be associated with extracranial EEG alterations. Attenuation of the spikes by the Dura bone and scalp also limits the sensitivity of scalp recordings. The activity may be further degraded by the muscle and movement artifacts. Hence a small but significant number of patients will need additional invasive evaluation for better delineation of the seizure onset zone.

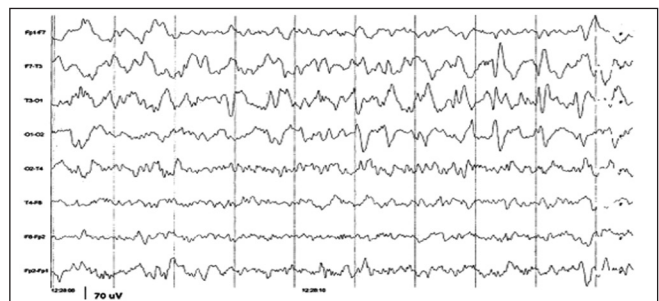


Figure 6: Ebersole ictal pattern type II involving the right temporal region (arrows) in one of the complex partial seizures recorded during continuous video (LFF = 1 Hz; HFF = 70 Hz) (LFF = Low-frequency filter, HFF = High frequency filter)

Table 2: Indications for intracranial EEG recordings

Temporal lobe syndrome with bilateral independent interictal or ictal abnormalities

Discordant data seizures originating from the side contralateral to the MRI abnormality or interictal discharges

Seizures with undetermined side of onset

Mesial versus neocortical seizure onset

“Temporal plus epilepsies”

EEG = Electroencephalogram, MRI = Magnetic resonance imaging

The indications for these are listed in Table 2. The invasive evaluation would include either depth or grid electrodes or a combination of both. The strategy will be designed on an individualized basis based on a working hypothesis of seizure onset and propagation as well as the need to map adjacent eloquent cortex. Studies comparing surface EEG with simultaneous SEs and DEs demonstrate that most subclinical electrical seizures confined to the hippocampus do not result in surface EEG changes.

Wasted Hippocampus Syndrome

In rare instances, one may come across the patients with a severe unilateral hippocampal sclerosis with contralateral ictal onset of seizures on scalp. These patients are often referred to have “wasted hippocampal syndrome.”^[30] In vast majority of patients, invasive recordings show seizures arising from the atrophic side and they have very good seizure outcomes with surgery.

References

- Silverman D. The anterior temporal electrode and the ten-twenty system. *Electroencephalogr Clin Neurophysiol* 1960;12:735-7.
- Nowack WJ, Janati A, Metzger WS, Nickols J. The anterior temporal electrode in the EEG of the adult. *Clin Electroencephalogr* 1988;19:199-204.
- Kissani N, Alarcon G, Dad M, Binnie CD, Polkey CE. Sensitivity of recordings at sphenoidal electrode site for detecting seizure onset: Evidence from scalp, superficial and deep foramen ovale recordings. *Clin Neurophysiol* 2001;112:232-40.
- Kanner AM, Parra J, Gil-Nagel A, Soto A, Leurgans S, Iriarte J, *et al.* The localizing yield of sphenoidal and anterior temporal electrodes in ictal recordings: A comparison study. *Epilepsia* 2002;43:1189-96.
- So N, Gloor P, Quesney LF, Jones-Gotman M, Olivier A, Andermann F. Depth electrode investigations in patients with bitemporal epileptiform abnormalities. *Ann Neurol* 1989;25:423-31.
- Geyer JD, Bilir E, Faught RE, Kuzniecky R, Gilliam F. Significance of interictal temporal lobe delta activity for localization of the primary epileptogenic region. *Neurology* 1999;52:202-5.
- Pfänder M, Arnold S, Henkel A, Weil S, Werhahn KJ, Eisensehr I, *et al.* Clinical features and EEG findings differentiating mesial from neocortical temporal lobe epilepsy. *Epileptic Disord* 2002;4:189-95.
- Hamer HM, Najm I, Mohamed A, Wyllie E. Interictal epileptiform discharges in temporal lobe epilepsy due to hippocampal sclerosis versus medial temporal lobe tumors. *Epilepsia* 1999;40:1261-8.
- Cendes F, Dubeau F, Andermann F, Quesney LF, Gambardella A, Jones-Gotman M, *et al.* Significance of mesial temporal atrophy in relation to intracranial ictal and interictal stereo EEG abnormalities. *Brain* 1996;119:1317-26.
- Aykut-Bingol C, Bronen RA, Kim JH, Spencer DD, Spencer SS. Surgical outcome in occipital lobe epilepsy: Implications for pathophysiology. *Ann Neurol* 1998;44:60-9.
- Schulz R, Lüders HO, Hoppe M, Tuxhorn I, May T, Ebner A. Interictal EEG and ictal scalp EEG propagation are highly predictive of surgical outcome in mesial temporal lobe epilepsy. *Epilepsia* 2000;41:564-70.
- Chung MY, Walczak TS, Lewis DV, Dawson DV, Radtke R. Temporal lobectomy and independent bitemporal interictal activity: What degree of lateralization is sufficient? *Epilepsia* 1991;32:195-201.
- Hufnagel A, Elger CE, Pels H, Zentner J, Wolf HK, Schramm J, *et al.* Prognostic significance of ictal and interictal epileptiform activity in temporal lobe epilepsy. *Epilepsia* 1994;35:1146-53.
- Sadler RM, Blume WT. Significance of bisynchronous spike-waves in patients with temporal lobe spikes. *Epilepsia* 1989;30:143-6.
- Malow BA, Kushwaha R, Lin X, Morton KJ, Aldrich MS. Relationship of interictal epileptiform discharges to sleep depth in partial epilepsy. *Electroencephalogr Clin Neurophysiol* 1997;102:20-6.
- So EL. Value and limitations of seizure semiology in localizing seizure onset. *J Clin Neurophysiol* 2006;23:353-7.
- Loddenkemper T, Kotagal P. Lateralizing signs during seizures in focal epilepsy. *Epilepsy Behav* 2005;7:1-17.
- Fakhoury T, Abou-Khalil B, Peguero E. Differentiating clinical features of right and left temporal lobe seizures. *Epilepsia* 1994;35:1038-44.
- Fogarasi A, Jokeit H, Faveret E, Janszky J, Tuxhorn I. The effect of age on seizure semiology in childhood temporal lobe epilepsy. *Epilepsia* 2002;43:638-43.
- Brockhaus A, Elger CE. Complex partial seizures of temporal lobe origin in children of different age groups. *Epilepsia* 1995;36:1173-81.
- Acharya JN, Wyllie E, Lüders HO, Kotagal P, Lancman M, Coelho M. Seizure symptomatology in infants with localization-related epilepsy. *Neurology* 1997;48:189-96.
- Pataria E, Lurger S, Serles W, Lindinger G, Aull S, Leutmezer F, *et al.* Ictal scalp EEG in unilateral mesial temporal lobe epilepsy. *Epilepsia* 1998;39:608-14.
- Lee SY, Lee SK, Yun CH, Kim KK, Chung CK. Clinico-electrical characteristics of lateral temporal lobe epilepsy; anterior and posterior lateral temporal lobe epilepsy. *J Clin Neurol* 2006;2:118-25.
- Ebersole JS, Pacia SV. Localization of temporal lobe foci by ictal EEG patterns. *Epilepsia* 1996;37:386-99.
- Foldvary N, Lee N, Thwaites G, Mascha E, Hammel J, Kim H, *et al.* Clinical and electrographic manifestations of lesional neocortical temporal lobe epilepsy. *Neurology* 1997;49:757-63.
- Pedley TA, Mendiratta A, Walczak TS. Seizures and epilepsy. In: Ebersole JS, Pedley TA, editors. *Current Practice of Clinical Electroencephalography*. 3rd ed. Philadelphia, PA, USA: Lippincott Williams and Wilkins; 2003. p. 506-87.
- Walczak TS, Radtke RA, Lewis DV. Accuracy and interobserver reliability of scalp ictal EEG. *Neurology* 1992;42:2279-85.
- Kaibara M, Blume WT. The postictal electroencephalogram. *Electroencephalogr Clin Neurophysiol* 1988;70:99-104.
- Blume WT, Holloway GM, Wiebe S. Temporal epileptogenesis: Localizing value of scalp and subdural interictal and ictal EEG data. *Epilepsia* 2001;42:508-14.
- Mintzer S, Cendes F, Soss J, Andermann F, Engel J Jr, Dubeau F, *et al.* Unilateral hippocampal sclerosis with contralateral temporal scalp ictal onset. *Epilepsia* 2004;45:792-802.

How to cite this article: Mani J. Video electroencephalogram telemetry in temporal lobe epilepsy. *Ann Indian Acad Neurol* 2014;17:45-9.

Received: 06-09-13, **Revised:** 02-10-13, **Accepted:** 02-10-13

Source of Support: Nil, **Conflict of Interest:** Nil