



# Extremely low birth weight infant surviving left congenital diaphragmatic hernia: a case report

Seongjin Choi<sup>1^</sup>, Euseok Jung<sup>1^</sup>, Jung-Man Namgoong<sup>2^</sup>, Jiyeon Jeong<sup>1^</sup>, Taehyen Cha<sup>1^</sup>, Byong Sop Lee<sup>1^</sup>, Ellen Ai-Rhan Kim<sup>1^</sup>, Ki-Soo Kim<sup>1^</sup>

<sup>1</sup>Department of Pediatrics, Asan Medical Center Children's Hospital, University of Ulsan College of Medicine, Seoul, Republic of Korea; <sup>2</sup>Division of Pediatric Surgery, Asan Medical Center Children's Hospital, University of Ulsan College of Medicine, Seoul, Republic of Korea

*Correspondence to:* Euseok Jung, MD. Department of Pediatrics, University of Ulsan College of Medicine, Asan Medical Center, 88, Olympic-ro 43-gil, Songpa-gu, Seoul 05505, Republic of Korea. Email: euisjung@amc.seoul.kr.

**Abstract:** In this study, we present the case of a 900 g, male infant born at 27+5 weeks, who was placed on high frequency oscillatory ventilation (HFOV) until repair of a left congenital diaphragmatic hernia (CDH) at 39 days of life (DOL). To date, this is the smallest infant with repair of the left CDH reported in the literature. After birth, he passed the cardiopulmonary stabilization phase and successfully underwent delayed surgery; in the process, he received ventilator assistance through HFOV. He weighed 1,660 gm at the time of surgery. We performed the thoracoscopic primary closure of the diaphragmatic defect. He was extubated on post-operation day (POD) 7 and discharged from hospital on POD 36 with 0.1 L/min supplemental oxygen via nasal cannula. He is being followed for growth and development and there has been no recurrence at the surgical site at 24 months of corrected age. In this case, high mean airway pressure (MAP) was required based on the patient's weight to achieve adequate recruitment of the left lung, and the patient was diagnosed with mental developmental delay on Bayley Scales of Infant Development-II. Thus, we suggest that the postnatal course and long-term outcomes for extremely low birth weight (ELBW) and preterm infants with left CDH is different from that for full-term babies. Therefore, future research should focus on preterm infants with left CDH.

**Keywords:** Congenital diaphragmatic hernias (CDH); extremely low birth weight (ELBW); survival; case report

Submitted Aug 16, 2021. Accepted for publication Oct 15, 2021.

doi: 10.21037/tp-21-355

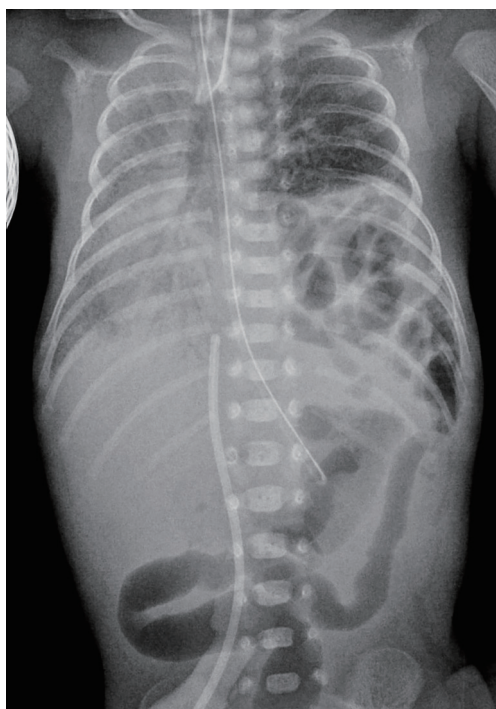
View this article at: <https://dx.doi.org/10.21037/tp-21-355>

## Introduction

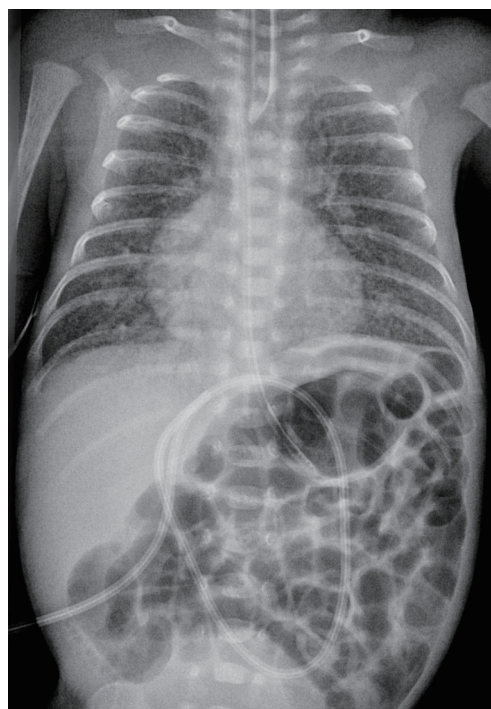
Congenital diaphragmatic hernia (CDH) is rare congenital disease, and most reports estimate the incidence at between 2 and 5 per 10,000 births. Through the development of ventilation strategies and surgical skills, the overall survival of infants with CDH is 68.7%; however, preterm infants (<37 weeks) have a significantly lower survival than full-term infants: 53.5% versus 73.1%, and survival decreases with younger gestational ages (GA) (1). Furthermore, it

has been reported that the survival rate is decreased for infants whose birth weight is under 2.5 kg (2). In the course of development, herniation of viscera into the thoracic cavity interrupts normal lung development, including bronchiolar branching and the surfactant system, and results in pathophysiologic pulmonary circulation, leading to supraphysiologic right-sided cardiac pressure, which causes pulmonary hypertension (3). Babies with CDH have varying degrees of pulmonary hypertension and hypoplasia and

<sup>^</sup> ORCID: Seongjin Choi, 0000-0002-7016-1585; Euseok Jung, 0000-0003-0693-5627; Jung-Man Namgoong, 0000-0002-9237-7440; Jiyeon Jeong, 0000-0002-3363-1162; Taehyen Cha, 0000-0002-6877-7516; Byong Sop Lee, 0000-0002-1347-4200; Ellen Ai-Rhan Kim, 0000-0002-9859-3021; Ki-Soo Kim, 0000-0003-1547-5220.



**Figure 1** Initial chest X-ray. The X-ray shows herniation of abdominal contents into the left hemithorax and mediastinal shift.



**Figure 2** After elevation of mean airway pressure (MAP). Abdominal contents are located beneath the diaphragm and the volume of the left lung has increased.

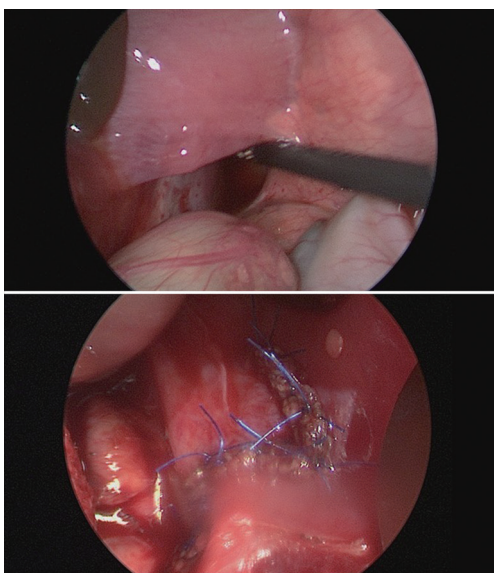
managing these aspects impacts their viability and survival. According to the International Network for Evaluating Outcomes of Neonates (iNeo), GA-specific survival rates among infants (24–29 weeks' gestation, birth weight <1,500 g) born between 2007 and 2013 decreased as GA decreased (4). Therefore, it can be reasonably estimated that preterm infants with CDH who have a low birth weight will have a poor prognosis.

We present the case of a 900 g, male infant born at 27<sup>+5</sup> weeks, who was placed on high frequency oscillatory ventilation (HFOV) until repair of the left CDH at 39 days of life (DOL). Despite his prematurity and size, he did not require corticosteroid treatment for bronchopulmonary dysplasia or medication for pulmonary hypertension. He was discharged with only 0.1 L/min supplemental oxygen via nasal cannula, and oxygen was stopped at postmenstrual age 41 weeks.

We present the following case in accordance with the CARE reporting checklist (available at <https://dx.doi.org/10.21037/tp-21-355>).

### Case presentation

A 900 g male was born at 27<sup>+5</sup> weeks of gestation via emergency cesarean section to a 37-year-old mother who had previously had two full-term pregnancies and one spontaneous abortion. Fetal anomaly scan at 18 weeks was reported as normal, and the current pregnancy was complicated by pre-eclampsia. At birth, he was awarded Apgar scores of 1 at 1 min, 3 at 5 min, and 7 at 10 min. In view of his gestation and extremely low birth weight (ELBW), he was intubated and given prophylactic surfactant for the treatment of respiratory distress syndrome. He was admitted to the regional neonatal intensive care unit (NICU), and was then transferred to the tertiary NICU for operation because left-sided CDH was diagnosed in his initial chest X-ray (*Figure 1*). Following admission, he was treated with HFOV to prevent barotrauma in the contralateral lung. On DOL 5, Mean airway pressure (MAP) was elevated to 14 cmH<sub>2</sub>O to achieve adequate recruitment of the ipsilateral lung (*Figure 2*). On DOL 6, blood pressure (BP) support with dopamine and hydrocortisone was required to maintain his arterial mean BP



**Figure 3** Thoracoscopic primary closure of the diaphragmatic defect.

levels ( $\geq 25$  mmHg), and an acute pulmonary hemorrhage was treated with epinephrine via endotracheal tube. On DOL 39, the diaphragmatic hernia was repaired. He weighed 1,660 g at the time of the operation. Thoracoscopic primary closure of the diaphragmatic defect, measuring approximately 3 cm  $\times$  2 cm, was performed. Small bowel, colon, and spleen were found in the thorax without malrotation or a hernia sac (*Figure 3*). After the operation, he was extubated on post-operation day (POD) 7 and discharged from hospital on POD 36 with 0.1 L/min supplemental oxygen via nasal cannula.

The postoperative hospital course was complicated by parenteral nutrition-associated liver disease, patent ductus arteriosus, and congenital hypothyroidism. Although parenteral fish oil (Omegaven<sup>®</sup>) and ursodeoxycholic acid were used, enteral feeds were postponed after repair on POD 3 (DOL 42), and cholestasis lasted until discharge without abnormality of biliary tract. Patent ductus arteriosus (3.9 mm) was detected by echocardiography on DOL 22; however, it was closed with fluid restriction and “watchful waiting”, not by pharmacologic management or surgical ligation. Levothyroxine was administered due to thyroid hormone deficiency.

At 24 months of corrected age, the patient’s weight was 9.7 kg ( $<3^{\text{rd}}$  percentile), height was 85.5 cm (10–25<sup>th</sup> percentile), and head circumference was 45 cm ( $<3^{\text{rd}}$  percentile). The Bayley Scales of Infant Development-II was performed to evaluate neurodevelopmental status, and

the mental development index was 69, indicating mental developmental delay. The psychomotor development index was 95.

All procedures performed in this study involving human participants were in accordance with the ethical standards of the institutional and/or national research committee(s) and with the Helsinki Declaration (as revised in 2013). Written informed consent was obtained from the patient’s parent or legal guardian for publication of this case report and accompanying images. A copy of the written consent is available for review by the editorial office of this journal.

## Discussion

In this case study, we report a surviving preterm infant with left CDH with the smallest birth weight reported in the literature to date. After birth, he passed the cardiopulmonary stabilization phase and successfully underwent delayed surgery; in the process, he received ventilator assistance through HFOV, during which the herniated organs were restored into the abdominal cavity. Even at his corrected age of 24 months, he is being followed for growth and development without recurrence at the surgical site.

During the past two decades, the surgical strategy for CDH has changed from early to delayed repair for cardiopulmonary stabilization with new supportive modalities such as HFOV, inhalation of nitric oxide, and extracorporeal membrane oxygenation. However, the optimal time for operating on preterm infants with CDH remains unclear. A recent risk-stratified analysis found that infants who underwent delayed repair had significantly lower birth weights, GAs, and mean APGAR 1 scores compared with those who underwent early repair (5). The patient in this report, who was 900 g at 27<sup>+5</sup> weeks of gestation, successfully underwent delayed surgery. Further studies on the operating time for preterm infants with CDH are needed.

In this case, HFOV was applied instead of conventional ventilation before CDH surgery. Moreover, HFOV was often used to recruit adequate lung volume while minimizing the effects of barotrauma and volutrauma. Simultaneously, we were inspired by the fetoscopic endoluminal tracheal occlusion (FETO) trial. FETO is currently considered for stimulation of fetal lung growth in fetuses with poor prognoses born between 26 and 30 weeks of gestation. Airway obstruction prevents the flow of pulmonary fluid from the lungs to the amniotic cavity, which creates lung growth by a mechanism of stretching

the lung parenchymal cells (6,7). A recently published meta-analysis that gathered data from five different studies revealed that the survival rate was better in the FETO group, with 7-fold greater odds of survival after FETO (8). In a similar way, we suggest that HFOV can stimulate lung growth by preserving end-expiratory lung volume and continuous alveolar recruitment. The patient discussed in this report was placed on HFOV at high MAP based on his weight, and his X-ray showed increased lung volume. It is known that CDH does not represent a recruitable lung and attempts to use a high MAP are likely to cause pulmonary damage (9). However, the situation can be different for ELBW or preterm infants who are still in the fetal state of the developmental process. In premature infants with CDH, higher MAP may have a positive effect on promoting lung development similar to FETO. More studies focused on prematurity are needed.

Despite the relapse-free survival, the patient in this case was diagnosed with mental developmental delay at the corrected age of 24 months. Improving survival for babies with CDH has increased the focus on neurodevelopmental outcomes in this vulnerable group. Neurodevelopmental impairment is one of the most common and most significant morbidities in CDH. Although the underlying mechanisms that contribute to brain injury in CDH are not completely understood, there is increasing evidence that the central nervous system development might be abnormal (10,11). Also, infants with CDH are exposed to potential risk of hypoxia, acidosis, and hypotension, all of which affect neurodevelopment. A recent review reported an 18% incidence of PVL (12); therefore, future research should focus on strategies to improve hemodynamics and brain perfusion to optimize neurodevelopment. Moreover, younger GA is associated with adverse neurodevelopmental outcomes, and preterm infants (24–33 weeks) had significantly lower scores in all composite Bayley Scales (13). According to the latest improvements in the survival of premature babies with CDH, appropriate evaluation of neurodevelopment and individual rehabilitation, including speech, occupational, and physical therapy is required for long-term management.

## Conclusions

This study reports the case of the smallest infant to date with repair of the left CDH. From this case, we suggest that the postnatal course and long-term outcomes for ELBW and preterm infants with left CDH could be different to

that for full-term babies. Therefore, future research focused on preterm infants with left CDH is required.

## Acknowledgments

The authors acknowledge all NICU staffs at Asan Medical Center.

*Funding:* None.

## Footnote

*Reporting Checklist:* The authors have completed the CARE reporting checklist. Available at <https://dx.doi.org/10.21037/tp-21-355>

*Conflicts of Interest:* All authors have completed the ICMJE uniform disclosure form (available at <https://dx.doi.org/10.21037/tp-21-355>). The authors have no conflicts of interest to declare.

*Ethical Statement:* The authors are accountable for all aspects of the work in ensuring that questions related to the accuracy or integrity of any part of the work are appropriately investigated and resolved. All procedures performed in this study involving human participants were in accordance with the ethical standards of the institutional and/or national research committee(s) and with the Helsinki Declaration (as revised in 2013). Written informed consent was obtained from the patient's parent or legal guardian for publication of this case report and accompanying images. A copy of the written consent is available for review by the editorial office of this journal.

*Open Access Statement:* This is an Open Access article distributed in accordance with the Creative Commons Attribution-NonCommercial-NoDerivs 4.0 International License (CC BY-NC-ND 4.0), which permits the non-commercial replication and distribution of the article with the strict proviso that no changes or edits are made and the original work is properly cited (including links to both the formal publication through the relevant DOI and the license). See: <https://creativecommons.org/licenses/by-nc-nd/4.0/>.

## References

1. Tsao K, Allison ND, Harting MT, et al. Congenital diaphragmatic hernia in the preterm infant. *Surgery* 2010;148:404-10.

2. Brindle ME, Cook EF, Tibboel D, et al. A clinical prediction rule for the severity of congenital diaphragmatic hernias in newborns. *Pediatrics* 2014;134:e413-9.
3. Gupta VS, Harting MT. Congenital diaphragmatic hernia-associated pulmonary hypertension. *Semin Perinatol* 2020;44:151167.
4. Helenius K, Sjörs G, Shah PS, et al. Survival in Very Preterm Infants: An International Comparison of 10 National Neonatal Networks. *Pediatrics* 2017;140:e20171264.
5. Hollinger LE, Lally PA, Tsao K, et al. A risk-stratified analysis of delayed congenital diaphragmatic hernia repair: does timing of operation matter? *Surgery* 2014;156:475-82.
6. Ruano R, Ali RA, Patel P, et al. Fetal endoscopic tracheal occlusion for congenital diaphragmatic hernia: indications, outcomes, and future directions. *Obstet Gynecol Surv* 2014;69:147-58.
7. Russo FM, De Coppi P, Allegaert K, et al. Current and future antenatal management of isolated congenital diaphragmatic hernia. *Semin Fetal Neonatal Med* 2017;22:383-90.
8. Al-Maary J, Eastwood MP, Russo FM, et al. Fetal Tracheal Occlusion for Severe Pulmonary Hypoplasia in Isolated Congenital Diaphragmatic Hernia: A Systematic Review and Meta-analysis of Survival. *Ann Surg* 2016;264:929-33.
9. Bohn D. Congenital diaphragmatic hernia. *Am J Respir Crit Care Med* 2002;166:911-5.
10. Tracy S, Estroff J, Valim C, et al. Abnormal neuroimaging and neurodevelopmental findings in a cohort of antenatally diagnosed congenital diaphragmatic hernia survivors. *J Pediatr Surg* 2010;45:958-65.
11. Hunt RW, Kean MJ, Stewart MJ, et al. Patterns of cerebral injury in a series of infants with congenital diaphragmatic hernia utilizing magnetic resonance imaging. *J Pediatr Surg* 2004;39:31-6.
12. Danzer E, Hedrick HL. Neurodevelopmental and neurofunctional outcomes in children with congenital diaphragmatic hernia. *Early Hum Dev* 2011;87:625-32.
13. Danzer E, Gerdes M, D'Agostino JA, et al. Younger gestational age is associated with increased risk of adverse neurodevelopmental outcome during infancy in congenital diaphragmatic hernia. *J Pediatr Surg* 2016;51:1084-90.

**Cite this article as:** Choi S, Jung E, Namgoong JM, Jeong J, Cha T, Lee BS, Kim EAR, Kim KS. Extremely low birth weight infant surviving left congenital diaphragmatic hernia: a case report. *Transl Pediatr* 2021;10(11):3091-3095. doi: 10.21037/tp-21-355