



Since January 2020 Elsevier has created a COVID-19 resource centre with free information in English and Mandarin on the novel coronavirus COVID-19. The COVID-19 resource centre is hosted on Elsevier Connect, the company's public news and information website.

Elsevier hereby grants permission to make all its COVID-19-related research that is available on the COVID-19 resource centre - including this research content - immediately available in PubMed Central and other publicly funded repositories, such as the WHO COVID database with rights for unrestricted research re-use and analyses in any form or by any means with acknowledgement of the original source. These permissions are granted for free by Elsevier for as long as the COVID-19 resource centre remains active.



Brazilian Journal of ANESTHESIOLOGY



CASE REPORT

Ultrasound-guided central venous access for patients in the Intensive Care Unit in prone position: report of three cases

Bruno Manuel Marques Lima *, Linda Cheung

Hospital de Braga EPE, Anesthesiology Unit, Braga, Portugal

Received 29 January 2021; accepted 9 October 2021

Available online xxx

KEYWORDS

Ultrasound;
Central venous catheter;
Internal jugular vein;
Prone position;
SARS-CoV-2 pneumonia;
Case report

Abstract

The prone position is extensively used to improve oxygenation in patients with severe acute respiratory distress syndrome caused by SARS-CoV-2 pneumonia. Occasionally, these patients exhibit cardiac and respiratory functions so severely compromised they cannot tolerate lying in the supine position, not even for the time required to insert a central venous catheter. The authors describe three cases of successful ultrasound-guided internal jugular vein cannulation in prone position. The alternative approach here described enables greater safety and well-being for the patient, reduces the number of episodes of decompensation, and risk of tracheal extubation and loss of in-situ vascular lines.

© 2021 Sociedade Brasileira de Anestesiologia. Published by Elsevier Editora Ltda. This is an open access article under the CC BY-NC-ND license (<http://creativecommons.org/licenses/by-nc-nd/4.0/>).

Introduction

The prone position is a widely used measure to improve oxygenation during severe Acute Respiratory Distress Syndrome (ARDS) treatment, enhancing patient survival rates.¹ During the COVID-19 pandemic, we have often observed Intensive Care Units (ICU) overcrowded with patients in prone position.² COVID-19 patients often require intravenous administration of several drugs and vasopressors; therefore, they require the placement of a central venous line. In a patient in prone position, the Internal Jugular Vein (IJV) is the only feasible venous access for ultrasound-guided placement of a

Central Venous Catheter (CVC). The existing literature dealing with the insertion of a CVC in the patient in prone position is scarce,^{3,4} and it reports few cases in the perioperative and ICU settings. In some of these reports, the placement of central venous lines in patients in prone position is even described by the authors as a last resort.

The present report aims to describe the use of ultrasonography for inserting a central venous catheter in the internal jugular vein of patients in prone position, and the feasibility of this approach in ICU and Operating Room (OR) current practice.

Case reports

Patient 1: Female, 51 years old, American Society of Anesthesiologists (ASA) physical status II, past medical history of

* Corresponding author.

E-mail: bmmlima82@gmail.com (B.M. Lima).

<https://doi.org/10.1016/j.bjane.2021.10.008>

0104-0014/© 2021 Sociedade Brasileira de Anestesiologia. Published by Elsevier Editora Ltda. This is an open access article under the CC BY-NC-ND license (<http://creativecommons.org/licenses/by-nc-nd/4.0/>).

Please cite this article in press as: B.M. Lima and L. Cheung, Ultrasound-guided central venous access for patients in the Intensive Care Unit in prone position: report of three cases, Brazilian Journal of Anesthesiology (2021), <https://doi.org/10.1016/j.bjane.2021.10.008>

High Blood Pressure (HBP), depressive disorder and dyslipidemia. She was admitted to the ICU for SARS-CoV-2 pneumonia with severe hypoxemic respiratory failure. Shortly after admission, she was submitted to urgent tracheal intubation and mechanical ventilation, but due to hypoxemia severity, she was immediately placed in prone position and ventilated with an inspired oxygen fraction (FiO₂) of 1.0, with subsequent improvement of oxygenation.

Patient 2: Male, 64 years old, physical status ASA III, past medical history of HBP, type 2 Diabetes Mellitus (DM2), dyslipidemia, obesity, smoker, severe obstructive sleep apnea syndrome, and cerebrovascular disease. He had been in the ICU for 15 days for SARS-CoV-2 pneumonia, with bacterial superinfection, severe ARDS, and extremely low lung compliance. He had a right subclavian vein CVC in situ for 14 days and showed evident worsening of inflammatory markers (Procalcitonin and C-Reactive Protein).

Patient 3: Male, 71 years old, physical status ASA III, past medical history of HBP, insulin dependent DM2, and chronic kidney disease status III. He had been in the ICU for 21 days due to SARS-CoV-2 pneumonia, with bacterial superinfection and severe ARDS. He had a right IJV CVC in situ for 12 days, with evident inflammatory signs at the catheter insertion site and showed worsening of inflammatory markers.

All three patients were unable to tolerate the supine position. After emergency tracheal intubation of Patient 1, her severe clinical instability did not allow keeping her in supine position for the time requested for the placement of a CVC. Patients with severe ARDS generally are kept in prone position for periods of 16 to 20 hours daily,¹ but Patients 2 and 3 were kept in the prone position continuously for periods of more than 48 hours, because they could not tolerate the supine position. Prior attempts to switch to supine position, precipitated severe hypoxemia (peripheral oxygen saturation less than 50%) and hemodynamic instability (hypotension and dysrhythmias). Patient 3 even presented a peri-arrest period, with extreme bradycardia associated

with severe hypotension. Given the worsening clinical status and suspected infection of Patients 2 and 3, requiring antibiotic therapy adjustment, we decided to replace the central venous catheter immediately, and with the patients in prone position.

Inserting CVC in the right IJV in two of the three patients would be feasible, but we decided to place the catheter in the left IJV in all patients. The rationale was the lower theoretical risk of inadvertent entry of the guidewire into the right ventricle, with the risk of cardiac arrhythmias and eventual cardiac arrest in a patient in prone position and already receiving inotropics, that are potentially arrhythmogenic drugs.

For CVC placement in the IJV, we turned the heads of the patients to the left and after verifying orotracheal tube positioning, we firmly secured it. To ensure better neck exposure and capturing of ultrasound images of cervical structures, we applied a slight elevation of the trunk with a pillow, extended the neck, applied traction over the ipsilateral shoulder with adhesive tape (or help from a collaborator), and tilted the bed to 15° Trendelenburg (Fig. 1A).

US machines used were the Logiq™ P9 (GE Healthcare) with a linear probe (6–12 MHz) and the Siemens Acuson™ X600, with a linear probe (5–10 MHz). Maintaining an aseptic technique, the operator was positioned at the patient's head. The US machine screen was placed on the patient's side and facing the operator, ensuring ideal ultrasound ergonomics and optimal hand-eye coordination for performing the technique.

The probe was initially placed on the lateral side of the patient's neck, in a transverse plane, enabling the identification of the Sternocleidomastoid Muscle (SCM), the Carotid Artery (CA) and the IJV. Compared to CA, the IJV image is a hypoechoic, non-pulsatile and more collapsible structure. IJV size varies among patients and is highly dependent on intravascular volume status. Before IJV puncture, we moved the probe caudally, from the base of the mandible to the

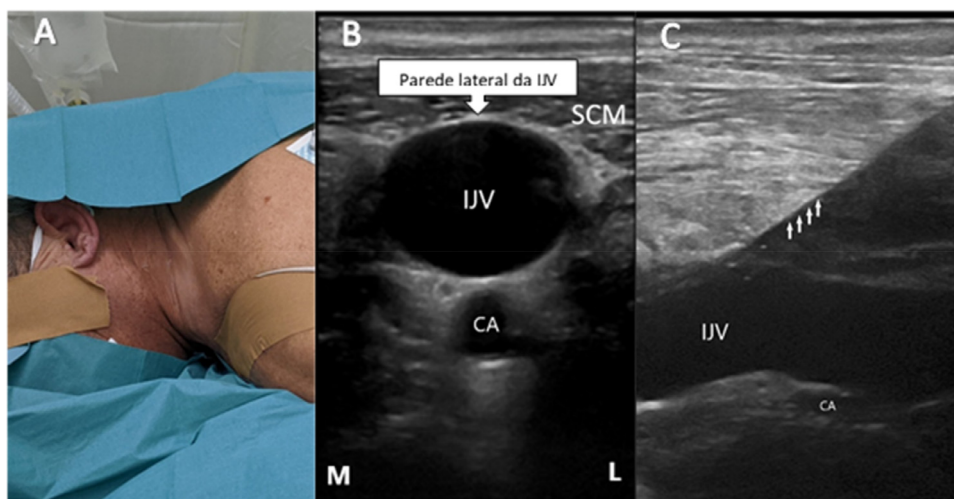


Figure 1 A, Positioning of the patient for CVC placement in the prone position; B, anatomical US landmarks of the out-of-plane approach; C, Direct ultrasound image of needle insertion during in-plane approach. CVC, Central Venous Catheter; SCM, Sternocleidomastoid Muscle; IJV, Internal Jugular Vein; CA, Carotid Artery; ↑↑↑↑, needle; M, Medial; L, Lateral.

Parede lateral da IJV = IJV lateral wall

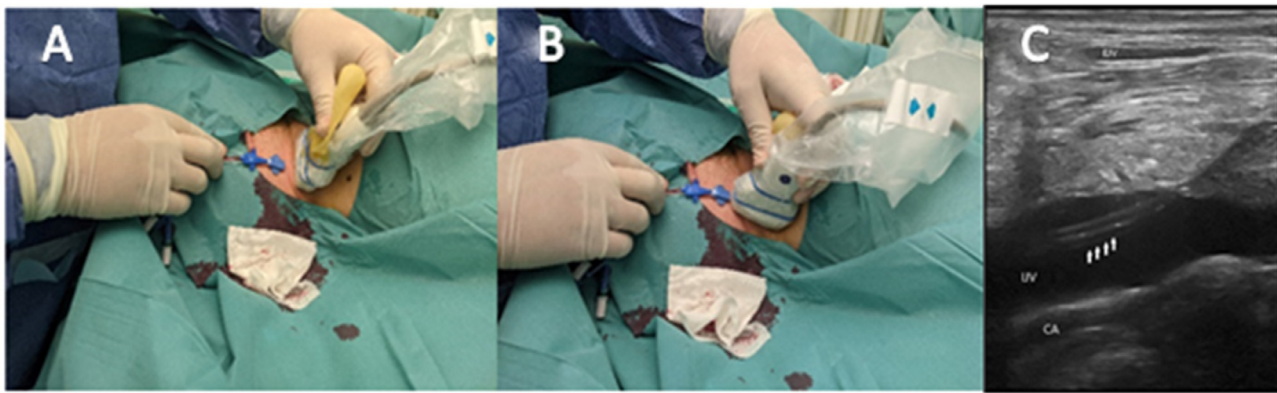


Figure 2 A, Probe orientation for the out-of-plane approach to confirm the correct position of the CVC; B, Probe orientation for the in-plane approach to confirm the correct position of the CVC; C, Direct ultrasound image of the CVC inserted inside the IJV in the in-plane approach. CVC, Central Venous Catheter; EJV, External Jugular Vein; IJV, Internal Jugular Vein; CA, Carotid Artery; ↑↑↑↑, Central Venous Catheter.

base of the neck and performed a careful analysis of the anatomical relationship between the IJV and the Internal Carotid Artery, and confirmed IJV trajectory and patency.

When performing the anterior approach with the patient in supine position, the needle penetrates the anterior wall of the IJV, usually anterior and lateral to the CA. On the other hand, when one performs the modified anterior approach on a patient in prone position and with ipsilateral rotation of the neck, the needle penetrates the IJV lateral wall, usually anterior to the CA (Fig. 1B).

After identifying anatomical ultrasound landmarks using the out-of-plane approach, the needle pierced the skin with an entry angle of about 45° with the operator continuously applying aspiration in the distal third between the mandible angle and clavicle. After the vein was punctured, the CVC was inserted using the Seldinger technique.

Since the CA was located posteriorly to the IJV in this position (Fig. 1B) and, because arterial blood color of critically ill patients with COVID-19 can be misleading and be misperceived as venous blood, it is desirable to verify the correct positioning of the guidewire (or needle) in the IJV before inserting the dilator. Rotating US probe from the transverse to the longitudinal plane enables confirmation of IJV cannulation (Fig. 1C).

The length of insertion of the CVC (7 French, 3 or 4 lumens, 20 centimeters long, Arrow®) was adjusted to the height of each patient. After checking the proper placement of the catheter inside the IJV (Fig. 2 A–C) and confirming the patency of all lumens, the catheter was fixed to the skin by a silk suture.

For all three patients, at the end of the procedure, gas analysis was obtained to confirm venous blood, and a postero-anterior chest X-Ray was performed to confirm the correct location of the catheter tip and rule out complications. All procedures were uneventful.

Discussion

In this case report, IJV cannulation was successfully performed through a modified anterior approach, in patients kept in prone position due to severe pneumonia caused by SARS-CoV-2.

Patients with ARDS due to SARS-CoV-2 present reduced physiological reserve and cardiorespiratory instability that may preclude them from tolerating supine position even for the execution of short-time procedures, such as hygiene care or CVC placement. In these circumstances, maintaining the prone position warrants greater patient safety and well-being, reduces the risks of tracheal extubation and loss of in situ vascular lines, and the number of episodes of clinical decompensation, that can increase need for higher FiO₂, leading to worsening of the lung injury.

Like every invasive technique, CVC placement is associated with risks and complications. These are largely associated with operator experience, use of US, and patient-related factors such as coagulation disorders, anatomical anomalies, and obesity.

Among the most frightening complications, severe arrhythmias can be triggered by central venous catheterization and can progress to cardiac arrest requiring advanced life support in the prone position. This will always be a limiting factor for this technique, despite the fact that the effectiveness of resuscitation maneuvers in prone position has been reported.⁵

Ideally, this approach should be performed by two operators, allowing continuous real-time visualization of the CVC insertion on the US screen, with expected improvement in patient safety and procedural efficiency.

Conclusion

The limited number of cases described in the literature dealing with the US-guided placement of vascular lines for patients in prone position, makes this case report more relevant. If performed by trained and experienced personnel, the modified anterior approach may be an effective, feasible and safe alternative for the placement or replacement of CVC in ICU patients who need to be kept for extended periods in the prone position.

More studies are required to validate the benefits and effectiveness of this approach. There is the prospect of the approach being used in other scenarios, such as during surgery performed in prone position and when other types of

catheters need to be inserted (e.g., hemofiltration and extracorporeal oxygenation).

Conflicts of interest

The authors declare no conflicts of interest.

References

1. Guérin C, Reigner J, Richard JC, et al. Prone positioning in severe acute respiratory distress syndrome. *N Engl J Med.* 2013;368:2159–68.
2. Mittermaier M, Pickerodt P, Kurth F, et al. Evaluation of PEEP and prone positioning in early COVID-19 ARDS. *EClinicalMedicine.* 2020;28:100579.
3. Chen GY, Cheng KI, Hsu HT, Lu YM. Ultrasound-guided central venous catheterization in the prone position. *Br J Anaesth.* 2017;119:337–8.
4. Flament T, Mankikian J, Mercier E. Ultrasound-guided insertion of dialysis catheter in the prone position. *Intensive Care Med.* 2014;40:620.
5. Anez C, Becerra-Bolaños A, Vives-Lopez A, Rodríguez-Pérez A. Cardiopulmonary resuscitation in the prone position in the operating room or in the intensive care unit: a systematic review. *Anesth Analg.* 2021;132:285–92.