



Open Access

ORIGINAL ARTICLE

Male Health

3D digital image microscope system-assisted vasovasostomy and vasoepididymostomy in rats

Peng Li^{1,*}, Na-Chuan Liu^{1,*}, Er-Lei Zhi¹, Chen-Cheng Yao¹, Zhi-Liang Zhao², Zhi-Yong Yu³, Qi-Meng Li⁴, Yu-Hua Huang¹, Jie-Chang Ju⁵, Wen-Bin Huang⁶, Husanjan Rozi⁷, Zhi-Yong Ji⁸, San-Wei Guo⁹, Ru-Hui Tian¹, Zheng Li¹

Optimal vision and ergonomics are essential factors contributing to the achievement of good results during microsurgery. The three-dimensional (3D) digital image microscope system with a better 3D depth of field can release strain on the surgeon's neck and back, which can improve outcomes in microsurgery. We report a randomized prospective study of vasoepididymostomy and vasovasostomy using a 3D digital image microscope system (3D-DIM) in rats. A total of 16 adult male rats were randomly divided into two groups of 8 each: the standard operating microscope (SOM) group and the 3D-DIM group. The outcomes measured included the operative time, real-time postoperative mechanical patency, and anastomosis leakage. Furthermore, a user-friendly microscope score was designed to evaluate the ergonomic design and equipment characteristics of the microscope. There were no differences in operative time between the two groups. The real-time postoperative mechanical patency rates were 100.0% for both groups. The percentage of vasoepididymostomy anastomosis leakage was 16.7% in the SOM group and 25.0% in the 3D-DIM group; however, no vasovasostomy anastomosis leakage was found in either group. In terms of the ergonomic design, the 3D-DIM group obtained better scores based on the surgeon's feelings; in terms of the equipment characteristics, the 3D-DIM group had lower scores for clarity and higher scores for flexibility and adaptivity. Based on our randomized prospective study in a rat model, we believe that the 3D-DIM can improve surgeon comfort without compromising outcomes in male infertility reconstructive microsurgery, so the 3D-DIM might be widely used in the future.

Asian Journal of Andrology (2021) 23, 396–399; doi: 10.4103/aja.aja_94_20; published online: 09 February 2021

Keywords: microsurgery; three-dimensional digital image microscope system; vasoepididymostomy; vasovasostomy

INTRODUCTION

Male infertility microsurgery is regarded as the most successful procedure to restore patency to the vas deferens or epididymis with the return of sperm in the ejaculate.¹ Refinements in the technique have continually improved the patency and pregnancy rates for microsurgical vasovasostomy (VV) and vasoepididymostomy (VE) in experienced hands. Although excellent results depend on the surgeon's skill and technique, optimal vision and ergonomics are also important factors contributing to the achievement of good results during male infertility microsurgery. Because of a stable, ergonomic, scalable control system with three-dimensional (3D) visualization and magnification, robotic microsurgical procedures have been applied in male infertility. Several other advantages include the elimination of tremor, multiview magnification, enhanced dexterity with articulating instrument arms, and short learning curve.² However, access to robotic platforms is not available in some countries. Recently, the use of a new revolutionary technology, the 3D digital image microscope system (3D-DIM) with a video-assisted telescope operating monitor, may fill the gap between

the need for good surgical vision and maintenance of a comfortable posture during surgery and may improve surgeon comfort.³

The 3D-DIM, with possibilities of an application similar to that of the operating microscope, allows working in a setting that is similar to that of endoscopic surgery. The video-assisted telescope operating monitor has been reported to be applied in cranial surgery, microvascular anastomosis, and spinal surgeries.^{4,5} Male infertility reconstructive microsurgery remains the most technically and physically challenging procedure.¹ We aimed to explore the application of the 3D-DIM in VV and VE. To our knowledge, there have been no prior reports of 3D system VV and VE, so we report a randomized prospective study of VV and VE using the 3D-DIM system in rats.

MATERIALS AND METHODS

Animal selection

A total of 16 adult male Sprague–Dawley (SD) rats were housed in groups of 2 animals per cage, and the weights ranged from 250 g to 300 g (mean ± standard deviation [s.d.]: 269 ± 15 g) at the start of

¹Shanghai General Hospital, Shanghai Jiao Tong University School of Medicine, Shanghai 200080, China; ²Gansu Provincial Hospital of Traditional Chinese Medicine, Lanzhou 730050, China; ³Weifang Traditional Chinese Hospital, Weifang 250200, China; ⁴The Third Affiliated Hospital of Wenzhou Medical University, Wenzhou 325000, China; ⁵Zhengzhou Central Hospital Affiliated with Zhengzhou University, Zhengzhou 450007, China; ⁶Wenzhou Integrated Traditional Chinese, Wenzhou 325000, China; ⁷Kashgar District Second People's Hospital, Kashgar 844000, China; ⁸Shanghai General Hospital of Nanjing Medical University, Shanghai 200080, China; ⁹Shanghai Tenth People's Hospital, Tongji University, Shanghai 200072, China.

*These authors contributed equally to this work.

Correspondence: Dr. Z Li (lizhengboshi@163.com)

Received: 28 February 2020; Accepted: 27 November 2020

the study. The procedure was approved by the Ethics Committee of Shanghai General Hospital (2017KY020-2, Shanghai, China).

Microsurgical techniques

The animals were randomly divided into a standard operating microscope (SOM) group and a 3D-DIM group. The animals were anaesthetized with a ketamine/xylazine mixture. A midline abdominal incision was made. The testes and vasa were delivered into the wound, and all adhesions were bluntly dissected. In both groups, animals were further randomized to undergo multilayer VV (Figure 1a–1c)⁷ or modified single-armed longitudinal VE (Figure 1d–1f).⁸ In the SOM group, the microsurgical procedures were performed with a Zeiss F140 operating microscope (Carl Zeiss, Oberkochen, Germany) providing $\times 4$ – $\times 25$ magnification. In the 3D-DIM group, we performed surgery with a 3D-DIM (Mitaka Kohki, Mitaka, Japan) at $\times 1.9$ – $\times 39.3$ magnification (Supplementary Figure 1). The 3D-DIM was placed over the surgical field, the working distance was 350–900 mm, and two surgeons stood on each side of the operating table in a natural position and looked at opposite monitors on both sides. The entire procedure was captured on 3D digital high-definition video. One experienced surgeon performed all the procedures.

Assessment of anastomosis and patency evaluations

The animals were sacrificed immediately postoperatively, and anastomotic patency was assessed mechanically. Patency was evaluated by performing a distal vasectomy and examining the fluid expressed after gentle pressure to the testis and the epididymis. The presence of vasal fluid indicated patency (Figure 1c and 1f). However, leakage was identified as the presence of vasal fluid from the anastomosis site.

User-friendly microscope score

An assessment scale was designed to evaluate the difference in comfort between the 3D-DIM and SOM in terms of eye fatigue, neck/back pain,

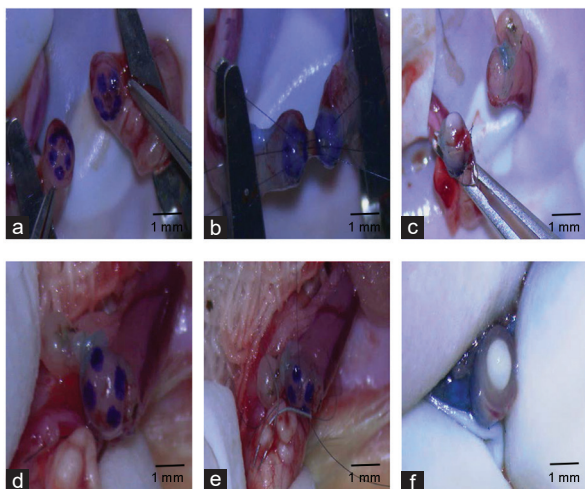


Figure 1: 3D-DIM-assisted multilayer vasovasostomy and single-armed longitudinal vasoepididymostomy. (a) Six microdots marked on each vasal end. (b) Three interrupted sutures of 10–0 single-armed monofilament prolene placed through the mucosal layer of the anterior part of the vas deferens. (c) Distal vas transected and presence vasal fluid noted. (d) Four microdots marked on vasal end. (e) 10–0 nylon single-armed sutures placed parallel and longitudinal into epididymal tubule. (f) Distal vas transected and presence vasal fluid noted. Scale bars = 1 mm. 3D-DIM: three-dimensional digital image microscope system.

dizziness, clarity, flexibility, and adaptivity (Supplementary Table 1). Clarity refers to the quality of the images displayed on the screen of the 3D-DIM or through the SOM. At higher resolutions, such as 3840×2160 pixels (4K), items appeared sharper. Flexibility refers to the ability of a microscope to change the position or be moved easily. Adaptivity refers to the surgeon's subjective experience of the microscope, whether they can adapt it quickly and are willing to operate it. All the surgeons (8 surgeons) who took part in this study completed the scale to assess their degree of acceptance of the microscope during the operation. Relevant statistical analysis studies were conducted.

Statistical analyses

The operative time, user-friendly score, patency rates, and leakage rates were calculated. The Student's *t*-test was used for the operative time and user-friendly score analyses, and the Fisher's exact test was used for patency and leakage analysis. Statistical significance was declared at $P < 0.05$.

RESULTS

There were no differences in operative time (mean \pm standard error of mean [s.e.m.]) between the 3D-DIM and SOM groups (VV: 54.0 ± 6.3 min vs 55.9 ± 10.6 min, $P = 0.68$; VE: 44.4 ± 4.6 min vs 44.6 ± 11.7 min, $P = 0.96$, respectively). The real-time postoperative mechanical patency rates were 100.0% in both groups. The percentage of VE anastomosis leakage was 16.7% in the SOM group and 25.0% in the 3D-DIM group. No VV anastomosis leakage was found in either group (Table 1).

For the user-friendly score of the microscope, the scales were collected when all the surgeries were finished. In terms of the assessment of user-friendly microscope scores (mean \pm s.e.m.), the 3D-DIM group had higher scores for eye discomfort and pain (3D-DIM: 3.9 ± 1.6 vs SOM: 2.1 ± 0.7 , $P = 0.004$), neck/back pain (3D-DIM: 5.0 ± 0.0 vs SOM: 2.3 ± 0.9 , $P = 0.00002$), and dizziness (3D-DIM: 3.4 ± 1.6 vs SOM: 3.4 ± 0.9 , $P = 1.0$); in terms of the equipment characteristics of the operating microscope, the 3D-DIM group had lower scores for clarity (3D-DIM: 2.4 ± 0.8 vs SOM: 4.4 ± 0.7 , $P = 0.0001$) and higher scores for flexibility (3D-DIM: 4.3 ± 1.0 vs SOM: 3.3 ± 0.9 , $P = 0.04$) and adaptivity (3D-DIM: 4.3 ± 0.9 vs SOM: 3.5 ± 0.8 , $P = 0.09$), as shown in Figure 2.

DISCUSSION

The 3D-DIM is gradually entering surgical practice. It was initially optimized for neurosurgery and was increasingly applied in pituitary, skull base, and spinal surgeries;⁹ it allows limited skin and bone opening when providing adequate surgical exposure and visualization of buried structures, resulting in decreased postoperative discomfort and complications.¹⁰ The 3D-DIM allows the surgeon to operate in a natural and comfortable ergonomic position that can be maintained

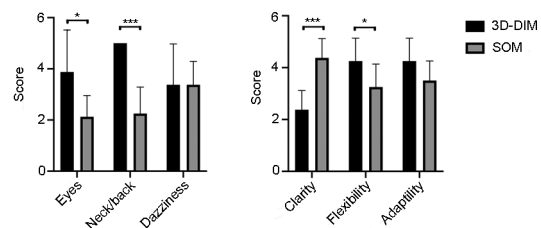


Figure 2: Scores of the 3D-DIM and SOM systems. * $P < 0.05$; *** $P < 0.001$. 3D-DIM: three-dimensional digital image microscope system; SOM: standard operating microscope.

Table 1: Outcomes of 3D-DIM versus SOM VE and 3D-DIM versus SOM VV by operative time, leakage, and patency

Variable	VV			VE		
	3D-DIM (n=8)	SOM (n=8)	P	3D-DIM (n=8)	SOM (n=6)	P
Operative time (min), mean±s.e.m.	54.0±6.3	55.9±10.6	0.68	44.4±4.6	44.6±11.7	0.96
Leakage, % (n/total)	0 (0/8)	0 (0/8)	-	25.0 (2/8)	16.7 (1/6)	1
Patency, % (n/total)	100.0 (8/8)	100.0 (8/8)	-	100.0 (8/8)	100.0 (6/6)	-

3D: three-dimensional; 3D-DIM: 3D digital image microscope system; SOM: standard operating microscope; VV: vasovasostomy; VE: vasoevididymostomy; -: no comparability between two groups; s.e.m.: standard error of means

Table 2: Comparison between the 3D-DIM and SOM

	3D-DIM	SOM
Magnification	1×–39.3×	1×–30×
Focal length (cm)	30–100	20–50
Stereopsis	3D	3D
Image capture	3D-2K monitor	Full-HD LCD display
Eye lens	No	Yes
Surgeon comfort	High	Medium

3D: three-dimensional; 3D-DIM: 3D digital image microscope system; SOM: standard operating microscope; HD: high-definition; LCD: liquid crystal display

during the entire procedure. The bionic design allows for a natural view with a real sense of the depth of field, allows precise left and right eye image alignment for a natural review, relieves surgeons' stress, and allows for easy image sharing.⁴ The main advantages of the 3D system in the use of neurosurgery are as follows: visualization, ergonomics, and versatility. This is similar to robot-assisted microsurgery for male infertility using the Da Vinci platform, which offers 3D high-definition (HD) visualization, excellent ergonomics, and flexibility. There are several potential benefits of robot-assisted microsurgery: a stable, ergonomic, scalable control system with 3D visualization and magnification and elimination of tremor.² Schiff *et al.*¹¹ reported an animal study of robotic technology for reconstructive microsurgery in 2004 and stated that the robotic systems currently available do not offer overall benefits in surgical outcomes other than the elimination of tremor in the hands of tremor-prone microsurgeons.¹² Chan *et al.*¹² stated that long-term outcomes are comparable for robotic and microsurgical vasectomy reversal and varicocelelectomy, and the learning curve for better postoperative outcomes can be achieved faster by microsurgeons utilizing the robotic platform. Unfortunately, there are only a few hospitals with robotic platform in China, and it is difficult for us to access robotic platforms currently.

The rat vas deferens measures approximately 1.5–2 mm in outer diameter and 0.15–0.25 mm in luminal diameter. For experienced surgeons, the unobstructed rat model may also be used for microsurgical training or research.¹³ Therefore, we performed VV and VE in unobstructed rats in both groups. Surprisingly, for VV, the real-time postoperative mechanical patency rates were 100.0% in both groups, and there was no anastomosis leakage; for VE, the percentage of anastomosis leakage was 16.7% in the SOM group and 25.0% in the 3D-DIM group ($P > 0.05$), which might have caused a higher anastomosis stricture rate if these animals were followed for months to years. However, a 100.0% real-time postoperative mechanical patency rate was observed in both groups. Based on the good results in rats, we performed vasovasostomy using the 3D-DIM on an obstructive azoospermia patient with a history of bilateral vasectomy; the semen analysis showed that the sperm concentration was $63.0 \times 10^6 \text{ ml}^{-1}$, and the progressive sperm rate was 2.0% in 6 weeks postoperatively.¹⁴

The Vasovasostomy Study Group reported that the most extensive series of outcomes with microsurgical VV and patency

rates of 99.5% had been reported for microsurgical VV in humans.¹⁵ In regard to VE, patency rates of 52.0%–92.0% with a pregnancy rate of 11.0%–56.0% can be expected in humans.¹⁶ The postoperative results depend on the surgeon's skill and technique, optimal vision, and ergonomics. However, it is known that the operating microscope has some drawbacks: surgeons often have to maintain positions for hours that increase fatigue, and the operating microscope sometimes occupies an ample space and has limited maneuverability. As assessed with SOM, the 3D-DIM results in a significant benefit in regard to the surgeon's body mechanics because it can decrease eye discomfort and neck/back pain due to freedom from eye lens use, but it does not increase dizziness (Table 2). Therefore, the use of 3D microscopy can significantly reduce the fatigue of surgeons during surgery.

Regarding the equipment characteristics of the operating microscope, the 3D-DIM group had lower scores for clarity. We used a 2K 3D microscope, so the image was not as sharp due to the poor resolution. With the development of technology, 4K technology would be applied to 3D microscopy, and the resolution of monitoring would be better. However, the 3D-DIM showed higher scores for flexibility and adaptivity of the microscope, which allows the surgeon to operate in a natural and comfortable ergonomic position during the entire procedure and to rapidly and easily manipulate the microscope between microscopic and macroscopic vision without losing microscopic vision.

The current study also presents certain limitations, which might bias the assessment of the safety and effectiveness of the 3D-DIM system. First, the number of rats included in the current study was small. The recently launched 3D-DIM system was lent to the Department of Urology, Shanghai General Hospital, for 2 months. Second, in the present study, anastomotic patency was assessed mechanically immediately postoperatively but not functionally several weeks postoperatively. Third, we could not inspect the anastomotic sites for the presence of adhesions, scarring, or sperm granulomas, only for the presence or absence of leakage. Moreover, some bias might be induced by the user-friendly microscope score.

Moreover, before the animal study, the main surgeon and all the assistants underwent basic microsurgical training and preliminary animal operations. The chief surgeon had more than 20 h of experience working with the 3D-DIM system and had performed more than 100 cases of anastomosis using SOM in rats. Even after this practice, some surgeons still felt very uncomfortable during their first surgery. As a certain degree of adaptation is required to be used to look at a screen for surgeons,^{4,10} we recommend training in the laboratory before clinical use.

CONCLUSION

In summary, based on our randomized prospective study in a rat model, we believe that the 3D-DIM system can significantly improve

surgeon comfort without compromising outcomes in male infertility reconstructive microsurgery. Furthermore, the ergonomic design and equipment characteristics of the 3D-DIM system will promote its widespread use in the field of male infertility in the future. However, the resolution of the 3D-DIM system should be improved, and surgeons should be well trained to use this system in the laboratory before clinical use.

AUTHOR CONTRIBUTIONS

PL and NCL drafted the manuscript. PL, ELZ, ZLZ, ZYY, QML, WBH, HR, and JCJ performed the surgeries. PL performed the surgeries. NCL, ELZ, ZLZ, ZYY, QML, WBH, HR, and JCJ were assistants. CCY, ZYJ, SWG, YHH, and RHT participated in its design and helped draft the manuscript. ZL conceived of the study, participated in its design and coordination, and helped draft the manuscript. All authors read and approved the final manuscript.

COMPETING INTERESTS

All authors declared no competing interests.

ACKNOWLEDGMENTS

This work was supported by grants from the National Nature Science Foundation of China (81701524, 81871215), the Strategic Priority Research Program of the Chinese Academy of Sciences (XDA16020701), and the National Key R&D Program of China (2017YFC1002003).

Supplementary Information is linked to the online version of the paper on the *Asian Journal of Andrology* website.

REFERENCES

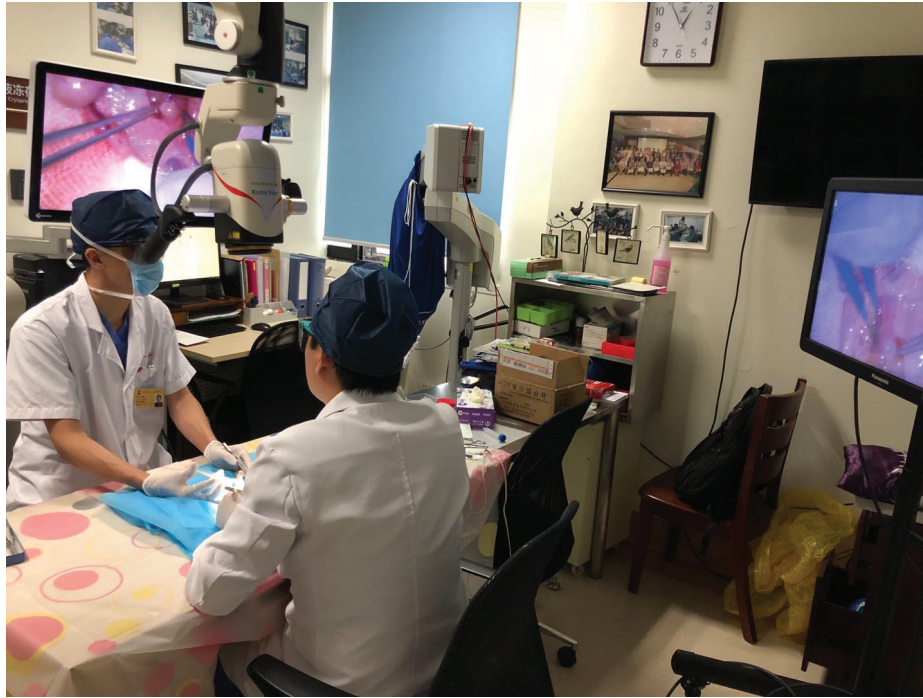- Meng MV, Greene KL, Turek PJ. Surgery or assisted reproduction? A decision analysis of treatment costs in male infertility. *J Urol* 2005; 174: 1926–31.
- Etafy M, Gudeloglu A, Brahmhatt JV, Parekattil SJ. Review of the role of robotic surgery in male infertility. *Arab J Urol* 2018; 16: 148–56.
- Shirzadi A, Mukherjee D, Drazin DG, Paff M, Perri B, *et al*. Use of the video telescope operating monitor (VITOM) as an alternative to the operating microscope in spine surgery. *Spine (Phila Pa 1976)* 2012; 37: E1517–23.

- Rossini Z, Cardia A, Milani D, Lasio GB, Fornari M, *et al*. VITOM 3D: preliminary experience in cranial surgery. *World Neurosurg* 2017; 107: 663–8.
- Oertel JM, Burkhardt BW. Vitom-3D for exoscopic neurosurgery: initial experience in cranial and spinal procedures. *World Neurosurg* 2017; 105: 153–62.
- Monoski MA, Schiff J, Li PS, Chan PT, Goldstein M. Innovative single-armed suture technique for microsurgical vasoepididymostomy. *Urology* 2007; 69: 800–4.
- Goldstein M, Li P, Matthews GJ. Microsurgical vasovasostomy: the microdot technique of precision suture placement. *J Urol* 1998; 159: 188–90.
- Zhao L, Deng CH, Sun XZ, Chen Y, Wang WW, *et al*. A modified single-armed technique for microsurgical vasoepididymostomy. *Asian J Androl* 2013; 15: 79–82.
- Smith S, Kozin ED, Kanumuri VV, Barber SR, Backous D, *et al*. Initial experience with 3-dimensional exoscope-assisted transmastoid and lateral skull base surgery. *Otolaryngology Head Neck Surg* 2019; 160: 364–7.
- Muhammad S, Lehecka M, Niemela M. Preliminary experience with a digital robotic exoscope in cranial and spinal surgery: a review of the Synaptive Modus V system. *Acta Neurochir (Wien)* 2019; 161: 2175–80.
- Schiff J, Li PS, Goldstein M. Robotic microsurgical vasovasostomy and vasoepididymostomy: a prospective randomized study in a rat model. *J Urol* 2004; 171: 1720–5.
- Chan P, Parekattil SJ, Goldstein M, Lipshultz LI, Kavoussi P, *et al*. Pros and cons of robotic microsurgery as an appropriate approach to male reproductive surgery for vasectomy reversal and varicocele repair. *Fertil Steril* 2018; 110: 816–23.
- Mehta A, Li PS, Goldstein M. Male infertility microsurgical training. *Transl Androl Urol* 2014; 3: 134–41.
- Li P, Zhi EL, Yao CC, Xia SJ, Li Z. A novel approach: successful management of vasectomy reversal with a 3D digital image microscope system. *Asian J Androl* 2021; 23: 118–9.
- Belker AM, Thomas AJ, Fuchs EF, Konnak JW, Sharlip ID. Results of 1,469 microsurgical vasectomy reversals by the Vasovasostomy Study Group. *J Urol* 1991; 145: 505–11.
- Chan PT. The evolution and refinement of vasoepididymostomy techniques. *Asian J Andro* 2013; 15: 49–55.

This is an open access journal, and articles are distributed under the terms of the Creative Commons Attribution-NonCommercial-ShareAlike 4.0 License, which allows others to remix, tweak, and build upon the work non-commercially, as long as appropriate credit is given and the new creations are licensed under the identical terms.

©The Author(s)(2021)





Supplementary Figure 1: Lab setup with the 3D-DIM. The telescope, which is attached to its holding arm and comes from the assistant's right side, is held over the surgical field. The assistant sits on the opposite side of the surgeon. The surgeon controls the microscope with the use of a foot pedal. One video monitor is positioned on the surgeon's side, and another is positioned on the assistant's side. 3D-DIM: three-dimensional digital image microscope system.

Supplementary Table 1: User-friendly microscope score

Think about your experience with the surgery you participated in just now. For each item, please circle the number that describes how true the sentence is about your experience

1. My eyes felt very comfortable without soreness
 1. Not true
 2. A little true
 3. Somewhat true
 4. Mostly true
 5. Really true
 2. My neck/back didn't feel any pain
 1. Not true
 2. A little true
 3. Somewhat true
 4. Mostly true
 5. Really true
 3. No dizziness came over me during or after the surgery
 1. Not true
 2. A little true
 3. Somewhat true
 4. Mostly true
 5. Really true
 4. I can get a very clear vision
 1. Not true
 2. A little true
 3. Somewhat true
 4. Mostly true
 5. Really true
 5. The microscope is easy and flexible to operate with
 1. Not true
 2. A little true
 3. Somewhat true
 4. Mostly true
 5. Really true
 6. I can easily adapt with the microscope during the surgery
 1. Not true
 2. A little true
 3. Somewhat true
 4. Mostly true
 5. Really true
-