



## A case of simultaneous bilateral reverse shoulder arthroplasty for bilateral comminuted proximal humerus fractures in an elderly patient

Yuki Iijima, MD<sup>a,\*</sup>, Hideyuki Sasanuma, MD<sup>b</sup>, Tomohiro Saito, MD<sup>a</sup>, Sueo Nakama, MD<sup>b</sup>, Katsushi Takeshita, MD<sup>a</sup>

<sup>a</sup>Jichi Medical University, Department of Orthopaedic Surgery, Shimotsuke, Tochigi, Japan

<sup>b</sup>Tochigi Medical Center Shimotsuga, Department of Orthopaedic Surgery, Ohira, Tochigi, Japan

### ARTICLE INFO

#### Keywords:

Bilateral reverse shoulder arthroplasty  
Comminuted proximal humerus fractures  
Osteoporotic fracture  
Elderly people  
4-part fracture  
Simultaneous surgery

Proximal humeral fracture (PHF) is a common osteoporotic fracture in the elderly population, with a reported frequency of 82 per 100,000 people per year.<sup>10</sup> However, comminuted PHF (CPHF) is less common, accounting for only 3% of all PHF.<sup>3</sup> The treatment for CPHF depends on the patient's age, sex, fracture type, and activity level. Although treatment for PHF can be treated conservatively, CPHF may be treated with surgery to achieve pain relief and functional improvement.<sup>14,16</sup> Operative methods performed for PHF in elderly patients include open reduction and internal fixation (ORIF), hemiarthroplasty, and reverse shoulder arthroplasty (RSA). In recent years, better results have been achieved with RSA than with conservative therapy, ORIF, or hemiarthroplasty.<sup>4,6,11</sup>

RSA performed for bilateral CPHF is very rare. In this report, we present the case of an 82-year-old woman who underwent simultaneous bilateral RSA for CPHF with 4-year clinical follow-up.

### Case report

An 82-year-old woman (body mass index, 28.2 kg/m<sup>2</sup>) with a history of hypertension came to the emergency department with pain and functional impairment in her bilateral shoulders after slipping and falling on her outstretched arms in her room. Before

the injury, she had been independent in her daily living without shoulder pain. Initial examination revealed no neurological or vascular deficits; mobility of the hands and fingers was normal with no sensory loss. Plain radiographs and computed tomography (CT) with 3D reconstruction of the shoulders showed bilateral CPHF (4-part fracture according to Neer's classification,<sup>15</sup> fracture type C2 according to the AO classification<sup>13</sup>; Figs. 1 and 2).

We selected simultaneous bilateral RSA for this case, considering the patient's age, fracture type, bone fragility, and general condition without major comorbidities. The patient's preoperative hemoglobin level was 12.8 g/dl, so she did not receive a preoperative blood transfusion.

Five days after the injury, we performed bilateral RSA. A hybrid RSA system was used: a stem (Trabecular Metal Reverse Stem; Zimmer Biomet, Warsaw, IN, USA) was used as the humeral component, and a lateralized glenosphere (Comprehensive Reverse Shoulder Glenoid Baseplate; Zimmer Biomet) was used as the glenoid component. Under general anesthesia, surgery was started on the right shoulder via a deltopectoral approach with the patient in the beach-chair position. Before incision, 600 mg of tranexamic acid (TXA) was administered intravenously to reduce intraoperative bleeding. Two surgeons (first author and second author) together performed surgery on each shoulder in turn. In surgery, the supraspinatus tendon was temporarily detached from the greater tuberosity (GT). The fracture was exposed, and the humeral head was removed. After the glenoid was exposed, we set a 25-mm-diameter baseplate at an inferior tilt of 10 degrees. A glenosphere with a diameter of 36 mm was used. After 4 high-strength sutures were passed through holes created in the diaphyseal

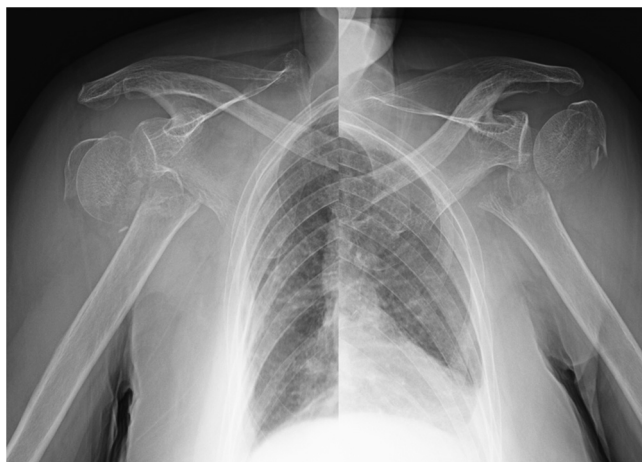No institutional review board approval was required for this case report. Verbal and written consent was obtained from the patient in order to publish information pertaining to this case.

\* Corresponding author: Yuki Iijima, MD, Jichi Medical University, Department of Orthopaedic Surgery, 3311-1 Yakushiji, Shimotsuke, Tochigi 3292740822, Japan.

E-mail address: [y-jima@omiya.jichi.ac.jp](mailto:y-jima@omiya.jichi.ac.jp) (Y. Iijima).

<https://doi.org/10.1016/j.jseint.2021.03.003>

2666-6383/© 2021 The Authors. Published by Elsevier Inc. on behalf of American Shoulder and Elbow Surgeons. This is an open access article under the CC BY-NC-ND license (<http://creativecommons.org/licenses/by-nc-nd/4.0/>).



**Figure 1** X-ray image of bilateral comminuted proximal humeral fractures (4-part according to Neer's classification).

region of the bone, the stem was fixed to the shaft with cement (Cobalt Bone Cement; Zimmer Biomet) at a retroversion angle of 20 degrees. After stem repositioning, cancellous bone gathered from the humeral head was grafted to the proximal part of the stem. The GT was repaired by suturing between the tuberosities and between each tuberosity and the diaphyseal region with No. 2 high-strength suture material. The cut end of the supraspinatus tendon was sutured to the infraspinatus tendon. A drain was inserted before closing the wound. RSA was subsequently performed in the left shoulder in the same way. The total operation time was 5 hours, 16 minutes and total blood loss was 365 ml. The patient did not need intraoperative or postoperative blood transfusion. She did not have any perioperative complications.

The patient underwent postoperative rehabilitation. The bilateral arms were kept in slings for 4 weeks. One week after surgery, passive range of motion exercises were started, and pendulum and self-assisted circumduction exercises were encouraged. After 4 weeks, self-assisted active exercises were started. Isotonic strengthening exercises with an elastic band were started 8 weeks postoperatively. Three months after surgery, the patient was allowed to gradually return to activities of daily living.

Clinical and radiographic outcomes were followed at our hospital. The postoperative course was stable. At 4 weeks after surgery, the patient was able to eat meals without help and could perform active anterior elevation to 90 degrees bilaterally, abduction to 45 degrees on the right side and 30 degrees on the left, and internal rotation to sacrum level bilaterally (Fig. 3). Internal rotation was measured by assessing how far up the spine the patient could reach with the thumbs.

Four years after surgery, the patient's American Shoulder and Elbow Surgeons shoulder score was 76.6 and her pain score on the numeric rating scale was 0 points in both shoulders. She could perform anterior elevation to 120 degrees bilaterally, external rotation at the sides to 15 degrees on the right side and 10 degrees on the left, and internal rotation to L5 bilaterally (Fig. 4).

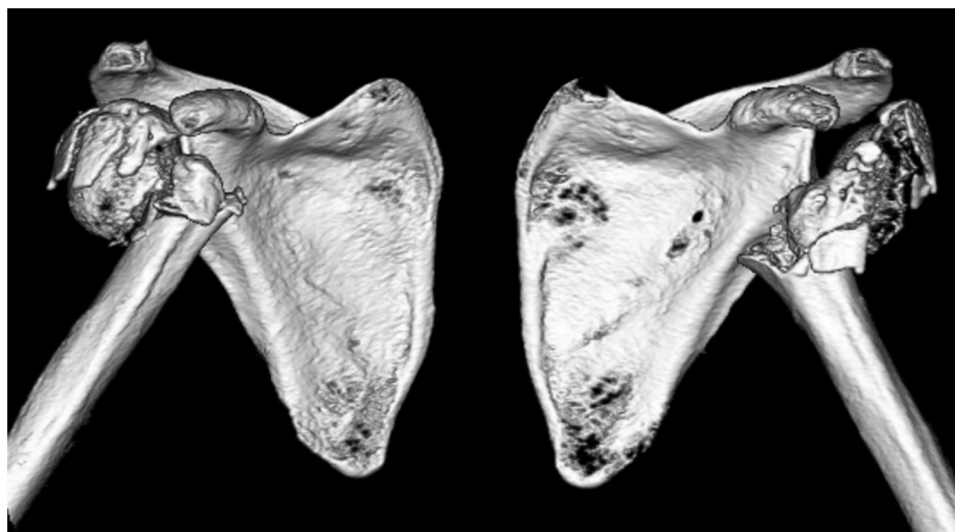
Radiographs taken at 4-year follow-up showed no radiolucent lines or scapular notching; the GT was visible without reabsorption bilaterally (Fig. 5).

## Discussion

Although the frequency of PHF is increasing with the aging society, simultaneous bilateral PHF is very rare, accounting for only 1% of all humeral fractures.<sup>2</sup> PHF can be treated conservatively; however, in some cases surgery is selected. Surgical procedures include percutaneous Kirshner wiring, tension-band wiring, screw fixation, plate fixation, intramedullary nail fixation, hemiarthroplasty, and RSA. RSA has become a common treatment for CPHF in elderly patients.<sup>4,6,11</sup>

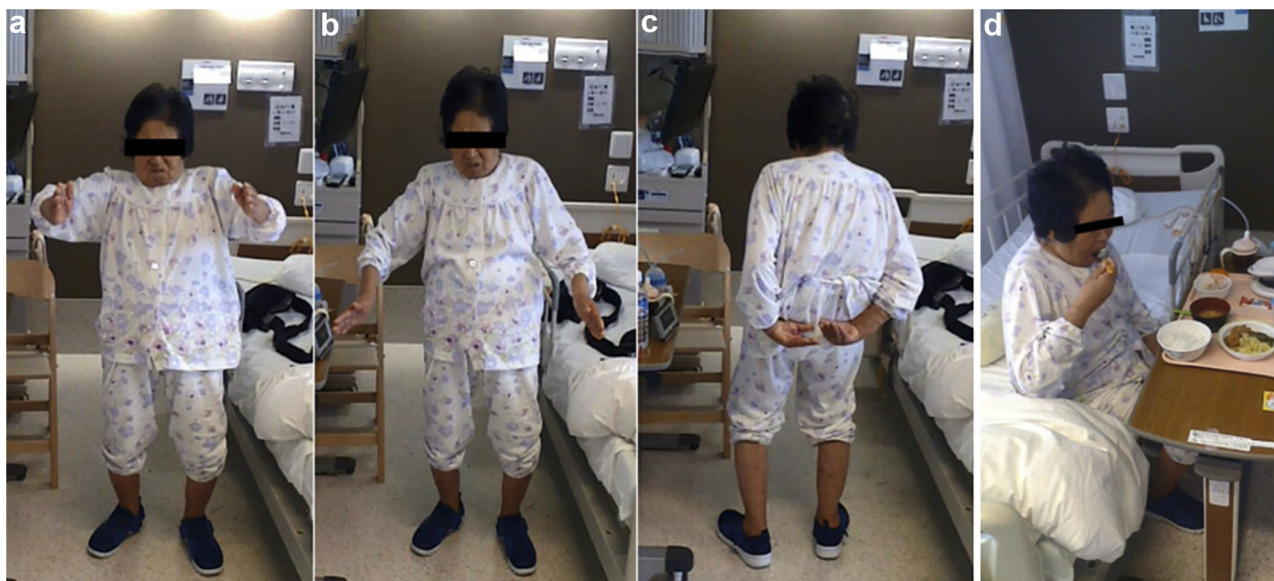There are very few reports of treatment of bilateral PHF. Rodrigues-Corley et al reported one case of conservative treatment for bilateral displaced PHF in an elderly woman, and the outcome was satisfactory.<sup>17</sup> Ellanti et al described the case of a 56-year-old woman who underwent ORIF with threaded pins and tension-band wiring in her right shoulder and hemiarthroplasty in her left shoulder. Two years after surgery, that patient was satisfied with her shoulders.<sup>5</sup> Jaiswal et al and Maalouly et al reported cases of plate fixation for bilateral CPHF.<sup>9,12</sup> These patients also had good outcomes.

There is only one reported case of simultaneous bilateral RSA for CPHF. Ceri et al reported good clinical and radiographic results at 1-year follow-up.<sup>2</sup> Our case was followed for 4 years after surgery, and the medium-term results were satisfactory.

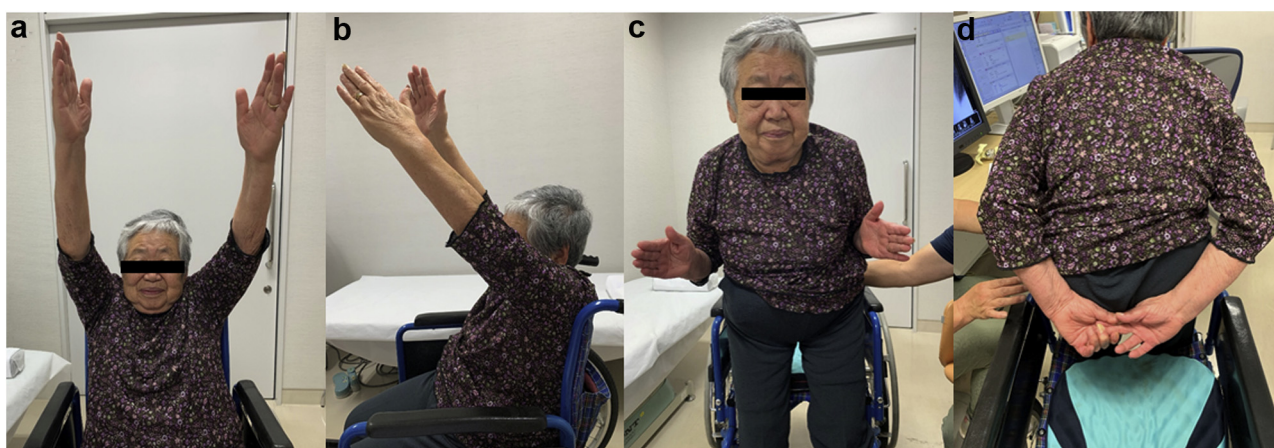

**Figure 2** Three-dimensional computed tomography reconstruction of bilateral comminuted proximal humeral fractures (4-part according to Neer's classification).

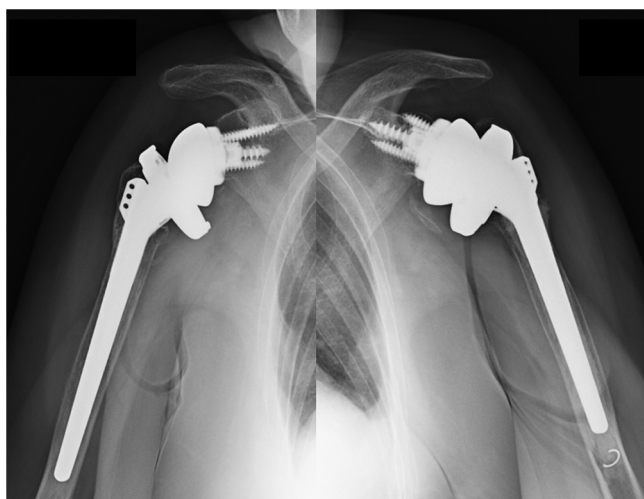




**Figure 3** Four weeks after surgery. Photographs demonstrate active anterior elevation (a), abduction (b), and internal rotation (c). (d) The patient was able to feed herself.



**Figure 4** Four years after surgery. Photographs demonstrate active anterior elevation (a, b), external rotation at side (c), and internal rotation (d).



**Figure 5** X-ray image taken 4 years after surgery show no radiolucent lines around implant or scapular notching, and the GT is visible without reabsorption bilaterally.

To reduce perioperative bleeding, we used intravenous TXA before surgery. Administration of intravenous TXA is reported to control total blood loss in RSA.<sup>1,19</sup> Fortunately, our patient avoided perioperative and postoperative blood transfusion. Another crucial consideration when performing RSA is the importance of GT bone union, which affects clinical outcomes in elderly patients with CPHF.<sup>7,8</sup> We repaired the GT by placing strong sutures between the tuberosities and between each tuberosity and the diaphyseal region after grafting cancellous bone around the proximal stem, which was coated with trabecular metal.<sup>18</sup> Four years after surgery, GT bone was not resorbed on X-rays of the bilateral shoulders.

Simultaneous bilateral RSA may be beneficial treatment for bilateral CPHF in elderly patients. However, long-term follow-up is necessary in this case.

**Conclusion**

In this report, we presented a case of simultaneous bilateral RSA. The medium-term results were good. In select cases, RSA is a strategy for treating bilateral CPHF in elderly patients.

## Acknowledgments

The authors thank Rebecca Tollefson, DVM, from Edanz Group (<https://en-author-services.edanz.com/ac>) for editing a draft of this manuscript.

## Disclaimers:

**Funding:** No funding was disclosed by the author(s).

**Conflicts of interest:** The authors, their immediate family, and any research foundation with which they are affiliated have not received any financial payments or other benefits from any commercial entity related to the subject of this article.

## References

- Abildgaard JT, McLemore R, Hatstrup SJ. Tranexamic acid decreases blood loss in total shoulder arthroplasty and reverse total shoulder arthroplasty. *J Shoulder Elbow Surg* 2016;25:1643-8. <https://doi.org/10.1016/j.jse.2016.02.002>.
- Ceri L, Mondanelli N, Sangaletti R, Bottai V, Muratori F, Giannotti S. Simultaneous bilateral reverse shoulder arthroplasty for bilateral four-part fracture of the proximal humerus in an elderly patient: A case report. *Trauma Case Rep* 2019;19:100242. <https://doi.org/10.1016/j.tcr.2019.100242>.
- Court-Brown CM, Garg A, McQueen MM. The epidemiology of proximal humeral fractures. *Acta Orthop Scand* 2001;72:365-71.
- Cuff DJ, Pupello DR. Comparison of hemiarthroplasty and reverse shoulder arthroplasty for the treatment of proximal humeral fractures in elderly patients. *J Bone Joint Surg Am* 2013;95:2050e5. <https://doi.org/10.2106/JBJS.L.01637>.
- Ellanti P, Harrington P. Functional outcome after simultaneous bilateral four-part proximal humerus fracture: a comparison of ORIF and hemiarthroplasty in an individual patient. *Case Rep Orthop* 2012;2012:941829. <https://doi.org/10.1155/2012/941829>.
- Fraser AN, Bjørndal J, Wagle TM, Karlberg AC1, Lien OA, Eilertsen L, et al. Reverse shoulder arthroplasty is superior to plate fixation at 2 years for displaced proximal humeral fractures in the elderly: a multicenter randomized controlled trial. *J Bone Joint Surg Am* 2020;102:477e85. <https://doi.org/10.2106/JBJS.19.01071>.
- Grubhofer F, Wieser K, Meyer DC, Catanzaro S, Beeler S, Riede U, et al. Reverse total shoulder arthroplasty for acute head-splitting, 3- and 4-part fractures of the proximal humerus in the elderly. *J Shoulder Elbow Surg* 2016;25:1690.e8. <https://doi.org/10.1016/j.jse.2016.02.024>.
- Jain NP, Mannan SS, Dharmarajan R, Rangan A. Tuberosity healing after reverse shoulder arthroplasty for complex proximal humeral fractures in elderly patients—does it improve outcomes? A systematic review and meta-analysis. *J Shoulder Elbow Surg* 2019;28:e78e91. <https://doi.org/10.1016/j.jse.2018.09.006>.
- Jaiswal A, Kachchhap ND, Chatterjee R, Tanwar YS, Habib M, Singh SP. Bilateral traumatic proximal humerus fractures managed by open reduction and internal fixation with locked plates. *Chin J Traumatol* 2013;16:379-81.
- Launonen AP, Lepola V, Saranko A, Flinkkilä T, Laitinen M, Mattila VM. Epidemiology of proximal humerus fractures. *Arch Osteoporos* 2015;10:209. <https://doi.org/10.1007/s11657-015-0209-4>.
- Lopiz Y, Alcobía-Díaz B, Galan-Olleros M, García-Fernández C, Picado AL, Marco F. Reverse shoulder arthroplasty versus nonoperative treatment for 3- or 4-part proximal humeral fractures in elderly patients: a prospective randomized controlled trial. *J Shoulder Elbow Surg* 2019;28:2259e71. <https://doi.org/10.1016/j.jse.2019.06.024>.
- Maalouly J, Aouad D, Dib N, Tawk A, Rassi GE. Simultaneous ORIF for bilateral comminuted proximal humerus fractures: Case report in an elderly patient. *Int J Surg Case Rep* 2019;65:193-6. <https://doi.org/10.1016/j.ijscr.2019.10.061>.
- Marsh JL, Slongro TF, Agel J, Broderick JS, Creevey W, DeCoster TA, et al. Fracture and dislocation classification compendium - 2007: Orthopaedic Trauma Association classification, database and outcomes committee. *J Orthop Trauma* 2007;21:S1-133. <https://doi.org/10.1097/00005131-200711101-00001>.
- Murray IR, Amin AK, White TO, Robinson CM. Proximal humeral fractures: current concepts in classification, treatment and outcomes. *J Bone Joint Surg Br* 2011;93:e11. <https://doi.org/10.1302/0301-620X.93B1.25702>.
- Neer CS. Displaced proximal humeral fractures. I. Classification and evaluation. *J Bone Joint Surg Am* 1970;52:1077e89.
- Neuhaus V, Bot AG, Swellengrebel CH, Jain NB, Warner JJ, Ring DC. Treatment choice affects inpatient adverse events and mortality in older aged inpatients with an isolated fracture of the proximal humerus. *J Shoulder Elbow Surg* 2014;23:800e6. <https://doi.org/10.1016/j.jse.2013.09.006>.
- Rodriguez-Corlay RE, Velutini-Becker R, Aguilar-Alcalá LD. Conservative treatment for bilateral displaced proximal humerus head fracture. *Cureus* 2016;8:6. <https://doi.org/10.7759/cureus.657>.
- Sasanuma H, Iijima Y, Saito T, Kanaya Y, Yano Y, Fukushima T, et al. Clinical results of reverse shoulder arthroplasty for comminuted proximal humerus fractures in elderly patients: a comparison between nonporous stems versus trabecular metal stems. *J Shoulder Elbow Surg Int* 2020;4:952-8. <https://doi.org/10.1016/j.jseint.2020.08.010>.
- Vara AD, Koueiter DM, Pinkas DE, Gowda A, Wiater BP, Wiater JM. Intravenous tranexamic acid reduces total blood loss in reverse total shoulder arthroplasty: a prospective, double-blinded, randomized, controlled trial. *J Shoulder Elbow Surg* 2017;26:1383-9. <https://doi.org/10.1016/j.jse.2017.01.005>.