

Neovascular glaucoma - A review

Sirisha Senthil, Tanuj Dada¹, Taraprasad Das², Sushmita Kaushik³, George Varghese Puthuran⁴, Reni Philip⁵, Padmaja Kumari Rani², Harsha Rao⁶, Shaveta Singla, Lingam Vijaya⁵

Neovascular glaucoma (NVG) is a sight-threatening secondary glaucoma characterized by appearance of new vessels over the iris and proliferation of fibrovascular tissue in the anterior chamber angle. Retinal ischemia is the common driving factor and common causes are central retinal vein occlusion, proliferative diabetic retinopathy, and ocular ischemic syndrome. The current rise in the prevalence of NVG is partly related to increase in people with diabetes. A high index of suspicion and a thorough anterior segment evaluation to identify the early new vessels on the iris surface or angle are essential for early diagnosis of NVG. With newer imaging modalities such as the optical coherence tomography angiography and newer treatment options such as the anti-vascular endothelial growth factor, it is possible to detect retinal ischemia early, tailor appropriate treatment, monitor disease progression, and treatment response. The management strategies are aimed at reducing the posterior segment ischemia, reduce the neovascular drive, and control the elevated intraocular pressure. This review summarizes the causes, pathogenesis, and differential diagnoses of NVG, and the management guidelines. We also propose a treatment algorithm of neovascular glaucoma.

Key words: Neovascular glaucoma, secondary glaucoma, retinal ischemia

Neovascular glaucoma (NVG) is a potentially blinding secondary glaucoma, characterized by the development of rubeosis iridis and elevated intraocular pressure (IOP). Coats described rubeosis iridis in 1906 in a patient with central retinal vein occlusion (CRVO).^[1] It has been referred to as hemorrhagic glaucoma, thrombotic glaucoma, congestive glaucoma, rubeotic glaucoma, and diabetic hemorrhagic glaucoma.^[2] Weiss *et al.*^[3] proposed the term NVG as the elevated IOP was shown related to the new vessels' formation and associated connective tissue growth. NVG is a secondary ocular disorder resulting from a variety of ocular pathologies, and nearly in all cases, retinal ischemia is the underlying mechanism. The prevalence of NVG in the population is low, 0.12% in migrant Indians in Singapore^[4] and 0.01% in the Hooghly River Study (West Bengal, India).^[5] In hospital-based studies, the proportion of eyes with NVG among the secondary glaucomas was 9–17.4%.^[6,7] Though the overall prevalence of NVG is low, it contributes to significant visual loss and morbidity.

This review includes a comprehensive overview of the etiology, pathology, diagnosis, and management of eyes with NVG.

VST Glaucoma Center, L V Prasad Eye Institute, Banjara Hills, ²Srimathi Kanuri Santhamma Centre for Vitreoretinal Diseases, L V Prasad Eye Institute, Hyderabad, Telangana, ¹Dr. Rajendra Prasad Center for Ophthalmic Sciences, All India Institute of Medical Sciences, New Delhi, ⁶Narayana Nethralaya, Bangalore, Karnataka, ³Advanced Eye Centre, Post Graduate Institute of Medical Education and Research, Chandigarh, ⁴Aravind Eye Hospital, Madurai, ⁵Smt Jadhavabai Nathmal Singhvee Glaucoma Services, Sankara Nethralaya, Chennai, Tamil Nadu, India

Address for correspondence: Dr. Sirisha Senthil, L.V Prasad Eye Institute, Kallam Anji Reddy Campus, L V Prasad Marg, Road No. 2, Banjara Hills, Hyderabad - 500 034, Telangana, India. E-mail: sirishasenthil@lvpei.org

Received: 20-May-2020

Revision: 09-Jul-2020

Accepted: 08-Aug-2020

Published: 17-Feb-2021

Access this article online

Website:

www.ijo.in

DOI:

10.4103/ijo.IJO_1591_20

Quick Response Code:



Etiology

A large number of ocular and systemic disorders could cause NVG [Table 1].^[8-16] But three quarters of times it is caused by three conditions—diabetic retinopathy (DR) (33%), ischemic CRVO (33%), and the ocular ischemic syndrome (OIS) (13%).^[6]

NVG is a complication mostly of ischemic CRVO. Up to 60% of patients with ischemic CRVO develop anterior-segment neovascularization (NV) within a few weeks to 2 years after disease onset, with an estimated incidence of 3,800 new cases per year.^[7] Eyes with nonischemic CRVO usually do not develop NV or NVG unless there is associated DR or OIS. Usually, eyes with larger areas of capillary nonperfusion (CNP), 30–75 disc areas, are at risk of developing NVG.^[17,18] Identifying ischemic CRVO is crucial for proper management. Hayreh had proposed two broad categories of tests to differentiate ischemic from nonischemic CRVO; these include both “Functional” tests (vision, visual field on a Goldmann perimeter, relative afferent pupillary defect, and electroretinography), and “Morphological” tests (ophthalmoscopy and fluorescein angiography [FA]).^[8]

NVG is an advanced manifestation of DR. The incidence of new vessels of the iris (NVI) among people with diabetes ranges from 1% to 17%,^[19,20] occurring most often in proliferative diabetic retinopathy (PDR).^[21] The incidence of NVI in PDR was reported as high as 65% with a 33% risk of contralateral eye developing NVG in people with diabetes with NVG in one eye.^[22] NVG in DR is related to the degree of retinal ischemia.

This is an open access journal, and articles are distributed under the terms of the Creative Commons Attribution-NonCommercial-ShareAlike 4.0 License, which allows others to remix, tweak, and build upon the work non-commercially, as long as appropriate credit is given and the new creations are licensed under the identical terms.

For reprints contact: WKHLRPMedknow_reprints@wolterskluwer.com

Cite this article as: Senthil S, Dada T, Das T, Kaushik S, Puthuran GV, Philip R, *et al.* Neovascular glaucoma - A review. Indian J Ophthalmol 2021;69:525-34.

Table 1: Ocular and systemic conditions predisposing to Neovascular Glaucoma.^[12-20]**Ischemic**

Central Retinal Vein occlusion
 Diabetic retinopathy
 Carotid insufficiency or Ocular Ischemic syndrome
 Sick cell retinopathy
 Radiation retinopathy
 Central retinal artery occlusion
 Retinopathy of prematurity
 Familial exudative vitreoretinopathy
 Persistent hyperplastic primary Vitreous

Inflammatory

Uveitis
 Trauma
 Eales' disease
 Retinal vasculitis
 Anterior segment ischemia (may be post-surgical)
 Endophthalmitis
 Extraocular Inflammatory vascular causes like Giant Cell Arteritis, temporal arteritis

Retinal detachment

Long standing retinal detachment
 Proliferative vitreoretinopathy
 Coats' disease
 Retinoschisis
 Detachment associated with intraocular tumours

Tumours

Choroidal melanoma
 Iris melanoma
 Retinoblastoma
 Intraocular metastasis
 Ciliary body medulloepithelioma
 Vasoproliferative tumours of the retina
 Hyperviscosity syndromes and myeloproliferative disorders

Systemic diseases

Juvenile myelomonocytic leukemia
 Systemic lupus erythematosus
 Juvenile xanthogranuloma
 Cryoglobulinemia type 1
 Neurofibromatosis type 1
 Extraocular vascular disorders like internal carotid artery obstruction, carotid cavernous fistula

OIS results from global reduction of blood flow to the eyeball. While it could cause both anterior and/or posterior segment ischemia, the former is mostly responsible for development of iris and angle new vessels. Severe carotid artery occlusive disease and DR are usually associated with OIS.^[9]

Pathogenesis

The pathogenesis of NVG is outlined in the flow chart [Fig. 1]. The primary event is a condition leading to retinal hypoxia and ischemia which disrupts the balance between pro- and anti-angiogenic factors and thereby stimulates angiogenesis. Common angiogenic factors are vascular endothelial growth factors (VEGFs), hepatocyte growth factor, insulin-like growth factor, tumor necrosis factor, and inflammatory cytokines (especially IL-6). Common antiangiogenic factors are pigment epithelium-derived factor, transforming growth factor-beta (TGF- β), thrombospondin, and somatostatin.^[23-27] VEGF, produced by a variety of cells in the retina (Muller cells, retinal pigment epithelium, pericytes, and ganglion cells) as well as the nonpigmented ciliary epithelium, is the major inciting factor implicated in the disease process.^[28] VEGF is a

vaso-permeability factor and a strong endothelial cell mitogen. It induces endothelial cell migration by expression of α/β integrins.^[29] In addition to cell migration, VEGF increases the leucocyte adhesion at the endothelium resulting in breakdown of blood-retinal barrier.^[23,24] TGF- β stimulates the formation of the fibrovascular membrane and fibroblast proliferation.^[25] The secondary event is the growth of new leaky vessels in the anterior chamber obstructing the trabecular meshwork. This leads to a rise in IOP and can rapidly progress to glaucomatous optic neuropathy with irreversible blindness, if not managed on time. It is also postulated that oxygen from the aqueous humor diffuses posteriorly to the hypoxic retina, thereby causing iris hypoxia. Consequently, the nonpigmented ciliary epithelium becomes an important site of VEGF synthesis.^[23] This could explain the high risk of rubeosis in cases of NVG after surgeries like vitrectomy and lens extraction, in which the oxygen can easily reach the ischemic retina through diffusion and lead to rapid and severe iris hypoxia.

Histologically, vascular proliferation occurs with endothelial budding at the capillary level from minor and major arterial circle. These endothelial buds progress to glomerulus-like vascular tufts and new vessels that are mainly located near or on the iris surface and are composed of endothelial cells without a muscular layer and with little adventitial tissue [Fig. 2]. They arise from any place in the iris including root of iris and major arterial circle and are mostly located over the surface of the iris but can also be found in the stroma.^[30] The endothelial cells of the new vessels lack tight junctions and have fenestrated walls, which leads to leakage of proteins and cells into the aqueous. The fibrovascular membrane in NVI also contains proliferating myofibroblasts with smooth muscle differentiation. This clinically transparent and contractile membrane causes flattening and effacement of iris surface.^[30,31]

The main reason for visual loss with high IOP in NVG is ischemia of the optic nerve head and/or retina. Perfusion pressure (mean blood pressure – IOP) and ocular blood flow (perfusion pressure/vascular resistance) play important roles in this cascade of events. Blood flow is reduced significantly in an event of high IOP and low blood pressure; this causes greater damage to the optic nerve head and retina. Hence, it is suggested to take care not to lower the systemic arterial blood pressure while lowering the IOP, crucial for treatment of NVG.^[18]

Clinical Features**Symptoms**

NVG typically presents with a chronically red, painful eye that often has significant vision loss. It could be asymptomatic in the early stages,^[10] if IOP rise is gradual and the corneal endothelial count is good, especially in young individuals.

Signs

The first sign of iris NV is leakage of intravenously injected sodium fluorescein from vessels at the pupillary margin. The leakage can be detected even when the iris is apparently normal on slit-lamp examination. The following features are clinically seen:

- Visible neovascularization of the iris (NVI) and neovascularization of angle (NVA). Only rarely will NVA develop without NVI. NVI usually begins at pupillary margin but can also begin at the edges of a YAG iridotomy
- Elevated IOP (often exceeding 50 mmHg) with or without corneal edema
- Gonioscopically, NVA with partial or complete closure of the angle

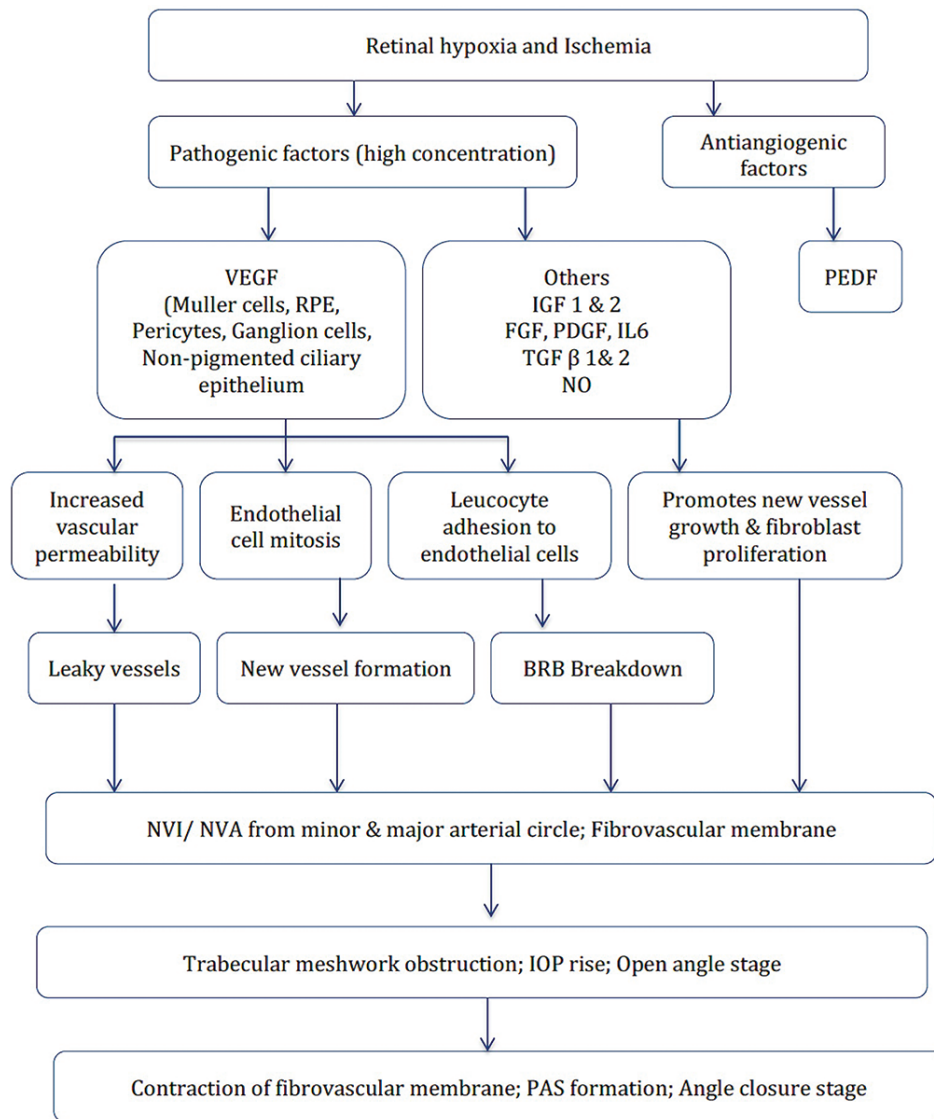


Figure 1: Flow chart highlighting the pathogenesis of neovascular glaucoma

- Fundoscopically, features of ophthalmic disorders, such as DR, retinal vessel occlusion, or OIS.

Two consistent signs are the NVI and NVA. NVI, on slit-lamp examination, presents as thin, tortuous vessels, randomly oriented on the surface of the iris, near the pupillary margin, and is more obvious in light-colored iris. These newly formed blood vessels must be differentiated from the normal radial vessels from the ciliary trunk and the radial iris vessels from the circular ciliary band.^[22] The aberrant normal vessels are radial, often arising from the iris root, and may be visible until mid-periphery and disappear into the iris stroma. At an early stage, the abnormal iris new vessels may be fine or these may appear as small tufts of blood vessels at the pupillary ruff, which can be easily missed unless specifically looked for. Leakage of vessels at pupillary margin after an intravenous injection of 5–10% sodium fluorescein occurs before clinically evident NVI (prerubeotic stage). Sometimes these iris new vessels may be extensive, flat, arborizing, and present all over the iris surface with grooves/tracks typically seen in OIS [Fig. 3]. In advanced cases, there would be ectropion uveae at pupillary margin with attenuation of normal iris pattern due to growth of fibrovascular membrane.

NVA is a gonioscopic finding. They appear as thin vessels crossing the scleral spur, branching, and arborizing over the trabecular meshwork [Fig. 3]. Sometimes these vessels may initially grow in the angle prior to appearance of pupillary margin NV and therefore gonioscopy is essential to recognize this important clinical finding.^[32] They should be differentiated from occasional prominent vessels in the angle which may have a radial orientation or may be looped and visible close to the iris root, which arise from major arterial circle.

The clinical stages of NVG and classification of NVI and NVA are shown in Tables 2 and 3.^[33] NVG can be divided into a prerubeotic stage where new vessels are not clinically visible but may be documented on anterior segment angiography and three clinical stages—the rubeosis iridis, secondary open-angle glaucoma, and secondary angle-closure glaucoma.^[34] Fig. 4 shows the clinical stages of NVG.

Ophthalmic Investigations

Slit-lamp biomicroscopy and gonioscopy are the essential tools to screen for NVI. Gonioscopy is a dynamic examination and is easily performed at the slit lamp but has a learning curve. Very

fine NVI could be missed in both slit-lamp examination and gonioscopy. In these early stages, FA is more useful to detect

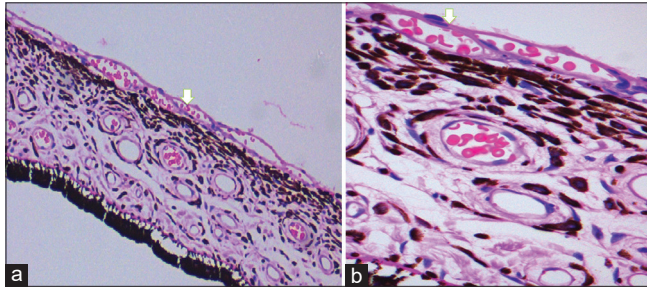


Figure 2: Histopathology shows blood vessel formation on the anterior surface of iris (white arrow) composed of single-layered endothelial cells and the lumen is filled with RBCs. (a) H and E, 10 × and (b) H and E, 40×

rubeosis iridis.^[35-37] Fundus fluorescein angiography (FFA) is the current gold standard to detect areas of CNP and retinal new vessels elsewhere (NVE) or on the disc (NVD). Ultrawide-field FFA helps to visualize a larger retinal area, up to 200°. Iris FA shows leakage from these new vessels. Anterior segment indocyanine green angiography has the advantage of displaying the vasculature in more detail. Dye-based angiography is good but cannot be used in people allergic to these dyes. The most recent technique to assess retinal ischemia and neovascularization is the optical coherence tomography angiography (OCTA).^[38-40] This imaging technique is based on motion contrast.^[41,42] It is noninvasive and can be performed in eyes without dilatation. The OCTA in comparison to FFA can delineate the extent and depth of NV. Also, OCTA can be an excellent follow-up tool to document regression of NV [Fig. 5]. Commercial availability of wide field OCTA imaging has enabled larger area (12 mm × 12 mm) of retinal scanning [Fig. 5]. OCTA has also been used to image the iris vasculature and detect NVI.^[43]

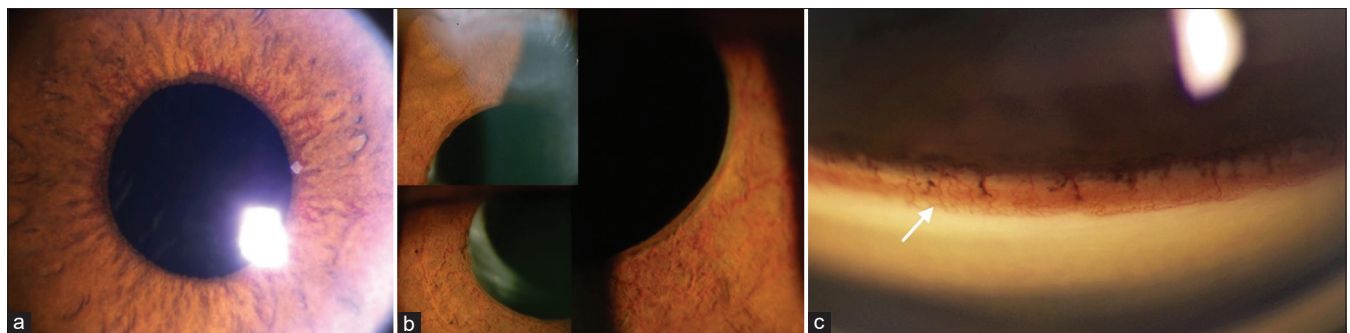


Figure 3: (a) Fine new vessels in the pupillary margin and over the iris surface close to the pupil in an eye with proliferative diabetic retinopathy and neovascular glaucoma; compare this with the (b) extensive new vessels of the iris which are flat, arborizing, and present all over the iris surface with grooves/tracks in the iris, typically seen in ocular ischemic syndrome; (c) gonio-photograph showing aggressive new vessels over the trabecular meshwork (white arrow)

Table 2: The clinical stages of neovascular glaucoma

Stages	Rubeosis iridis	Secondary open-angle glaucoma	Secondary angle-closure glaucoma
Clinical features	Tiny tufts of new vessels appear first at the pupillary margin and less commonly at the angle which cross the SS to arborize over the TM New vessels grow over iris surface in an irregular fashion	Development of a fibrovascular membrane on anterior surface of the iris and angle of anterior chamber, blocks the TM, and obstructs aqueous outflow in an open-angle manner	Contracture of fibrovascular membrane pulls the iris over the TM forming PAS
NVI	Present	Prominent	Prominent with ectropion uveae
Gonioscopy	Open angles, NVA with or without NVI may be present	Open angles, NVA may or may not be visible	Closed angles, NVA usually not visible
IOP	Normal	Raised	Raised
Prognosis	Good	Good with timely intervention	Usually guarded

IOP=Intraocular pressure, NVA=New vessels of the angle, NVI=New vessels of the iris, PAS=Peripheral anterior synechiae, TM=Trabecular meshwork

Table 3: Weiss and Gold classification^[39] of iris and anterior chamber angle neovascularization

	Grade 1	Grade 2	Grade 3	Grade 4
NVI	Iris new vessels at pupillary zone <2 quadrants	Iris new vessels at pupillary zone >2 quadrants	Iris new vessels at ciliary zone and/or ectropion uveae 1-3 quadrants	Surface new vessels at ciliary zone and/or ectropion uveae ≥ 3 quadrants
NVA	Angle vessels cross SS and ramify on TM <2 quadrants	Angle vessels cross SS and ramify on TM >2 quadrants	Angle vessels at TM, and PAS 1-3 quadrants	PAS ≥ 3 quadrants

IOP=Intraocular pressure, NVA=New vessels of the angle, NVI=New vessels of the iris, PAS=Peripheral anterior synechiae, SS=Scleral spur, TM=Trabecular meshwork

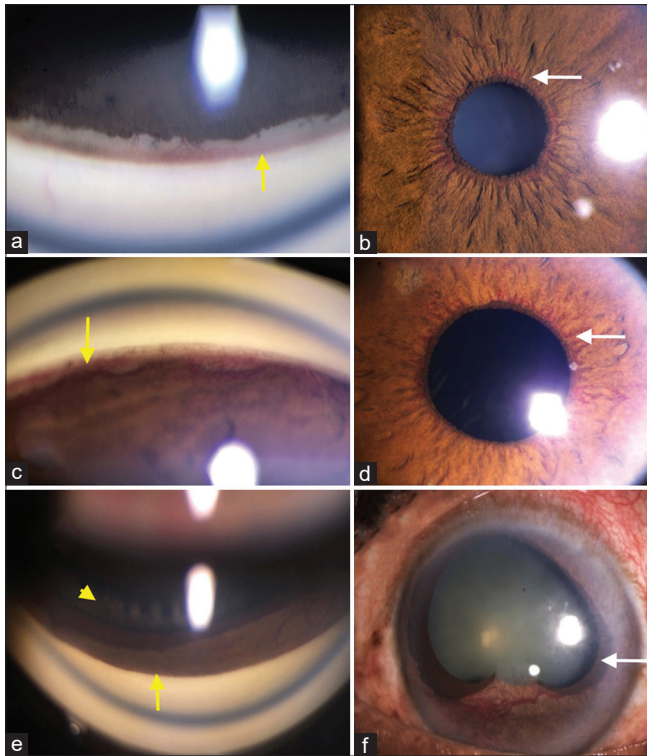


Figure 4: (a and b) Neovascularization at the angle—thin vessels crossing the scleral spur and arborizing over the trabecular meshwork in the superior angle (a). Fine new vessels at pupillary border (b)—stage of rubeosis iridis/NVI. (c and d) Neovascular glaucoma with early PAS formation in the angle (c) and fine vessels visible near pupillary border (d)—stage of secondary open-angle glaucoma. (e and f) Neovascular glaucoma with completely closed angle (yellow arrow) (e) uveal ectropion (white arrow) and iris atrophy with neovascularization of the iris (f)—advanced NVG or stage of secondary angle-closure glaucoma

Many studies have reported the ability of OCTA to detect NV and were comparable to FA. A dye-based angiography is superior to OCTA when one needs to study the dye leakage pattern. The sensitivity and specificity of OCTA vis-à-vis FA and different modalities of OCTA in detecting new vessels have been reported. OCTA was 79% sensitive and 96% specific compared to FA,^[44] wide-field OCTA was 100% sensitive and 97% specific compared to ultrawide field FA,^[45] and wide-field OCTA imaging at baseline and 3 months after panretinal photocoagulation (PRP) was comparable with ultrawide field FA.^[46] OCTA could be useful to monitor the activity of neovascular complexes after panretinal photocoagulation providing better assessment of treatment response and guide additional treatment with retinal laser and/or intravitreal anti-VEGF injections. OCTA could allow a fast and noninvasive screening tool of patients with NVG and patients at risk of NV. However, certain technological issues like motion artifacts, image registration for follow-up imaging, as well as a quantitative and objective evaluation method for retinal and iris NV have to be addressed before it can be recommended for routine clinical practice.

Ultrasonography B scan (USG-B scan) helps to exclude rare and unexplained causes of NVG like the long-standing retinal detachment or intraocular tumors. In young patients with NVG, ultrasound biomicroscopy helps to rule out ciliary body tumors.

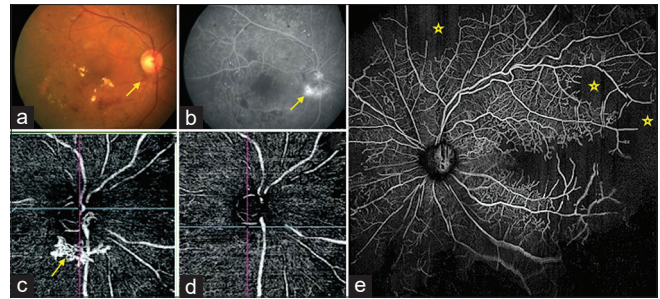


Figure 5: (a) Subtle neovascularization of disc seen on color fundus photo (yellow arrow); (b) FFA showing corresponding leakage in the NVD area (yellow area), (c) OCTA showing the accurate extent and depth of NVD (yellow arrow), (d) follow-up OCTA showing good regression of NVD after panretinal photocoagulation and anti-VEGF injection, (e) wide-angle OCTA clearly depicting capillary non-perfusion areas (depicted by star) in a case of NVG secondary to CRVO

Table 4: Investigations in patients with neovascular glaucoma

Systemic condition	Recommended tests
Hypertension	Blood pressure
Diabetes	Blood sugar and HbA1c
Ocular ischemic syndrome ^[16]	Carotid Doppler (retrobulbar vessels, intra, and extracranial) Magnetic resonance and computed tomographic angiography Carotid intra-arterial digital subtraction angiography (selectively and with extreme caution)
Carotid cavernous fistula/tumor metastasis	CT scan/magnetic resonance imaging/MR venogram/PET scan
Uveitis, retinal vasculitis, blood dyscrasia	HLA B 27 Hemogram+ESR, CRP, ANA, VDRL, serum protein electrophoresis, and immunoelectrophoresis (rules out hyperviscosity syndromes) Ancillary investigations to exclude tuberculosis, sarcoidosis, blood dyscrasias, etc.

ANA=Antinucleotide antibody, ANCA=Antineutrophilic cytoplasmic antibody, CRP=C-reactive protein, CT=Computerized tomogram, ESR=Erythrocyte sedimentation rate, MR=Magnetic resonance, PET=Positron emission tomography, VDRL=Venereal disease research laboratory

Systemic Investigations

The basic checklist of systemic investigations in these patients is shown in Table 4. Certain special tests may not be recommended for all patients.

Differential Diagnosis

The differential diagnosis of NVG takes into consideration various etiologies, which can predispose to NVG, as well as ocular conditions that may have similar clinical presentation [Table 6].^[8-16] It is important to note that the underlying mechanism for various ocular conditions may be multifactorial and concurrent.

Acute angle-closure glaucoma mimics NVG most closely. The patient presents with an acutely painful eye, with

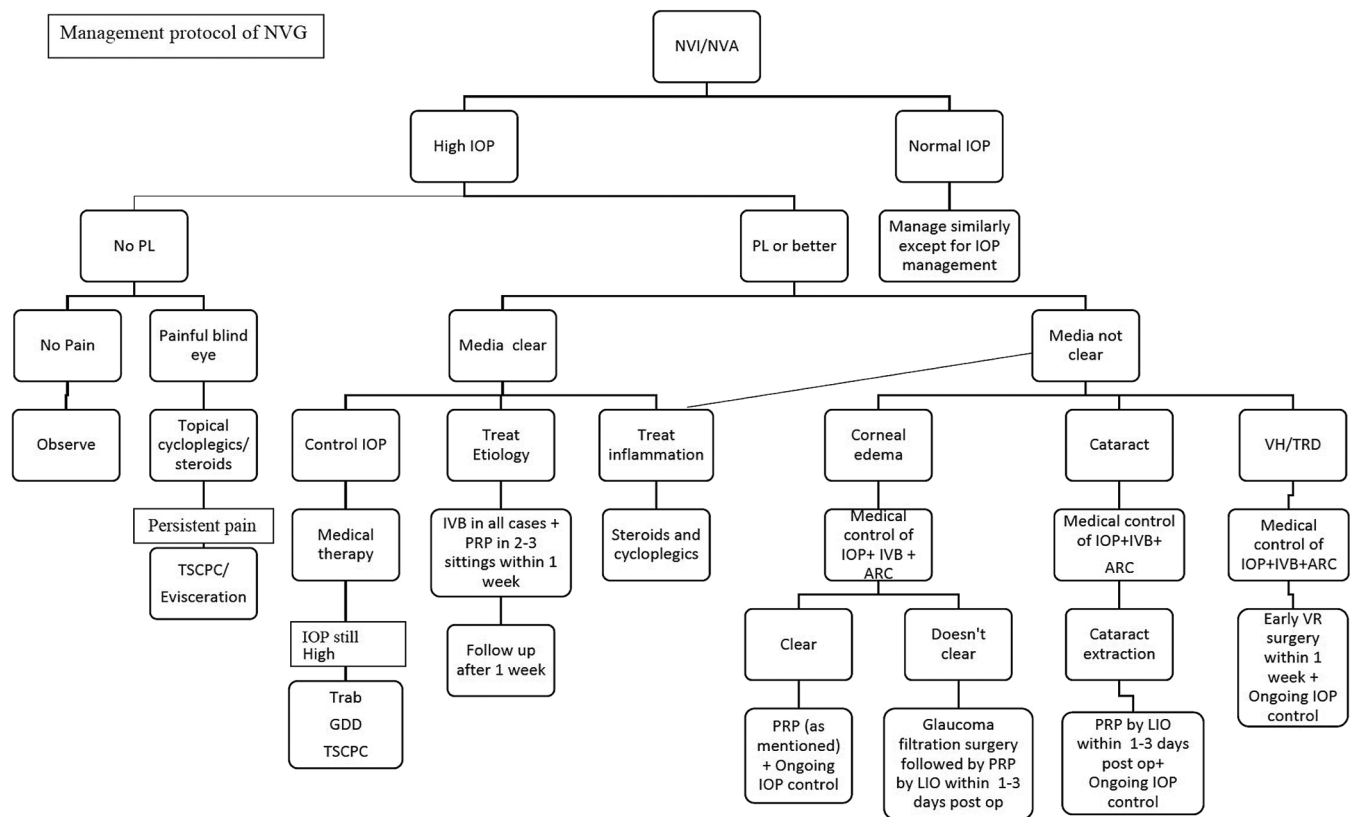


Figure 6: Flow chart showing the recommended treatment protocol of NVG. NVD- Neovascularization of the disc; NVE- Neovascularization elsewhere; IOP- intraocular pressure; NVG- neovascular glaucoma; VEGF- vascular endothelial growth factor; IOP Intraocular pressure; NVA New vessels of the angle;- NVI New vessels of the iris, PL-perception of light, TSCPC-transscleral cyclophotocoagulation, Trab-trabeculectomy, GDD-glaucoma drainage device surgery, PRP: panretinal photocoagulation, IVB-intravitreal anti-vascular endothelial growth factor injection, ARC-anterior retinal cryopexy, VR-vitreoretinal, LIO-laser indirect ophthalmoscopy, VH-vitreous haemorrhage, TRD-tractional retinal detachment

Table 5: Outlines the treatment paradigm^[47-52]

Stage	Description	Ocular features	Treatment			
			PRP	Anti-VEGF	AGM	GFS
I	Preglaucoma	NVI	+	+	-	-
II	Open angle	Elevated IOP, NVA	+	+	+	±
III	Closed angle	Elevated IOP, NVA	+	+	+	+

AGM=Anti-glaucoma medication, GFS=Glaucoma filtration surgery, IOP=Intraocular pressure, NVA=New vessels angle, NVG=Neovascular glaucoma, VEGF=Vascular endothelial growth factor

decreased vision, increased IOP, and dilation of circumciliary blood vessels. In the former, engorged iris vessels may be mistaken for rubeosis iridis, or the assessment of iris vessels may not be possible due to associated corneal edema. The examination of the fellow eye, with occludable or closed angles, is often the only differentiating feature, in eyes where posterior segment assessment is not possible. If the posterior segment can be visualized, the presence (usually measured by FFA) of retinal hypoxia helps in diagnosing NVG.

OIS resulting from carotid artery obstructive disease is the third most common cause of NVG. These patients may have normal or even low IOP despite established NVG. There may be a history of ocular pain, amaurosis fugax, and metamorphopsia.^[9]

Engorged vessels in patients with anterior uveitis, especially after surgery, and/or hypotony, may also be confused with NVG. A therapeutic trial of topical corticosteroids decreases this dilation of vessels, whereas NV of the iris does not regress.

Anterior segment NV along with elevated IOP may also be seen in anterior segment dysgenesis (especially essential iris atrophy), Fuchs’ heterochromic iridocyclitis, and pseudoexfoliation syndrome.

A good clinical examination helps. The prominent iris vessels are radial, lie within the iris stroma, and never traverse the scleral spur. New vessels, on the other hand, are haphazard, superficial, and often cross the scleral spur, causing a zippering of the anterior chamber angle.

Treatment of NVG

Treatment principles^[10]

1. Treatment of retinal ischemia, in order to reduce the stimulus for NV:
 - a. Intravitreal anti-VEGF agents to suppress iris and angle NV

Table 6: Conditions mimicking neovascular glaucoma^[8-16]

Ocular condition	Differentiating features	Ancillary investigations
Uveitis	Engorged iris blood vessels, KP, AC cells	Slit lamp, uveitis workup, blood tests
Acute angle-closure glaucoma	Shallow AC, closed angles, convex iris configuration, no NVI, corneal edema	Slit lamp, gonioscopy, AS-OCT, fundus, fellow eye examination
Chronic angle-closure glaucoma	Shallow AC, closed angles, convex iris configuration, pupillary block, NVI; no NVE/NVD	Slit lamp, gonioscopy, AS-OCT, fundus
Intraocular tumors	Neovascularization of iris and angle ±	Slit lamp, fundus examination, USG B-scan, ancillary imaging for metastasis
Carotid-cavernous fistula	Blood in Schlemm's canal	Gonioscopy, imaging studies of brain
Anterior segment dysgenesis	Corectopia, iris atrophy with prominent blood vessels	Gonioscopy, fundus
Retinal detachment	If longstanding, PVR changes and neovascularization Following surgery, there may be signs of anterior segment ischemia	Slit lamp, fundus, USG B-scan

AC=Anterior chamber, AS OCT=Anterior segment optical coherence tomography, KP=Keratic precipitates, NVD=Neovascularization of the disc, NVE=Neovascularization elsewhere, NVI=Neovascularization of iris, USG=Ultrasonogram

- b. Panretinal photocoagulation
2. Treatment of underlying systemic disease, if any, in order to improve retinal blood flow
3. Control of IOP
4. Control of inflammation

The management protocol is shown in Fig. 6. PRP is the current treatment of choice wherever retinal ischemia is the cause of NVG.^[47-49] The photocoagulation parameters in NVG are 1200–1600 burns, approximately 500 µm spot size and one spot apart. Ideally, it is completed in 1–3 sessions, over a period of 5–7 days. PRP is indicated not only in initial rubeosis but also in late stages of NVG with goniosynechia.^[13] The treatment paradigm is changing with the introduction of anti-VEGF agents.^[50-52] The broad treatment guidelines of glaucoma are shown in Table 5.^[47-52] It is an incremental increase from PRP only in preglaucoma stage to combination of anti-VEGF injections, antiglaucoma medications, and glaucoma filtration surgery based on the disease progression and angle configuration.

When adequate PRP is not possible due to a poor view of the fundus, retinal ablation can be augmented with anterior retinal cryotherapy (ARC). ARC can be combined with intravitreal anti-VEGF injection; and in extreme cases, vitrectomy could be combined with intravitreal anti-VEGF injection, PRP, and endocyclo-photocoagulation. NVG with the primary pathology of PDR was reported to be less aggressive than ischemic CRVO.^[8]

Medical management

Antiglaucoma medications include carbonic anhydrase inhibitors (oral and topical), beta-blockers, and alpha-2 agonists, which lower aqueous production. Prostaglandin analogs may aggravate inflammation but are effective and are used only when IOP is not controlled with other medications. Miotics should be avoided because they may increase the inflammation and worsen synechial angle closure. Supportive measures like topical steroids and cycloplegics help in treating inflammation in these eyes.

VEGF inhibitors are effective but provide temporary means of reducing NVI and NVA leading to lowering of IOP.^[50-52] Anti-VEGF agents induce a rapid involution of NVI confirmed with iris FA^[53] and allow time for the onset of action of PRP.^[54]

Surgical management

Surgical management of NVG is challenging mainly due to increased risk for failure.^[55,56] The main indications of surgery

in NVG are insufficient IOP control despite maximum medical therapy and extensive peripheral anterior synechia formation that occludes the angle and impedes aqueous outflow. Prior measures to reduce inflammation and activity of neovascularization help improve the surgical outcome.^[55,57,58] Common surgical modalities include trabeculectomy, glaucoma drainage devices (GDDs), and cyclodestructive procedures.

Trabeculectomy

Traditional trabeculectomy has a high failure rate attributed to severe inflammation and hyphema.^[59,60] Success of trabeculectomy has improved with use of antimetabolites (mitomycin C/5-fluorouracil), prior good PRP, prior ARC, and intravitreal anti-VEGF injection alone or with vitrectomy.^[13,57,61-63] [Fig. 7]. The success rates of trabeculectomy with mitomycin C vary from 62.6% to 81.2% at 1 year^[55,58,61,64] and reduce to 51.3% at 5 years.^[55,58] Preoperative intravitreal bevacizumab (IVB) has shown to decrease postoperative hyphema^[57,58,65] and improve success of trabeculectomy with mitomycin C.^[57,66] The possible causes of failure of trabeculectomy in NVG have been investigated. Takihara *et al.* found age ≤50 years ($P = 0.0007$) and history of previous vitrectomy ($P = 0.02$) to be significant independent risk factors for failure on multivariate analysis.^[58] Studies have also reported lower preoperative IOP^[55] and previous cataract surgery^[61] to be significant risk factors for persistent hypotony or failure.

Glaucoma drainage devices

The glaucoma drainage devices (GDDs) include valved/flow restrictive implants (Ahmed glaucoma valve [AGV]) and nonvalved implants (Baerveldt, Molteno, and AADI). In eyes with NVG, valved implants are preferred to help with immediate IOP reduction with lesser possibilities of hypotony. Care should be taken to prevent intraoperative and postoperative hypotony and damage to the iris. Success rates of GDD in NVG are lower compared to other indications.^[13,67-69] The success rate did not improve with prior PRP^[70] or concurrent use of anti-VEGF therapy.^[71-73] Reduction of IOP is not much different with Ahmed glaucoma valve and Baerveldt shunt implant.^[67,70] The 5-year results of the Ahmed versus Baerveldt study were similar on a multivariate analysis ($P = 0.20$).^[67] GDD surgery combined with vitrectomy could bring additional benefit.^[74]

Comparison of trabeculectomy and GDD in eyes with NVG

In a retrospective study, Shen *et al.* reported similar success rate for trabeculectomy with MMC and AGV over 2 years (trabeculectomy

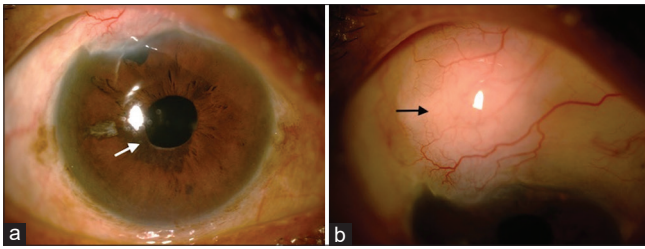


Figure 7: (a) Posttrabeculectomy pictures of an eye with neovascular glaucoma. Sphincter atrophy and iris burns due to accidental laser on the iris (white arrow); (b) good functional bleb (black arrow)

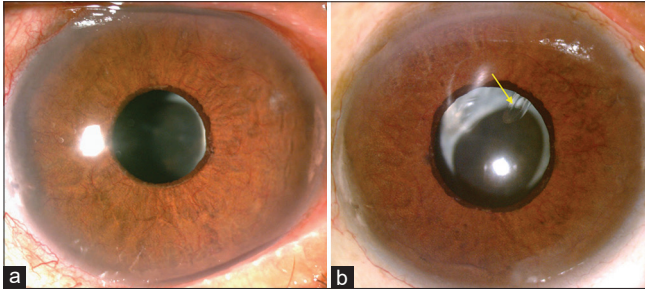


Figure 8: (a) Preoperative picture of neovascular glaucoma (ocular ischemic syndrome) with persistent new vessels and (b) post-Ahmed glaucoma valve implantation with tube in the posterior chamber (yellow arrow)

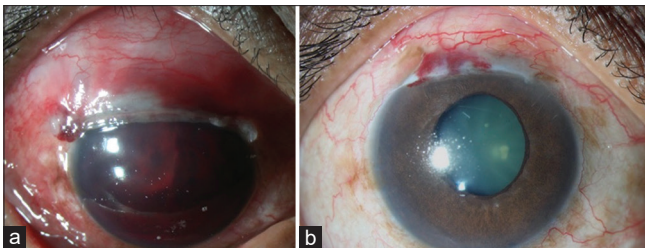


Figure 9: (a) Total hyphema in an eye with NVG post-trabeculectomy and (b) post-resolution of hyphema—note ectropion uveae and moderately elevated bleb

55%, AGV 60%, $P=0.474$).^[75] In a prospective study, higher success was seen in eyes with intravitreal ranibizumab (IVR) followed by trabeculectomy than AGV (significantly lower IOP in IVR at 1 month ($P=0.02$) but not at 6 months; complete + qualified success 94.5% and 68.4%, respectively; $P=0.32$).^[76] Wang *et al.* recorded greater reduction of IOP with AGV over trabeculectomy in eyes with NVG and vitreous hemorrhage (VH) (performed after pars plana vitrectomy for VH) ($P=0.01$ at 12 months); but the difference in absolute success probabilities was not significantly different with AGV or trabeculectomy at 12 months: 71.3% and 46.7%, $P=0.11$.^[77]

The outcome is not much different between trabeculectomy with MMC and AGV when retinal ischemia is adequately addressed preoperatively.^[63,75] Usually, GDD is reserved for eyes with persistent new vessels, or in those where other filtering surgeries are not feasible^[78] [Fig. 8].

Cyclophotocoagulation (CPC) using diode laser is a cycloablative procedure to decrease aqueous production and reduce IOP in eye with NVG.^[78] Complications following CPC include hyphema, chronic iritis, corneal edema, and phthisis bulbi. CPC is usually reserved for eyes with poor visual potential or as a temporizing measure in eyes with high IOP

where the media are not clear enough to perform PRP or in those instances where other filtering surgeries are not feasible.^[78]

CPC could also be combined with anterior retinal cryopexy in eyes with persistent NV and uncontrolled IOP. Micropulse diode CPC is another modality, but the ability to control IOP is not much different than diode CPC. Endocyclophotocoagulation with pars plana vitrectomy and PRP are reported to have better capability to reduce the elevated IOP.^[79]

The treatment of NVG secondary to OIS should be multidisciplinary approach by involving a cardiologist and/or vascular surgeon for carotid arteries imaging and carotid endarterectomy if indicated.^[80]

Complications after glaucoma surgery in eyes with neovascular glaucoma

In view of complex pathology in NVG, ongoing inflammation and new vessels in the eye, and surgical interventions like trabeculectomy and GDD are associated with various complications. Most common complication is hyphema that ranges from 4%^[81] to 85%^[82] [Fig. 9]. The incidence of hyphema can be reduced by cauterizing iris before iridectomy, preoperative IVB to reduce NVI, and avoiding intraoperative and postoperative hypotony. Other complications include anterior chamber shallowing up to 30%,^[82] and serous choroidal detachment up to 20%.^[73] Late complications like bleb leak with mitomycin C trabeculectomy have been reported in up to 13% eyes.^[55] Two serious complications in these eyes are persistent hypotony reported up to 16.7%^[65] and suprachoroidal hemorrhage up to 5% of eyes.^[82]

GDD in NVG has good IOP control; however, long-term complications can be serious. Microangiopathy and ischemia predispose eyes with GDD to complications like conjunctival erosion and tube exposure in up to 12.5% eyes.^[83,84] Contraction of fibrovascular membrane results in tube occlusion and tube corneal touch may present in 3%^[83,84] to 14% eyes.^[70]

Prognosis

NVG carries a guarded prognosis. Prognosis is predominantly dependent on two factors: prevention and treatment of NVG early in its course and the underlying disease process. Intensity and frequency of follow-up depend on the etiology of NVG and the clinical course. In subjects with ischemic CRVO, it calls for a 2–4 weekly review with a detailed evaluation including undilated gonioscopy to detect early angle new vessels that could occur in 6–12% of eyes with CRVO without NVI.^[19]

Conclusion

NVG is a potentially blinding disease and is an ophthalmic emergency. Early diagnosis and multidisciplinary systematic approach would be needed to salvage useful vision in these eyes. Timely and appropriate treatment of underlying cause of ischemia and controlling the IOP are the keys to successful management of this condition. Diabetes is an important cause of NVG. With global increase in diabetes mellitus,^[85] an increase in NVG secondary to DR is expected. Hence, prompt detection and adequate treatment of PDR would help decrease the occurrence of this blinding disease.

Acknowledgment

The authors thank Dr. Talvir Sidhu for photographs of angle and iris new vessels and Dr. Dilip Mishra for the histopathology images.

Financial support and sponsorship

The study was supported by the Hyderabad Eye Research Foundation.

Conflicts of interest

There are no conflicts of interest.

References

- Coats G. Further cases of thrombosis of the central vein. J. & A. Churchill; 1906.
- Salus R. Rubeosis iridis diabetica, eine bisher unbekannte diabetische Irisveränderung. Med Klin 1928;24:256-8.
- Weiss DI, Shaffer RN, Nehrenberg TR. Neovascular glaucoma complicating carotid-cavernous fistula. Arch Ophthalmol 1963;69:304-7.
- Narayananwamy A, Baskaran M, Zheng Y, Lavanya R, Wu R, Wong WL, *et al.* The prevalence and types of glaucoma in an urban Indian population: The Singapore Indian Eye Study. Invest Ophthalmol Vis Sci 2013;54:4621-7.
- Paul C, Sengupta S, Choudhury S, Banerjee S, Sleath BL. Prevalence of glaucoma in Eastern India: The Hooghly River glaucoma study. Indian J Ophthalmol 2016;64:578-83.
- OHRT V. The frequency of rubeosis iridis in diabetic patients. Acta Ophthalmol 1971;49:301-7.
- Mocanu C, Barăscu D, Marinescu F, Lăcrăţeanu M, Iliuşi F, Simionescu C. Neovascular glaucoma--retrospective study. Oftalmologia (Bucharest, Romania: 1990). 2005;49:58-65.
- Hayreh SS. Neovascular glaucoma. Prog Retin Eye Res 2007;26:470-85.
- Luo J, Yan Z, Jia Y, Luo R. Clinical analysis of 42 cases of ocular ischemic syndrome. J Ophthalmol 2018;2018: 2606147. doi: 10.1155/2018/2606147.
- Shazly TA, Latina MA. Neovascular glaucoma: Etiology, diagnosis and prognosis. Paper presented at: Seminars in ophthalmology. 2009.
- Sivak-Callcott JA, O'Day DM, Gass JDM, Tsai JC. Evidence-based recommendations for the diagnosis and treatment of neovascular glaucoma. Ophthalmology 2001;108:1767-76.
- Brown GC, Magargal LE, Schachat A, Shah H. Neovascular glaucoma: Etiologic considerations. Ophthalmology 1984;91:315-20.
- Rodrigues GB, Abe RY, Zangalli C, Sodre SL, Donini FA, Costa DC, *et al.* Neovascular glaucoma: A review. Int J Retin Vitreous 2016;2:26.
- Morrison JC, Pollack IP. Glaucoma: Science and practice. Thieme New York; 2003.
- Havens SJ, Gulati V. Neovascular glaucoma. In: Retinal Pharmacotherapeutics. Vol 55. Karger Publishers; 2016. p. 196-204.
- Barac IR, Pop MD, Gheorghe AI, Taban C. Neovascular secondary glaucoma, etiology and pathogenesis. Rom J Ophthalmol 2015;59:24-8.
- Group CVOS. A randomized clinical trial of early panretinal photocoagulation for ischemic central vein occlusion: The central vein occlusion study group n report. Ophthalmology 1995;102:1434-44.
- Hayreh SS. The CVOS group M and N reports. Ophthalmology 1996;103:350-2.
- Hayreh SS, Rojas P, Podhajsky P, Montague P, Woolson RF. Ocular neovascularization with retinal vascular occlusion-III: Incidence of ocular neovascularization with retinal vein occlusion. Ophthalmology 1983;90:488-506.
- Armaly MF, Baloglou PJ. Diabetes mellitus and the eye: I. Changes in the anterior segment. Arch Ophthalmol 1967;77:485-92.
- Madsen P. Haemorrhagic glaucoma. Comparative study in diabetic and nondiabetic patients. Br J Ophthalmol 1971;55:444-50.
- Lee P, Wang CC, Adamis AP. Ocular neovascularization: An epidemiologic review. Surv Ophthalmol 1998;43:245-69.
- Chalam KV, Brar VS, Murthy RK. Human ciliary epithelium as a source of synthesis and secretion of vascular endothelial growth factor in neovascular glaucoma. JAMA Ophthalmol 2014;132:1350-4.
- Tolentino MJ, Miller JW, Gragoudas ES, Chatzistefanou K, Ferrara N, Adamis AP. Vascular endothelial growth factor is sufficient to produce iris neovascularization and neovascular glaucoma in a nonhuman primate. Arch Ophthalmol 1996;114:964-70.
- Yu XB, Sun XH, Dahan E, Guo WY, Qian SH, Meng FR, *et al.* Increased levels of transforming growth factor-beta1 and-beta2 in the aqueous humor of patients with neovascular glaucoma. Ophthalmic Surg Lasers Imaging Retina 2007;38:6-14.
- Chen K-H, Wu C-C, Roy S, Lee S-M, Liu J-H. Increased interleukin-6 in aqueous humor of neovascular glaucoma. Invest Ophthalmol Vis Sci 1999;40:2627-32.
- Simo R, Carrasco E, Garcia-Ramirez M, Hernandez C. Angiogenic and antiangiogenic factors in proliferative diabetic retinopathy. Curr Diabetes Rev 2006;2:71-98.
- Aiello LP, Avery RL, Arrigg PG, Keyt BA, Jampel HD, Shah ST, *et al.* Vascular endothelial growth factor in ocular fluid of patients with diabetic retinopathy and other retinal disorders. New Engl J Med 1994;331:1480-7.
- Senger DR, Perruzzi CA, Streit M, Koteliansky VE, de Fougerolles AR, Detmar M. The $\alpha\beta 1$ and $\alpha\beta 1$ integrins provide critical support for vascular endothelial growth factor signaling, endothelial cell migration, and tumor angiogenesis. Am J Pathol 2002;160:195-204.
- Gartner S, Henkind P. Neovascularization of the iris (rubeosis iridis). Surv Ophthalmol 1978;22:291-312.
- John T, Sassani JW, Eagle Jr RC. The myofibroblastic component of rubeosis iridis. Ophthalmol 1983;90:721-8.
- Azad R, Arora T, Sihota R, Chandra P, Mahajan D, Sain S, *et al.* Retcam fluorescein gonioangiography: A new modality for early detection of angle neovascularization in diabetic retinopathy. Retina 2013;33:1902-7.
- Weiss D, Gold D. Neofibrovascularization of iris and anterior chamber angle: A clinical classification. Ann Ophthalmol 1978;10:488-91.
- Dubey S, Pegu J. Management of neovascular glaucoma. J Curr Glaucoma Pract 2009;3:27-34.
- Brancato R, Bandello F, Lattanzio R. Iris fluorescein angiography in clinical practice. Surv Ophthalmol 1997;42:41-70.
- Parodi MB, Bondel E, Russo D, Ravalico G. Iris indocyanine green videoangiography in diabetic iridopathy. Br J Ophthalmol 1996;80:416-419.
- Li ZQ, Zhou XX, Lin S, Li JL, Wu JG. Angiography reveals early hiding iris neovascularization after ischemic CRVO. Int J Ophthalmol 2013;6:253-254.
- Hwang TS, Hagag AM, Wang J, Zhang M, Smith A, Wilson DJ, *et al.* Automated quantification of nonperfusion areas in 3 vascular plexuses with optical coherence tomography angiography in eyes of patients with diabetes. JAMA Ophthalmol 2018;136:929-6.
- Hwang TS, Gao SS, Liu L, Lauer AK, Bailey ST, Flaxel CJ, *et al.* Automated quantification of capillary nonperfusion using optical coherence tomography angiography in diabetic retinopathy. JAMA Ophthalmol 2016;134:367-73.
- Spaide RF, Klancnik JM, Jr., Cooney MJ. Retinal vascular layers imaged by fluorescein angiography and optical coherence tomography angiography. JAMA Ophthalmol. 2015;133:45-50.
- An L, Wang RK. *In vivo* volumetric imaging of vascular perfusion within human retina and choroids with optical micro-angiography. Opt Express 2008;16:11438-52.
- Spaide RF, Fujimoto JG, Waheed NK. Optical coherence tomography angiography. Retina 2015;35:2161-2.
- Roberts PK, Goldstein DA, Fawzi AA. Anterior segment optical coherence tomography angiography for identification of iris vasculature and staging of iris neovascularization: A pilot study. Curr Eye Res 2017;42:1136-42.
- Hirano T, Kakihara S, Toriyama Y, Nittala MG, Murata T, Sadda S. Wide-field en face swept-source optical coherence tomography angiography using extended field imaging in diabetic retinopathy. Br J Ophthalmol 2018;102:1199-203.
- Sawada O, Ichiyama Y, Obata S, Ito Y, Kakinoki M, Sawada T, *et al.* Comparison between wide-angle OCT angiography and ultra-wide field fluorescein angiography for detecting non-perfusion areas and retinal neovascularization in eyes with diabetic retinopathy. Graefes Arch Clin Exp Ophthalmol 2018;256:1275-80.
- Russell JF, Shi Y, Hinkle JW, Scott NL, Fan KC, Lyu C, *et al.*

- Longitudinal wide-field swept-source OCT angiography of neovascularization in proliferative diabetic retinopathy after panretinal photocoagulation. *Ophthalmol Retina* 2019;3:350-61.
47. Callahan MA. Photocoagulation and rubeosis iridis. *Am J Ophthalmol* 1974;78:873-4.
 48. Laatikainen L. Preliminary report on effect of retinal panphotocoagulation on rubeosis iridis and neovascular glaucoma. *Br J Ophthalmol* 1977;61:278-84.
 49. Murphy RP, Egbert PR. Regression of iris neovascularization following panretinal photocoagulation. *Arch Ophthalmol* 1979;97:700-2.
 50. Tasman W, Magargal LE, Augsburger JJ. Effects of argon laser photocoagulation on rubeosis iridis and angle neovascularization. *Ophthalmol* 1980;87:400-2.
 51. Horsley MB, Kahook MY. Anti-VEGF therapy for glaucoma. *Curr Opin Ophthalmol* 2010;21:112-7.
 52. Grisanti S, Biester S, Peters S, Tatar O, Ziemssen F, Bartz-Schmidt KU, *et al.* Intracameral bevacizumab for iris rubeosis. *Am J Ophthalmol* 2006;142:158-60.
 53. SooHoo JR, Seibold LK, Kahook MY. Recent advances in the management of neovascular glaucoma. Paper presented at: Seminars in ophthalmology. 2013.
 54. Grant WM. Management of neovascular glaucoma. Paper presented at: Symposium on ocular therapy. 1974.
 55. Higashide T, Ohkubo S, Sugiyama K. Long-term outcomes and prognostic factors of trabeculectomy following intraocular bevacizumab injection for neovascular glaucoma. *PLoS One* 2015;10:e0135766.
 56. Mietz H, Raschka B, Krieglstein GK. Risk factors for failures of trabeculectomies performed without antimetabolites. *Br J Ophthalmol* 1999;83:814-21.
 57. Saito Y, Higashide T, Takeda H, Ohkubo S, Sugiyama K. Beneficial effects of preoperative intravitreal bevacizumab on trabeculectomy outcomes in neovascular glaucoma. *Acta Ophthalmol* 2010;88:96-102.
 58. Takihara Y, Inatani M, Fukushima M, Iwao K, Iwao M, Tanihara H. Trabeculectomy with mitomycin C for neovascular glaucoma: Prognostic factors for surgical failure. *Am J Ophthalmol* 2009;147:912-918. e911.
 59. Olmos LC, Lee RK. Medical and surgical treatment of neovascular glaucoma. *Int Ophthalmol Clin* 2011;51:27-36.
 60. Nakatake S, Yoshida S, Nakao S, Arita R, Yasuda M, Kita T, *et al.* Hyphema is a risk factor for failure of trabeculectomy in neovascular glaucoma: A retrospective analysis. *BMC Ophthalmol* 2014;14:55.
 61. Al Obeidan S, Osman E, Al-Amro S, Kangave D, Abu El-Asrar A. Full preoperative panretinal photocoagulation improves the outcome of trabeculectomy with mitomycin C for neovascular glaucoma. *Eur J Ophthalmol* 2008;18:758-64.
 62. Kiuchi Y, Nakae K, Saito Y, Ito S, Ito N. Pars plana vitrectomy and panretinal photocoagulation combined with trabeculectomy for successful treatment of neovascular glaucoma. *Graefes Arch Clin Exp Ophthalmol* 2006;244:1627-32.
 63. Sandramouli S, Sihota R, Sood N. Role of anterior retinal cryoablation in the management of neovascular glaucoma. *Doc Ophthalmol* 1993;84:179-85.
 64. Mandal AK, Majji AB, Mandal SP, Das T, Jalali S, Gothwal VK, *et al.* Mitomycin-C-augmented trabeculectomy for neovascular glaucoma. A preliminary report. *Indian J Ophthalmol* 2002;50:287-93.
 65. Takihara Y, Inatani M, Kawaji T, Fukushima M, Iwao K, Iwao M, *et al.* Combined intravitreal bevacizumab and trabeculectomy with mitomycin C versus trabeculectomy with mitomycin C alone for neovascular glaucoma. *J Glaucoma* 2011;20:196-201.
 66. Gupta V, Jha R, Rao A, Kong G, Sihota R. The effect of different doses of intracameral bevacizumab on surgical outcomes of trabeculectomy for neovascular glaucoma. *Eur J Ophthalmol* 2009;19:435-41.
 67. Christakis PG, Kalenak JW, Tsai JC, Zurakowski D, Kammer JA, Harasymowycz PJ, *et al.* The Ahmed versus Baerveldt study: Five-year treatment outcomes. *Ophthalmol* 2016;123:2093-102.
 68. Netland PA, Ishida K, Boyle JW. The Ahmed Glaucoma Valve in patients with and without neovascular glaucoma. *J Glaucoma* 2010;19:581-6.
 69. Netland PA. The Ahmed glaucoma valve in neovascular glaucoma (An AOS Thesis). *Trans Am Ophthalmol Soc* 2009;107:325-42.
 70. Yalvac I, Eksioglu U, Satana B, Duman S. Long-term results of Ahmed glaucoma valve and Molteno implant in neovascular glaucoma. *Eye* 2007;21:65-70.
 71. Kang JY, Nam KY, Lee SJ, Lee SU. The effect of intravitreal bevacizumab injection before Ahmed valve implantation in patients with neovascular glaucoma. *Int Ophthalmol* 2014;34:793-9.
 72. Sahyoun M, Azar G, Khoueir Z, Antoun J, Kourie H, Nehme J, *et al.* Long-term results of Ahmed glaucoma valve in association with intravitreal bevacizumab in neovascular glaucoma. *J Glaucoma* 2015;24:383-8.
 73. Arcieri ES, Paula JS, Jorge R, Barella KA, Arcieri RS, Secches DJ, *et al.* Efficacy and safety of intravitreal bevacizumab in eyes with neovascular glaucoma undergoing Ahmed glaucoma valve implantation: 2-year follow-up. *Acta Ophthalmol* 2015;93:e1-6.
 74. Kolomeyer AM, Seery CW, Emami-Naeimi P, Zarbin MA, Fechtner RD, Bhagat N. Combined pars plana vitrectomy and pars plana Baerveldt tube placement in eyes with neovascular glaucoma. *Retina* 2015;35:17-28.
 75. Shen CC, Salim S, Du H, Netland PA. Trabeculectomy versus Ahmed Glaucoma Valve implantation in neovascular glaucoma. *Clin Ophthalmol*. 2011;5:281-6.
 76. Liu L, Xu Y, Huang Z, Wang X. Intravitreal ranibizumab injection combined trabeculectomy versus Ahmed valve surgery in the treatment of neovascular glaucoma: Assessment of efficacy and complications. *BMC Ophthalmol* 2016;16:65.
 77. Wang MH, Li QM, Dong HT, Dong SQ, Li Y, Zheng CY. Ahmed valves vs trabeculectomy combined with pars plana vitrectomy for neovascular glaucoma with vitreous hemorrhage. *Eur J Ophthalmol* 2017;27:774-80.
 78. Bloom PA, Tsai JC, Sharma K, Miller MH, Rice NS, Hitchings RA, *et al.* "Cyclodiode": Trans-scleral diode laser cyclophotocoagulation in the treatment of advanced refractory glaucoma. *Ophthalmol* 1997;104:1508-20.
 79. Marra KV, Wagley S, Omar A, Kinoshita T, Kovacs KD, Silva P, *et al.* Case-matched comparison of vitrectomy, peripheral retinal endolaser, and endocyclophotocoagulation versus standard care in neovascular glaucoma. *Retina* 2015;35:1072-83.
 80. Terelak-Borys B, Skonieczna K, Grabska-Liberek I. Ocular ischemic syndrome—a systematic review. *Med Sci Monit* 2012;18:RA138-44.
 81. Zhou M-W, Wei W, Huang W-b, Chen S-d, Li X-Y, Gao X-B, *et al.* Adjunctive with versus without intravitreal bevacizumab injection before Ahmed glaucoma valve implantation in the treatment of neovascular glaucoma. *Chin Med J* 2013;126:1412-7.
 82. Mahdy RA, Nada WM, Fawzy KM, Alnashar HY, Almosalamy SM. Efficacy of intravitreal bevacizumab with panretinal photocoagulation followed by Ahmed valve implantation in neovascular glaucoma. *J Glaucoma* 2013;22:768-72.
 83. Sevim MS, Buttanri IB, Kugu S, Serin D, Sevim S. Effect of intravitreal bevacizumab injection before Ahmed glaucoma valve implantation in neovascular glaucoma. *Ophthalmologica* 2013;229:94-100.
 84. Ma KT, Yang JY, Kim JH, Kim NR, Hong S, Lee ES, *et al.* Surgical results of Ahmed valve implantation with intraoperative bevacizumab injection in patients with neovascular glaucoma. *J Glaucoma* 2012;21:331-6.
 85. Cho N, Shaw J, Karuranga S, Huang Y, da Rocha Fernandes J, Ohlogge A, *et al.* IDF Diabetes Atlas: Global estimates of diabetes prevalence for 2017 and projections for 2045. *Diabetes Res Clin Pract* 2018;138:271-81.