

Case Report

Saphenous nerve compression in the differential diagnosis of knee pain. Case study and a review of the literature

Timo Jokela, Pekka Löppönen *

Department of Orthopedics and Traumatology, Seinäjoki Central Hospital, Seinäjoki, Finland

ARTICLE INFO

Keywords:

Knee pain

Saphenous nerve

ABSTRACT

A 17-year old male athlete presented with right knee and lower extremity pain that was resistant to traditional physical therapy and pain management for almost two years. He had played ice hockey as a goalie since childhood but was unable to return to play because of the pain. He had to a history of several different injuries to the same knee and had several MRI scans and physician visits without any help. Pain was aggravated by physical activity especially when the knee was extended but there was no major problem in the knee itself. Palpation of the adductor canal greatly aggravated the pain radiating below the knee. As local anaesthetic to the adductor canal eased the pain saphenous nerve impingement was suspected. Successful decompression of the nerve was performed and pain disappeared right after surgery. He was able to return to play ice hockey as a goalie three months after surgery. Even though iatrogenic injuries to saphenous nerve are common after orthopaedic operations, compression of the nerve in adductor canal is a rare condition that can cause problems in the differential diagnosis of knee pain. If needed, surgical treatment seems to yield a good outcome.

Case report

A 17-year old male athlete presented with right knee and lower extremity pain that was resistant to traditional physical therapy and pain management for almost two years. Due to a history of several different injuries to the same knee the diagnosis was delayed.

He had a history of septic arthritis and osteomyelitis of the same right knee from BCG (Bacillus Calmette–Guérin) vaccine requiring surgical drainage at the age of two that had healed perfectly. He had played ice hockey as a goalie since childhood. At the age of 13 he had had a traumatic patellar luxation of the right knee with medial patellofemoral ligament (MPFL) avulsion while playing ice hockey, eventually healing well with active physiotherapy. At the age of 15 he hurt his right knee again in a motorcycle accident ending with hemarthrosis and oedema of the medial condyle of femur in MRI. Again, the patient healed well without surgical procedures.

At the age of 16 yet another right knee injury occurred to the medial side of the knee while playing ice hockey with mainly old MPFL injury findings in MRI. No patellofemoral instability was observed, and physical therapy was started. However, this time the pain at the medial side of the right knee did not resolve. After almost two years of active physiotherapy and numerous visits to physicians, he had still not been able to return to playing ice hockey. The pain was aggravated by physical activity but also during rest when the knee was extended. The pain in the leg had become constant and there was soreness from the cold. He began to experience pain in the lower back and numbness and tingling of the lower leg. Traditional pain medication such as ibuprofen and paracetamol did not help with the pain

* Corresponding author.

E-mail address: pekka.lopponen@hyvaep.fi (P. Löppönen).

so codeine and pregabalin were prescribed. He has had an astonishing number of 14 MRI scans of the same right knee during his life.

He was eventually referred to an experienced orthopaedic surgeon. He had not been able to play ice hockey, and walking had become difficult. Even though he complained about right knee pain there was no major problem in the knee itself. The patient seemed to recognize some minor patellofemoral instability, but his primary pain was more severe and not directly caused by patellar movement. There was no motor weakness in the leg, but extension of the knee and tensioning of the thigh muscles led to severe pain migrating to the lower leg. There was an old scar on the skin at the superior medial side of the knee probably due to surgical drainage decades ago, but there was no local pain at that point. Provocative tests for sciatica were negative and peripheral muscle strength was preserved, indicating that the problem was not in the lower back. A clear Tinel sign at the medial side of the knee was found, indicating a cutaneous nerve problem but the pain was even more greatly aggravated by palpation of the adductor canal in the middle third of the thigh. As the pain radiated below the knee, but also to the anteromedial side of the shin, a saphenous nerve impingement at the adductor canal was suspected.

An ultrasound guided injection of local anaesthetic to the adductor canal momentarily eased the pain. The decision to decompress the nerve was made.

The operation was performed on the patient supine using spinal block anaesthesia and a tourniquet at the proximal thigh (Fig. 1). The incision was made to the medial side of the thigh. The branches of the medial cutaneous nerves of the thigh were first identified and protected. With the knee flexed, the sartorius muscle was retracted medially to expose the adductor canal. The thick fascia of the adductor canal was opened at the position of the proximal pain and the saphenous nerve was decompressed. Oedema surrounding the nerve in the adductor canal was noticed, thus indicating the main compressive point. The nerve and the femoral vessels were followed proximally as needed. The saphenous nerve was followed also distally when it travelled under the sartorius muscle, but no additional compression was found. Pain at the site of the positive Tinel sign remained outside the route of the saphenous nerve but seems to have been caused by a femoral cutaneous nerve (Fig. 2). The tourniquet was released and haemostasis controlled. The skin was closed in two

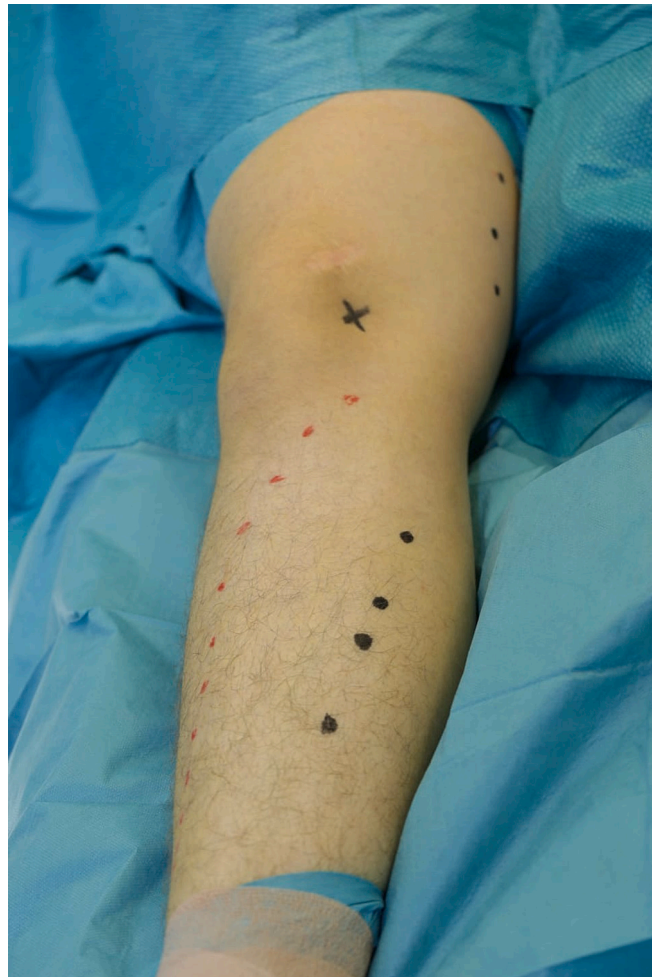

Fig. 1. Patient complained of radiating pain from the medial thigh to the right lower leg. Adductor canal on the median side of the thigh is marked with black marker pen. The area of the radiating pain in the shin is marked with a red and black marker pen. Point of the positive Tinel sign is marked with X.

layers. Leg use was allowed within the limits of pain after the proper healing of the wound in about two weeks.

The postoperative recovery of the nerve was rapid. The radiating pain from the nerve disappeared right after surgery. The recovery was slightly impaired when a superficial abscess occurred in the wound and required surgical drainage. No specific physiotherapy was needed to regain function, as the patient was seen at an out-patient clinic at one month and was already able to function well. Knee movements had returned normal with no neuropathic pain. The Tinel sign and hyperesthesia of the skin had vanished. He returned to playing ice hockey as a goalie three months after initial surgery with training sessions five times a week. One and a half years after surgery, the patient remains pain free.

Discussion

The saphenous nerve is a cutaneous branch of femoral nerve deriving mostly from L3 and L4 roots. It is a purely sensory nerve innervating the skin on the medial thigh, knee and lower leg (Fig. 3). Along with femoral artery and vein, the saphenous nerve travels in the medial thigh through the adductor (Hunter's) canal where it can be entrapped (Figs. 4, 5). The adductor canal is an aponeurotic tunnel surrounded by vastus medialis, sartorius and adductor muscles. An infrapatellar branch of the saphenous nerve then divides to provide sensation to the skin in front of the patella and anterior shin. The infrapatellar branch can get compressed at the knee level where it passes between the sartorius and the gracilis muscles. There is variation in the passage of the infrapatellar branch but also the area of skin innervation varies from anterior to lateral shin [1]. The common saphenous nerve descends along the medial side of the tibia.

Injury to the infrapatellar branch has been clearly reported in the literature as surgical operations in the knee area are very common. Typical operations predisposing to this injury include knee arthroscopy, anterior cruciate ligament repair and venous stripping surgery [2–4]. Direct trauma to the infrapatellar branch has also been reported as it is vulnerable to direct injury [5].

Our study represents a case of entrapment neuropathy of the saphenous nerve in the adductor canal. Because the compression site is more proximal to the infrapatellar branch, symptoms were also more comprehensive and radiating also to the medial shin. No clear problem was found regarding the infrapatellar branch and the common saphenous nerve was impinged and oedematous in the adductor canal proposing the true compressing site.

Saphenous nerve compression at the adductor canal is a rare condition with a limited number of series reported in the literature. Also, the reports are not always clear if the compression was at the adductor canal or affecting only the infrapatellar branch. Romanoff et al. treated a series of 30 patients with symptoms of saphenous nerve compression in the adductor canal [6]. The average age was 44 years and 73 % were females. Their criteria were 1. pain at the saphenous nerve distribution (thigh, knee and/or lower leg), 2. normal motor function and 3. tenderness to palpation at the adductor canal. Of all patients, 90 % experienced knee pain, 7 % had thigh pain and 3 % had calf pain. Surprisingly up to 41 % had had knee arthroscopy initially to treat the knee pain with obviously negative results. 27 % had had a clear trauma before saphenous nerve pain began and in 6 % the onset of pain had been surgery to the site. Patients were treated with repeated bupivacaine and triamcinolone injections into the adductor canal. 80 % had a favourable outcome while 13 % came out with no change and 7 % with increased pain.

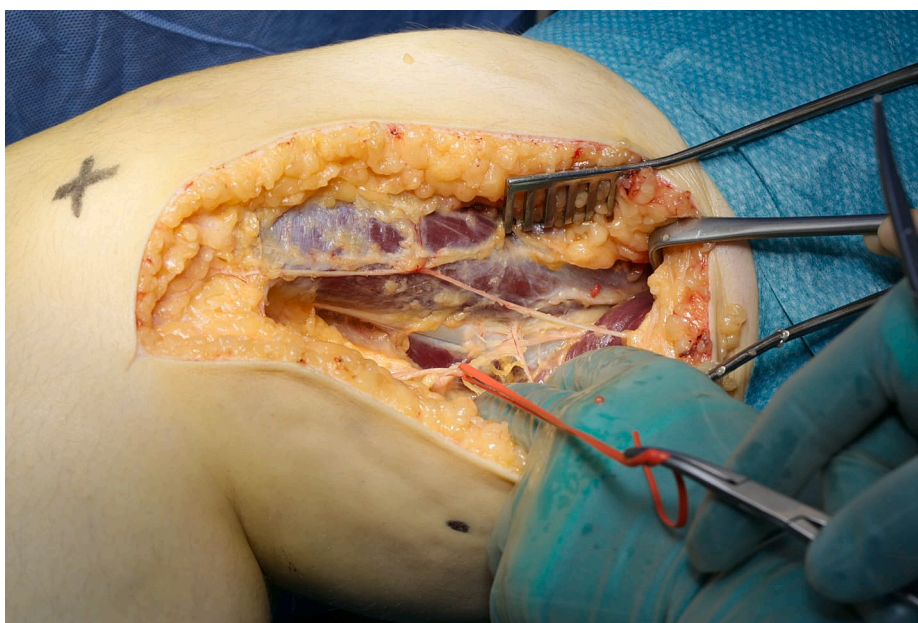
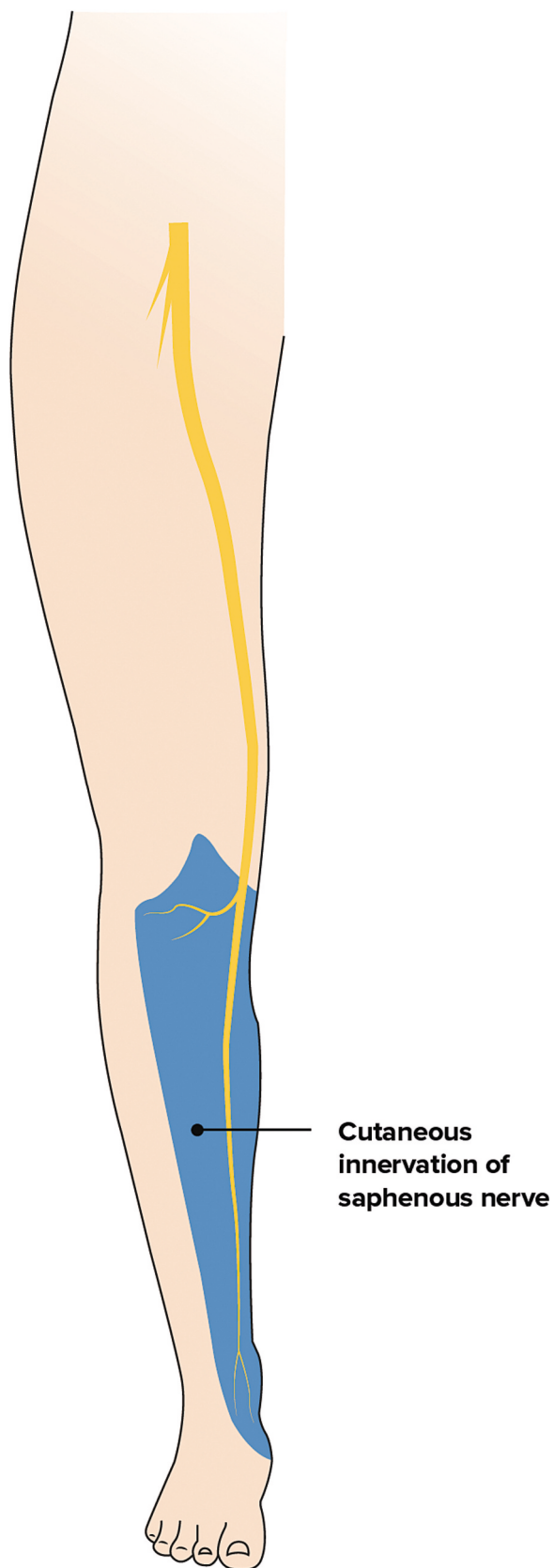


Fig. 2. Intraoperative view after decompression of the adductor canal. The knee is flexed to relax the sartorius muscle. The saphenous nerve is held by a vessel loop. A smaller femoral cutaneous nerve branch crosses the wound.



(caption on next page)

Fig. 3. Saphenous nerve is a pure sensory nerve innervating the skin on the medial thigh, knee and lower leg. Sensory area of the infrapatellar branch varies and can range also to the lateral part of the shin.

Worth et al. describe a series of 14 patients with 15 saphenous nerve entrapments [7]. 11 patients were female, and the average age was 47 years. Previous knee surgery was found to initiate symptoms in 10 knees, but the pain was spontaneous in 5 knees. A typical symptom was medial knee and leg pain after prolonged walking (87 %) and standing (47 %). In 67 % pain occurred at night and in 60 % after quadriceps exercises. Local pain at the adductor canal was found in all patients. All patients had a short relief of symptoms after the anaesthetic block. As the cause of symptoms varied, the surgical procedures also varied from nerve neurolysis to neurectomy. Some patients were operated several times including also knee or patella arthroplasty. Results showed complete relief of pain in 13 out of 15 knees. Worth et al. conclude that in their series neurectomy provided more predictable results than neurolysis.

Mozez et al. presented 32 patients with persistent pain in the lower part of the thigh and leg that was aggravated by movement [8]. The patients had difficulties in pointing to the site of pain origin. Hyperextension of the thigh complicated the pain in many patients. The pain was aggravated by compressing the adductor canal and relieved by local injection of anaesthetic. All patients were initially treated with injections. 12 (38 %) improved with injection but 4 were lost in the follow up. The remaining 16 were treated with neurolysis with 14 clearly improving.

Luerssen et al. treated six patients with seven saphenous nerve entrapments [9]. None had had an injury to the site and were thought to be spontaneous neuropathies. Five of the patients were female and the average age was 48 years. All patients presented with medial thigh and leg pain with tenderness in the adductor canal and sensory changes in the leg. A local block of anaesthetic was used to confirm the diagnosis. Two patients had back pain that resolved after operation. All six were treated operatively by initial neurolysis of

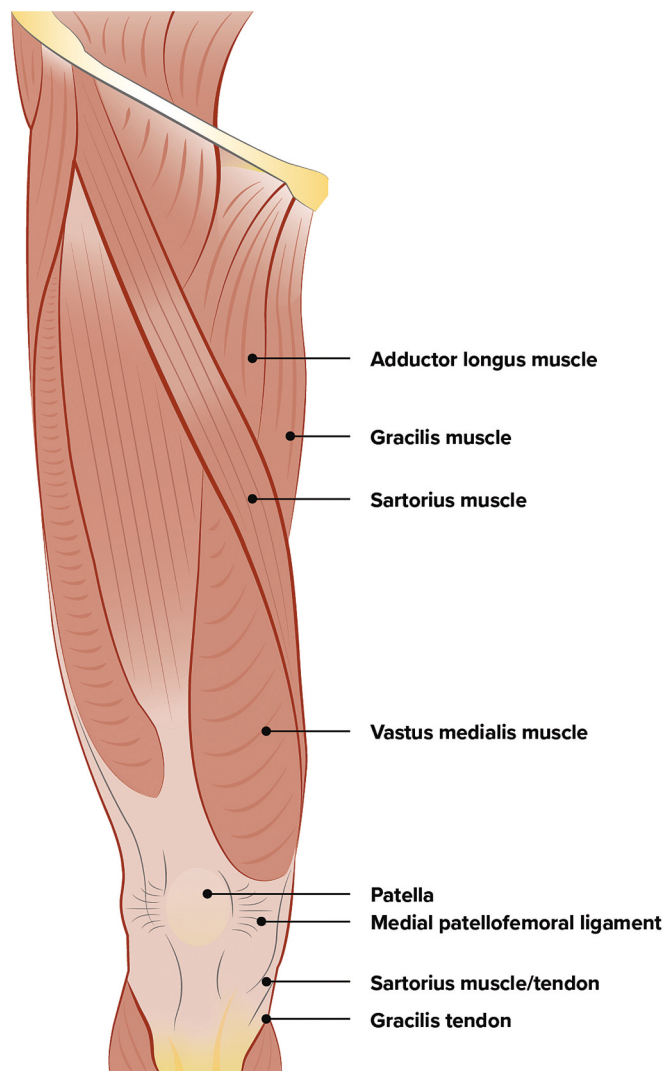


Fig. 4. Superficial anatomy of the thigh.

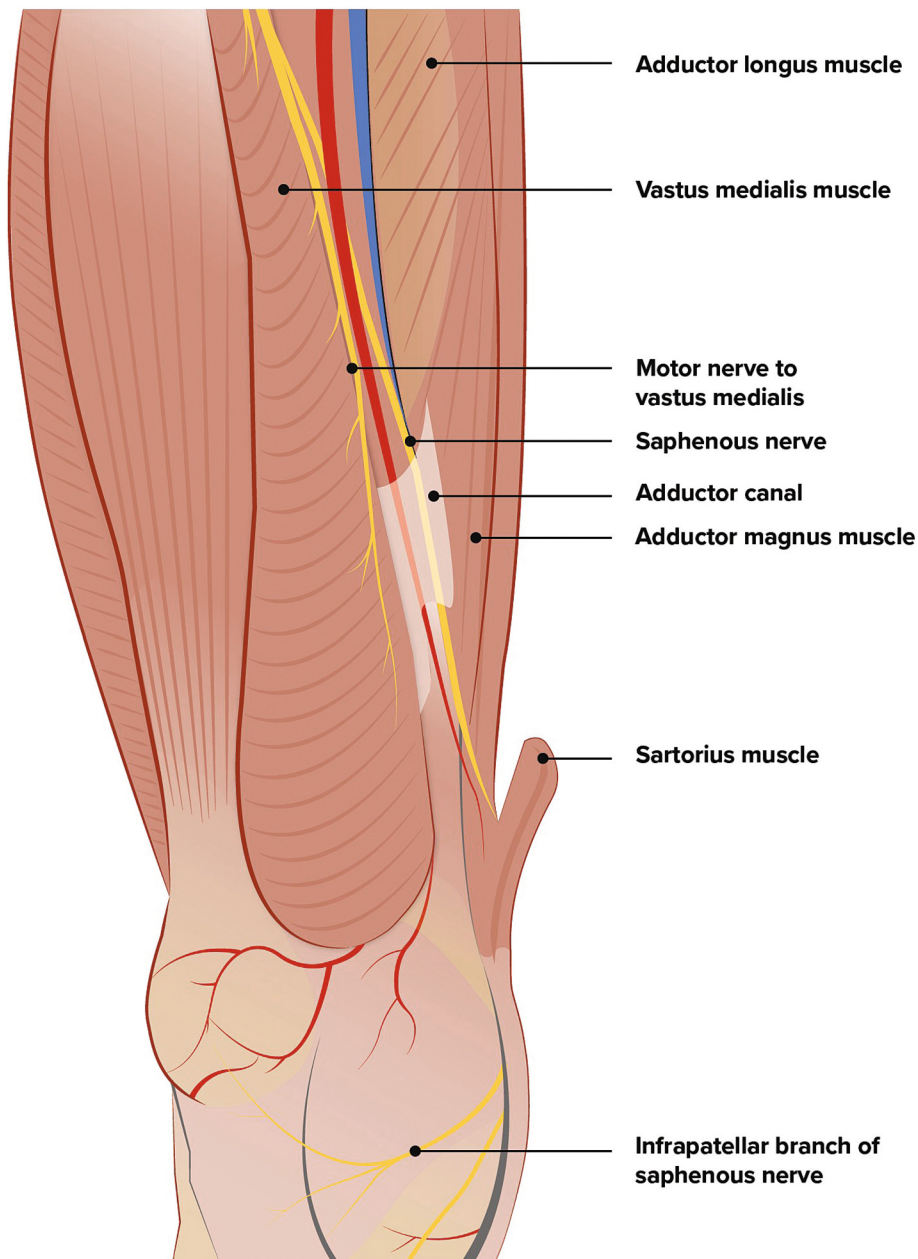


Fig. 5. Deep anatomy of the thigh. Saphenous nerve can get compressed in the adductor (Hunter's) canal surrounded by vastus medialis, sartorius and adductor muscles.

the nerve but three had to be re-operated at least once.

This present case report of a young athlete demonstrates the difficulty in diagnosing knee pain as nerve compressions in the leg are less common. The history of surgically treated bacterial arthritis and several minor injuries to the same knee probably caused the diagnostic problems. Also, the patient played as an ice hockey goalie, therefore requiring a lot of activation of medial thigh muscles. Thigh muscle hypertrophy has been reported to predispose to nerve entrapment [10].

When treating nerve problems, physicians need to understand the anatomy properly. Sciatica and other more common proximal nerve compressions radiate pain distally along these same peripheral nerves and should initially be excluded. Clinical findings implying a saphenous nerve entrapment are identification of the area of sensory disturbance and pain but also preservation of motor functions. The predominant entrapment site of maximal tenderness and pain provocation should be found either at the adductor canal or medial to the knee if only the infrapatellar branch is affected. Undoubtedly, multiple sites of compression can occur at the same time as well and compression at one site seems to predispose the whole nerve for other impingements too [11]. ENMG studies can be used to

help with the diagnosis but might still be negative even in clear saphenous nerve compression [12].

There is no scientific evidence to determine optimal treatment of saphenous nerve entrapment. It might be reasonable to begin physiotherapy with nerve gliding exercises, local manipulation and pain management. Local injections with an anaesthetic combined with glucocorticoids can be used to confirm the diagnosis and might even be used as a treatment. If the symptoms persist, a surgical decompression of the nerve can be performed. A complete release of all possible sites of compression along the saphenous nerve is recommended to avoid residual symptoms.

Conclusions

Saphenous nerve compression in the leg possesses a diagnostic problem due to its rarity. Objective imaging studies might turn out negative despite severe symptoms. The diagnosis is based on thorough clinical assessment and accurate knowledge of the anatomy. If needed, surgical treatment seems to yield a good outcome.

Ethical approval and consent

Written informed consent was obtained from the patient for this report to include publication of case and associated images.

CRediT authorship contribution statement

Timo Jokela: Conceptualization, Data curation, Writing – review & editing. **Pekka Löppönen:** Conceptualization, Data curation, Writing – original draft.

Consent

Written informed consent was provided by the patient.

Funding

P.L. received a grant from The Finnish Society for Surgery of the Hand for preparation of this article.

Declaration of competing interest

The authors declared no potential conflicts of interest with respect to the research, authorship and/or publication of this article.

References

- [1] K. Natsis, G. Konstantinidis, G. Geropoulos, T. Totlis, N. Lazaridis, T. Tegos, Transtendinous course of the infrapatellar branch of saphenous nerve. A contribution to the aetiology of entrapment neuropathy and modification of the existing classification, *Folia Morphol. (Warsz)* 75 (4) (2016) 481–485, <https://doi.org/10.5603/FM.a2016.0024> (Epub 2016 Nov 10. PMID: 27830881).
- [2] A. Hardy, L. Casabianca, K. Andrieu, L. Baverel, T. Noailles, Junior French Arthroscopy Society, Complications following harvesting of patellar tendon or hamstring tendon grafts for anterior cruciate ligament reconstruction: systematic review of literature, *Orthop. Traumatol. Surg. Res.* 103 (8S) (Dec 2017) S245–S248, <https://doi.org/10.1016/j.otsr.2017.09.002> (Epub 2017 Sep 6. PMID: 28888527).
- [3] A. Ruffilli, M. De Fine, F. Traina, F. Pilla, D. Fenga, C. Faldini, Saphenous nerve injury during hamstring tendons harvest: does the incision matter? A systematic review, *Knee Surg. Sports Traumatol. Arthrosc.* 25 (10) (Oct 2017) 3140–3145, <https://doi.org/10.1007/s00167-016-4217-8> (Epub 2016 Jun 23. PMID: 27338956).
- [4] R.C. Sam, S.H. Silverman, A.W. Bradbury, Nerve injuries and varicose vein surgery, *Eur. J. Vasc. Endovasc. Surg.* 27 (2) (Feb 2004) 113–120, <https://doi.org/10.1016/j.ejvs.2003.11.007> (PMID: 14718891).
- [5] T.D. Tennent, N.C. Birch, M.J. Holmes, R. Birch, N.J. Goddard, Knee pain and the infrapatellar branch of the saphenous nerve, *J. R. Soc. Med.* 91 (11) (Nov 1998) 573–575, <https://doi.org/10.1177/014107689809101106> (PMID: 10325872; PMCID: PMC1296949).
- [6] M.E. Romanoff, P.C. Cory Jr., A. Kalenak, G.C. Keyser, W.K. Marshall, Saphenous nerve entrapment at the adductor canal, *Am. J. Sports Med.* 17 (4) (Jul-Aug 1989) 478–481, <https://doi.org/10.1177/036354658901700405> (PMID: 2782531).
- [7] R.M. Worth, D.B. Kettelkamp, R.J. Defalque, K.U. Duane, Saphenous nerve entrapment. A cause of medial knee pain, *Am. J. Sports Med.* 12 (1) (Jan-Feb 1984) 80–81, <https://doi.org/10.1177/036354658401200114> (PMID: 6703186).
- [8] M. Mozes, G. Ouaknine, H. Nathan, Saphenous nerve entrapment simulating vascular disorder, *Surgery* 77 (2) (Feb 1975) 299–303 (PMID: 1129703).
- [9] T.G. Luerssen, R.L. Campbell, R.J. Defalque, R.M. Worth, Spontaneous saphenous neuralgia, *Neurosurgery* 13 (3) (Sep 1983) 238–241, <https://doi.org/10.1227/00006123-198309000-00004> (PMID: 6621837).
- [10] D. Dumitru, R.E. Windsor, Subartorial entrapment of the saphenous nerve of a competitive, *Phys. Sportsmed.* 17 (1) (Jan 1989) 116–125, <https://doi.org/10.1080/00913847.1989.11709686> (PMID: 27448006).
- [11] S.E. Mackinnon, Double and multiple “crush” syndromes. Double and multiple entrapment neuropathies, *Hand Clin.* 8 (2) (May 1992) 369–390 (PMID: 1613044).
- [12] M.E. Evangelopoulos, S. Humpert, K.M. Rösler, Ultrasound-guided electrodes for conduction studies of the saphenous nerve, *J. Clin. Neurophysiol.* 34 (3) (May 2017) 243–247, <https://doi.org/10.1097/WNP.0000000000000361> (PMID: 27870646).