

Neglected isolated scaphoid dislocation

Jong-Ryoon Baek, Seung Hyun Cho, Yong Seuk Lee, Young Hak Roh

ABSTRACT

The authors present a case of isolated scaphoid dislocation in a 40-year-old male that was undiagnosed for 2 months. The patient was treated by open reduction, Kirschner wire fixation, interosseous ligament repair using a suture anchor and Blatt's dorsal capsulodesis. At 6 years followup, his radiographs of wrist showed a normal carpal alignment with a scapholunate gap of 3 mm and no evidence of avascular necrosis (AVN) of the scaphoid.

Key words: Dislocation, isolated, scaphoid, neglected

MeSH terms: Dislocations, wrist joint, neglected diseases, osteonecrosis

INTRODUCTION

Isolated dislocation of the carpal scaphoid is a rare injury. To the best of our knowledge only approximately 35 cases have been reported in the literature since 1930. The present case is unique in the following aspects: (1) There was a delay of 2 months in treatment; (2) 6 years mid term followup was conducted; (3) suture anchor repair of the scapholunate ligament was done and Blatt's dorsal capsulodesis were performed.

CASE REPORT

A 40 year old male presented with a chief complaint of pain in the right dominant wrist. Two months prior to presentation, he sustained injury to the right wrist while protecting himself with extended right upper extremity upwards from heavy object falling from a high place. Initially, he did not seek any treatment despite immediate severe pain. However, symptoms of the injured wrist, including swelling and pain increased over time. Examination of the right wrist revealed generalized swelling, diffuse tenderness, limited range of motion, at wrist and an abnormal bony prominence in the

palmar aspect of the scaphoid. The function of the fingers was unimpaired. There was no sign of neurovascular injury. Radiographs of wrist showed an isolated palmar dislocation of the scaphoid and there were no abnormal findings in other carpal bones [Figure 1]. These findings were confirmed with computed tomography [Figure 2].

Initially, closed reduction was attempted by longitudinal traction and ulnar deviation under manual application of direct pressure over the dislocated scaphoid under general anesthesia, but it was unsuccessful. We determined further attempts would be futile considering that 2 months had already passed from the date of trauma. Thus, open reduction was performed through a dorsal approach. After capsulotomy, the isolated palmar scaphoid dislocation was observed, and a complete tear of the scapholunate ligament was noted [Figure 3]. Although we could not identify the integrity of the volar side ligaments, we assumed that they were disrupted. Reduction was interrupted due to fibrotic soft tissue interposed in the scapholunate interval. After debridement and retraction, the dislocated scaphoid was reduced [Figure 4]. The torn scapholunate ligament was sutured using a Mitek anchor (DepuyMitek, Inc. Raynham, MA, USA) and the reduced scaphoid was stabilized using two Kirschner wires (one scapholunate wire and one scaphocapitate wire). In addition, Blatt's dorsal capsulodesis was performed using a Mitek anchor to prevent rotary subluxation of the distal pole of the scaphoid [Figure 5]. After wound closure, an above the elbow thumb spica splint was applied for 2 weeks. An above the elbow thumb spica cast was worn in the same position for the subsequent 3 weeks, which was followed by application of a below the elbow thumb spica cast for an additional 2 weeks. In the 7th postoperative week, Kirschner wires were removed and rehabilitation was started.

The patient showed satisfactory wrist function on subsequent followup. He was doing regular physiotherapy.

Department of Orthopaedic Surgery, Gil Medical Center, Gachon University School of Medicine, Gil Hospital, 1198 Guwol-dong, Namdong-gu, Incheon, 405-760, Korea

Address for correspondence: Prof. Jong-Ryoon Baek, Department of Orthopaedic Surgery, Gil Medical Center, Gachon University School of Medicine, Gil Hospital, 1198 Guwol-dong, Namdong-gu, Incheon, 405-760, Korea. E-mail: baekjr@gilhospital.com

Access this article online	
Quick Response Code:	Website: www.ijoonline.com
	DOI: 10.4103/0019-5413.193472

He was able to return to his work as a manual laborer and had no complaints of residual pain. At 6 years followup,

his radiographs of wrist showed a normal carpal alignment with a scapholunate gap of 3 mm and no evidence of avascular necrosis (AVN) of the scaphoid [Figure 6]. The grip strength measured using a dynamometer was 21 Kg in

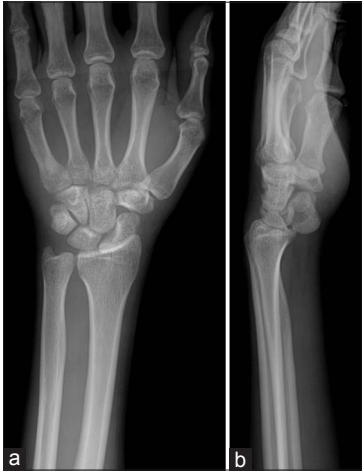

Figure 1: Initial radiograph of wrist joint with forearm posteroanterior (a) and lateral (b) view showing isolated scaphoid palmar dislocation

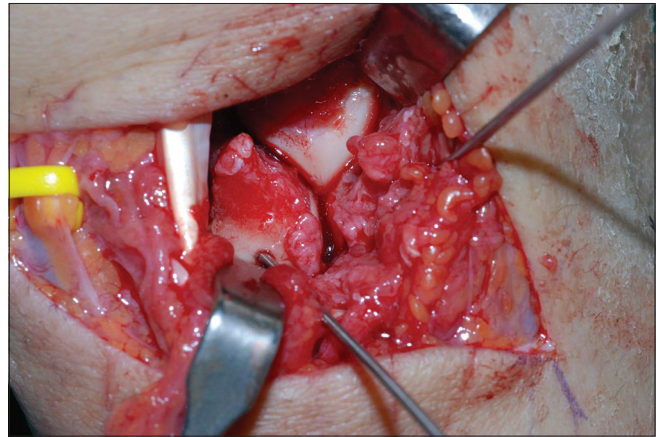


Figure 4: Intraoperative photograph showing reduced scaphoid

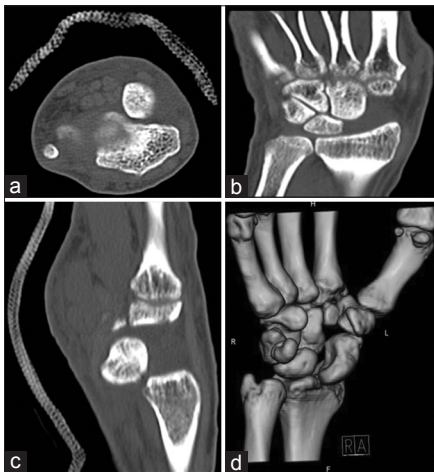


Figure 2: (a) Axial, (b) Coronal, (c) Sagittal, and (d) Three-dimension computed tomography scans of wrist showing isolated scaphoid palmar dislocation

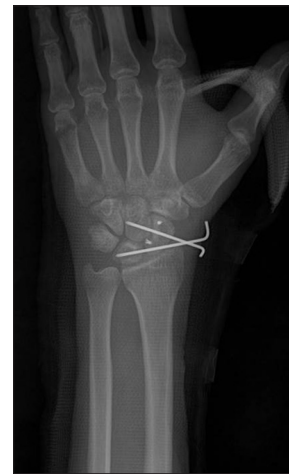

Figure 5: Immediate postoperative radiographs showing reduced scaphoid with Kirschnerwire fixation and two Mitek anchor sutures

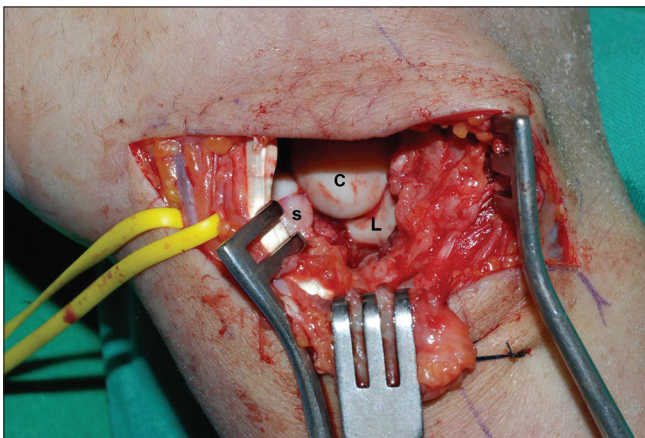


Figure 3: Intraoperative photograph showing the completely torn scapholunate ligament and scaphoid palmar dislocation. (C; capitate, S;scaphoid, L; lunate)

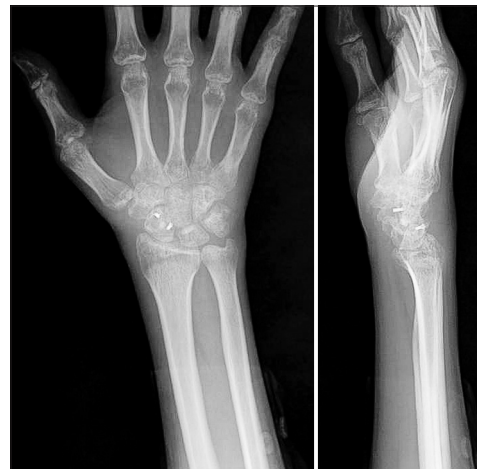

Figure 6: Followup x-rays six years after surgery showing that there was no avascular necrosis of scaphoid or redislocation

the right wrist (20 Kg in the left wrist). The range of motion in the right wrist was 60° dorsiflexion, 55° palmar flexion, 25° ulnar deviation and 15° radial deviation (70°, 70°, 30° and 15°, respectively, in the left wrist).

DISCUSSION

Isolated scaphoid dislocation is an extremely rare injury. The exact mechanism of scaphoid dislocation has yet to be established, but it is generally believed to involved dorsiflexion and ulnar deviation with or without rotational forces.^{1,2} There are several treatment options for scaphoid dislocation: Closed reduction and immobilization with a cast,^{3,4} closed reduction and percutaneous pinning,^{5,6} open reduction and pinning⁷ and open reduction and pinning followed by ligament repair.^{1,8,9} These treatment modalities are comparable in terms of long term clinical outcomes and share a relatively favorable prognosis. However, if diagnosis and treatment are delayed, open reduction and ligament repair may become inevitable.¹⁰⁻¹² In our patient, we performed open reduction, Kirschner wire pinning, interosseous ligament repair, and Blatt's capsulodesis. Open reduction was considered necessary, in part due to failed attempt at closed reduction, but mainly due to the need for ligament repair for enhanced stability after anatomical reduction. Open reduction and ligament repair have increasingly become more practical treatment strategy as demonstrated in previous studies.^{7,8,11,13} The torn scapholunate ligament was repaired to prevent scapholunate dissociation, which is the most common complication associated with scaphoid dislocation.¹⁴ A dorsal approach was used for ligament repair since the patient showed no sign of median nerve compression, thereby eliminating the need for the palmar approach. Furthermore, this approach allowed access to the strongest portion of the scapholunate interosseous ligament which is dorsal. In general, ligament reconstruction is considered a more appropriate option than repair for delayed treatment of ligament injuries. However, we thought repair using the remnant ligament tissue would yield better results in our case and stability of the scaphoid could be improved by Blatt's capsulodesis. The closed reduction failure can be attributed mainly to the presence of interposed soft tissue as well as to treatment delay. Thus, we believed it is reasonable to undertake open reduction in cases where closed reduction appears unattainable after one or two attempts. In contrast to most studies using only suture materials, we utilized an anchor device for ligament repair as suggested by Akinci M *et al.* (2012) and Samford MP *et al.* (2010).^{10,15} Blatt's capsulodesis was additionally carried out to prevent rotary subluxation and improve stability of the scaphoid¹⁶ which has never been employed by other authors other than Gómez *et al.*¹³ AVN of the scaphoid is a potential complication, but only one case of AVN after

isolated scaphoid dislocation has been reported.⁹ The low incidence of AVN following partial scaphoid dislocation can be attributed to the remaining scaphotrapezial ligament and capsular attachments providing sufficient blood supply.^{8,17} In cases of complete disruption of all ligamentous attachments, undisturbed intraosseous channels within the intact scaphoid bone allow rapid revascularization from surrounding soft tissue.¹ There was no development of AVN in our case as in other previous reports, which, however, is notable considering that the followup period was relatively long (6-years) compared to the other short-term followup studies.^{2,4,11,18} We believe ligament repair with open reduction effectively enhanced revascularization of the scaphoid from surrounding soft tissue, contributing to the prevention of AVN. Delayed diagnosis and treatment is a major risk factor for unfavorable prognosis of scaphoid dislocation.^{1,5-7,12,19} However, despite the 2 months delay, treatment results were satisfactory in our patient. To conclude, although early diagnosis and treatment is an important prognostic factor, accurate anatomic reduction, ligament repair, and secure fixation have more profound impact on the prognosis of scaphoid dislocation. A mid term results of treatment of neglected isolated scaphoid dislocation is presented.

REFERENCES

1. Leung YF, Wai YL, Kam WL, Ip PS. Solitary dislocation of the scaphoid. From case report to literature review. *J Hand Surg Br* 1998;23:88-92.
2. Ritchie DA, Gibson PH. Isolated dislocation of the scaphoid. *Injury* 1988;19:405-6.
3. Cherif MR, Ben Ghazlen R, Chehimi A, Annabi H, Trabelsi M, Mbarek M *et al.* [Isolated dislocation of the carpal scaphoid. A case report with review of the literature]. *Chir Main* 2002;21:305-8.
4. LEE WE. Isolated radial dislocation of carpal scaphoid. *Annals of Surgery* 1934;100:553-4.
5. Amamilo SC, Uppal R, Samuel AW. Isolated Dislocation of carpal scaphoid. *J Hand Surg Br* 1985;10:385-8.
6. McNamara MG, Corley FG. Dislocation of the carpal scaphoid: An 8-year followup. *J Hand Surg Am* 1992;17:496-8.
7. Chloros GD, Themistocleous GS, Zagoreos NP, Korres DS, Efstathopoulos DG, Soucacos PN. Isolated dislocation of the scaphoid. *Arch Orthop Trauma Surg* 2006;126:197-203.
8. Horton T, Shin AY, Cooney WP, 3rd. Isolated scaphoid dislocation associated with axial carpal dissociation: An unusual injury report. *J Hand Surg Am* 2004;29:1102-8.
9. Szabo RM, Newland CC, Johnson PG, Steinberg DR, Tortosa R. Spectrum of injury and treatment options for isolated dislocation of the scaphoid. A report of three cases. *J Bone Joint Surg Am* 1995;77:608-15.
10. Akinci M, Yildirim AO, Kati YA. Late-presenting, isolated, complete radial dislocations of the scaphoid treated with the Szabo technique. *J Hand SurgEurVol* 2012;37:901-3.
11. Inoue G, Maeda N. Isolated dorsal dislocation of the scaphoid. *J Hand Surg Br* 1990;15:368-9.

12. Kolby L, Larsen S, Jorring S, Sorensen AI, Leicht P. Missed isolated volar dislocation of the scaphoid. *Scand J Plast Reconstr Surg Hand Surg* 2007;41:264-6.
13. Gómez Fernández JM, Mendez López JM, GrauGaltés P, Caracuel Redondo F. Palmar scaphoid dislocation associated with dorsal perilunate dislocation. A case report and review of the literature. *Rev Esp Cir OrtopTraumatol* 2013;57:140-4.
14. Kennedy JG, O'Connor P, Brunner J, Hodgkins C, Curtin J. Isolated carpal scaphoid dislocation. *ActaOrthopBelg* 2006;72:478-83.
15. Somford MP, Sturm MF, Vroemen JP. Reconstruction of isolated scaphoid dislocation with carpal dissociation, associated with a carpal anomaly. *Strategies Trauma Limb Reconstr* 2010;5:105-10.
16. Blatt G. Capsulodesis in reconstructive hand surgery. Dorsal capsulodesis for the unstable scaphoid and volar capsulodesis following excision of the distal ulna. *Hand Clin* 1987;3:81-102.
17. Milankov M, Somer T, Jovanovic A, Brankov M. Isolated dislocation of the carpal scaphoid: Two case reports. *J Trauma* 1994;36:752-4.
18. Richards RS, Bennett JD, Roth JH. Scaphoid dislocation with radial-axial carpal disruption. *AJR Am J Roentgenol* 1993;160:1075-6.
19. Kilic M, Kalali F, Unlu M, Yildirim OS. Isolated carpal scaphoid dislocation. *ActaOrthopTraumatolTurc* 2012;46:68-71.

How to cite this article: Baek JR, Cho SH, Lee YS, Roh YH. Neglected isolated scaphoid dislocation. *Indian J Orthop* 2016;50:693-6.

Source of Support: Nil, **Conflict of Interest:** None.