



# Is early migration enough to explain late clinical loosening of hip prostheses?

Bengt Mjöberg

- Prosthetic loosening has been debated for decades, both in terms of the timing and nature of the triggering events. Multiple radiostereometric studies of hip prostheses have now shown that early migration poses a risk of future clinical failure, but is this enough to explain late clinical loosening?
- To answer this question, the progression of loosening from initiation to radiographic detection is described; and the need for explanations other than early prosthetic loosening is analysed, such as stress-shielding, particle disease, and metal sensitivity.
- Much evidence indicates that prosthetic loosening has already been initiated during or shortly after the surgery, and that the subsequent progression of loosening is affected by biomechanical factors, fluid pressure fluctuations and inflammatory responses to necrotic cells and cell fragments, i.e. the concept of late loosening appears to be a misinterpretation of late-detected loosening.
- Clinical implications: atraumatic surgery and initial prosthetic stability are crucial in ensuring low risk of prosthetic loosening.

**Keywords:** periprosthetic osteolysis; prosthetic loosening; radiostereometric analysis

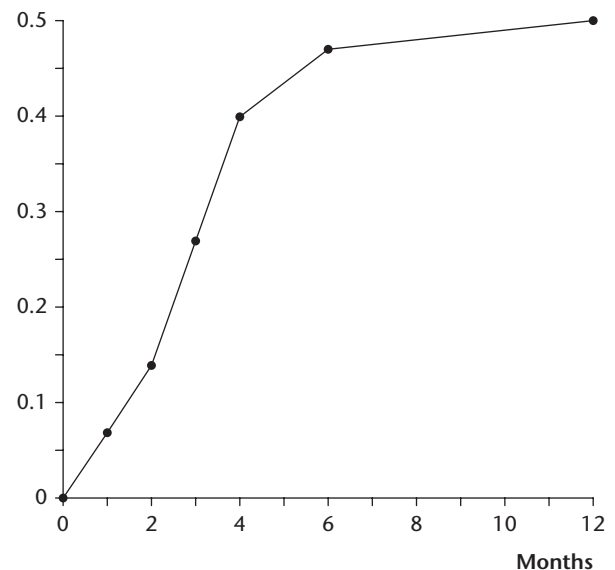
Cite this article: *EFORT Open Rev* 2020;5:113-117.

DOI: 10.1302/2058-5241.5.190014

## Introduction

Minor prosthetic migration as detected by radiostereometric analysis (RSA)<sup>1</sup> – with a detection limit of 0.1–0.2 mm – is sometimes seen as unrelated to loosening since such prosthetic components usually remain asymptomatic for a long time. An early rapid migration (Fig. 1) has thus been designated as ‘bone remodelling’,<sup>3</sup> ‘impaction’,<sup>4</sup> ‘bedding in’,<sup>5</sup> ‘initial settlement’<sup>6,7</sup> etc, and a subsequent slow migration of the femoral component even seen as ‘contributing to secure fixation’.<sup>8</sup> When loosening of such a

Cranial migration (mm)



**Fig. 1** Cranial migration of a migrating acetabular component studied using RSA at close intervals during the first year following arthroplasty.

Note. From *Acta Orthop Scand*<sup>2</sup> with permission.

prosthetic component is eventually detected on standard radiographs, it may be interpreted as late loosening of a previously apparently well-fixed component and explained by various *ad hoc* assumptions, such as stress-shielding, particle disease, and metal sensitivity.

The debate has mostly focused on the hypothesis of particle disease,<sup>9–16</sup> which states that wear particles, through a complex series of inflammatory responses, cause periprosthetic osteolysis and ultimately late loosening, i.e. that the periprosthetic osteolysis precedes the loosening. The theory of early loosening,<sup>17,18</sup> on the other hand, postulates that the process leading to clinical failure has already been initiated during or shortly after the surgery, i.e. that the periprosthetic osteolysis is secondary to the loosening. The latter theory is summarized and the need for other explanations is analysed.

## The theory of early loosening

### *Radiostereometric analysis (RSA)*

Multiple RSA studies of cemented and uncemented hip prostheses have shown that early prosthetic migration poses a risk of future failure; the larger the early migration, the greater the risk of future failure.<sup>19–24</sup> For example, in meta-regression analyses of data from combined RSA and survival studies, the 10-year revision rate increased about 10% for every 1-mm increase in proximal migration at two years of cemented as well as uncemented acetabular components,<sup>21</sup> and the 10-year revision rate increased about 4% for every 0.1-mm increase in distal migration at two years of cemented composite-beam femoral components.<sup>23</sup> Although the threshold values for early migration of various prosthetic components are not yet exactly determined, these combined studies indicate that the threshold values (above which an early migration poses a risk of future failure) are less than 0.2 mm cranial migration at two years for acetabular components<sup>21</sup> and less than 0.15 mm distal migration at two years for cemented composite-beam femoral components.<sup>23</sup> No threshold values were provided for cemented tapered or uncemented femoral components due to too few combined RSA and survival studies.<sup>23</sup>

### *Triggering factors*

The theory of early loosening (originally based on RSA studies)<sup>17,18</sup> postulates that prosthetic loosening is initiated by a few triggering factors (in italics below) during or shortly after the surgery. The initial fixation may be insufficient due to *poor interlock* (between the cement and the bone or between a cementless prosthetic component and the bone) or because of *poor bone quality* (due to osteoporosis or rheumatoid arthritis). An early loss of fixation may be caused by *resorption of a necrotic bone bed* formed during surgery (due to the surgical trauma or to the heat from curing cement). Interestingly, the resorption of necrotic bone can be pharmacologically inhibited with a bisphosphonate during the healing period, which reduces the early migration<sup>25</sup> and consequently increases the prosthetic survival time.<sup>26</sup>

### *Secondary affecting biomechanical factors*

The theory of early loosening further postulates that, if loosening has been initiated, the progression of loosening is affected by biomechanical factors such as *the degree of early prosthetic instability*, *the prosthetic design*, and *the magnitude of the mechanical stress* to which the prosthetic components are exposed during normal daily activity. These stresses vary according to the patient's body weight and level of physical activity. They also vary for different components depending on differing prosthetic neck length, varus/valgus position, impingement, friction and acetabular component eccentricity.

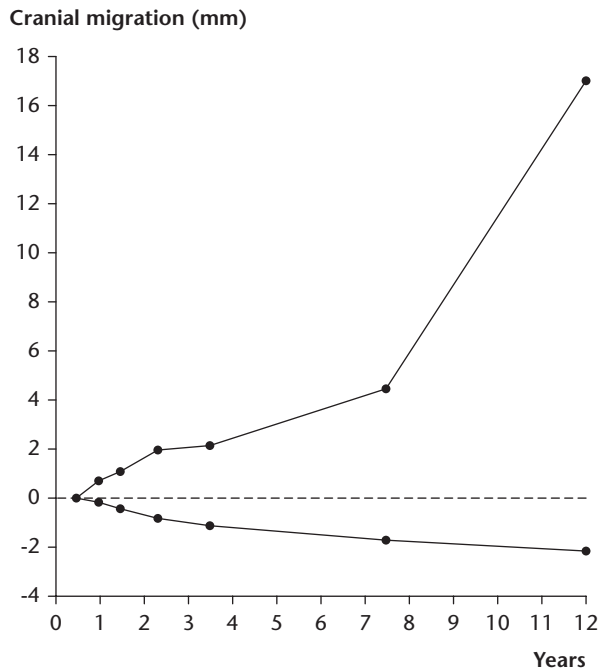
For example, a femoral component with a long neck or in a varus position is exposed to extra high torque during walking and, especially, when climbing stairs and rising from a chair. After initiation of loosening, if all else is equal, such a femoral component can be expected to cause a faster increase in the micromovements and thus to result in an earlier failure than a femoral component with a short neck or in a valgus position. Similarly, an acetabular component with increased eccentricity (due to design or wear) is exposed to higher torque, and therefore (if initiated) a faster progression of loosening and an earlier failure can be expected. Thus, improved wear resistance of the acetabular component (e.g. by using highly cross-linked polyethylene) can, for purely biomechanical reasons, be expected to result in reduced rate of loosening (due to less eccentricity of and hence less torque on the acetabular component).

In short, prosthetic components exposed to higher mechanical stresses (e.g. femoral components with a long neck or in a varus position) can be expected, all else being equal, to be over-represented among prosthetic failures due to faster progression of loosening of the components in which loosening has been initiated. However, individual components (e.g. femoral components with a long neck or in a varus position) can, if loosening has not been initiated, be well-fixed. These expected outcomes are well in line with the epidemiology of clinical failures.

### *Fluid pressure fluctuations and periprosthetic osteolysis*

The micromovements of a loose prosthetic component (e.g. at heel strike) may cause devitalizing spikes of high fluid pressure in the interstice between the component and the bone, which induce periprosthetic osteolysis<sup>27</sup> – by a complex series of inflammatory responses to the damage-associated molecular patterns (DAMPs) of the generated necrotic cells and cell fragments.<sup>28</sup> The periprosthetic osteolysis is thus secondary, and causes additional prosthetic instability, which in turn causes perpetuating increased osteolysis (Fig. 2). The necrotic cells and cell fragments are spread through prosthetic micromovements and may cause inflammatory responses in accessible spaces for the fluid from the periprosthetic interstice – and may, for example, in cases of acetabular component loosening, induce osteolysis of the medial cortex of the femoral neck.

Micromovements may, through spikes of high fluid pressure, force the periprosthetic fluid further into the bone<sup>30</sup> (Fig. 3), where the expelled fluid which contains wear debris and bone detritus will be partially resorbed and invaded by granulation tissue. A similar mechanism, of course, applies to a loose liner in an acetabular shell with screw holes that allow for devitalizing high fluid pressure to form fluid jets through the holes when the hip is loaded.<sup>18,32</sup> Sometimes the periprosthetic fluid is forced into the surrounding soft tissues to form an extrasosseous granuloma.<sup>33</sup>



**Fig. 2** Cranial migration of the acetabular component (above) and distal migration of the head of the femoral component (below) followed by RSA from six months postoperatively until the revision after 12 years. The acetabular component was found to be loose in an eroded cavity and surrounded by a thick layer of dense fibrous connective tissue.

Note. From *Arch Orthop Trauma Surg*<sup>29</sup> with permission.

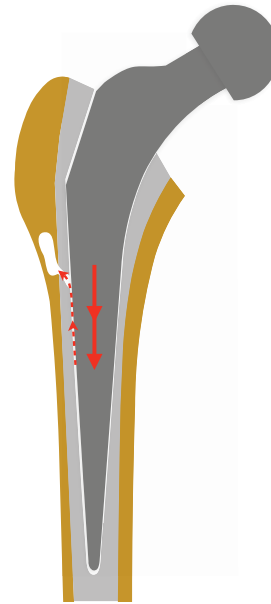
### Late detection of loosening

The prosthetic micromovements and the periprosthetic osteolysis may increase subclinically for a long time. Eventually, the loosening may be detected on standard radiographs to be interpreted as late loosening, but ought to be interpreted as late detection of loosening.

## Other explanations for prosthetic loosening

### Stress-shielding

Stress-shielding of the proximal femur refers to the bone loss commonly seen in distally apparently well-fixed stems (often associated with mid-thigh pain).<sup>34</sup> This proximal bone loss has been presumed to be caused by stress removal (hence the name) and cause impaired prosthetic fixation and eventually late loosening. However, the underlying pathophysiological mechanism remains enigmatic. From a logical point of view, either the proximal bone must be unnecessary for prosthetic fixation and resorption of unloaded proximal bone would not induce loosening, or the proximal bone must be necessary for



**Fig. 3** Drawing to show how prosthetic micromovements (arrows) pump joint fluid (dashed arrows) under high pressure from the gap between the stem and the cement through a defect in the cement mantle. The pressure waves may devitalize the adjacent bone tissue, which is resorbed, thereby causing focal femoral osteolysis.

Note. From *Acta Orthop*<sup>31</sup> with permission.

prosthetic fixation and resorption of unloaded proximal bone would signify inadequate initial proximal fixation.

A more plausible mechanism for the proximal bone resorption is as follows: Although a prosthetic stem would be well-fixed distally, the difference in flexural stiffness between the prosthetic stem and the proximal bone may cause micromovements between the two during daily activities, and the accompanying (sometimes painful) pressure fluctuations in the interstice fluid may cause a bone resorption that gives an illusion of being the result of a proximal stress-shielding.<sup>35</sup> A similar mechanism for proximal bone resorption is of course also applicable to clearly loose femoral components moving around an axis passing near the distal portion of the stem.

### Particle disease

Particle disease, i.e. wear-particle-induced loosening, was proposed because wear particles and numerous macrophages and giant cells were observed in the periprosthetic tissue samples from failed hip prostheses; and because the wear particles were assumed to trigger the inflammatory responses, resulting in periprosthetic osteolysis and ultimately late loosening.<sup>9–16</sup> However, some facts indicate that the causality between wear and loosening may be the reverse, i.e. an increased wear due to

loosening. Firstly, wear particles cannot be the cause of the early prosthetic migration (Fig. 1), which occurs long before any significant amounts of wear particles have been produced. Secondly, wear particles do not appear to cause osteolysis at a stable interface,<sup>36</sup> i.e. in the absence of pressure fluctuations in the interstice fluid. Thirdly, spikes of high fluid pressure may cause osteolysis even in the absence of wear particles.<sup>27</sup> Fourthly, loose prosthetic components typically generate free cement or metal particles that may become trapped in the joint cavity and cause extensive abrasive wear.<sup>37,38</sup>

Thus, wear particles do not appear to cause loosening, but loosening of the acetabular or the femoral component can cause extensive wear, fluid pressure fluctuations and periprosthetic osteolysis. The hypothesis of particle disease appears to have emerged because the inflammatory responses to the DAMPs of the necrotic cells and cell fragments in the periprosthetic tissue samples from failed hip prostheses (as well as in various experimental studies with tissue debris contamination) were misinterpreted as inflammatory responses to wear particles.<sup>31</sup>

#### Metal sensitivity

Metal sensitivity (contact allergy to chromium, cobalt, or nickel) has also been suspected of causing implant failure,<sup>39</sup> but clinical and epidemiological investigations indicate that the risk of hip prosthetic loosening is not increased even in patients with pre-existing metal sensitivity.<sup>40,41</sup> The metal sensitivity associated with prosthetic loosening is probably caused by metal ions released by fretting corrosion and thus secondary to the loosening.

## Conclusions

The theory of early loosening is based on a few postulates that concur with convincing evidence from both clinical and experimental research: poor interlock, poor bone quality, and resorption of a necrotic bone bed may initiate prosthetic loosening; biomechanical factors and periprosthetic osteolysis (due to inflammatory responses to necrotic cells and cell fragments generated by devitalizing spikes of high periprosthetic fluid pressure from an unstable implant) do affect the subsequent progression of loosening. This theory, with its two different phases (early initiation and, if initiated, subsequent progression), can explain the rapid early prosthetic migration, the development of periprosthetic osteolysis and wear granulomas, the bone loss commonly seen in the proximal femur of distally apparently well-fixed stems, the causality between wear and loosening, and largely the epidemiology of clinical failure of hip prostheses – without any need for hypotheses such as stress-shielding, particle disease, and metal sensitivity. The concept of late loosening appears to be a misinterpretation of late-detected loosening.

Although stress-shielding, particle disease, metal sensitivity, and other imaginable explanations for loosening (e.g. endotoxin-induced osteolysis, culture-negative infection), and the existence at all of genuine late onset of loosening can never be completely ruled out (because it is impossible to prove a negative; cf. Russell's teapot), these hypotheses should be avoided – not because they are proven wrong, but because they appear unnecessary. The principle of parsimony (Occam's razor) tells us to choose the simplest scientific explanation that fits the evidence and avoid more complex alternatives.

Clinical implications of the theory of early loosening: atraumatic surgery (possibly supplemented with a locally applied bisphosphonate)<sup>25</sup> and initial prosthetic stability are crucial in ensuring low risk of prosthetic loosening.

#### AUTHOR INFORMATION

Department of Orthopaedics, Lund University, Lund, Sweden.

Correspondence should be sent to: Bengt Mjöberg, Västra Vallgatan 29, SE-27135 Ystad, Sweden.

Email: [bengt.mj@telia.com](mailto:bengt.mj@telia.com)

#### ICMJE CONFLICT OF INTEREST STATEMENT

The author declares no conflict of interest relevant to this work.

#### FUNDING STATEMENT

No benefits in any form have been received or will be received from a commercial party related directly or indirectly to the subject of this article.

#### LICENCE

© 2020 The author(s)

This article is distributed under the terms of the Creative Commons Attribution-Non Commercial 4.0 International (CC BY-NC 4.0) licence (<https://creativecommons.org/licenses/by-nc/4.0/>) which permits non-commercial use, reproduction and distribution of the work without further permission provided the original work is attributed.

#### REFERENCES

1. Selvik G. Roentgen stereophotogrammetry: a method for the study of the kinematics of the skeletal system (Reprint from the original 1974 thesis). *Acta Orthop Scand Suppl* 1989;232:1–51.
2. Mjöberg B. Loosening of the cemented hip prosthesis. *Acta Orthop Scand Suppl* 1986;221:1–40.
3. Ryd L, Albrektsson BE, Carlsson L, et al. Roentgen stereophotogrammetric analysis as a predictor of mechanical loosening of knee prostheses. *J Bone Joint Surg Br* 1995;77-B:377–383.
4. Campbell D, Mercer G, Nilsson KG, Wells V, Field JR, Callary SA. Early migration characteristics of a hydroxyapatite-coated femoral stem: an RSA study. *Int Orthop* 2011;35:483–488.
5. Salemyr M, Muren O, Ahl T, et al. Lower periprosthetic bone loss and good fixation of an ultra-short stem compared to a conventional stem in uncemented total hip arthroplasty. *Acta Orthop* 2015;86:659–666.

6. **Finnilä S, Moritz N, Svedström E, Alm JJ, Aro HT.** Increased migration of uncemented acetabular cups in female total hip arthroplasty patients with low systemic bone mineral density: a 2-year RSA and 8-year radiographic follow-up study of 34 patients. *Acta Orthop* 2016;87:48–54.
7. **Kutzner KP, Pfeil D, Kovacevic MP, et al.** Radiographic alterations in short-stem total hip arthroplasty: a 2-year follow-up study of 216 cases. *Hip Int* 2016;26:278–283.
8. **Murray DW, Gulati A, Gill HS.** Ten-year RSA-measured migration of the Exeter femoral stem. *Bone Joint J* 2013;95-B:605–608.
9. **Goodman SB, Gibon E, Pajarinen J, et al.** Novel biological strategies for treatment of wear particle-induced periprosthetic osteolysis of orthopaedic implants for joint replacement. *J R Soc Interface* 2014;11:20130962.
10. **Steinbeck MJ, Jablonowski LJ, Parvizi J, Freeman TA.** The role of oxidative stress in aseptic loosening of total hip arthroplasties. *J Arthroplasty* 2014;29:843–849.
11. **Singh G, Nuechtern JV, Meyer H, et al.** Particle characterisation and cytokine expression in failed small-diameter metal-on-metal total hip arthroplasties. *Bone Joint J* 2015;97-B:917–923.
12. **Wang Z, Liu N, Shi T, et al.** ER stress mediates TiAl6V4 particle-induced peri-implant osteolysis by promoting RANKL expression in fibroblasts. *PLoS One* 2015;10:e0137774.
13. **Athanasou NA.** The pathobiology and pathology of aseptic implant failure. *Bone Joint Res* 2016;5:162–168.
14. **Kandahari AM, Yang X, Laroche KA, Dighe AS, Pan D, Cui Q.** A review of UHMWPE wear-induced osteolysis: the role for early detection of the immune response. *Bone Res* 2016;4:16014.
15. **Sukur E, Akman YE, Ozturkmen Y, Kucukdurmaz F.** Particle disease: a current review of the biological mechanisms in periprosthetic osteolysis after hip arthroplasty. *Open Orthop J* 2016;10:241–251.
16. **Jämsen E, Kouri VP, Ainola M, et al.** Correlations between macrophage polarizing cytokines, inflammatory mediators, osteoclast activity, and toll-like receptors in tissues around aseptically loosened hip implants. *J Biomed Mater Res A* 2017;105:454–463.
17. **Mjöberg B.** Theories of wear and loosening in hip prostheses: wear-induced loosening vs. loosening-induced wear. *Acta Orthop Scand* 1994;65:361–371.
18. **Mjöberg B.** The theory of early loosening of hip prostheses. *Orthopedics* 1997;20:1169–1175.
19. **Kärrholm J, Borssén B, Löwenhielm G, Snorrason F.** Does early micromotion of femoral stem prosthesis matter? 4–7-year stereoradiographic follow-up of 84 cemented prostheses. *J Bone Joint Surg Br* 1994;76-B:912–917.
20. **Nieuwenhuijse MJ, Valstar ER, Kaptein BL, Nelissen RG.** Good diagnostic performance of early migration as a predictor of late aseptic loosening of acetabular cups: results from ten years of follow-up with Roentgen stereophotogrammetric analysis (RSA). *J Bone Joint Surg Am* 2012;94-A:874–880.
21. **Pijls BG, Nieuwenhuijse MJ, Fiocco M, et al.** Early proximal migration of cups is associated with late revision in THA: a systematic review and meta-analysis of 26 RSA studies and 49 survival studies. *Acta Orthop* 2012;83:583–591.
22. **Klerken T, Mohaddes M, Nemes S, Kärrholm J.** High early migration of the revised acetabular component is a predictor of late cup loosening: 312 cup revisions followed with radiostereometric analysis for 2–20 years. *Hip Int* 2015;25:471–476.
23. **van der Voort P, Pijls BG, Nieuwenhuijse MJ, et al.** Early subsidence of shape-closed hip arthroplasty stems is associated with late revision: a systematic review and meta-analysis of 24 RSA studies and 56 survival studies. *Acta Orthop* 2015;86:575–585.
24. **Johanson PE, Antonsson M, Shareghi B, Kärrholm J.** Early subsidence predicts failure of a cemented femoral stem with minor design changes. *Clin Orthop Relat Res* 2016;474:2221–2229.
25. **Schilcher J, Palm L, Ivarsson I, Aspenberg P.** Local bisphosphonate reduces migration and formation of radiolucent lines adjacent to cemented acetabular components. *Bone Joint J* 2017;99-B:317–324.
26. **Prieto-Alhambra D, Javaid MK, Judge A, et al.** Association between bisphosphonate use and implant survival after primary total arthroplasty of the knee or hip: population based retrospective cohort study. *BMJ* 2011;343:d7222.
27. **Fahlgren A, Bostrom MPG, Yang X, et al.** Fluid pressure and flow as a cause of bone resorption. *Acta Orthop* 2010;81:508–516.
28. **Rock KL, Kono H.** The inflammatory response to cell death. *Annu Rev Pathol* 2008;3:99–126.
29. **Önsten I, Mjöberg B.** Osteolysis, wear and failure of a migrating acetabular component: a roentgen stereophotogram case report. *Arch Orthop Trauma Surg* 1995;114:267–268.
30. **Anthony PP, Gie GA, Howie CR, Ling RS.** Localised endosteal bone lysis in relation to the femoral components of cemented total hip arthroplasties. *J Bone Joint Surg Br* 1990;72-B:971–979.
31. **Mjöberg B.** Does particle disease really exist? *Acta Orthop* 2018;89:130–132.
32. **Manley MT, D'Antonio JA, Capello WN, Edidin AA.** Osteolysis: a disease of access to fixation interfaces. *Clin Orthop Relat Res* 2002;405:129–137.
33. **Reigstad A, Røkkum M.** An intrapelvic granuloma induced by acetabular cup loosening. *Acta Orthop Scand* 1992;63:465–466.
34. **Khanuja HS, Vakil JJ, Goddard MS, Mont MA.** Cementless femoral fixation in total hip arthroplasty. *J Bone Joint Surg Am* 2011;93:500–509.
35. **Mjöberg B.** Is the proximal bone resorption around the femoral stem after hip arthroplasty really caused by reduced stress? *Acta Orthop* 2018;89:128–129, 139.
36. **Aspenberg P, Herbertsson P.** Periprosthetic bone resorption: particles versus movement. *J Bone Joint Surg Br* 1996;78-B:641–646.
37. **McKellop HA, Sarmiento A, Schwinn CP, Ebramzadeh E.** In vivo wear of titanium-alloy hip prostheses. *J Bone Joint Surg Am* 1990;72:512–517.
38. **Wang A, Essner A.** Three-body wear of UHMWPE acetabular cups by PMMA particles against CoCr, alumina and zirconia heads in a hip joint simulator. *Wear* 2001;250:212–216.
39. **Basko-Plluska JL, Thyssen JP, Schallock PC.** Cutaneous and systemic hypersensitivity reactions to metallic implants. *Dermatitis* 2011;22:65–79.
40. **Carlsson Å, Möller H.** Implantation of orthopaedic devices in patients with metal allergy. *Acta Derm Venereol* 1989;69:62–66.
41. **Thyssen JP, Jakobsen SS, Engkilde K, Johansen JD, Søballe K, Menné T.** The association between metal allergy, total hip arthroplasty, and revision. *Acta Orthop* 2009;80:646–652.