

# Bone Remodelling of the Proximal Femur After Hip Revision with a Metaphyseal-Fixation Femoral Stem Component

Zhijie Li<sup>1,2,\*</sup>, Mengnan Li<sup>1,\*</sup>, Xiaowei Yao<sup>3</sup>, Bo Liu<sup>1</sup>, Sikai Liu<sup>1</sup>, Zeming Liu<sup>1</sup>, Binqun Zhang<sup>1</sup>, Yongtai Han<sup>1</sup>

<sup>1</sup>Department of Osteonecrosis and Hip Surgery, Hebei Medical University Third Affiliated Hospital, Shijiazhuang, People's Republic of China;

<sup>2</sup>Orthopedics Department, Affiliated Hospital of Hebei Engineering University, Handan, People's Republic of China; <sup>3</sup>Orthopedics Department, Hebei Provincial Chest Hospital, Shijiazhuang, People's Republic of China

\*These authors contributed equally to this work

Correspondence: Yongtai Han, Email [yongtaihan@foxmail.com](mailto:yongtaihan@foxmail.com)

**Background:** Whether hip revision with a metaphyseal-fixation femoral stem component can restore the bone mass of the proximal femur remains unclear. The aims of this study were to identify whether the bone mineral density (BMD) of the proximal femur increases following hip revision with a metaphyseal-fixation femoral stem and to identify the factors associated with BMD recovery.

**Methods:** This was a retrospective study involving 36 patients who underwent hip arthroplasty with a metaphyseal-diaphyseal fixation stem (standard length stem) and had indications for hip revision, which was performed with a proximal press-fit short-stem prosthesis for each patient. Dual-energy X-ray absorptiometry (DEXA) was used to obtain, evaluate, and compare the BMD at baseline and one year and two years postoperatively. The proximal femur was divided into several independent areas according to the Gruen zone (Gruen 1 to Gruen 7 from the greater trochanter counterclockwise to the lesser trochanter). Logistic regression analyses were used to assess potential factors significantly associated with an increase in BMD.

**Results:** An increased BMD was obviously identified in the proximal femur. Two years after the surgery, the BMD of the Gruen 1, Gruen 2, Gruen 6, and Gruen 7 areas had increased by 22.6%, 12.6%, 16.2% and 24.2%, respectively, relative to baseline. Three independent risk factors associated with bone mineral density recovery were identified: age (OR=1.100, 95% CI=1.005–1.203, P=0.038), osteoporosis (OR=14.921, 95% CI=1.223–182.101, P=0.034) and fair to poor hip function (OR=13.142, 95% CI=1.024–168.582, P=0.048).

**Conclusion:** This study confirms that metaphyseal-fixation stem hip revision can indeed help restore bone mass in the proximal femur, especially in the Gruen 1, Gruen 2, Gruen 6 and Gruen 7 zones. It was also found that advanced age, osteoporosis, and fair to poor hip joint function were three important risk factors affecting the recovery of proximal femur bone mass after surgery.

**Trial Registration:** Retrospectively registered.

**Keywords:** uncemented fixation, hip revision, bone mineral density, metaphyseal-fixation femoral stem component

## Background

The process of hip revision includes removing the original prosthesis and filling the resulting bone deficiency with the goal of reconstructing the normal structure of the proximal femur and achieving stable fixation of the newly implanted prosthesis. However, one major problem following primary arthroplasty is that the rigidity of the femoral component is significantly higher than that of the proximal femoral bone. Therefore, the stress, namely, the load of the body weight, would transfer predominantly via the femoral stem instead of the proximal femoral bone. In other words, the physiological biomechanical environment of the proximal femur is altered in this case. This phenomenon, also called “stress shielding”, can lead to local osteoporosis or bone loss in the proximal femur. Therefore, in addition filling the bone

deficiency and achieving a stable fixation of prosthesis, the physiological biomechanical environment of the proximal femur should also be reconstructed during hip revision.

Unfortunately, in traditional hip revision surgery, this goal is rarely achieved. Paprosky et al suggested that to achieve an initial stable fixation during the revision surgery, the newly implanted prosthesis should be a fully coated metaphyseal-diaphyseal fixation stem (such as Corail from DePuy) or even a diaphyseal fixation stem.<sup>1</sup> However, implantation of a lengthened stem would result in an aggressive concentration of stress in the local bone at the distal level of the stem. Correspondingly, obvious stress shielding can be identified in the proximal femur, which might cause bone remodelling, osteoporosis and, in some cases, even early loosening of the prosthesis<sup>2,3</sup> and the need for re-revision surgery.<sup>4</sup> To overcome this crucial issue, some studies have suggested that the fixation segment of the newly implanted stem should be limited to the local proximal femur. Therefore, short stems, which refer to femoral stems whose total length is less than twice the vertical distance from the tip of the greater trochanter to the bottom of the lesser trochanter, were introduced to hip revision surgery.<sup>5</sup> Theoretically, this would reduce the stress shielding and the subsequent bone remodelling of the proximal femur,<sup>6-9</sup> even bone mass recovery. However, in the real world, whether bone mass recovery occurs in the proximal femurs of patients after short-stem revision and the factors associated with the bone mass recovery remain poorly described.

In some previous studies, bone remodelling was investigated via postoperative X-ray exams. However, it is difficult to accurately evaluate bone remodelling using this method.<sup>10-12</sup> In this study, changes in local bone mineral density (BMD) were investigated via dual-energy X-ray absorptiometry (DEXA), which is considered to be a highly accurate method for evaluating the areal BMD.<sup>13</sup> Subsequently, the bone remodelling of the proximal femur was investigated in patients who underwent hip revision with a metaphyseal-fixation femoral stem (Tri-lock from DePuy) to identify whether they experienced bone mass recovery. The research questions were 1) to identify whether the BMD of the proximal femur would increase following hip revision with a metaphyseal-fixation femoral stem; 2) to determine the predominant BMD recovery location of the proximal femur; and 3) to identify the factors associated with BMD recovery.

## Methods

### Participants

This study retrospectively analysed patients who underwent hip revisions from January 2016 to January 2020. The inclusion criteria were as follows: 1) hip revision surgery with a proximal press-fit short-stem prosthesis, including replacement of both the femoral and acetabular components during revision and retention of the acetabular component while replacing only the femoral component; and 2) aseptic loosening as the revision indicator. The exclusion criteria were 1) lack of bone mineral density testing after surgery and 2) less than two years of bone mineral density testing. After applying the inclusion and exclusion criteria, a total of 36 patients were finally included in this study. The demographic information and characteristics of the primary hip arthroplasty patients were summarized in [Table 1](#).

The study was approved by the Institutional Review Board of the Third Hospital of Hebei Medical University and was conducted in accordance with the Declaration of Helsinki and the Health Insurance Portability and Accountability Act (HIPAA). Before the last follow-up, we obtained the patients' written informed consent. A total of 41 patients underwent revision surgery for implantation of a short-stem prosthesis for aseptic loosening of the femoral component. Five patients were excluded based on the exclusion criteria. One patient had an intraoperative periprosthetic fracture; the prosthesis was loosened early at 3 months after surgery, and secondary revision with a longer cement prosthesis was performed. One patient died 11 months after surgery because of cardiovascular disorder. The remaining three patients demonstrated osteoporosis of the proximal femur; prebundling with steel wire was performed intraoperatively to prevent proximal femur fracture caused by intraoperative prosthesis implantation; the wire binding affected the femoral bone densitometry, so no postoperative BMD test was performed.

A total of 36 patients were further analysed in this study. There were 19 men and 17 women aged  $57.64 \pm 14.09$  years. The average BMI was  $23.44 \pm 1.72$  kg/m<sup>2</sup>. Preoperatively, osteoporosis was found in 11 patients, and femur head necrosis was the main cause of primary arthroplasty in this study, observed in 55.6% of all included individuals (20/36). Cement fixation was performed in 11 patients, and uncemented fixation was used for 25 patients. Metaphyseal-diaphyseal fixation

**Table 1** Demographic Information and Features of Primary Hip Arthroplasty in Patients Undergoing Hip Revision with a Short Femoral Stem

Characteristics		Significant Bone Mass Restoration (n=15)	Nonsignificant Bone Mass Restoration (n=21)	Total (n=36)	Test Statistics	P
Age (years)		49.40±12.63	63.52±12.18		-2.636	0.007
Sex	Male	8	11	19		
	Female	7	10	17		
Body mass index		23.60±2.99	23.33±1.75		-0.468	0.643
Smoking	No	10	15	25		1.000 <sup>#</sup>
	Yes	5	6	11		
Alcohol	No	10	16	26		0.709 <sup>#</sup>
	Yes	5	5	10		
Diabetes	No	12	17	29		1.000 <sup>#</sup>
	Yes	3	4	7		
Rheumatism	No	14	19	33		1.000 <sup>#</sup>
	Yes	1	2	3		
Osteoporosis	No	14	11	25	5.120	0.024
	Yes	1	10	11		
Indication for primary hip arthroplasty	Osteonecrosis	9	11	20	1.324	0.857
	Femoral neck fracture	1	4	5		
	Osteoarthritis	2	2	4		
	Hip dysplasia	2	3	5		
	Other	1	1	2		
Stem fixation for primary hip arthroplasty	Cemented	4	7	11	0.004	0.951
	Uncemented	11	14	25		
Stem fixation segment for primary hip arthroplasty	Metaphysis	2	3	5		1.000 <sup>#</sup>
	Metaphysis-Diaphysis	13	18	31		
	Diaphysis	0	0	0		
Bearing	Ceramic-Ceramic	5	6	11		1.000 <sup>#</sup>
	Ceramic-Polyethylene	10	15	25		
	Metal-Polyethylene	0	0	0		

Note: <sup>#</sup>Fisher's exact test.

was most frequently selected in primary total hip arthroplasty (THA). The number of patients in the two groups who smoked, consumed alcohol, and had other comorbidities is shown in Table 1. All patients underwent surgery through the posterior approach: 26 patients underwent acetabular revision, and 10 patients only underwent revision surgery with a femoral stem. Cancellous bone grafting was performed for 13/36 patients. Femoral bone defects were classified according to the Paprosky classification system intraoperatively. Femoral defects and other surgery and postoperative conditions are shown in Table 2. The mean Harris score at the two-year follow-up was  $85.83 \pm 7.4$ , with an overall excellent rate of 72.2%.

## Surgical Procedure and Rehabilitation

All procedures were performed by the same experienced and professionally trained hip surgeon. All operations were performed through the posterior approach. First, the previous femoral prosthesis was removed. Because in this study, the revision indication in all patients was aseptic loosening, all the femoral stems were successfully removed by direct extraction, and no proximal femoral osteotomy was performed. Subsequently, the granulation tissue and bone cement in the medullary cavity were cleaned, and the bone defect of the proximal femur was evaluated. The bone defect was classified according to the Paprosky classification,<sup>14</sup> and the defect type was recorded in the medical record. We selected only Paprosky types I, II, and III A patients with less severe proximal bone defects for implantation of short femoral stems. The stability of the different prostheses was tested by reaming the prosthesis from small to large using broaches. As with the primary replacement, we assessed the stability of the prosthesis by its ability to obtain a medial-lateral press

**Table 2** Characteristics of the Surgical Process and Rehabilitation in Patients Undergoing Hip Revision with a Short Femoral Stem

Characteristics		Patients who Underwent Revision with a Short Femoral Stem (n=36)
Acetabular component revision	No	10
	Yes	26
Femoral bone deficiency	Type I	6
	Type II	27
	Type III A	3
Femoral bone grafting	No	23
	Yes	13
Weight-bearing time	<3 weeks	6
	3 weeks - 3 months	21
	>3 months	9
Antiosteoporosis therapy	No	23
	Yes	13
Hip function	Excellent-Good	26
	Fair-Poor	10

fit with axial and rotational stability. Stability was assessed through the surgeon's subjective feedback and experience. If sufficient initial stability was not obtained, a lengthened diaphyseal fixation prosthesis was used. If a surrounding gap between the broach and the proximal femur was observed, bone grafting was performed to restore the proximal bone mass and further increase the initial stability of the prosthesis. After testing the prosthesis size with sufficient stability, we placed a one-size smaller broach in the medullary cavity, pressed the bone graft around it, filled the position of the bone defect, and then inserted the stem. Subsequently, the stability of the prosthesis was tested to ensure a good press fit for the proximal femur.

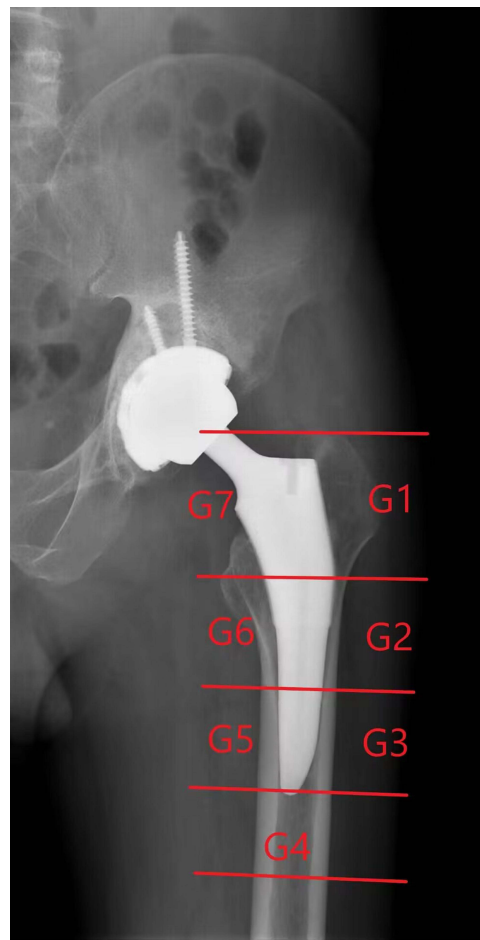
In all patients included in the study, the DePuy Tri-lock (BPS) prosthesis was used, which is a tapered proximal porous-coated stem implanted with a proximal press-fit technique. The proximal end adopts a triple locking mechanism to achieve stable initial prosthesis stability and achieve better bone ingrowth. The stem is a short-stem prosthesis, and the overall length and distal part of the coating are shorter, allowing retention of more bone in the proximal femur. Acetabular prostheses are porous coated and were implanted using a compression fit technique with or without screws.

Within 8 weeks after the operation, the patients were encouraged to use crutches to partially bear weight, and after 8 weeks, they could completely practice independent walking without crutches. All patients received a routine post-operative rehabilitation regimen, including range of motion exercises, progressive abductor strengthening, and gait. The characteristics of the surgical process and rehabilitation are shown in [Table 2](#).

## Outcome

All patients were followed up at 1 month, 3 months, 6 months, 12 months, and annually after surgery. Clinical efficacy was assessed using the Harris scoring system. The HHS ranges from 0 to 100 and is divided into excellent (90–100), good (80–89), fair (70–79) and poor (<70). We also accessed all patient demographic information through our healthcare facility's picture archiving and communication system (PACS).

We regularly performed BMD measurements in postrevision patients. All studies were performed with dual-energy X-ray absorptiometry scans using the Hologic Discovery (Hologic Inc., Waltham, MA, USA) DEXA scanner at our medical facility. Preoperative scans included lumbar spine (L1eL4) and bilateral hip scans to assess BMD. Periprosthetic BMD (g/cm<sup>2</sup>) was measured using the Orthopaedic Hip Analysis scan mode, which automatically identifies the implant metal and surrounding bone. The traditional Gruen area<sup>15</sup> is automatically adapted to the short handle design by software ([Figure 1](#)). Individual regions of interest for each patient were saved in the system and used for all subsequent measurements to reduce bias. The patient was examined in the supine position with mild



**Figure 1** Dual-energy X-ray absorptiometry images with Gruen zone schemes.

internal rotation of both lower extremities. Since lower extremity rotation has a great influence on BMD measurement, all patients' feet were fixed in a dedicated fixation device to obtain repeatable rotation to limit rotation measurement error in the BMD measurement.<sup>16</sup> The first postoperative scan was performed within one week of surgery and was used as the baseline for subsequent studies of BMD changes. The BMD was measured again 12 months and 24 months after the operation.

## Quality Control

To reduce measurement errors, we performed quality control on the DEXA equipment every morning to verify system stability, as specified by the manufacturer's guidelines. All results were reviewed by 2 experienced radiologists and then averaged. To test for interobserver and interobserver reproducibility, each measurement was performed independently and again after 1 week. In this study, all intraclass correlation coefficients used to assess reproducibility were  $>0.9$ .

## Statistical Analysis

Statistical analyses were performed using SPSS version 19.0 statistical software for Windows (IBM, Armonk, New York). Continuous variables are expressed as the mean $\pm$ SD, and categorical variables are expressed as frequencies. The Mann–Whitney *U*-test and Friedman test were used for comparisons between continuous variables, and the chi-square test was used for comparing categorical variables. Logistic regression analyses were used to assess potential factors significantly associated with increases in the BMD. A *P* value less than 0.05 was considered to be significant.

## Results

### Bone Remodelling

One year postoperatively, the DEXA results demonstrated that compared with the baseline BMD level, the BMD in the G1, G2, G6, and G7 regions of the proximal femur had increased one week after surgery by 13.2% ( $0.60 \pm 0.11$  vs  $0.53 \pm 0.12$ ,  $P < 0.001$ ), 9% ( $1.21 \pm 0.23$  vs  $1.11 \pm 0.25$ ,  $P < 0.001$ ), 11.4% ( $1.17 \pm 0.17$  vs  $1.05 \pm 0.22$ ,  $P < 0.001$ ), and 16.7% ( $0.77 \pm 0.18$  vs  $0.66 \pm 0.21$ ,  $P < 0.001$ ), respectively, while the BMD in the G3, G4, and G5 areas, located at the distal end of the prosthesis, increased by 3.7% ( $1.40 \pm 0.17$  vs  $1.35 \pm 0.21$ ,  $P < 0.001$ ), 3.5% ( $1.47 \pm 0.16$  vs  $1.42 \pm 0.18$ ,  $P < 0.001$ ), and 6.8% ( $1.41 \pm 0.18$  vs  $1.32 \pm 0.21$ ,  $P < 0.001$ ), respectively. The BMD in every Gruen region increased significantly one year after surgery compared with the baseline level. Two years after the surgery, the BMD of the proximal femur in the G1, G2, G6, and G7 areas was still increasing, with changes of 22.6% ( $0.65 \pm 0.10$  vs  $0.53 \pm 0.12$ ,  $P < 0.001$ ), 12.6% ( $1.25 \pm 0.22$  vs  $1.11 \pm 0.25$ ,  $P < 0.001$ ), 16.2% ( $1.22 \pm 0.16$  vs  $1.05 \pm 0.22$ ,  $P < 0.001$ ) and 24.2% ( $0.82 \pm 0.17$  vs  $0.66 \pm 0.21$ ,  $P < 0.001$ ), respectively, relative to baseline. However, in the G3, G4 and G5 areas at the distal end of the prosthesis, compared with that 1 year postoperatively, the BMD two years after surgery had not increased significantly, showing increases of only 4.4% ( $1.41 \pm 0.17$  vs  $1.35 \pm 0.21$ ,  $P < 0.001$ ), 4.2% ( $1.48 \pm 0.15$  vs  $1.42 \pm 0.18$ ,  $P < 0.001$ ), and 7.6% ( $1.42 \pm 0.17$  vs  $1.32 \pm 0.21$ ,  $P < 0.001$ ) with respect to the baseline, respectively. The details of the BMD changes are shown in Table 3 and Figure 2.

### Factors Influencing Bone Remodelling

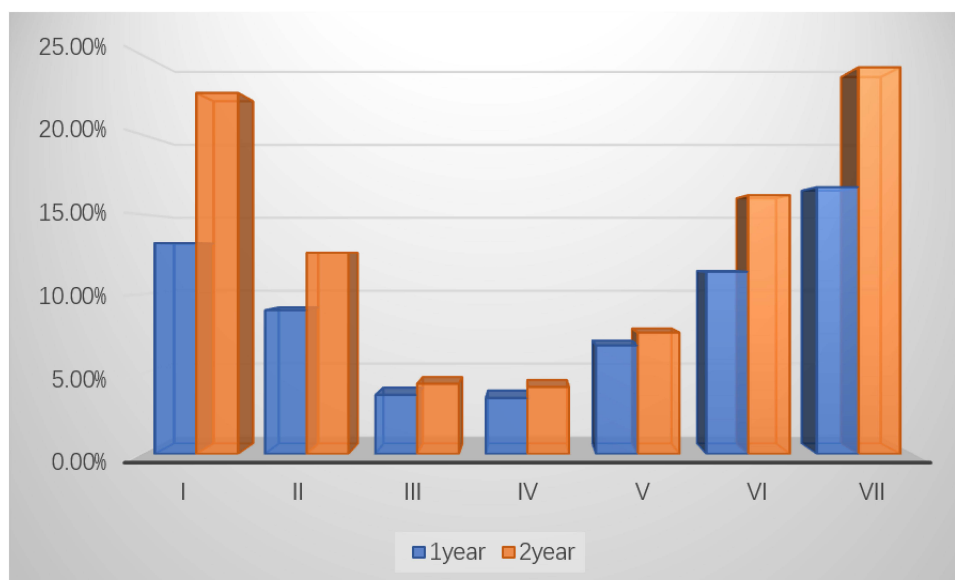
Two major factors associated with the increased BMD were analysed. The first is anti-osteoporotic treatment, such as bisphosphonates, teriparatide and other molecules. Our study found that anti-osteoporotic treatment did not significantly increase BMD ( $t=0.086$ ,  $P=0.769$ ) (Table 4). Therefore, we infer that antiosteoporotic treatment has no obvious correlation with the increased BMD. The other is bone grafting. Similar to antiosteoporotic treatment, there was also no significant difference in the increase in BMD with or without bone graft ( $t=0.169$ ,  $P=0.681$ ). Therefore, this study concluded that there was no significant difference between the group treated with antiosteoporotic drugs and the untreated group.

For multifactor analysis, a multivariate regression model was built. The interesting event was the >27% increase in BMD in Gruen 7. Three independent risk factors associated with bone mineral density recovery were identified: age, osteoporosis, and hip function. First, in this study, every year of age increase was associated with an approximately 10% increase in the risk of statistically insignificant recovery of bone mineral density (OR=1.100, 95% CI=1.005–1.203,  $P=0.038$ ). Second, patients with osteoporosis were 14.9-fold more likely to have statistically insignificant postoperative

**Table 3** Bone Remodelling (Change in Bone Mineral Density) After Surgery in Patients Undergoing Hip Revision with a Short Femoral Stem

Gruen Zone		Immediately After Revision ( $\text{g/cm}^3$ )	1 Year After Revision ( $\text{g/cm}^3$ )	P	2 Years After Revision ( $\text{g/cm}^3$ )	P*	P#
Absolute value	I	$0.53 \pm 0.12$	$0.60 \pm 0.11$	<0.001	$0.65 \pm 0.10$	<0.001	<0.001
	II	$1.11 \pm 0.25$	$1.21 \pm 0.23$	<0.001	$1.25 \pm 0.22$	<0.001	<0.001
	III	$1.35 \pm 0.21$	$1.40 \pm 0.17$	<0.001	$1.41 \pm 0.17$	<0.001	0.231
	IV	$1.42 \pm 0.18$	$1.47 \pm 0.16$	<0.001	$1.48 \pm 0.15$	<0.001	0.065
	V	$1.32 \pm 0.21$	$1.41 \pm 0.18$	<0.001	$1.42 \pm 0.17$	<0.001	1.000
	VI	$1.05 \pm 0.22$	$1.17 \pm 0.17$	<0.001	$1.22 \pm 0.16$	<0.001	<0.001
	VII	$0.66 \pm 0.21$	$0.77 \pm 0.18$	<0.001	$0.82 \pm 0.17$	<0.001	<0.001
Percentage	I	100%	113.2%		122.6%		
	II	100%	109%		112.6%		
	III	100%	103.7%		104.4%		
	IV	100%	103.5%		104.2%		
	V	100%	106.8%		107.6%		
	VI	100%	111.4%		116.2%		
	VII	100%	116.7%		124.2%		

Notes: \*Comparison with bone mineral density immediately after surgery, #Comparison with bone mineral density 1 year after surgery.



**Figure 2** Pattern of BMD changes during the follow-up for all 7 regions of interest.

bone mineral density recovery than those without osteoporosis (OR=14.921, 95% CI=1.223–182.101, P=0.034). Finally, fair to poor hip function was also an independent factor affecting the recovery of bone mineral density (OR=13.142, 95% CI=1.024–168.582, P=0.048). Two years after surgery, patients with hip function scores less than 80 were 13.1-fold more likely to have poor bone mineral density recovery than patients with excellent or good hip function scores. These independent risk factors, odds ratios, and 95% confidence intervals are shown in Table 5.

## Discussion

### Bone Remodelling After Hip Revision with a Metaphyseal-Fixation Stem

This study provides quantitative DEXA and BMD analyses to further define femoral bone remodelling after the use of short-stem prostheses for hip revision. Several studies have suggested that postoperative bone remodelling mainly occurs two years after surgery.<sup>17–19</sup> Therefore, we mainly observed changes in BMD in patients within two years after surgery. The results of our study clearly indicate that the bone mineral density of the proximal femur increases gradually after revision, indicating that short-stem revision can help restore the bone mass of the proximal femur.

By investigating the BMD of the proximal femur, it was found that one year after the surgery, the bone mineral density of the G1-7 area around the prosthesis was greater than that one week after the operation. We believe that this is related to the well-recovered stress loading of the proximal femur after replacement of the stable femoral component as well as to the significantly improved hip function and increased activity level of the patient.<sup>2</sup> Decreased BMD around a loose hip femoral prosthesis is related to many factors. Proximal femoral stress shielding can cause a gradual decrease in proximal femoral BMD after primary replacement.<sup>2,9</sup> In addition, after prosthesis loosening, the proximal femoral

**Table 4** Effect of Antiosteoporotic Treatment and Bone Grafting on Increases in BMD

	Antiosteoporotic Treatment		Bone Grafting	
	Yes	No	Yes	No
Significant bone mass restoration (n=15)	5	10	6	9
Nonsignificant bone mass restoration (n=21)	8	13	7	14
t	0.086		0.169	
P	0.769		0.681	



**Table 5** Independent Factors Associated with Significant Bone Mass Restoration of the Proximal Femur in Patients Undergoing Hip Revision with a Short Femoral Stem

Factors	OR	95% CI for OR	P
Age	1.100	1.005–1.203	0.038
Osteoporosis			
No (Ref.)			
Yes	14.921	1.223–182.101	0.034
Hip function			
Excellent-Good (Ref.)			
Fair-Poor	13.142	1.024–168.582	0.048

**Abbreviations:** OR, odds ratio; CI, confidence interval.

bone loses good stress stimulation, which further aggravates the loss of proximal bone density.<sup>16</sup> Loosening of the hip prosthesis also causes hip pain, decreased function, and a decrease in the patient's activity level. Disuse osteoporosis of the femur may occur, which also results in a decrease in bone density.

The results of this study demonstrated that the BMD of the proximal femur increased significantly in the G1, G7, G2, and G6 regions after revision, and the percentage of BMD at two years after surgery was still significantly higher than that at one year after surgery. There was no further increase in bone mineral density at the distal end of the prosthesis. Previous studies have found that after prosthesis loosening, the proximal femur loses more bone,<sup>16</sup> so there is more room for bone density recovery after revision. In addition, it was further confirmed that the metaphyseal-fixation short-stem prosthesis mainly conducts stress to the proximal femur after revision and rarely undergoes stress shielding after surgery, which results in distal bone hypertrophy and bone loss in the proximal femur. Lacko Marek<sup>20</sup> compared the changes in bone mineral density around the prosthesis after primary arthroplasty with short-stem and ordinary prostheses and found that the proximal femoral bone density also decreased after short-stem prosthesis implantation. Bone density decreased more at the proximal end, and it is believed that short-stem prostheses can restore a more natural proximal force than traditional long-stem prostheses. Gasbarra et al<sup>21</sup> also found that compared with the standard-length prosthesis, the short-stemmed prosthesis (Fitmore) (Zimmer, Inc; Warsaw, IN) resulted in less postoperative BMD decrease in Gruen 1–7 and even greater BMD in G1 and G7 relative to the preoperative BMD. It is also believed that short-stem prostheses mainly conduct stress to the proximal femur to prevent stress shielding. No previous studies have identified postrevision bone remodelling using DEXA; instead, some used X-ray films for stress shielding and bone regeneration studies.<sup>9,22</sup> However, X-ray films are not sufficiently sensitive for evaluating bone mineral density changes.<sup>11,12</sup> Enget et al used postoperative X-ray films to evaluate and grade stress shielding of the proximal femur.<sup>23</sup> Moreland and Bernstein reported<sup>24</sup> that after 144 hip revisions using a wide-coated stem, mild stress shadowing occurred in the proximal femur in 50.7% (73) of cases and in 7.6% (11) of cases of severe stress masking. However, the study by Roger H.<sup>9</sup> found that the proximal stress shielding rate was only 11% after revision with a proximal coated prosthesis, and there was no severe stress shielding. Roger H. also suggested that the proximal coated prosthesis can reduce the incidence of postoperative stress shielding, which is similar to our findings. During revision, a metaphyseal-fixation stem should be used to avoid further loss of the proximal femur bone after surgery.

## Factors Associated with Postoperative Increases in BMD

Due to the fact that a previous study demonstrated that the most significant change in BMD occurred in the G7 area, in this study, the change in bone mineral density in the G7 area was used to analyse the related influencing factors. A previous study found that in the case of stem loosening after regular primary THA, the bone density in the G7 area of the loose prosthesis decreased by approximately 31% compared with that without loosening.<sup>16</sup> If the bone density of the G7 area after revision is to be restored to the state without loosening, theoretically, the bone density after loosening should be increased by up to 45%. Because recovery of the BMD after revision is affected by many factors, an ideal



increase in BMD is difficult to achieve. Therefore, we believe that a bone mineral density increase in the G7 area of more than 27% (60% of the theoretical increase in bone density) two years after revision with respect to that one week after surgery should be regarded as a significant recovery of BMD. Accordingly, a multivariate regression model was built to further investigate the factors associated with BMD recovery.

The first is age. Although patients undergoing hip revision surgery tend to be younger, older revision patients still account for a large proportion.<sup>25</sup> Age is a specific factor associated with decreased bone strength, fragility, osteoporosis<sup>26,27</sup> and, notably, osteogenesis. Gibon<sup>28</sup> suggested that an increase in age is accompanied by an increase in the basic state of inflammation, which may affect the physiological process of human osteogenesis. Studies have shown that femoral neck fractures in elderly patients have difficulty achieving bony union.<sup>29,30</sup> The second factor influencing BMD recovery after revision is osteoporosis. The pathophysiology of osteoporosis mainly involves a dynamic imbalance between bone resorption and formation. Osteoclasts are more active than osteoblasts in patients with osteoporosis, which affects recovery of the proximal femoral bone mineral density after revision surgery. While osteoporosis also affects prosthesis stability, Aro et al<sup>31</sup> reported that patients with lower bone mass achieved higher prosthesis settlement during the first 3 months after THA, while osteoporosis was identified as a risk factor affecting bone ingrowth and long-term stability for uncemented prostheses. Studies have found that postoperative use of antiosteoporosis drugs can reduce the loss of periprosthetic bone mineral density in patients with osteoporosis after primary replacement.<sup>32</sup> Although our findings showed that the application of antiosteoporosis drugs after revision surgery had no significant effect on bone mineral density recovery (considering factors such as the small sample size), we considered that in patients with preoperative osteoporosis, revision surgery should be followed up with antiosteoporosis drugs. The third influencing factor was hip function. After short-stem revision, patients with excellent hip function scores had better proximal femoral bone mineral density recovery than patients with lower functional scores, which may be related to the different postoperative weight-bearing conditions of the affected limbs. Patients with good hip function recovery after surgery were more active, the proximal femur was stimulated by more stress, and the bone density gradually recovered. Patients with poor hip joint function after surgery, due to pain and other reasons, are more inclined to bear weight on the unaffected side and less on the affected side, which may have affected the recovery of bone mineral density at the proximal femur.

## Limitations

Our study also has many shortcomings: 1. The sample size of our study is relatively small, and it is impossible to determine whether the same conclusion could be drawn with a large sample. 2. There was no control group. 3. Only a two-year follow-up study was conducted; given the short study time, the long-term bone remodelling results could not be determined.

## Conclusion

In conclusion, our study confirms that metaphyseal-fixation stem hip revision can indeed help restore bone mass in the proximal femur. The increases in bone mineral density after surgery mainly occurred in the Gruen 1, Gruen 2, Gruen 6 and Gruen 7 zones of the proximal femur. In other regions, slight increases in BMD were also identified. We also found that advanced age, osteoporosis, and fair to poor hip joint function were three important risk factors affecting recovery of proximal femur bone mass after surgery.

## Abbreviations

BMD, bone mineral density; DEXA, dual-energy X-ray absorptiometry; HIPAA, Health Insurance Portability and Accountability Act; PACS, picture archiving and communication system; THA, total hip arthroplasty.

## Data Sharing Statement

The datasets generated and analysed during the current study are not publicly available due patient privacy concerns but are available from the corresponding author on reasonable request.

## Ethics Approval and Consent to Participate

The study was approved by the Institutional Review Board of the Third Hospital of Hebei Medical University and was conducted in accordance with the Declaration of Helsinki and the Health Insurance Portability and Accountability Act (HIPAA). Before the last follow-up, we obtained the patients' written informed consent.

## Funding

There is no funding to report.

## Disclosure

The authors declare that they have no competing interests in this work.

## References

- Paprosky WG, Greidanus NV, Antoniou J. Minimum 10-year +results of extensively porouscoated stems in revision Hip arthroplasty. *Clin Orthop*. 1999;369:230. doi:10.1097/00003086-199912000-00024
- MacDonald SJ, Rosenzweig S, Guerin JS, et al. Proximally versus fully porous-coated femoral stems: a multicenter randomized trial. *Clin Orthop Relat Res*. 2010;468(2):424. doi:10.1007/s11999-009-1092-3
- Chen JH, Liu C, You L, Simmons CA. Bony up on Wolff's law: mechanical regulation of the cells that make and maintain bone. *J Biomech*. 2010;43:108e18. doi:10.1016/j.jbiomech.2009.09.016
- Krishnamurthy AB, MacDonald SJ, Paprosky WG. 5- to 13-year follow-up study on cementless femoral components in revision surgery. *J Arthroplasty*. 1997;12:839–847. doi:10.1016/S0883-5403(97)90152-2
- Feyen H, Shimmin AJ. Is the length of the femoral component important in primary total Hip replacement? *Bone Jt J*. 2014;96(4):442–448. doi:10.1302/0301-620X.96B4.33036
- Bohm P, Bischel O. The use of tapered stems for femoral revision surgery. *Clin Orthop Relat Res*. 2004;420:148e59.
- Young PS, Middleton RG, Learmonth ID, et al. Conversion of a long distally fixed uncemented revision femoral stem to a proximally fixed implant following fatigue fracture. *Hip Int*. 2011;21(6):766. doi:10.5301/HIP.2011.8859
- Khanuja HS, Issa K, Naziri Q, Banerjee S, Delanois RE, Mont MA. Results of a tapered proximally-coated primary cementless stem for revision Hip surgery. *J Arthroplasty*. 2014;29(1):225–228. doi:10.1016/j.arth.2013.04.025
- Emerson RH, Head WC, Higgins LL. Clinical and radiographic analysis of the Mallory Head femoral component in revision total Hip arthroplasty. A minimum 8.8-year and average eleven-year follow-up study. *J Bone Joint Surg Am*. 2003;85(10):1921–1926. doi:10.2106/00004623-200310000-00009
- Freitag T, Hein MA, Wernerus D, Reichel H, Bieger R. Bone remodelling after femoral short stem implantation in total Hip arthroplasty: 1-year results from a randomized DEXA study. *Arch Orthop Trauma Surg*. 2016;136(1):125–130. doi:10.1007/s00402-015-2370-z
- Engh CA, McGovern TF, Schmidt LM. Roentgenographic densitometry of bone adjacent to a femoral prosthesis. *Clin Orthop*. 1993;292:177–190. doi:10.1097/00003086-199307000-00023
- West JD, Mayor MB, Collier JP. Potential errors inherent in quantitative densitometric analysis of orthopaedic radiographs: a study after total Hip arthroplasty. *J Bone Joint Surg*. 1987;69:58–64. doi:10.2106/00004623-198769010-00010
- Hochreiter J, Mattiassich G, Ortmaier R, Steinmair M, Anderl C. Femoral bone remodeling after short-stem total Hip arthroplasty: a prospective densitometric study. *Int Orthop*. 2020;44(4):753–759. doi:10.1007/s00264-020-04486-0
- Sheth NP, Nelson CL, Paprosky WG. Femoral bone loss in revision total Hip arthroplasty: evaluation and management. *J Am Acad Orthop Surg*. 2013;21(10):601–612. doi:10.5435/JAAOS-21-10-601
- Gruen TA, McNeicep GM, Amstutz HC. "Modes of failure" of cemented stem-type femoral components. A radiographic analysis of loosening. *Clin Orthop Relat Res*. 1979;141:17e27.
- Martini F, Leberherz C, Mayer F, et al. Precision of the measurements of periprosthetic bone mineral density in hips with a custom-made femoral stem. *J Bone Joint Surg Br*. 2000;82:1065e1071. doi:10.1302/0301-620X.82B7.0821065
- Wilkinson JM, Hamer AJ, Rogers A, Stockley I, Eastell R. Bone mineral density and biochemical markers of bone turnover in aseptic loosening after total Hip arthroplasty. *J Orthop Res*. 2003;21(4):691–696. doi:10.1016/S0736-0266(02)00237-1
- Aldinger PR, Sabo D, Pritsch M, et al. Pattern of periprosthetic bone remodeling around stable uncemented tapered Hip stems: a prospective 84-month follow-up study and a median 156-month cross-sectional study with DXA. *Calcif Tissue Int*. 2003;73(2):115–121. doi:10.1007/s00223-002-2036-z
- Kilgus DJ, Shimaoka EE, Tipton JS, Eberle RW. Dual-energy X-ray absorptiometry measurement of bone mineral density around porous-coated cementless femoral implants. Methods and preliminary results. *J Bone Joint Surg Br*. 1993;75(2):279–287. doi:10.1302/0301-620X.75B2.8444950
- Lacko M, Filip V, Gharaibeh A, Lackova A, Folvarsky M, Zamborsky R. Comparison of bone remodelling around short stem and conventional straight stem in total Hip replacement: a prospective randomized radiographic and dual-energy X-ray absorptiometric study. *Bratisl Lek Listy*. 2021;122(8):548–554. doi:10.4149/BLL\_2021\_087
- Gasbarra E, Celi M, Perrone FL, et al. Osseointegration of Fitmore stem in total Hip arthroplasty. *J Clin Densitom*. 2014;17(2):307–313. doi:10.1016/j.jocd.2013.11.001
- Gutiérrez Del Alamo J, Garcia-Cimbrello E, Castellanos V, Gil-Garay E. Radiographic bone regeneration and clinical outcome with the Wagner SL revision stem: a 5-year to 12-year follow-up study. *J Arthroplasty*. 2007;22(4):515–524. doi:10.1016/j.arth.2006.04.029
- Engh CA, Bobyn JD, Glassman AH. Porous-coated Hip replacement. The factors governing bone ingrowth, stress shielding, and clinical results. *J Bone Joint Surg Br*. 1987;69:45–55. doi:10.1302/0301-620X.69B1.3818732
- Moreland JR, Bernstein ML. Femoral revision Hip arthroplasty with uncemented, porous-coated stems. *Clin Orthop*. 1995;319:141–150.
- Schwartz AM, Farley KX, Guild GN, Bradbury TL. Projections and epidemiology of revision hip and knee arthroplasty in the United States to 2030. *J Arthroplasty*. 2020;35(6S):S79–S85. doi:10.1016/j.arth.2020.02.030

26. Burger H, Van Daele PL, Odling E, et al. Association of radiographically evident osteoarthritis with higher bone mineral density and increased bone loss with age. *Rotterdam Study Arthritis Rheum*. 1996;39(1):81–86. doi:10.1002/art.1780390111
27. David BB. Muscle strength, bone mass, and age-related bone loss. *J Bone Miner Res*. 1997;12(10):1547–1551. doi:10.1359/jbmr.1997.12.10.1547
28. Gibon E, Lu LY, Nathan K, Goodman SB. Inflammation, ageing, and bone regeneration. *J Orthop Translat*. 2017;10:28–35. doi:10.1016/j.jot.2017.04.002
29. Mitani Y. Effective treatment of a steroid-induced femoral neck fracture nonunion with a once-weekly administration of teriparatide in a rheuma-toid patient: a case report. *Arch Osteoporos*. 2013;8:131. doi:10.1007/s11657-013-0131-6
30. Kang JS, Jeon YS, Ahn CH, Roh TH. Osteosynthesis versus endoprosthesis for the treatment of femoral neck fracture in Asian elderly patients. *BMC Musculoskelet Disord*. 2016;17:264. doi:10.1186/s12891-016-1123-7
31. Aro HT, Alm JJ, Moritz N, Mäkinen TJ, Lankinen P. Low BMD affects initial stability and delays stem osseointegration in cementless total Hip arthroplasty in women: a 2-year RSA study of 39 patients. *Acta Orthop*. 2012;83:107–114. doi:10.3109/17453674.2012.678798
32. Liu Y, Xu JW, Li MY, Wu LM, Zeng Y, Shen B. Zoledronic acid for periprosthetic bone mineral density changes in patients with osteoporosis after hip arthroplasty-an updated meta-analysis of six randomized controlled trials. *Front Med*. 2021;8:801282. doi:10.3389/fmed.2021.801282

## Therapeutics and Clinical Risk Management

Dovepress

### Publish your work in this journal

Therapeutics and Clinical Risk Management is an international, peer-reviewed journal of clinical therapeutics and risk management, focusing on concise rapid reporting of clinical studies in all therapeutic areas, outcomes, safety, and programs for the effective, safe, and sustained use of medicines. This journal is indexed on PubMed Central, CAS, EMBase, Scopus and the Elsevier Bibliographic databases. The manuscript management system is completely online and includes a very quick and fair peer-review system, which is all easy to use. Visit <http://www.dovepress.com/testimonials.php> to read real quotes from published authors.

Submit your manuscript here: <https://www.dovepress.com/therapeutics-and-clinical-risk-management-journal>