



Stomach perforation post cardiopulmonary resuscitation—A case report



Aasim Khan*, Neil Merrett, Selwyn Selvendran

Department of General & Hepato-Biliary Surgery, Bankstown Hospital, Sydney, Australia

ARTICLE INFO

Article history:

Received 12 June 2017

Received in revised form 17 August 2017

Accepted 17 August 2017

Available online 24 August 2017

Keywords:

Cardiopulmonary resuscitation

Stomach perforation

Laparotomy

ABSTRACT

INTRODUCTION: Stomach perforation after cardiopulmonary resuscitation is a rare finding. This is mainly caused by incorrect management of the airway during CPR performed by non-medical personnel.

PRESENTATION OF CASE: We report a case of 72 year old female who sustained a stomach perforation during prolonged CPR in an out of hospital arrest situation. This was diagnosed on a computed tomography scan of the abdomen requiring midline laparotomy and a primary repair of the stomach.

DISCUSSION: The training of medical and non-medical persons in cardiopulmonary resuscitation is to be encouraged. However it should be emphasized that any technique which breaches the normal integrity of the body can itself lead to life-threatening complications.

CONCLUSION: A high degree of vigilance is required in patients presenting after a cardiac arrest and CPR.

© 2017 The Author(s). Published by Elsevier Ltd on behalf of IJS Publishing Group Ltd. This is an open access article under the CC BY-NC-ND license (<http://creativecommons.org/licenses/by-nc-nd/4.0/>).

1. Introduction

The work has been reported in line with the SCARE criteria [1]. Cardiopulmonary resuscitation (CPR) remains the best way to restore to spontaneous circulation in a patient with cardiac arrest. CPR can cause multiple complications namely rib and/or sternal fractures, pneumothorax, solid organ injuries including the liver and spleen lacerations and rarely cardiac contusions. A rupture of the stomach post CPR has been rarely described [2]. We describe a case of 72-year female patient who underwent CPR in an out of hospital arrest situation and developed a large stomach perforation which was managed surgically.

2. Presentation of case

A 72-year old female patient was referred to our unit after a blunt abdominal trauma (BAT) call in our emergency department. The patient had an unconscious collapse at home and underwent chest compressions by her family members for 20 min before the paramedics arrived at the scene. Expectoration of blood from the mouth and nostrils was noted. She underwent resuscitation according to Advanced Cardiac Life Support (ACLS) protocol using 6 mg of adrenaline, one 200J DC shock for VF and CPR for 15 mins before return of spontaneous circulation (ROSC). She was intubated and brought to the emergency department for further assessment.

Her past medical history was significant for asthma with underlying chronic obstructive airways disease, gastro-oesophageal reflux disease and migraine. Her regular medications included daily prednisolone 5 mg and pantoprazole 20 mg orally.

On examination, the patient was intubated and ventilated with oxygen saturation 94%. Her other vitals were HR 100/min, BP 150/90 and equal non-reactive 2 mm pupils. Her secondary survey showed a soft but mildly distended abdomen and a normal examination of her extremities. Focused Assessment with Sonography in Trauma (FAST), performed in the emergency department was negative. Her ECG showed a sinus rhythm with an old left bundle branch block (LBBB). Her blood investigations were negative for a troponin rise.

An orogastric tube was inserted without difficulty with a small volume of blood (<20 mls) was aspirated. A mobile chest x-ray showed correct positions of the endotracheal and orogastric tubes with significant opacification of both sides of the lungs suggestive of an acute pulmonary oedema (APO). A non-contrast computed tomography scan of the head and a triple phase scan of thorax, chest, abdomen and pelvis was performed. The scan of her head was unremarkable. There was good opacification of her pulmonary arteries with no evidence to suggest pulmonary embolism. She had gross pneumoperitoneum (Fig. 1) with a left subphrenic fluid collection measuring 50 × 82 mm in size with soft tissue stranding of the left sub phrenic fat. The gastric fundus was irregular in contour with apparent discontinuity of wall anteromedial with extra luminal air (Fig. 2).

An emergency midline laparotomy was performed. Gross contamination of the peritoneal cavity with food debris was noted. A 10cm linear laceration was noted in the anterior wall along

* Corresponding author at: Unit 2905, 420 Macquarie Street, Liverpool, NSW, 2170, Australia.

E-mail address: aasim@doctor.com (A. Khan).

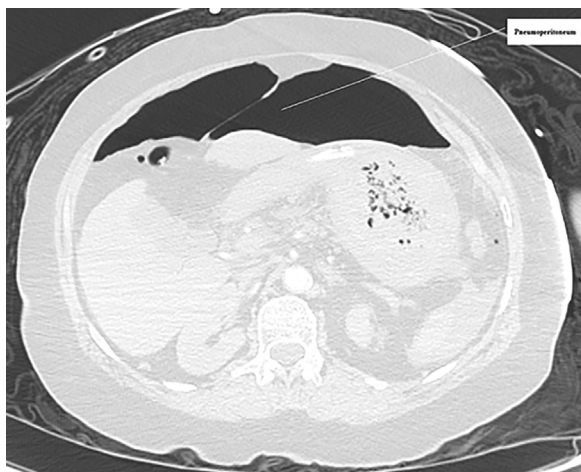

Fig. 1. Pneumoperitoneum post CPR.

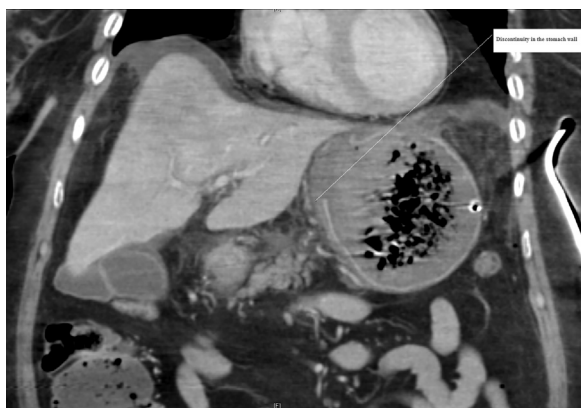


Fig. 2. Discontinuity in the anterior stomach wall post CPR.

the lesser curvature of the stomach. The edges of the ruptured stomach were resected and primary repair of the stomach was performed using 3-0 PDS. The stomach was closed in two layers and the anastomosis site was covered with omentum using 3-0 PDS. The abdominal cavity was washed using 12 L of warm saline. A 19F Blake drain was placed in the stomach bed and the abdominal wall was closed in two layers. Skin clips were applied.

The patient was transferred to the Intensive Care Unit for monitoring and was extubated after 11 days due to slow neurological recovery. Parenteral feeding was commenced within 48 h through a peripherally inserted central catheter. A gastrograffin leak test performed via NGT on day 18 did not show a leak from the anastomotic site and oral feeding was commenced. Her admission was complicated by bilateral pulmonary emboli and general deconditioning requiring a prolonged stay in the rehabilitation unit. She made an uneventful recovery and was discharged home 75 days later. She was followed up in the surgical outpatient clinic 3 months later when she made a full recovery.

3. Discussion

The most common causes of pneumoperitoneum include a perforated appendix, duodenal and gastric ulcer, colon diverticulum and perforation of the bowel secondary to inflammatory bowel disease [2].

Following CPR gastric mucosal tears occurred in 9–12% of patients [3–5]. A combination of a pneumothorax, pneumo-mediastinum and pneumoperitoneum as complications after

resuscitation has been described [6]. Although stomach perforation is a rare complication of CPR, it may cause serious morbidity and mortality without early diagnosis and treatment [7].

Mortality rates may be high due to peritonitis and septic shock [8]. The period between the appearance of symptoms and implementation of treatment is a determining factor on survival. Although the most common symptom of stomach perforation in a conscious patient is pain, the sign of stomach perforation in patients undergoing cardiac arrest is sudden-onset abdominal distention, which progresses rapidly [7].

It was assumed that the primary air leak originates in the thorax and secondarily migrates to the abdomen through the foramen of Winslow or other diaphragmatic apertures. However massive dilatation of the stomach can occur if forceful breaths with an incorrectly positioned airway are given [4,9].

Hypoxia might further increase pulmonary airway resistance and decrease compliance, therefore increasing the likelihood of gastric insufflations [10]. Reflex activity of the glottis is high compared with the cricopharyngeus and therefore, the air will simply pass through the cricopharyngeal sphincter and dilate the stomach [11].

All the factors that prevent gas being released from the stomach through the cardiac and pyloric orifices cause further distension of the stomach. These factors include spasms, tumours, inflammation, duodenal obstruction, a diaphragmatic hernia or a gastric volvulus [12]. Gastric dilatation alters the gastro-oesophageal angle and prevents the exit of gas into the oesophagus [13,14].

All reported cases of CPR-related gastric perforation have resulted in perforation along the lesser curvature of the stomach, usually adjacent to the gastro-oesophageal junction. (Table 1) This is the least elastic part of the stomach due to fewer mucosal folds than the rest of the stomach and due to fixation by the hepatogastric ligament [15].

Pressures from 120 to 150 mm Hg are required to perforate the normal gastric wall. These pressures correspond to an intragastric volume of approximately 4 L, as 1–1.9 L of air routinely enters the stomach daily [16]. Local ischemia, congenital weakness or muscle defects, intake of sodium bicarbonate and opioid overdose can further predispose towards gastric perforation [12,13,17].

In our case, a combination of increased gastric volume and vigorous cardiac compression probably elevated the intragastric pressure causing gastric perforation.

The most common treatment for this problem is laparotomy, including homeostasis, debridement and primary closure of the gastric wound, peritoneal lavage, and antibiotic therapy. Another possibility is gastrostomy, especially for older and high-risk patients [18].

A non-operative conservative management is described in literature [6,19–21]. Some authors argue that laparotomy is not necessary if the patient's abdomen has no signs of peritonitis or if peritoneal lavage and gastric studies are negative [3–5,21]. Peritoneal lavage may be a reasonable alternative to surgical exploration in a patient without signs of peritonitis but negative results do not rule out the diagnosis. It is widely accepted as a diagnostic tool for blunt abdominal trauma [3].

In summary, although gastric perforation after CPR is a rare phenomenon, it requires prompt diagnosis and treatment and carries high morbidity and mortality if left unrecognized. Attention to early endotracheal intubation, avoidance of oesophageal intubation, and gaseous distention of the stomach may reduce gastric injuries and perforation. Abdominal pain after CPR in an alert patient and/or abdominal distention unrelieved by a nasogastric tube should raise suspicion of tension pneumoperitoneum and lead to appropriate diagnostic measures such as plain chest x-rays, diagnostic peritoneal lavage, and gastroscopy [18].

Table 1
Successful surgical outcomes for gastric perforation post CPR.

Patient	Reason for CPR	Complication	Laparotomy outcome	Reference
67 M	Cardiac arrest	Pneumoperitoneum due to a 5 cm full thickness tear along lesser curvature	Successful	Demos and Poticha [22]
30 F	Cardiac arrest	Pneumoperitoneum due to 10 cm laceration of stomach	Successful	Darke and Bloomfield [23]
52 F	Cardiac arrest	Pneumoperitoneum due to perforation of the lesser curvature	Successful	Ducable et al. [24]
76 M	Cardiac arrest	Pneumoperitoneum due to 3 cm gastric perforation at the lesser curvature	Successful	Gisselsson and Idvall [25]
65 F	Cardiac arrest	Pneumoperitoneum due to gastric rupture	Successful	Mills et al. [26]
65 M	Syncope	Pneumoperitoneum	Successful	Shemesh et al. [27]
73 m	Cardiac arrest	Traumatic pancreatitis, aspiration pneumonia, 10 cm gastric perforation at lesser curvature	Successful	Krohn et al. [28]
71 M	Anaphylactic shock	4 cm tear at lesser curvature	Successful	Vinen and Gaudry [29]
78 F	Cardiac arrest	Rupture at lesser curvature of the stomach	Successful	Woods et al. [30]
66 M	Arrhythmia	Pneumoperitoneum	Successful	Woods et al. [30]
37 M	(Near) drowning	Perforation of stomach	Successful	Floret et al. [31]
61 F	Cardiac arrest	Pneumoperitoneum due to gastric perforation	Successful	Skulberg and Steen [32]
78 F	Cardiac arrest	2 cm gastric rupture	Successful	Armbruster et al. [33]
66 F	Cardiac arrest	12 cm laceration of the lesser curvature	Successful	Oh and Hewitt [34]
75 m	Cardiac arrest	3 cm rupture of the cardiac orifice of the stomach	Successful	Reiger et al. [35]
79 F	Cardiac arrest	12–15 cm gastric disruption along the lesser curvature	Successful	Strear et al. [36]
5 F	Cardiac arrest	Gastric rupture	Successful	Piardi et al. [37]
35 M	Heroin overdose	3 cm perforation at the posterior notch of the lesser curvature	Successful	Offerman et al. [38]
64 F	Choking	Full thickness tear of the anterior wall of lesser curve	Successful	Tung et al. [39]
73 M	Collapse after choking	10 cm laceration along lesser curvature	Successful	Tung et al. [39]
76 M	Acute dyspnea and collapse	Laceration of the stomach on the lesser curvature	Successful	Smally et al. [40]
79 F	Asystole	Rupture of lesser curvature of stomach	Successful	Hahn et al. [41]

The widespread training of medical and non-medical persons in cardiopulmonary resuscitation is to be encouraged. However it should be emphasized that any technique which breaches the normal integrity of the body can itself lead to life-threatening complications.

4. Conclusion

A high degree of vigilance is required in patients presenting after a cardiac arrest and CPR. Timely diagnosis and management of a hollow viscus injury is important for treatment as this has shown to improve patient outcomes.

Conflict of interest

None.

Funding

This research did not receive any specific grant from funding agencies in the public, commercial, or not-for-profit sectors.

Ethical approval

Not applicable.

Consent

Consent was obtained from the patient to publish this case report along with the images.

Author contribution

1. Dr Aasim Khan: study concept, data collection, data analysis, writing of paper.
2. Prof. Neil Merrett: study concept, data analysis, writing of paper.
3. Dr Selwyn Selvendran: study concept, data collection, data analysis, writing of paper.

Guarantor

Dr Aasim Khan.

References

- [1] R.A. Agha, A.J. Fowler, A. Saetta, I. Barai, S. Rajmohan, D.P. Orgill, for the SCARE group, the SCARE statement: consensus-based surgical case report guidelines, *Int. J. Surg.* (2016).
- [2] N.M. Williams, D.F. Watkin, Spontaneous pneumoperitoneum and other nonsurgical causes of intraperitoneal free gas, *Postgrad. Med. J.* 73 (1997) 531–537.
- [3] K.M. Hargaten, C. Aprahamian, J. Mateer, Pneumoperitoneum as a complication of cardiopulmonary resuscitation, *Am. J. Emerg. Med.* 6 (1988) 358–361.
- [4] P.A. Cameron, P.L. Rosengarten, W.R. Johnson, L. Dziukas, Tension pneumoperitoneum after cardiopulmonary resuscitation, *Med. J. Aust.* 155 (1991) 44–47.
- [5] S.R. Offerman, J.F. Holmes, D.H. Wisner, Gastric rupture and massive pneumoperitoneum after bystander cardiopulmonary resuscitation, *J. Emerg. Med.* 21 (2001) 137–139.
- [6] T.J. Hartoko, H.E. Demey, P.E. Rogiers, H.L. Decoster, J.M. Nagler, L.L. Bossaert, Pneumoperitoneum- a rare complication of cardiopulmonary resuscitation, *Acta Anaesthesiol. Scand.* 35 (1991) 235–237.
- [7] M.A. Afacan, S. Colak, H. Gunes, H. Kandis, A. Saritas, M. Cortuk, et al., An unusual complication of cardiopulmonary resuscitation: stomach perforation, *Am. J. Emerg. Med.* 9 (2014) 1149 (e1-3).
- [8] C.M. Strear, W.R. Jarnagin, W. Schecter, R.C. Mackersie, M.S. Hickey, Gastric rupture and tension pneumoperitoneum complicating cardiopulmonary resuscitation: case report, *J. Trauma* 44 (1998) 930–932.

- [9] W.H. Cassebaum, D.M. Carberry, P. Stefko, Rupture of the stomach from mouth-to-mouth resuscitation, *J. Trauma* 14 (1974) 811–814.
- [10] J.R. Custer, T.Z. Polley Jr., F. Moler, Gastric perforation following cardiopulmonary resuscitation in a child: report of a case and review of the literature, *Pediatr. Emerg. Care* 3 (1987) 24–27.
- [11] S.G. Darke, E. Bloomfield, Case of complete gastric rupture complicating resuscitation, *Br. Med. J.* 3 (1975) 414–415.
- [12] E.J. Valtonen, N. Hakola, Rupture of the normal stomach during mouth-to-mouth resuscitation, *Acta Chir. Scand.* 127 (1964) 427–431.
- [13] M. Solowiejczyk, E. Koren, S. Wapnick, J. Mandelbaum, Rupture of the stomach following mouth-to-mouth respiration, *Postgrad. Med. J.* 50 (1974) 769–772.
- [14] S.D. Woods, G. Hutchinson, W.R. Johnson, J.P. Masterton, Gastric rupture following cardiopulmonary resuscitation, *Aust. NZ J. Surg.* 56 (1986) 733–735.
- [15] I. Spoormans, K. Van Hoorenbeeck, L. Balliu, P.G. Jorens, Gastric perforation after cardiopulmonary resuscitation: review of the literature, *Resuscitation* 3 (2010) 272–280.
- [16] A.J. Smally, M.J. Ross, C.P. Huot, Gastric rupture following bag-valve-mask ventilation, *J. Emerg. Med.* 22 (2002) 27–29.
- [17] R.D. Stewart, Advances in prehospital immediate care, *Resuscitation* 18 (1989) S13–S20.
- [18] S.M. Jalali, H. Emami-Razavi, A. Mansouri, Gastric perforation after cardiopulmonary resuscitation, *Am. J. Emerg. Med.* 9 (2091) (2012) e1–2.
- [19] L.L. Low, G.R. Ripple, B.P. Bruderer, G.R. Harrington, Non-operative management of gastric perforation secondary to cardiopulmonary resuscitation, *Intensive Care Med.* 20 (1994) 442–443.
- [20] N. Haslam, G.C. Campbell, J.E. Duggan, Gastric rupture associated with use of the laryngeal mask airway during cardiopulmonary resuscitation, *BMJ* 329 (2004) 1225–1226.
- [21] S. Milanchi, Approach to pneumoperitoneum after cardiopulmonary resuscitation, *J. Trauma* 61 (2006) 1552–1553.
- [22] N.J. Demos, S.M. Poticha, Gastric rupture occurring during external cardiac resuscitation, *Surgery* 55 (1964) 364–366.
- [23] S.G. Darke, E. Bloomfield, Case of complete gastric rupture complicating resuscitation, *Br. Med. J.* 3 (1975) 414–415.
- [24] G. Ducable, S. Chamoun, C. Leturgie, J. Watelet, C. Winckler, Gastric ruptures after resuscitation, *Anesth. Analg. (Paris)* 35 (1978) 1153–1158.
- [25] L. Gisselsson, J. Idvall, Rupture of the stomach after heart–lung resuscitation, *Lakartidningen* 76 (1979) 2898–2899.
- [26] S.A. Mills, D. Paulson, S.M. Scott, G. Sethi, Tension pneumoperitoneum and gastric rupture following cardiopulmonary resuscitation, *Ann. Emerg. Med.* 12 (1983) 94–95.
- [27] E. Shemesh, Z. Dreznik, P. Shechter, I. Wolfstein, Rupture of stomach due to external cardiac resuscitation, *Isr. J. Med. Sci.* 19 (1983) 853–854.
- [28] C.D. Krohn, T. Buxrud, O. Kummen, Complications of cardiopulmonary resuscitation, *Tidsskr. Nor. Laegeforen.* 104 (1984) 2253–2254.
- [29] J.D. Vinen, P.L. Gaudry, Pneumoperitoneum complicating cardiopulmonary resuscitation, *Anaesth. Intensive Care* 14 (1986) 193–196.
- [30] S.D. Woods, G. Hutchinson, W.R. Johnson, J.P. Masterton, Gastric rupture following cardiopulmonary resuscitation, *Aust. NZ J. Surg.* 56 (1986) 733–735.
- [31] D. Floret, I. Melki, N. Philibert, P. Takvorian, Gastric rupture and resuscitation maneuvers, *Pediatric* 42 (1987) 95–97.
- [32] A. Skulberg, P.A. Steen, Ventricular rupture after mouth-to-mouth resuscitation without tube, *Tidsskr. Nor. Laegeforen.* 108 (1988) 215–224.
- [33] C. Armbruster, K. Dittrich, A. Tuchmann, Stomach rupture—a rare complication of resuscitation, *Chirurg* 60 (1989) 178–179.
- [34] C.M. Oh, P.M. Hewitt, Gastric rupture due to cardiopulmonary resuscitation, *Injury* 29 (1998) 399–400.
- [35] J. Reiger, C. Eritscher, K. Laubreiter, J. Trattng, F. Sterz, G. Grimm, Gastric rupture—an uncommon complication after successful cardiopulmonary resuscitation: report of two cases, *Resuscitation* 35 (1997) 175–178.
- [36] C.M. Strear, W.R. Jarnagin, W. Schechter, R.C. Mackersie, M.S. Hickey, Gastric rupture and tension pneumoperitoneum complicating cardiopulmonary resuscitation: case report, *J. Trauma* 44 (1998) 930–932.
- [37] T. Piardi, F. D'Adda, F. Palmieri, N. Vettoretto, S. Lanzi, Pouchè A. Shock, dyspnea after cardiopulmonary resuscitation: a case of iatrogenic gastric rupture, *Chir. Ital.* 52 (2000) 593–596.
- [38] S.R. Offerman, J.F. Holmes, D.H. Wisner, Gastric rupture and massive pneumoperitoneum after bystander cardiopulmonary resuscitation, *J. Emerg. Med.* 21 (2001) 137–139.
- [39] P.H. Tung, S. Law, K.M. Chu, W.L. Law, J. Wong, Gastric rupture after Heimlich maneuver and cardiopulmonary resuscitation, *Hepatogastroenterology* 48 (2001) 109–111.
- [40] A.J. Smally, M.J. Ross, C.P. Huot, Gastric rupture following bag-valve-mask ventilation, *J. Emerg. Med.* 22 (2002) 27–29.
- [41] C.D. Hahn, Y.U. Choi, D. Lee, J.D. Frizzi, Pneumoperitoneum due to gastric perforation after cardiopulmonary resuscitation: case report, *Am. J. Crit. Care* 17 (2008) 386–387.

Open Access

This article is published Open Access at [sciencedirect.com](https://www.sciencedirect.com). It is distributed under the [IJSCR Supplemental terms and conditions](#), which permits unrestricted non commercial use, distribution, and reproduction in any medium, provided the original authors and source are credited.