

Atypical and delayed de Winter electrocardiograph pattern

A case report

Yingchao Yang, MSc^a, Yeshuo Ma, PhD^b, Da Yin, MD^a, Ying Zhang, MD^a, Wei Song, MD^a, Yunpeng Cheng, MD^a, Tingting Fu, MSc^c, Ri Zhang, MSc^a, Yue Liu, MSc^d, Kai Kang, MSc^a, Lixin Wang, MSc^a, Yinong Jiang, PhD^{a,*}, Yan Lu, MD^{a,*}

Abstract

Rationale: de Winter electrocardiograph (ECG) pattern signifies proximal left anterior descending coronary artery (LAD) occlusion and extensive anterior myocardial infarction, and it is found in about 2% of patients with proximal LAD occlusion. However, it is often unrecognized by physicians. In this case report, we present a patient with chest pain but showing an atypical and delayed de Winter ECG pattern.

Patient concerns: A previously healthy 61-year-old man attended our emergency department with chest pain radiating to the left arm and back for 4 hours, who was without serious cardiovascular risk factors. ECG at emergency department showed no significant changes. High-sensitivity cardiac troponin I (hs-cTnI) was within normal limit.

Diagnosis: At 5 hours after onset, ECG showed significant upsloping ST depression at J point in precordial leads V3 to V6, slight ST elevation in aVR and depression in inferior leads, and hs-cTnI peaked at 2.610 µg/L. The diagnosis of de Winter ECG pattern was confirmed by coronary angiography with an occlusion of the proximal LAD.

Interventions: A stent was implanted through percutaneous coronary intervention.

Outcomes: The patient's chest pain was relieved without further increase of hs-cTnI. ECG after procedure showed ST segment back to baseline in leads V4 to V6, but persistent ST elevation in V1 to V3 with QS or Q wave.

Lessons: Timely diagnosis of de Winter ECG pattern is very important, especially the atypical and delayed ECG changes. It should be treated as ST elevation myocardial infarction equivalent and deserves emergent revascularization therapy.

Abbreviations: ECG = electrocardiograph, hs-cTnI = high-sensitivity cardiac troponin I, LAD = left anterior descending coronary artery, OCT = optical coherence tomography, PCI = percutaneous coronary intervention, STEMI = ST elevation myocardial infarction.

Keywords: acute coronary syndrome, de Winter electrocardiograph pattern, left anterior descending coronary artery, ST elevation myocardial infarction

Editor: N/A.

YM and YY share first authorship.

Informed written consent was obtained from the patient for publication of this case report and accompanying images.

This work was supported by National Natural Science Foundation of China (no: 81570391).

The authors have no conflicts of interest to disclose.

^aDepartment of Cardiology, Institute of Cardiovascular Diseases, First Affiliated Hospital of Dalian Medical University, ^bDepartment of Cardiology, The Third Xiangya Hospital of Central South University, Changsha, Hunan, ^cCardiac Echocardiography, First Affiliated Hospital of Dalian Medical University, ^dDepartment of Cardiology, Dalian Ganjingzi District People Hospital, Dalian, Liaoning, China.

*Correspondence: Yan Lu, Yinong Jiang, Department of Cardiology, Institute of Cardiovascular Diseases, First Affiliated Hospital of Dalian Medical University, 193 Lianhe Road, Dalian, Liaoning, 116021, China (e-mails: yan_lu439@126.com, yinongjiang@126.com).

Copyright © 2019 the Author(s). Published by Wolters Kluwer Health, Inc. This is an open access article distributed under the terms of the Creative Commons Attribution-Non Commercial-No Derivatives License 4.0 (CCBY-NC-ND), where it is permissible to download and share the work provided it is properly cited. The work cannot be changed in any way or used commercially without permission from the journal.

Medicine (2019) 98:18(e15436)

Received: 10 December 2018 / Received in final form: 23 March 2019 /

Accepted: 2 April 2019

<http://dx.doi.org/10.1097/MD.00000000000015436>

1. Introduction

In 2008, de Winter electrocardiograph (ECG) pattern was firstly described in the *New England Journal of Medicine*.^[1] Instead of classical ST elevation myocardial infarction (STEMI), de Winter ECG pattern presents 1 to 3 mm upsloping ST segment depression at J point followed by symmetric and tall T wave in the precordial leads. These characteristic changes in de Winter ECG pattern are associated with proximal left anterior descending coronary artery (LAD) occlusion and acute anterior myocardial infarction.^[1,2] Therefore, recognition of this ECG pattern is of vital significance, and it should be treated as STEMI equivalent.^[3]

2. Case report

A 61-year-old man presented to the emergency department with chest pain radiating to the left arm and back for 4 hours. He had healthy diets and lifestyle, and persisted in long-term regular sports for 40 years. History of hypertension, diabetes, smoking, and drink were denied. But the patient had a family history of cardiovascular disease. The ECG at emergency department showed slight ST segment elevation in lead aVR and depression in inferior leads (Fig. 1A). High-sensitivity cardiac troponin I (hs-cTnI) was 0.052 µg/L (normal value <0.1 µg/L). Isosorbide dinitrate intravenous infusion was administered. At the 5th

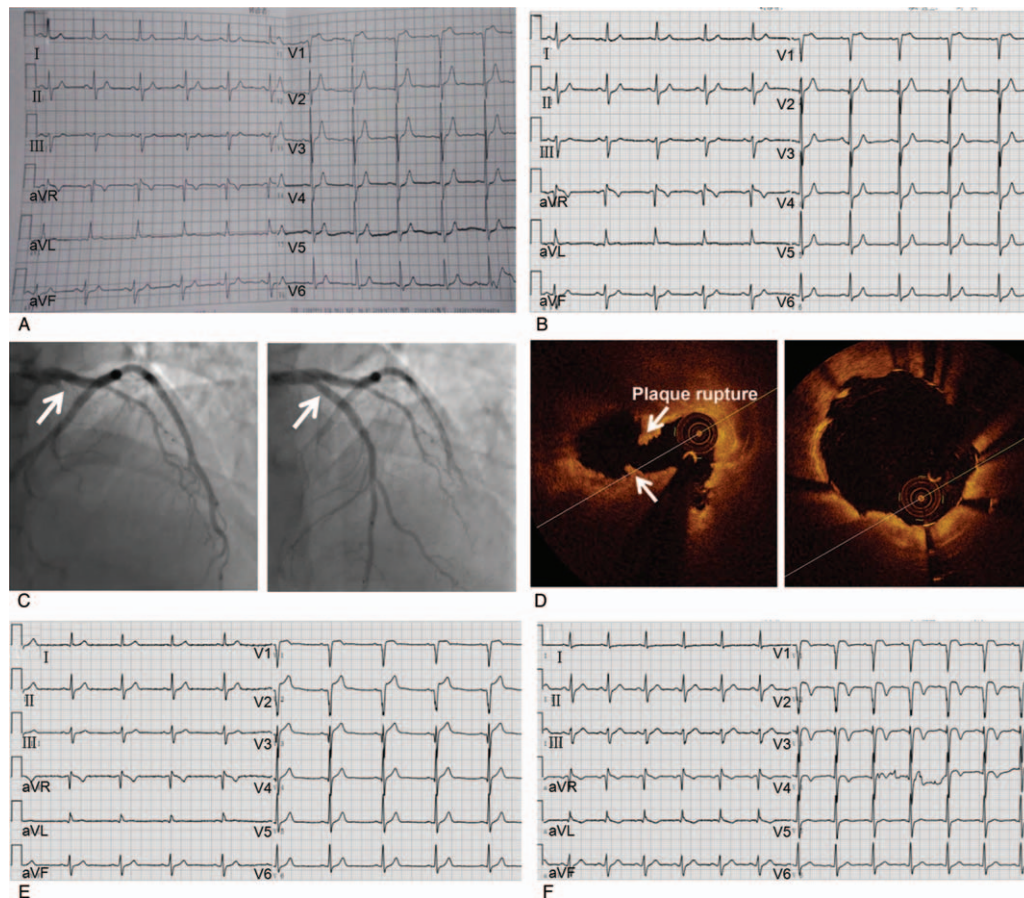


Figure 1. Electrocardiograph (ECG), coronary angiogram, and optical coherence tomography (OCT). (A) ECG at the 4th hour after onset when the patient presented to the emergency department. (B) ECG at the 5th hour after onset. (C) Coronary angiogram showed a proximal LAD occlusion (arrows, left). After implanting a stent at left anterior descending coronary artery (LAD) (arrows), coronary angiogram showed thrombolysis in myocardial infarction flow grade 3 C (right). (D) After aspiration of thrombus, OCT imaging showed rupture of plaque at proximal LAD (arrows, left). OCT imaging showed the stent stretched adequately and attached to the vascular wall smoothly after stenting (right). (E) ECG immediately after the percutaneous coronary intervention. (F) ECG at 3 days after procedure.

hour after onset, the ECG showed significant upsloping ST depression at J point in precordial leads V3 to V6, slight ST elevation in aVR, and depression in inferior leads that were compatible with the characteristics of de Winter ECG pattern (Fig. 1B). At the same time, hs-cTnI peaked at $2.610 \mu\text{g/L}$. The patient still suffered from sustained and severe chest pain, and was diagnosed with acute coronary syndrome with suspected de Winter ECG pattern. Oral aspirin and clopidogrel were administered. Coronary angiography showed an occlusion of the proximal LAD, which confirmed our prediagnosis, and a stent was implanted through percutaneous coronary intervention (PCI) (Fig. 1C). Complete restoration of blood flow with postprocedural thrombolysis in myocardial infarction flow grade 3 was observed, and a ventricular aneurysm was found during the procedure. In addition, optical coherence tomography (OCT) imaging showed a rupture of plaque at proximal LAD, and the stent stretched adequately and attached to the vascular wall smoothly after procedure (Fig. 1D). The ECG recorded immediately after the PCI showed ST segment back to baseline in leads V4 to V6, but persistent ST elevation in V1 to V3 with QS or Q wave (Fig. 1E, F). However, hs-cTnI did not increase anymore.

Ethical approval was not applicable in this case since standard care was performed. Informed consent was obtained from the

patient for publication of this case report and accompanying images.

3. Discussion

Our case demonstrates a previously healthy patient with acute coronary syndrome presenting an atypical and delayed de Winter ECG pattern. Fortunately, the patient was timely diagnosed and treated with PCI.

In the present case, de Winter ECG pattern was not detected till 5 hours after symptom onset. However, it has been described by de Winter et al that this pattern was usually recorded 1.5 hours after onset.^[1] In addition, the ECG recorded of this patient only showed significant upsloping ST segment depression at the J point in the precordial leads V3 to V6, but without prominent T wave, whereas subsequent urgent coronary angiography revealed a significant proximal LAD occlusion without lesion in the left main stem and other coronary artery, which provided the evidence of de Winter ECG pattern. We consider that the possible reasons for the differences in ECG changes include: individual difference in coronary anatomy, recruitment of collateral channels, repeated episodes of ischemia with preconditioning, different phases of the thrombotic cascade and subtotal occlusion causing some residual flow.^[4,5] This uncommon ECG pattern

recorded in the present case suggests that this delayed and atypical de Winter ECG pattern could also signify the proximal LAD occlusion and anterior myocardial infarction, which probably improves the definition of de Winter ECG pattern.

It is worth noting that the ECG taken after successful primary PCI revealed that ST segment elevation with QS or Q wave in leads V1 to V3 without further increasing of hs-cTnI. However, it has been verified that resolution of all ST depression and prominent T wave would be revealed after coronary stenting.^[1,6] We considered that these abnormal ECG changes were associated with the ventricular aneurysm that had been observed during coronary angiography. But it is still unclear that whether ventricular aneurysm is caused by de Winter ECG pattern directly, or the evolution of de Winter ECG pattern to STEMI and transmural infarction.^[7,8] During these years, there is controversial about the relationship between de Winter ECG pattern and STEMI. Initially, de Winter ECG pattern was considered to be persisting from the time of first ECG until mechanical reperfusion therapy.^[1] However, recent case reports demonstrate that de Winter ECG pattern could evolve to an STEMI ECG pattern within hours of presentation.^[8,9] No matter whether de Winter ECG pattern could progress to STEMI, it should be timely diagnosed and urgent managed as STEMI equivalent.^[10]

Another noticeable feature of this reported patient is that he did not have any vital risk factor excepting a family history. In addition, his eating habits and lifestyle were pretty healthy. What was more, the patient persisted in running 2 to 3 km daily since approximate 40 years ago. It suggests that myocardial infarction could even occur in a previously healthy person without serious risk factors presenting in certain special ECG patterns.

In conclusion, an atypical and delayed de Winter ECG pattern is verified in the present case. All physicians and paramedics should be aware of de Winter ECG pattern, especially the atypical and delayed ECG changes, because it is associated with proximal LAD occlusion and extensive anterior myocardial infarction. Once diagnosed with de Winter ECG pattern, it should be treated as STEMI equivalent.

Author contributions

Conceptualization: Yinong Jiang, Yan Lu.

Data curation: Yeshuo Ma, Yue Liu, Kai Kang, Lixin Wang.

Investigation: Yeshuo Ma, Da Yin, Ying Zhang.

Methodology: Wei Song, Yunpeng Cheng, Tingting Fu, Ri Zhang.

Supervision: Yinong Jiang, Yan Lu.

Writing – original draft: Yingchao Yang.

Writing – review & editing: Yeshuo Ma.

Yan Lu orcid: 0000-0002-8189-7168.

References

- [1] de Winter RJ, Verouden NJ, Wellens HJ, et al. A new ECG sign of proximal LAD occlusion. *N Engl J Med* 2008;359:2071–3.
- [2] Littmann L. The Dressler - de Winter sign of acute proximal LAD occlusion. *J Electrocardiol* 2018;51:138–9.
- [3] Verouden NJ, Koch KT, Peters RJ, et al. Persistent precordial “hyperacute” T-waves signify proximal left anterior descending artery occlusion. *Heart* 2009;95:1701–6.
- [4] Sunbul M, Erdogan O, Yesildag O, et al. De Winter sign in a patient with left main coronary artery occlusion. *Postepy Kardiol Interwencyjne* 2015;11:239–40.
- [5] Donato M, Evelson P, Gelpi RJ. Protecting the heart from ischemia/reperfusion injury: an update on remote ischemic preconditioning and postconditioning. *Curr Opin Cardiol* 2017;32:784–90.
- [6] Xu J, Wang A, Liu L, et al. The de winter electrocardiogram pattern is a transient electrocardiographic phenomenon that presents at the early stage of ST-segment elevation myocardial infarction. *Clin Cardiol* 2018;41:1177–84.
- [7] Zhao YT, Huang YS, Yi Z. de winters ECG changes and anterior myocardial infarction. *QJM* 2016;109:269–71.
- [8] Goebel M, Bledsoe J, Orford JL, et al. A new ST-segment elevation myocardial infarction equivalent pattern? Prominent T wave and J-point depression in the precordial leads associated with ST-segment elevation in lead aVr. *Am J Emerg Med* 2014;32:287.e5–8.
- [9] Pranata R, Huang I. Should de Winter T-wave electrocardiography pattern be treated as ST-segment elevation myocardial infarction equivalent with consequent reperfusion? A dilemmatic experience in rural area of Indonesia. *Case Rep Cardiol* 2018;2018:6868204.
- [10] Rao MY, Wang YL, Zhang GR, et al. Thrombolytic therapy to the patients with de Winter electrocardiographic pattern, is it right? *QJM* 2018;111:125–7.