



Ductus Arteriosus of Extremely Preterm Twins is More Resistant to Cyclooxygenase Inhibitors Than Those of Singletons

Toshikazu Ono¹ · Yuichiro Miura¹ · Maiko Kaga¹ · Tomoki Sato¹ · Masatoshi Sanjo¹

Received: 30 September 2021 / Accepted: 25 October 2021 / Published online: 30 October 2021
© The Author(s), under exclusive licence to Springer Science+Business Media, LLC, part of Springer Nature 2021

Abstract

Symptomatic patent ductus arteriosus (sPDA) is common among preterm infants, and can lead to several complications. This is particularly true for extremely preterm infants, as closure of the ductus arteriosus using cyclooxygenase inhibitors is often difficult. A recent study using a preterm sheep model showed that intimal thickening—required for anatomical closure of the ductus arteriosus—is less developed in twins than in singletons. Therefore, this study primarily aimed to prove that the ductus arteriosus of extremely preterm twins is more resistant to cyclooxygenase inhibitors than those of extremely preterm singletons. Its secondary aim was to assess whether the resistance against cyclooxygenase inhibitors differed according to chorionicity. In this retrospective case–control study, medical records of 162 extremely preterm infants (gestational age < 28 weeks) were reviewed, and the treatment course of sPDA was subsequently compared between singletons ($n = 131$) and twins ($n = 31$). The median indomethacin doses for sPDA and the necessity for surgical ligation were significantly higher in twins than in singletons (5 vs 2 [$p < 0.001$] and 42% vs 21% [$p = 0.018$], respectively). No significant differences in sPDA treatment, including the number of indomethacin doses and the necessity for surgical ligation, were observed between mono-chorionic diamniotic and dichorionic diamniotic twins. This study confirms that the ductus arteriosus of extremely preterm twins is more resistant to cyclooxygenase inhibitors than those of singletons. However, there was no significant difference in sPDA treatment by chorionicity.

Keywords Ductus arteriosus · Extremely preterm infants · Indomethacin · Extremely preterm twins · Cyclooxygenase Inhibitors

Introduction

Recent advances in perinatal care have increased the survival rate of extremely preterm infants (EPIs; delivered before 28 weeks' gestation) who were previously considered to be not viable. EPIs require medical care for respiratory and circulatory support in the neonatal intensive care unit (NICU) after birth because of their prematurity; furthermore, symptomatic patent ductus arteriosus (sPDA) is a common complication in these neonates. sPDA occurs in 55–70% of EPIs and leads to myocardial dysfunction due to left heart failure, resulting in pulmonary hemorrhage, intraventricular hemorrhage, necrotizing enterocolitis, and renal failure [1, 2]. The

first-line treatment of sPDA consists of intravenous administration of cyclooxygenase (COX) inhibitors, such as indomethacin and ibuprofen [3]. While COX inhibitors can be used to functionally close the ductus arteriosus (DA), the DA often reopens when subsequent anatomical closure cannot be achieved. Intimal thickening has been reported to be required for the anatomical closure of the DA, and the degree of such thickening greatly varies [4]. This indicates why some DAs close without any problem, whereas others repeatedly reopen, and may require more COX inhibitor doses or surgical ligation. The birth rate of twins has considerably increased over the last 30 years [5], at least partly due to the development of assisted reproductive technology [6]. As multiple gestation is an important risk factor for preterm birth [7], the number of extremely preterm twins has also increased [8]. Using a preterm sheep model, Ito et al. had recently reported that intimal thickening is less developed in twins than in singletons [9].

✉ Toshikazu Ono
t.ono@sendai.jrc.or.jp

¹ Department of Neonatology, Sendai Red Cross Hospital, 2-43-3 Yagiyama Honcho, Taihaku-Ward, Sendai, Miyagi 982-8501, Japan

Based on the findings of these studies, intimal thickening has been suggested to be less developed in human twins than in human singletons, as with the preterm sheep model. Therefore, it is hypothesized that the DAs of twins are more resistant to treatment with COX inhibitors than those of singletons. As the acquisition and histological analysis of human DA tissues are not possible because sPDA is not a life-threatening disease in most cases nowadays, this study was planned as an alternative attempt.

The primary aim of this study was to prove that the DAs of twins are more resistant to COX inhibitors than those of singletons in a human model by comparing the treatment course for sPDA between singletons and twins. The secondary aim of this study was to examine whether the resistance against COX inhibitors differs between monochorionic diamniotic (MD) and dichorionic diamniotic (DD) twins.

Materials and Methods

Study Design and Subjects

This study was approved by the ethics committee of Sendai Red Cross Hospital (no. 173). Infants who were born at <28 weeks' gestational age (GA) and admitted to the NICU of the Sendai Red Cross Hospital between November 1, 2010 and June 30, 2019 were included in this study. Neonatal deaths in the NICU, triplets, and infants with congenital malformations were excluded. All data were retrospectively extracted from medical records, and informed consent was obtained using an opt-out method.

General Clinical Protocol

All infants were resuscitated under a radiant heater immediately after birth according to standard practice; they were subsequently transferred to the NICU and incubated. Patients with respiratory distress syndrome (RDS) were intubated, given a surfactant, and placed on a ventilator. Continuous positive airway pressure was initiated in patients without RDS, and they were switched to mechanical ventilation if their respiratory condition deteriorated. A central venous catheter (Argyle PI catheter kit; Cardinal Health Inc., Ohio, USA) was peripherally inserted, and continuous intravenous infusion was initiated. When required, infants were sedated via bolus administration of phenobarbital (10–20 mg/kg/dose) and/or continuous intravenous infusion of midazolam (0.1–0.2 mg/kg/hr) or fentanyl (1.0–2.0 µg/kg/hr) until 72 h after birth to minimize the risk of intraventricular hemorrhage. The mean blood pressure was maintained above the value of the gestational week by volume loading and/or continuous intravenous administration of catecholamines (2.0–5.0 µg/kg/min). Parenteral nutrition, including amino

acids and lipids, was started within 24 h after birth, whereas enteral nutrition was initiated about 12 h after birth once the general condition had stabilized.

Clinical Data

The following clinical data were extracted from the subjects' medical records: presence or absence of histological chorioamnionitis; mother's age; administration of antenatal steroids, ritodrine hydrochloride, and magnesium sulfate; GA; birth weight; sex; Apgar scores at 1 and 5 min; development of sPDA; number of indomethacin doses; necessity for surgical ligation; development of RDS; necessity for mechanical ventilation and continuous positive airway pressure; development of intraventricular hemorrhage, periventricular leukomalacia, necrotizing enterocolitis, focal intestinal perforation, or pulmonary hemorrhage; the necessity for home oxygen therapy due to chronic lung disease; and the necessity for laser photocoagulation for retinopathy of prematurity (ROP).

Management of sPDA

No infants received prophylactic treatment for DA. sPDA was diagnosed based on clinical indicators (tachycardia, continuous systolic heart murmur, and widened pulse pressure) and echocardiographic findings (ductus diameter ≥ 1.4 mm/kg, left atrium-to-aortic root ratio ≥ 1.4 , and left pulmonary artery end-diastolic flow ≥ 0.2 m/s) [10]. Echocardiography was performed using Philips CX50 (Philips, Amsterdam, Netherlands) with an S12-4 probe; when infants developed sPDA, they were treated with indomethacin. The initial dose of indomethacin was 0.1 mg/kg for infants treated within 2 days after birth and 0.1–0.2 mg/kg for infants treated from 2 days after birth; in all cases, indomethacin was intravenously administered for 1 h and included up to 3 doses per course. Infants with sustained sPDA after the first course of indomethacin who had no contraindications to additional treatment were administered additional courses of indomethacin, as necessary, at intervals exceeding 48 h. The DAs were ligated only when one or more of the following were observed: (1) persistent disturbance of brain perfusion (interrupted diastolic flow in the anterior cerebral artery detected by ultrasonography); (2) feeding intolerance; and (3) contraindications to indomethacin treatment.

Diagnoses

GA was determined using early ultrasound scanning, whereas chorionicity was confirmed by placental histology. RDS was diagnosed according to X-ray findings, clinical symptoms of respiratory distress in the first 24 h of life, and a requirement for surfactant administration. Intraventricular

hemorrhage was defined as severe hemorrhage of grade II or higher [11]. Periventricular leukomalacia was diagnosed based on magnetic resonance imaging [12, 13]. Necrotizing enterocolitis was defined as stage II or greater [14], and focal intestinal perforation was diagnosed based on findings during surgery.

Statistical Analysis

Statistical analyses were performed using IBM SPSS for Windows version 26.0 (IBM Corp., NY, USA). All numerical data were evaluated for normality using the Shapiro–Wilk test; categorical variables were presented as number of cases and percentages, and chi-squared or Fisher’s exact test was used to analyze nominal values between two groups. As for numerical values, between-group differences in parametric data were analyzed using *t*-tests, whereas the Mann–Whitney U test was used for nonparametric data. To compare numerical values among the three groups, between-group differences in parametric data were evaluated using one-way ANOVA, and multiple post hoc comparisons were performed using Tukey’s test. On the other hand, between-group differences in nonparametric data were evaluated for significance using Kruskal–Wallis one-way ANOVA, and multiple post hoc comparisons were performed using the rank-sum test, with a *p*-value corrected for *n*-multiple comparisons. All *p*-values < 0.05 were considered significant.

Results

A retrospective review of the medical records of 2356 infants was undertaken; 185 EPIs were born during the study period. Infants with congenital malformations, neonatal deaths in the NICU, and triplets were excluded (singletons,

n = 9; twins, *n* = 4; triplets, *n* = 10). Eventually, 162 individuals were analyzed, including singletons (*n* = 131), MD twins (*n* = 10), DD twins (*n* = 19), and monochorionic monoamniotic twins (*n* = 2) (Fig. 1).

Comparison Between Singletons and Twins (Table 1)

The mothers of twins were significantly younger than those of singletons (*p* = 0.009). The frequency of chorioamnionitis was significantly higher in singletons than in twins (*p* = 0.023); nonetheless, the singletons and twins did not significantly differ in terms of other background variables, such as GA, birth weight, and sex. With respect to treatment for sPDA, the number of indomethacin doses and the necessity for surgical ligation were significantly higher in twins than in singletons (*p* < 0.001 and *p* = 0.018, respectively); additionally, the incidences of RDS and laser photocoagulation for ROP were significantly higher in twins than in singletons (*p* = 0.004 and *p* = 0.013, respectively).

Comparison Between MD and DD Twins (Table 2)

The mothers of DD twins were significantly older than those of MD twins (*p* = 0.011). However, no significant differences in sPDA treatment, including the number of indomethacin doses and the necessity for surgical ligation, were observed between MD and DD twins.

Comparison Among Singletons, MD Twins, and DD Twins

The number of indomethacin doses was significantly higher in MD twins than in singletons (*p* < 0.001); nevertheless, no significant difference between DD twins and singletons was identified (Fig. 2a). Additionally, there was no significant

Fig. 1 Flow chart of the study population. MD monochorionic diamniotic, DD dichorionic diamniotic, MM monochorionic monoamniotic

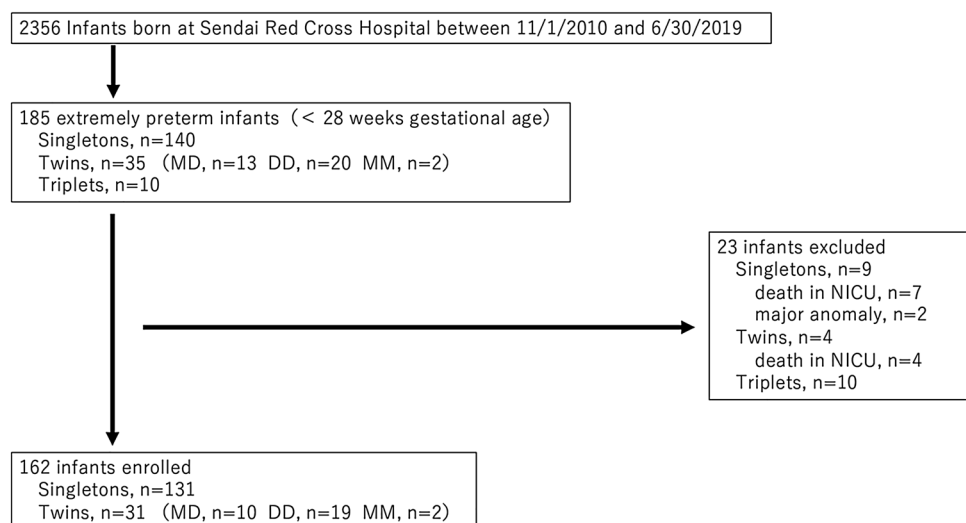


Table 1 Comparisons between singletons vs. twins

	Singletons (<i>n</i> = 131)	Twins (<i>n</i> = 31)	<i>P</i> value
Maternal variables			
Mother's age, years, median (IQR)	33 (7)	28 (11)	.009
Premature rupture of membranes, <i>n</i> (%)	52 (40)	14 (45)	n.s
Chorioamnionitis, <i>n</i> (%)	54 (41)	6 (19)	.023
Antenatal steroids administration, <i>n</i> (%)	85 (65)	24 (77)	n.s
Ritodrine hydrochloride administration, <i>n</i> (%)	93 (71)	26 (83)	n.s
Magnesium sulfate administration, <i>n</i> (%)	26 (20)	9 (29)	n.s
Neonatal variables			
Gestational age, weeks, median (IQR)	26.0 (2.0)	25.7 (2.0)	n.s
Birth weight, g, mean (\pm SD)	773 (\pm 201)	788 (\pm 152)	n.s
Male sex, <i>n</i> (%)	58 (44)	16 (52)	n.s
Apgar score at 1 min, median (IQR)	5 (3)	6 (3)	n.s
Apgar score at 5 min, median (IQR)	7 (3)	8 (3)	n.s
Symptomatic patent ductus arteriosus, <i>n</i> (%)	111 (85)	30 (97)	n.s
Number of doses of indomethacin, median (IQR)	2 (3)	5 (7)	<0.001
Surgical ligation, <i>n</i> (%)	28 (21)	13 (42)	0.018
Day on surgical ligation, days after birth, median (IQR)	22 (18)	26 (25)	n.s
Respiratory distress syndrome, <i>n</i> (%)	107 (82)	31 (100)	0.004
Mechanical ventilation, <i>n</i> (%)	126 (96)	31 (100)	n.s
Continuous positive airway pressure, <i>n</i> (%)	121 (92)	30 (97)	n.s
Intraventricular hemorrhage, <i>n</i> (%)	22 (17)	6 (19)	n.s
Periventricular leukomalacia, <i>n</i> (%)	6 (5)	1 (3)	n.s
Necrotizing enterocolitis, <i>n</i> (%)	3 (2)	0 (0)	n.s
Focal intestinal perforation, <i>n</i> (%)	7 (5)	2 (6)	n.s
Pulmonary hemorrhage, <i>n</i> (%)	19 (15)	2 (6)	n.s
Home oxygen therapy, <i>n</i> (%)	13 (10)	0 (0)	n.s
Laser photocoagulation for retinopathy of prematurity, <i>n</i> (%)	27 (21)	13 (42)	0.013

Continuous variables are represented by the mean values and SD when normally distributed. If data were not normally distributed, the variables are represented by the median values and interquartile range (IQR)

Values were statistically analyzed using either the Mann–Whitney U test, T-test or χ^2 test

n.s., not significant

difference in the need for surgical ligation among the three groups (Fig. 2b).

Discussion

This study highlights two important issues. First, the DAs of extremely preterm twins are more resistant to COX inhibitors than those of extremely preterm singletons (Table 1). The median number of indomethacin doses and the necessity for surgical DA ligation were significantly higher in twins than in singletons (5 vs 2 [$p < 0.001$] and 42% vs 21% [$p = 0.018$], respectively); however, the two groups did not significantly differ with respect to either GA or birth weight. These results suggest that the DAs of twins are more resistant to COX inhibitors than those of singletons. Our results are in line with the findings previously described by Ito

et al. [5]; that is, the DAs of twins tend to be resistant to COX inhibitors, possibly because of the attenuated intimal thickening of the DA. Our results also indicated that the morbidity of chorioamnionitis was significantly higher in singletons than in twins, which might have affected the DA's resistance to COX inhibitors. Considering that birth occurs after exposure to inflammation in the uterus due to chorioamnionitis—which may cause fetal inflammatory responses, including the production of prostaglandins—one may expect that elevated prostaglandins keep the DA open, leading to sPDA. However, our results revealed that twins who were less exposed to chorioamnionitis experienced difficulty in sPDA management. Ductal closure is a complex process, and prostaglandins have been suggested to play some key roles; namely, prostaglandins induce hyaluronic acid-mediated intimal cushion formation in utero, and the intimal cushion promotes ductal closure after birth, as shown by

Table 2 Comparisons between monochorionic diamniotic vs. dichorionic diamniotic twins

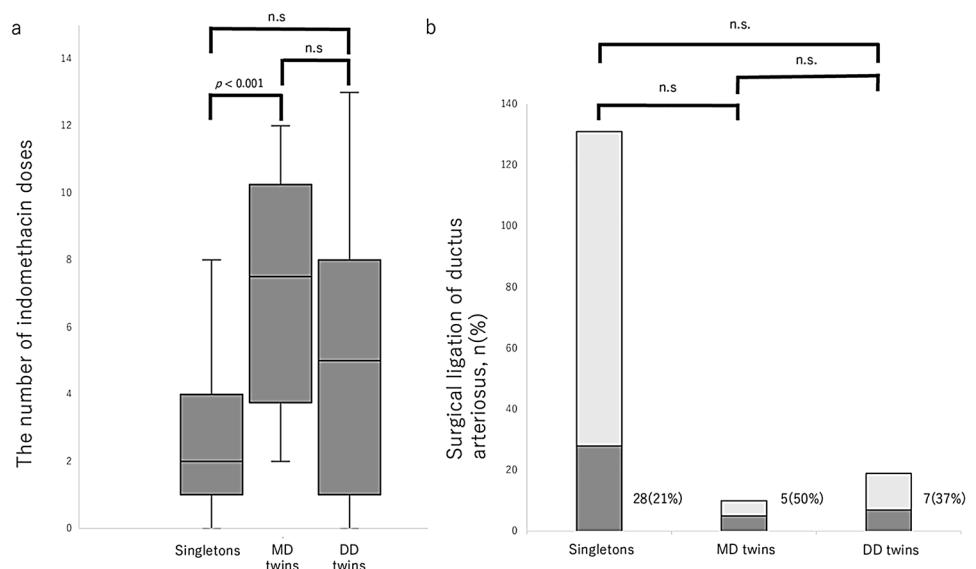
	MD twins (<i>n</i> = 10)	DD twins (<i>n</i> = 19)	<i>P</i> value
Maternal variables			
Mother's age, years, mean (\pm SD)	26 (\pm 5)	32 (\pm 7)	.011
Premature rupture of membranes, <i>n</i> (%)	4 (40)	10 (53)	n.s.
Chorioamnionitis, <i>n</i> (%)	4 (40)	2 (11)	n.s.
Antenatal steroids administration, <i>n</i> (%)	8 (80)	14 (74)	n.s.
Ritodrine hydrochloride administration, <i>n</i> (%)	9 (90)	15 (79)	n.s.
Magnesium sulfate administration, <i>n</i> (%)	3 (30)	6 (32)	n.s.
Neonatal variables			
Gestational age, weeks, mean (\pm SD)	25.9 (\pm 1.3)	25.9 (\pm 1.0)	n.s.
Birth weight, g, mean (\pm SD)	803 (\pm 169)	782 (\pm 154)	n.s.
Male sex, <i>n</i> (%)	3 (30)	13 (68)	n.s.
Apgar score at 1 min, median (IQR)	5 (4)	6 (3)	n.s.
Apgar score at 5 min, median (IQR)	7 (5)	8 (2)	n.s.
Symptomatic patent ductus arteriosus, <i>n</i> (%)	10 (100)	18 (95)	n.s.
Number of doses of indomethacin, median (IQR)	8 (7)	5 (7)	n.s.
Surgical ligation, <i>n</i> (%)	5 (50)	7 (37)	n.s.
Day on surgical ligation, days after birth, median (IQR)	32 (24)	26 (18)	n.s.
Respiratory distress syndrome, <i>n</i> (%)	10 (100)	19 (100)	n.s.
Mechanical ventilation, <i>n</i> (%)	10 (100)	19 (100)	n.s.
Continuous positive airway pressure, <i>n</i> (%)	9 (90)	19 (100)	n.s.
Intraventricular hemorrhage, <i>n</i> (%)	1 (10)	5 (26)	n.s.
Periventricular leukomalacia, <i>n</i> (%)	0 (0)	1 (5)	n.s.
Necrotizing enterocolitis, <i>n</i> (%)	0 (0)	0 (0)	n.s.
Focal intestinal perforation, <i>n</i> (%)	0 (0)	2 (11)	n.s.
Pulmonary hemorrhage, <i>n</i> (%)	0 (0)	2 (11)	n.s.
Home oxygen therapy, <i>n</i> (%)	0 (0)	0 (0)	n.s.
Laser photocoagulation for retinopathy of prematurity, <i>n</i> (%)	6 (60)	7 (37)	n.s.

Continuous variables are represented by the mean values and SD when normally distributed. If data were not normally distributed, the variables are represented by the median values and interquartile range (IQR)

Values were statistically analyzed using either the Mann–Whitney U test, T-test or χ^2 test

MD monochorionic diamniotic, DD dichorionic diamniotic, n.s. not significant

Fig. 2 **a** Comparison of the number of indomethacin doses among the three groups. **b** Comparison of the necessity for surgical ligation of the ductus arteriosus among the three groups. n.s. not significant



Yokoyama et al. using a rat model [15]. Whether chorioamnionitis induces spontaneous ductal closure or resistance to COX inhibitors remains unclear [16, 17], and further studies are warranted.

Second, no significant differences in the treatment course for sPDA were detected between MD and DD twins (Table 2). Furthermore, there were no significant differences in the number of indomethacin doses (8 vs 5, $p=0.137$) or the necessity for surgical ligation of the DA (50% vs 37%, $p=0.385$). Both MD and DD twins were more likely to require surgical ligation and needed more indomethacin doses than singletons; however, a statistical significance was only detected in the number of indomethacin doses between MD twins and singletons (Fig. 2). This result was somewhat unexpected, as our hypothesis was based on a report demonstrating that the development of intimal thickening in the DA was attenuated in preterm sheep twins [5], most of which are considered to be DD twins [18]. Yamaguchi et al. reported similar findings and showed that the frequency of sPDA was only significantly higher in MD twins than in singletons. Their data also indicated an elevated frequency of sPDA in DD twins compared to that in singletons; however, no significant differences were detected. They suggested that vascular anastomoses between co-twins were associated with a higher morbidity in sPDA [19]. In this study, no MD twins exhibited symptoms of twin-to-twin transfusion syndrome before birth; nonetheless, it is well known that even MD twins who do not meet the definition for twin-to-twin transfusion syndrome experience a certain degree of blood transfusion and are thus affected [20]. It may be satisfactory that only MD twins are at a high risk for sPDA, and their DAs are more resistant to COX inhibitors because of special hemodynamics in utero; however, the comparable results of our and Yamaguchi et al.'s studies do not seem to be a mere coincidence. Thus, further studies with a large number of patients and/or animal models are warranted to clarify whether the DAs of DD twins are more resistant to COX inhibitors.

There is one more finding to be noted in this study; ROP requiring laser photocoagulation was observed significantly more frequently in twins than in singletons. Despite conflicting data regarding the relationship between ROP and multiple births [21, 22], a recent cohort study conducted in Taiwan had shown that twins with an extremely low birth weight (below 1000 g) were at a 1.2-fold greater risk for ROP development than singletons with an extremely low birth weight [23]; our results are compatible with the findings of that study. Data on the relationship between ROP and COX inhibitor administration are also conflicting. Because an increase in prostaglandins is considered to result in ROP via retinal hyperoxygenation [24], administration of COX inhibitors may prevent ROP. However, a recent study reported that indomethacin

administration was associated with an increase in severe ROP [25]; thus, whether COX inhibitor administration increases or decreases the risk of ROP remains controversial. Excluding ROP, there were no significant differences in complications, including intraventricular hemorrhage, periventricular leukomalacia, and necrotizing enterocolitis, between singletons and twins. Conversely, a significant difference in the mothers' age was identified between singletons and twins and between MD and DD twins. To the best of our knowledge, no study has shown the correlation between mothers' age and the clinical course of sPDA. Thus, while statistically significant, the clinical significance of this issue is unclear.

This study has some limitations; first, a relatively small number of patients were included, as it was a single-center study. Second, the treatment strategies employed in this study may not have been optimal. There are no cardiovascular surgeons in our hospital, resulting in more indomethacin doses and delayed surgical ligation; therefore, our results may have been biased. Nevertheless, it is notable that there were no significant differences regarding neurodevelopmental outcomes between premature infants whose DA closed within 14 days and those whose DA remained open for a long time in our previous study [26]. In addition, although infants treated with indomethacin developed oliguria, all of them recovered without any sequelae.

Conclusion

This study confirmed that the DAs of extremely preterm twins are more resistant to COX inhibitors than those of extremely preterm singletons. Hence, treating sPDA may be more difficult in twins than in singletons. No significant differences in sPDA treatment according to chorionicity were identified in this study.

Acknowledgements The authors acknowledge Ritsuko Takahashi, Hiroo Chiba, Kaori Imai, Sachiko Onodera (Department of Neonatology, Sendai Red Cross Hospital), and Sadahiro Sai (Department of Cardiovascular Surgery, Miyagi Children's Hospital, Sendai, Miyagi, Japan) for their assistance in treating the patients.

Author Contributions YM and MK planned the study. TO, YM, MK, TS, and MS collected the data. TO and YM prepared the first draft of the manuscript. TO, YM, MK, TS, and MS critically revised the manuscript.

Funding This study received no financial support.

Data Availability All datasets on which the conclusions of the manuscript rely on are available to the editors, reviewers, and readers without unnecessary restriction.

Declarations

Conflict of interest The authors have no conflicts of interest to declare.

Ethical approval This study protocol was reviewed and approved by the ethics committee of Sendai Red Cross Hospital, approval number 173.

Consent to participate Informed consent was obtained using an opt-out method.

References

- Hamrick SE, Hansmann G (2010) Patent ductus arteriosus of the preterm infant. *Pediatrics* 125:1020–1030. <https://doi.org/10.1542/peds.2009-3506>
- Hermes-DeSantis ER, Clyman RI (2006) Patent ductus arteriosus: pathophysiology and management. *J Perinatol* 26:S14–18. <https://doi.org/10.1038/sj.jp.7211465>
- Clyman RI (2000) Ibuprofen and patent ductus arteriosus. *N Engl J Med* 343:728–730. <https://doi.org/10.1056/NEJM200009073431009>
- Gittenberger-de Groot AC, van Ertbruggen I, Moolaert AJMG, Harinck E (1980) The ductus arteriosus in the preterm infant: histologic and clinical observations. *J Pediatr* 96:88–93. [https://doi.org/10.1016/s0022-3476\(80\)80337-4](https://doi.org/10.1016/s0022-3476(80)80337-4)
- Martin JA, Hamilton BE, Osterman MJK, Driscoll AK, Drake P (2018) Births: final data for 2016. *Natl Vital Stat Reports* 67:1–55
- Sunderam S, Kissin DM, Zhang Y et al (2020) Assisted reproductive technology surveillance – United States. *MMWR Surveill Summ* 69:1–20. <https://doi.org/10.15585/mmwr.ss6909a1>
- Frey HA, Klebanoff MA (2016) The epidemiology, etiology, and costs of preterm birth. *Semin Fetal Neonatal Med* 21:68–73. <https://doi.org/10.1016/j.siny.2015.12.011>
- Monden C, Pison G, Smits J (2021) Twin Peaks: more twinning in humans than ever before. *Hum Reprod* 36:1666–1673. <https://doi.org/10.1093/humrep/deab029>
- Ito S, Yokoyama U, Saito J et al (2017) Attenuation of ductus arteriosus intimal thickening in preterm sheep twins compared with singletons. *J Physiol Sci* 67:723–729. <https://doi.org/10.1007/s12576-017-0565-5>
- El Hajjar M, Vaksman G, Rakza T (2005) Severity of the ductal shunt: a comparison of different markers. *Arch Dis Child Fetal Neonatal Ed* 90:F419–F422. <https://doi.org/10.1136/adc.2003.027698>
- Papile LA, Burstein J, Burstein R, Koffler H (1978) Incidence and evolution of subependymal and intraventricular hemorrhage: a study of infants with birth weights less than 1500 gm. *J Pediatr* 92:529–534. [https://doi.org/10.1016/s0022-3476\(78\)80282-0](https://doi.org/10.1016/s0022-3476(78)80282-0)
- Baker LL, Stevenson DK, Enzmann DR (1988) End-stage periventricular leukomalacia: MR evaluation. *Radiology* 168:809–815. <https://doi.org/10.1148/radiology.168.3.3406411>
- Maalouf EF, Duggan PJ, Rutherford MA et al (1999) Magnetic resonance imaging of the brain in a cohort of extremely preterm infants. *J Pediatr* 135:351–357. [https://doi.org/10.1016/s0022-3476\(99\)70133-2](https://doi.org/10.1016/s0022-3476(99)70133-2)
- Bell MJ, Ternberg JL, Feigin RD et al (1978) Neonatal necrotizing enterocolitis. Therapeutic decisions based upon clinical staging. *Ann Surg* 187:1–7. <https://doi.org/10.1097/00000658-197801000-00001>
- Yokoyama U, Minamisawa S, Quan H et al (2006) Chronic activation of the prostaglandin receptor EP4 promotes hyaluronan-mediated neointimal formation in the ductus arteriosus. *J Clin Invest* 116:3026–3034. <https://doi.org/10.1172/JCI28639>
- Behbodi E, Villamor-Martinez E, Degraeuwe PLJ, Villamor E (2016) Chorioamnionitis appears not to be a risk factor for patent ductus arteriosus in preterm infants: a systematic review and meta-analysis. *Sci Rep* 6:37967. <https://doi.org/10.1038/srep37967>
- Park HW, Choi YS, Kim KS, Kim SN (2015) Chorioamnionitis and patent ductus arteriosus: a systematic review and meta-analysis. *PLoS ONE* 10:e0138114. <https://doi.org/10.1371/journal.pone.0138114>
- Clark R (1932) The mode of production of twins in sheep. *J Anim Sci* 1932:207–209
- Yamaguchi H, Wada K, Nagasawa M et al (2016) Very low birth weight monochorionic diamniotic twins as a risk factor for symptomatic patent ductus arteriosus. *Neonatology* 109:228–234. <https://doi.org/10.1159/000442968>
- Bamberg C, Hecher K (2019) Update on twin-to-twin transfusion syndrome. *Best Pract Res Clin Obstet Gynaecol* 58:55–65. <https://doi.org/10.1016/j.bpobgyn.2018.12.011>
- Riazi-Esfahani M, Alizadeh Y, Karkhaneh R et al (2008) Retinopathy of prematurity: Single versus multiple-birth pregnancies. *J Ophthalmic Vis Res* 3:47–51
- Friling R, Axer-Siegel R, Hersocovici Z, Weinberger D, Sirotta L, Snir M (2007) Retinopathy of prematurity in assisted versus natural conception and singleton versus multiple births. *Ophthalmology* 114:321–324. <https://doi.org/10.1016/j.ophtha.2006.11.010>
- Tseng HC, Sung FC, Mou CH, Lin HY, Chiang CC, Hsia NY et al (2020) Population based retrospective cohort study on risk of retinopathy of prematurity in twins. *PLoS ONE* 15:e0230346. <https://doi.org/10.1371/journal.pone.0230346>
- Hardy P, Dumont I, Bhattacharya M, Hou X, Lachapelle P, Varma DR et al (2000) Oxidants, nitric oxide and prostanoids in the developing ocular vasculature: a basis for ischemic retinopathy. *Cardiovasc Res* 47:489–509. [https://doi.org/10.1016/s0008-6363\(00\)00084-5](https://doi.org/10.1016/s0008-6363(00)00084-5)
- Laughon M, Bose C, Clark R (2007) Treatment strategies to prevent or close a patent ductus arteriosus in preterm infants and outcomes. *J Perinatol* 27:164–170. <https://doi.org/10.1038/sj.jp.7211662>
- Kaga M, Sanjo M, Sato T, Miura Y, Ono T (2019) Safety of conservative approach for persistent patent ductus arteriosus in preterm infants: neurodevelopmental outcomes at 5 years of age. *Tohoku J Exp Med* 249:155–161. <https://doi.org/10.1620/tjem.249.155>

Publisher's Note Springer Nature remains neutral with regard to jurisdictional claims in published maps and institutional affiliations.