



Case report

Exacerbation of eosinophilic COPD and pneumonia in post-treatment pulmonary multidrug-resistant tuberculosis patient: A case report

Daniel Maranatha^{*}, Nur Nubli Julian Parade

Department of Pulmonology and Respiratory Medicine, Faculty of Medicine Airlangga University - Dr Soetomo General Hospital Surabaya, Indonesia



ARTICLE INFO

Keywords:

Eosinophilic COPD
Exacerbation
Multi-drug resistant tuberculosis

ABSTRACT

Eosinophilic chronic obstructive pulmonary disease (COPD) is a COPD phenotype with several clinical characteristics such as eosinophilic airway inflammation, more common in men and less severe COPD. Eosinophilic COPD has more exacerbations but responds well to corticosteroids and bronchodilators. We hereby report the case of a patient who came to us with shortness of breath, fever, wheezing and a cough with yellow phlegm. He had a history of smoking 4.5 pack-year and two episodes of pulmonary tuberculosis (the second was pulmonary multidrug-resistant tuberculosis). He was diagnosed with eosinophilic COPD exacerbation and pneumonia. Intravenous corticosteroids, bronchodilators and antibiotics were given and his condition improved after a week of hospitalisation.

Smoking and pulmonary tuberculosis are risk factors for COPD. In this case, irreversible airflow obstruction is related to COPD and also pulmonary TB. There are several mechanisms that cause airway obstruction in pulmonary tuberculosis, one of which is persistent mycobacterium acting as a co-factor along with smoking and several environmental factors that cause chronic airway inflammation and result in bronchial narrowing with or without parenchymal destruction.

1. Introduction

COPD is a heterogeneous disease [1]. The dominant inflammatory characteristic in COPD is neutrophilic, but some COPD patients have eosinophilic inflammation [2]. Eosinophilic COPD is a phenotype of COPD which is characterized by more than 2% in blood or sputum [3], higher predicted FEV₁%, fewer symptoms with lower St. George Respiratory Questionnaire (SGRQ) and modified Medical Treatment Council (mMRC) score and BODE (body mass index, airflow obstruction, dyspnea, exercise capacity) index [4,5].

There are several studies on the relationship of eosinophilic COPD and exacerbation risk. Eosinophilic COPD patients have higher exacerbation risk [6,7]. COPD patients with persistent high blood eosinophils have a better survival rate than those with persistent lower blood eosinophils [8]. However, eosinophilic COPD responds well to corticosteroid therapy and bronchodilators, which is a positive point [3].

2. Case presentation

A 68-year-old man came to the ER (emergency room) with shortness of breath over the last 3 days, wheezing, a fever and a cough with purulent sputum. He had been experiencing cough and exercise-induced fatigue for one year. Earlier, he had two episodes of pulmonary tuberculosis. Five years earlier, he was treated by primary health care for six months with standard first-line tuberculosis drugs and declared cured but 2 years later he was diagnosed with pulmonary multi-drug resistant TB (MDR-TB). He took anti-tuberculosis therapy from December 30, 2014 until September 30th, 2016 with a regimen consisting of Km-Lfx-Eto-Cs-Z-E during the intensive phase and Lfx-Eto-Cs-Z-E for the continuation phase. Sputum culture converted to negative in the second month of this therapy. He has had Diabetes Mellitus for 5 years and has been on insulin therapy. He had a previous history of smoking 4.5 packs per year but stopped smoking 5 years ago. There was no history of asthma, food or drug allergies.

On physical examination, the patient was alert with respiration rate 28 cycles per minute, blood pressure 140/80 mmHg, a pulse of 100 beats

^{*} Corresponding author. Department of Pulmonology and Respiratory Medicine, Faculty of Medicine, Airlangga University, Dr. Soetomo General Hospital, Jl. Prof. Dr. Moestopo 6-8, Surabaya, 60182, Indonesia.

E-mail address: daniel-maranatha@fk.unair.ac.id (D. Maranatha).

<https://doi.org/10.1016/j.rmcr.2019.100936>

Received 13 August 2019; Received in revised form 21 September 2019; Accepted 21 September 2019

Available online 27 September 2019

2213-0071/© 2019 The Authors.

Published by Elsevier Ltd.

This is an open access article under the CC BY-NC-ND license

(<http://creativecommons.org/licenses/by-nc-nd/4.0/>).

per minute, axillary temperature 38.5 °C. Thoracic examination showed symmetrical chest movement, sonorous percussion, bronchial sounds with rhonchi on the right side of the chest and bilateral wheezing.

Laboratory results were Hemoglobin 14.6 g/dL; Leukocytes $29.130 \times 10^9/L$; Thrombocyte $215.000 \times 10^{12}/L$, BUN 19 mg/dL, Creatinine 1.12 mg/dL, AST 24 U/L, ALT 17 U/L, Total Bilirubin 2.30 mg/dL, Direct Bilirubin 1.42 mg/dL, CRP 307.6 mg/dL, Sodium 132,7 mmol/l, Potassium 3.51 mmol/l, Random blood glucose 379 mg/dL. Blood gas analysis with 3L oxygen were pH 7.50, PaCO₂ 26.6 mmHg, PaO₂ 94.5 mmHg, HCO₃⁻ 21.1 mmol/l, BE -2.2 mmol/L, SaO₂ 98.2%, A-aDO₂ 71.9 mmHg, P/F ratio 337.5. A chest X-ray on day 1 of hospital admission demonstrated fibrosis and consolidation was observed in the right lung field (Fig. 1B).

Sputum microscopy for acid fast bacilli staining was negative, Gram staining showed gram negative bacteria, Xpert MTB/RIF from sputum result was negative for tuberculosis. With aerobic culture of sputum, we found *Acinetobacter baumannii* (sensitive to Gentamycin, Amikacin, Cef-tazidime, Cefoperazone-Sulbactam, Ciprofloxacin, Levofloxacin); MTB culture of sputum was negative. Total IgE serum was 242.9 IU/mL, no worm infection was found by faecal examination, differential count of sputum showed eosinophils 5%, basophils 1.1%, and neutrophils 6.6%. Spirometry was performed after pneumonia and COPD exacerbation resolved. Pre-bronchodilator spirometry results were FVC 3.66 L (107% of predicted), FEV₁ 2.46 L (94% of predicted), FEV₁/FVC 67.2% and post-bronchodilator spirometry results were FVC 3.97 L (116% of predicted), FEV₁ 2.71 L (104% of predicted), FEV₁/FVC 68.2%. Reversibility testing showed 10.1% (250 ml) increase on bronchodilator treatment.

Patient was diagnosed with pneumonia and eosinophilic COPD exacerbation based on findings of high total IgE serum and high eosinophil count of sputum. Eosinophilic COPD has several clinical characteristics, one of them is preserved FEV₁. A corresponding finding was seen in this patient (predictable FEV₁ is 94%). In this case, irreversible airflow obstruction (pre-bronchodilator FEV₁/FVC 67.2% and post-bronchodilator FEV₁/FVC 68.2%) is related to COPD and also previous episodes of pulmonary TB.

Oxygenation was given at 3 L/min, medications given were salbutamol + ipratropium bromide nebulizer solution every 6 hours, methylprednisolone 62.5 mg IV every 8 hours, continuous infusion of aminophylline 480 mg IV in 24 hours, infusion of Cefotaxime 1 g IV every 8 hours, subcutaneous short-acting insulin 10 IU 3 times before meals and long-acting insulin 14 IU at bedtime.

Patient's condition improved after a week of hospitalisation. Laboratory data showed a decrease of leukocyte count ($8.020 \times 10^9/L$). A follow-up chest x-ray 2 weeks later showed resolution of consolidation in the right lung field (Fig. 2).

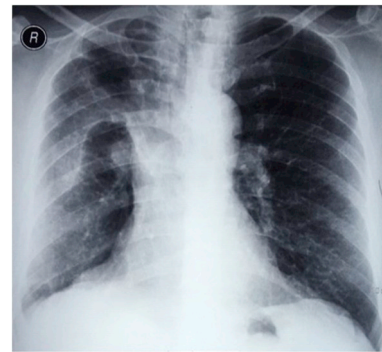


Fig. 2. Follow-up chest x-ray showing resolution of consolidation in right lung field.

3. Discussion

Eosinophilic COPD has several clinical characteristics such as preserved FEV₁. It responded well to corticosteroids during exacerbations. The sub-group analysis of ECLIPSE studies reported that during follow-up studies in COPD patients with persistent eosinophils $\geq 2\%$, a higher proportion of men and fewer current smokers than other COPD groups was found. Another characteristic of eosinophilic COPD is higher predictive FEV₁ [4]. This patient complained about shortness of breath and productive cough since 2016 and his spirometry results were FEV₁/FVC < 0.7 . With predictable FEV₁ is 94%, he was classified as GOLD 1 (mild) according to GOLD classification of airflow limitation.

High sputum eosinophil count (5%) and total IgE (242.9 IU/mL) suggest an eosinophilic inflammation pattern of the airway in this patient. The role of eosinophil as a bio marker for predicting the risk of COPD exacerbation and response to therapy has been widely investigated. A blood eosinophil count higher than 0.34×10^9 cells/L in COPD patients is associated with increased risk of exacerbations [6]. The report of a meta-analysis of 3 clinical trial studies [9] evaluated the effectiveness of oral corticosteroids in COPD exacerbation. Patients with COPD exacerbation who presents with blood eosinophils $\geq 2\%$ without corticosteroid therapy showed greater therapy failure rate than those given corticosteroids (66% vs 11%), while patients with COPD exacerbations with blood eosinophils $< 2\%$ showed no difference in treatment failure rate either given corticosteroids therapy or not (25% vs 22%). In this exacerbation episode, this eosinophilic COPD patient was given IV corticosteroid and inhaled bronchodilators and showed clinical improvement within 7 days.

Chest radiographs of pulmonary MDR-TB patients generally present extensive parenchymal lesions and cavities compared to drug-sensitive TB (DS-TB) [10,11]. However, other literature reported that overall radiological features and abnormality patterns of MDR-TB are not different from DS-TB [12]. Extensive lung lesions and cavitation are risk factors for poor outcomes [13]. In this case, after 18 months of MDR-TB therapy the patient was declared cured with end-of-treatment chest radiograph showed only right lung parenchymal fibrosis and slight tracheal deviation.

Smoking is a risk factor for COPD and pulmonary tuberculosis. Smoking > 10 cigarettes/day doubles the risk of tuberculosis recurrence compared to non or ex-smoker [14]. Interaction of diabetes mellitus and TB are bi-directional. A study on TB and diabetes mellitus interaction showed there is 3 times increase in risk of active TB in DM compared to non-DM [15]. Pulmonary TB is also one of risk factor for COPD [2,16]. Several mechanisms of TB-related chronic airway obstruction (CAO) are said to involve small airway obstruction, bronchiectasis and destruction of extracellular matrix (ECM) [16]. In this patient HRCT (high resolution CT) was not done therefore presence of bronchiectasis and ECM destruction cannot be proven. Another mechanism of TB-related CAO is persistent mycobacterial antigens that induce or act as co-factors along

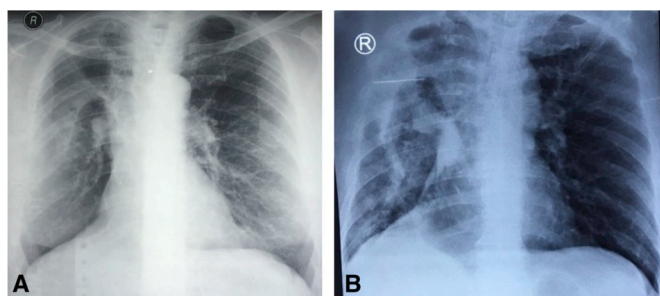


Fig. 1. A. Previous chest X-ray (1 year ago, after pulmonary MDR-TB treatment) showed fibrosis in right lung field; B. Chest X-ray on day 1 of hospital admission demonstrate fibrosis and consolidation in right lung field.

with smoking and some environmental factors such as pollution and biomass smoke and causing chronic airway inflammation which results in bronchial constriction with or without parenchymal destruction [17]. In this patient, there was irreversible obstruction with slight destruction of right lung parenchym.

Pulmonary function after tuberculosis tends to deteriorate and the impairment of lung function is aggravated by the number of tuberculosis episodes. There was a decrease of FEV₁ by 153 ml, 326 ml and 410 ml after one, two and three or more episodes of tuberculosis and decrease of FVC by 96 ml, 286 ml and 345 ml after one, two and three or more episodes of tuberculosis [18]. This patient experienced two episodes of pulmonary tuberculosis, the second was pulmonary MDR-TB. Despite those episodes of pulmonary tuberculosis, spirometry results of the patient showed irreversible obstruction with preserved lung function (FEV₁ 94% predicted).

Sequelae of pulmonary tuberculosis includes changes in bronchial and parenchymal structures such as bronchovascular distortion, bronchiectasis, emphysematous and pulmonary fibrosis [19,20]. Those deformities act as a nidus for the occurrence of TOPD (tuberculosis-associated obstructive pulmonary disease) [21], inhibiting airway secretion clearance which will lead to airway colonization. When the environment supports microbial growth, infection occurs. A study reported a microbial pattern which was dominated by gram-negative bacteria in post-tuberculosis patients with moderate-severe obstruction [20]. Other studies reported that *Streptococcus pneumoniae* is the most common found bacteria followed by *Pseudomonas aeruginosa* in studies of community-acquired pneumonia (CAP) in COPD patients [22, 23]. In this patient, gram negative bacteria (*Acinetobacter baumannii*) was found from an aerobic culture of sputum.

4. Conclusion

A patient with exacerbation of COPD and pneumonia who had 4.5 pack per year and two episodes of pulmonary tuberculosis (the second was pulmonary MDR-TB) was found to have an eosinophilic inflammation pattern of the airway. Despite those episodes of pulmonary tuberculosis, spirometry results of the patient showed irreversible obstruction with preserved lung function.

Declaration of competing interest

There was no conflict of interest in this study. No funding was received for this study. Written informed consent was obtained for publication of this case report.

References

- [1] M. Miravittles, J.J. Soler-Cataluña, M. Calle, J.B. Soriano, Treatment of COPD by clinical phenotypes: putting old evidence into clinical practice, *Eur. Respir. J.* 41 (2013) 1252–1256, <https://doi.org/10.1183/09031936.00118912>.
- [2] Global Initiative for Chronic Obstructive Lung Disease, Global Strategy for the Diagnosis, management, and Prevention of Chronic Obstructive Pulmonary Disease, 2018. www.goldcopd.org. (Accessed 1 April 2018).
- [3] J. Ho, W. He, M.T. V Chan, G. Tse, T. Liu, S.H. Wong, C.C.H. Leung, W.T. Wong, S. Tsang, L. Zhang, R.Y.P. Chan, T. Gin, J. Leung, B.W.M. Lau, W.K.K. Wu, S.P. C. Ngai, Eosinophilia and clinical outcome of chronic obstructive pulmonary disease: a meta-analysis, *Sci. Rep.* 7 (2017) 13451, <https://doi.org/10.1038/s41598-017-13745-x>.
- [4] D. Singh, U. Kolsun, A. Ravi, C.E. Brightling, N. Locantore, A. Agusti, et al., Eosinophilic inflammation in COPD: prevalence and clinical characteristics, *Eur. Respir. J.* 44 (2014) 1697–1700, <https://doi.org/10.1183/09031936.00162414>.
- [5] D. Tworek, A. Antczak, Eosinophilic COPD—a distinct phenotype of the disease, *Adv Respir Med* 85 (2017) 271–276, <https://doi.org/10.5603/ARM.2017.0045>.
- [6] S. Vadel-Krogh, S.F. Nielsen, P. Lange, Blood eosinophils and exacerbations in chronic obstructive pulmonary disease. The Copenhagen general population study, *Am. J. Respir. Crit. Care Med.* 193 (2016) 965–974, <https://doi.org/10.1164/rccm.201509-1869OC>.
- [7] S. Couillard, P. Larivee, J. Courteau, A. Vanessa, Eosinophils in chronic obstructive pulmonary disease exacerbations are associated with increased readmissions, *Chest* 151 (2017) 366–373, <https://doi.org/10.1016/j.chest.2016.10.003>.
- [8] S. Hye Shin, H. Yun Park, D. Kang, J. Cho, S. Ok Kwon, J. Hun Park, J. Seung Lee, Y.-M. Oh, D.D. Sin, W. Jin Kim, S.-D. Lee, K. Study Group, Serial blood eosinophils and clinical outcome in patients with chronic obstructive pulmonary disease, *Respir. Res.* 19 (2018) 134, <https://doi.org/10.1186/s12931-018-0840-x>.
- [9] M. Bafadhel, L. Davies, P.M.A. Calverley, S.D. Aaron, C.E. Brightling, I.D. Pavord, Blood eosinophil guided prednisolone therapy for exacerbation of COPD: a further analysis, *Eur. Respir. J.* 44 (2014) 789–791, <https://doi.org/10.1183/09031936.00062614>.
- [10] A.G. Icksan, M.R.S. Napitupulu, M.A. Nawas, F. Nurwidya, Chest X-ray findings comparison between multi-drug-resistant tuberculosis and drug-sensitive tuberculosis, *J. Nat. Sci. Biol.* 9 (2018) 42–46, <https://doi.org/10.4103/jnsbm.JNSBM.79.17>.
- [11] S. Zahirifard, M.V. Amiri, M. Bakhshayesh Karam, S.M. Mirsaedi, A. Ehsanpour, M.R. Masjedi, The radiological spectrum of pulmonary multidrug-resistant tuberculosis, *Iran. J. Radiol.* 1 (2003) 161–166.
- [12] J.E. Fishman, G.J. Sais, D.S. Schwartz, J. Otten, Radiographic findings and pattern in multidrug-resistant tuberculosis, *J. Thorac. Imaging* 13 (1998) 65–71.
- [13] J.B. Te Riele, V. Buser, G. Calligoro, A. Esmail, G. Theron, M. Lesosky, et al., Relationship between chest radiographic characteristics, sputum bacterial load, and treatment outcomes in patients with extensively drug-resistant tuberculosis, *Int. J. Infect. Dis.* 79 (2019) 65–71, <https://doi.org/10.1016/j.ijid.2018.10.026>.
- [14] Y.F. Yen, M.Y. Yen, Y.S. Lin, Y.P. Lin, H.C. Shih, L.H. Li, et al., Smoking increases risk of recurrence after successful anti-tuberculosis treatment: a population based study, *Int. J. Tuberc. Lung Dis.* 18 (2014) 492–498, <https://doi.org/10.5588/ijtld.13.0694>.
- [15] M.B. Yeon CY Murray, Diabetes mellitus increases the risk of active tuberculosis: a systematic review of 13 observational studies, *PLoS Med.* 5 (2008) e152, <https://doi.org/10.1371/journal.pmed.0050152>.
- [16] M. Sarkar, Srinivasa, I. Madabhavi, K. Kumar, Tuberculosis associated chronic obstructive pulmonary disease, *Clin. Res. J* 11 (2017) 285–295, <https://doi.org/10.1111/crj.12621>.
- [17] B.W. Allwood, R. Gillespie, Galperin-Aizenberg, M. Bateman, H. Olckers, L. Taborda-Barata, et al., Obstructive pulmonary disease in patients with previous tuberculosis: pathophysiology of a community-based cohort, *S. Afr. Med. J.* 107 (2017) 440–445, <https://doi.org/10.7196/SAMJ.2017.v107i5.12118>.
- [18] E. Hnizdo, T. Sing, G. Churchyard, Chronic pulmonary function impairment caused by initial and recurrent pulmonary tuberculosis following treatment, *Thorax* 55 (2000) 32–38, <https://doi.org/10.1136/thorax.55.1.32>.
- [19] I.L. de la Mora, D. Martinez-Oceguera, R. Laniado-Laborin, Chronic airway obstruction after successful treatment of tuberculosis and its impact on quality of life, *Int. J. Tuberc. Lung Dis.* 19 (2015) 808–810, <https://doi.org/10.5588/ijtld.14.0983>.
- [20] N. Srivastava, S. Saxena, K.K. Kawre, P. Tiwari, L. Dave, P. Sharma, Spirometric and bacteriological profile in post tubercular bronchiectasis, *Ind J Res* 6 (2017) 82–85.
- [21] R. Ramakrishna, P. Kumar, Tuberculosis airway disease and bronchiectasis - a debilitating trio, *J. Evid. Base. Med. Healthc.* 3 (2016) 818–822, <https://doi.org/10.18410/jebmh/2016/186>.
- [22] A. Liapikou, E. Polverino, S. Ewig, C. Cilloniz, M.A. Marcos, J. Mensa, S. Bello, I. Martin-Loeches, R. Menéndez, A. Torres, Severity and outcomes of hospitalised community-acquired pneumonia in COPD patients, *Eur. Respir. J.* 39 (2012) 855–861, <https://doi.org/10.1183/09031936.00067111>.
- [23] M.I. Restrepo, E.M. Mortensen, J.A. Pugh, A. Anzueto, COPD is associated with increased mortality in patients with community-acquired pneumonia, *Eur. Respir. J.* 28 (2006) 346–351, <https://doi.org/10.1183/09031936.06.00131905>.