

CASE REPORT

Open Access



# Whole exome sequencing of benign pulmonary metastasizing leiomyoma reveals mutation in the *BMP8B* gene

Deniss Sõritsa<sup>1,2,3\*</sup> , Hindrek Teder<sup>3,4</sup>, Retlav Roosipuu<sup>5</sup>, Hannes Tamm<sup>5</sup>, Triin Laisk-Podar<sup>1,3</sup>, Pille Soplepmann<sup>1,2,6</sup>, Alan Altraja<sup>7,8</sup>, Andres Salumets<sup>1,3,4,9</sup> and Maire Peters<sup>1,3</sup>

## Abstract

**Background:** Benign metastasizing leiomyoma (BML) is an orphan neoplasm commonly characterized by pulmonary metastases consisting of smooth muscle cells. Patients with BML have usually a current or previous uterine leiomyoma, which is therefore suggested to be the most probable source of this tumour. The purpose of this case report was to determine the possible genetic grounds for pulmonary BML.

**Case presentation:** We present a case report in an asymptomatic 44-year-old female patient, who has developed uterine leiomyoma with subsequent pulmonary BML. Whole exome sequencing (WES) was used to detect somatic mutations in BML lesion. Somatic single nucleotide mutations were identified by comparing the WES data between the pulmonary metastasis and blood sample of the same BML patient. One heterozygous somatic mutation was selected for validation by Sanger sequencing. Clonality of the pulmonary metastasis and uterine leiomyoma was assessed by X-chromosome inactivation assay.

**Conclusions:** We describe a potentially deleterious somatic heterozygous mutation in bone morphogenetic protein 8B (*BMP8B*) gene (c.1139A > G, Tyr380Cys) that was identified in the pulmonary metastasis and was absent from blood and uterine leiomyoma, and may play a facilitating role in the metastasizing of BML. The clonality assay confirmed a skewed pattern of X-chromosome inactivation, suggesting monoclonal origin of the pulmonary metastases.

**Keywords:** Benign metastasizing leiomyoma, BMP8B, Endometriosis, GnRH agonists, Pulmonary lesion, Somatic gene mutation

## Background

Benign metastasizing leiomyoma (BML) is a rare condition that occurs mainly in premenopausal women [1] and is characterized most commonly by pulmonary and lymph node metastases consisting of mature smooth muscle cells [2]. BML is usually associated with a current or previous uterine leiomyoma, and based on histological findings and positive staining for oestrogen and progesterone receptors [3], uterine leiomyomas have been proposed as the most probable source of this disease. The lesions are slow-growing and usually the disease has a favourable prognosis. However, there are

no standardized guideline-based treatments for BML and surgical removal along with hormone therapy is the most frequently used management [3, 4]. Although uterine leiomyomas are the most probable source of the metastases, the pathogenesis of BML has still remained enigmatic. Among other theories, it has been suggested that BML may emerge from lymphatic and hematological spread of the uterine tissue or via coelomic metaplasia [5]. The origin of metastases from uterine tissues is supported by molecular studies demonstrating the same clonal origin of the metastases of BML and original uterine leiomyomas [6–8]. Almost half of the uterine leiomyomas are cytogenetically abnormal and furthermore, they possess gene mutations, with mediator complex subunit 12 as the most frequently affected gene [9]. The occurrence of chromosomal aberrations in BML metastases has also been shown

\* Correspondence: [deniss@elitekliinik.ee](mailto:deniss@elitekliinik.ee)

<sup>1</sup>Institute of Clinical Medicine, Department of Obstetrics and Gynaecology, University of Tartu, Tartu, Estonia

<sup>2</sup>Elite Clinic, Sangla 63, 50407 Tartu, Estonia

Full list of author information is available at the end of the article



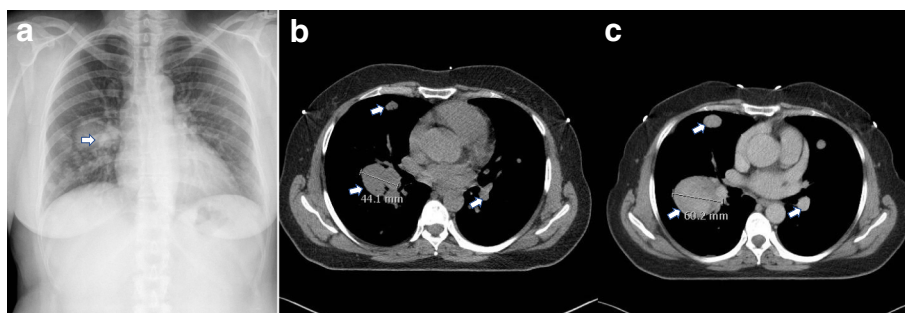
[10, 11]; however, only one study has explored single nucleotide variations (SNVs) and short insertions/deletions (indels) in metastases using massively parallel sequencing of a panel of 409 cancer-related genes [8]. Here, we present the results of whole exome sequencing (WES) of the BML metastasis from a 44-year-old female patient, who had developed uterine leiomyoma with subsequent pulmonary BML.

### Case presentation

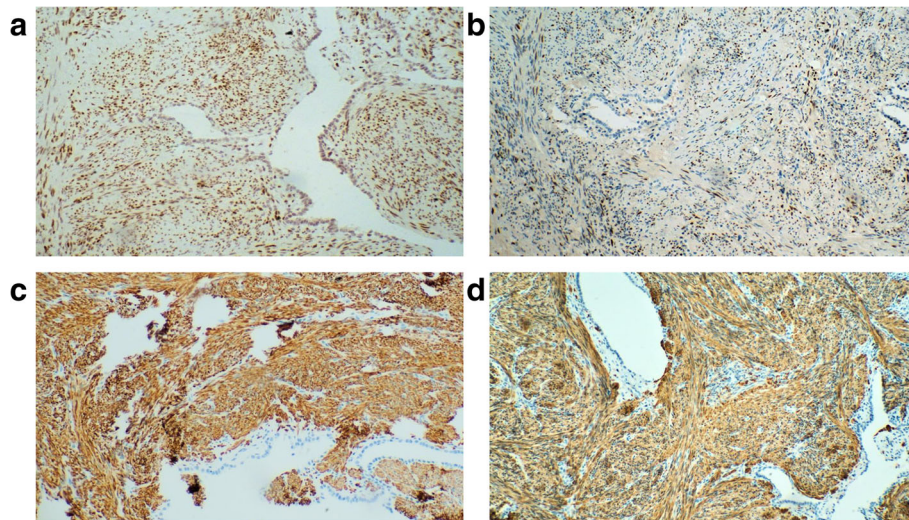
Caucasian female, at the age of 34, underwent abdominal uterine myomectomy because of anaemia, but not all nodules were removed. Six years later, she underwent laparoscopy-assisted supracervical hysterectomy (the weight of the uterus was 288 g) because of recurrent anaemia and uterine leiomyomas. Pathohistologically, the specimens presented as a uterine smooth muscle tumour without evidence of malignancy. Three years later, at the age of 43, laparoscopic salpingo-oophorectomy was performed because of a 6-cm endometrioma in the right ovary, and superficial endometriotic lesions on the left ovary were coagulated. In the same year, during a routine chest X-ray examination, multiple well-defined round pulmonary nodules of various sizes up to 40 mm in diameter were detected (Fig. 1a). After 1-year follow-up, a high-resolution computed tomography (HRCT)-scan of the chest confirmed the largest nodule of having a diameter of 40 mm. Video-assisted thoracoscopic surgery of the left lung with a biopsy was performed in November 2013. Immunohistochemistry (IHC) analysis of lung lesion specimens revealed positive staining for oestrogen receptor  $\alpha$ , progesterone receptor, desmin and  $\alpha$ -smooth muscle actin (Fig. 2a-d), while staining for Ki67 revealed low mitotic activity (< 1–5%). On the basis of pathohistology and IHC signature, the diagnosis of BML was established, and subsequently, the patient received a treatment with gonadotropin-releasing hormone (GnRH) agonist, goserelin (Zoladex, AstraZeneca UK Ltd. London, UK), for 6 months. The 4-month and 6-month follow-up chest X-ray showed that lesions, formerly undergoing progressive

enlargement, had remained unchanged (Fig. 3). However, the treatment was discontinued because of the disagreeable side effects (weight gain of > 10 kg, flushing and profuse sweating), and dietary and lifestyle modifications to address the overweight issue were suggested. After a 5-month treatment-free period (in January 2015), a new chest X-ray examination revealed enlargement of the metastases (the size of the largest nodule has increased by 4 mm reaching 44 mm, Fig. 1b) and the patient complained of shortness of breath occurring more easily. Six months later, a new HRCT-scan revealed further enlargement of the metastases as the diameter of the largest lesion was 60 mm (Figs. 1c and 3). The patient still decided to postpone the next treatment because of the fear of the side-effects. After the following 5 months (November 2015), additional enlargement of metastases was detected, with the largest lesion gaining a diameter of 70 mm. The monitoring continued without treatment as the patient reported her general health and wellbeing to be satisfactory (presumably because of the normalization of body weight), and refused from GnRH agonist treatment. Seven months later, the follow-up HRCT-scan showed the majority of the metastases had not changed. In October 2016, the second 6-month treatment with goserelin was initiated because of the further enlargement of some lesions, and the last chest X-ray in January 2017 showed stabilization of the size of majority of the lesions; moreover, the largest nodules had decreased by about 10% in size. The patient had no complaints except for weight regain.

During the visits to the pulmonologist, several functional tests were performed (Fig. 3). The values for diffusing capacity of the lungs for carbon monoxide (DLCO) were either within the normal range or slightly below the lower limit of normal (normal defined as 74% of the predicted value [12]), being in the range of 69.6–86.8% predicted. Post-bronchodilator forced vital capacity (FVC) values were below the lower limit of normal (defined as 80% of the predicted value for the patient), being 55.0–69.0% predicted. Patient's 6-min walk test (6MWT) results



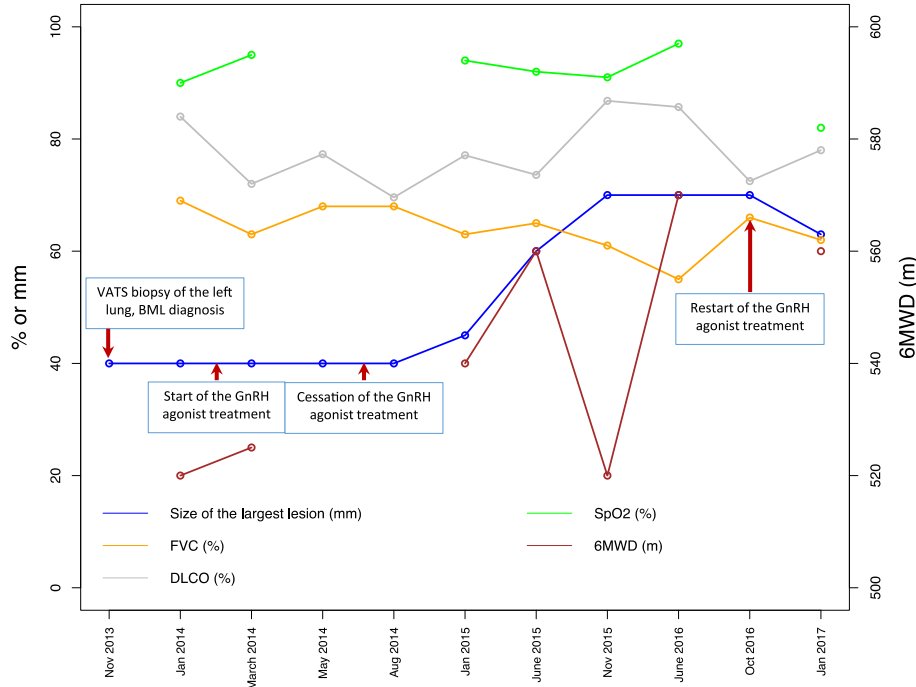
**Fig. 1** X-ray (a) and high resolution computed tomography (b, c) images of the BML patient from different examinations (November 2013, January 2015 and June 2015, respectively). Pulmonary metastases are shown by arrows



**Fig. 2** Immunohistochemistry of the BML patient’s lung metastasis showing positivity for oestrogen receptor  $\alpha$  (a), progesterone receptor (b), desmin (c) and  $\alpha$ -smooth muscle actin (d). Original magnifications  $\times 100$

were within the normal range, with absolute values of the 6-min walk distance (6MWD) being 520–570 m (100–139% of the predicted lower limit of normal values), accompanied with mild breathlessness during the 6MWT, but following by an adequate recovery.

The values of oxygen saturation measured by pulse oximetry ( $SpO_2$ ) during the 6MWT were 90–97%, i.e. normal or slightly below the lower limit of normal (94%), with only one exceptional registered value indicative of desaturation (81%).



**Fig. 3** The dynamics of pulmonary function parameters and the size of the largest lung metastasis of the BML patient. The size of the largest lung metastasis is given in mm’s (left side Y-axis), diffusing capacity of the lungs for carbon monoxide (DLCO) and post-bronchodilator forced vital capacity (FVC) are given as % predicted (left side Y-axis), the six-minute walk distances (6MWD) are given in meters (right side Y-axis), and the lowest oxygen saturation ( $SpO_2$ ) during the six-minute walk test is shown as % (left side Y-axis) of the lower limit of normal. VATS - video-assisted thoracoscopic surgery

To find possible genetic causes of BML, WES of blood and pulmonary metastasis was performed (detailed description of the WES is given in Additional file 1).

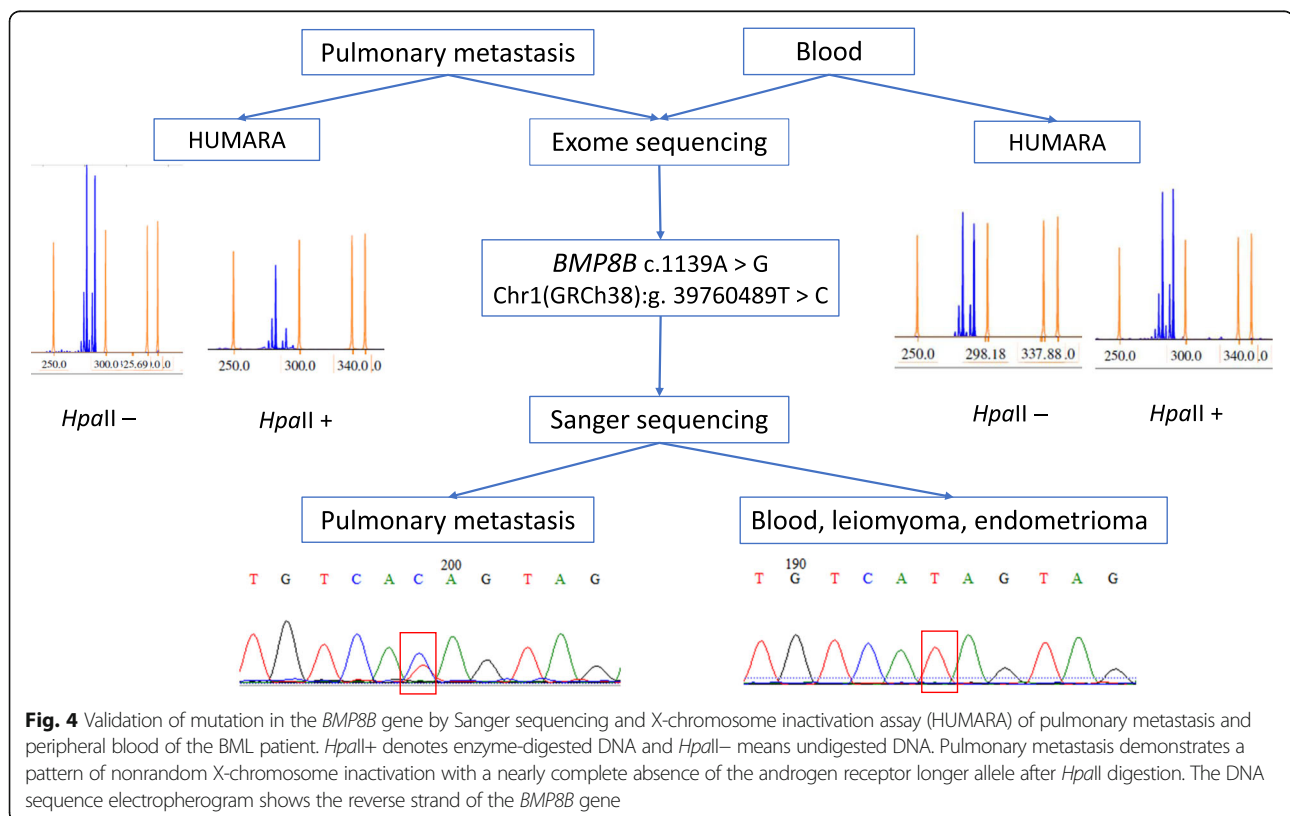
The mean sequencing depth was 57× for both DNA samples. The manual inspection of the metastasis and peripheral blood sample data did not reveal regions with aberrant sequencing coverage, suggesting that no large chromosomal alterations (deletions or duplications) were present in the coding areas. After filtering the exome data to exclude germline variants, a total of 121 potential somatic mutations (SNVs and short indels) affecting 109 genes (Additional file 2) were identified from the protein-coding gene regions of DNA from the pulmonary metastasis. The discovered somatic variants were manually inspected and the candidate mutations were filtered according to the following criteria: (1) mutations in splice regions, and coding exons that affect amino acids; (2) predicted deleterious by SIFT or PolyPhen2; (3) as the pulmonary metastasis was histologically estimated to consist almost entirely of smooth muscle cells (> 90%) then in case of heterozygous mutations, similar allelic depths for the reference and alternative allele were expected; and (4) reported or suggested to be involved in tumorigenesis. After rigorous filtering, one heterozygous mutation in the *BMP8B* (bone morphogenetic protein 8B) gene was found to correspond to the filtering criteria. The sequencing depths of the alternative and

reference alleles for BML and germline/blood DNA were 57/60 and 0/97, respectively. PolyPhen 2 and SIFT predicted this variant as probably damaging (score 0.994) and deleterious, respectively. Sanger sequencing confirmed the presence of an amino acid-affecting heterozygous mutation (c.1139A > G, Y380C) in the seventh exon of the *BMP8B* gene in the pulmonary metastasis (Fig. 4). The tissue specimens of endometrioma and leiomyoma from the same patient were also examined for this variation, but neither of the tissues had this mutation.

The human androgen receptor (AR) based X-chromosome inactivation assay (HUMARA) was used (as described elsewhere [13]) to determine the clonality status of the pulmonary metastasis and the uterine leiomyoma. Analysis of both of these specimens revealed a similar pattern of skewed X-chromosome inactivation, with an inactivation of the chromosome carrying the shorter AR allele (Fig. 4 and Additional file 3). On the contrary, the blood DNA demonstrated a random inactivation of X-chromosomes.

## Discussion and conclusions

We describe WES results of the patient, who has developed uterine leiomyoma with subsequent pulmonary BML. In addition, the patient suffered from endometriosis presenting as a large endometrioma of the right ovary and superficial lesions on the left ovary. The



mechanisms used to explain the pathogenesis of endometriosis [14, 15] can also apply to BML. Hence, it has been proposed that BML may evolve from lymphatic and hematological spread, coelomic metaplasia and intraperitoneal seeding from ruptured leiomyoma [16]. Furthermore, there is an evidence from molecular studies supporting the hypothesis that leiomyoma could be the source of this benign tumour, as X-chromosome inactivation assay has confirmed the clonal origin of uterine tumours and BML [6, 7, 17]. A very recent study that showed shared SNVs between synchronous pulmonary and uterine leiomyomata gives further strong evidence to support a clonal relationship between these two tumours [8]. Copy number variance (CNV) analysis has also been used to explore the origin of metastases and in some cases, similar chromosomal aberrations have been found in tumours of both locations, confirming their genetic relationship [10, 18]. In addition, the presence of consistent chromosomal deletions of 19q and 22q in all five investigated BML cases was demonstrated by Nucci et al. [11]. However, these deletions are not characteristic to rearrangements frequently found in uterine leiomyomas, with chromosomes 6, 7, 10 and 12 most commonly affected [19], and the authors proposed that BML may arise from a biologically distinct minority of uterine leiomyomas with an innate metastatic potential [11]. However, in some cases, CNV analysis showed balanced karyotype of BML specimens without any changes in DNA copy numbers [6, 17], as was also the case for the patient described in the current study.

Most of BML cases have been detected on routine chest X-rays. BML is a rare condition that should always be considered in case of incidental lung findings in women with a previous or coincident history of uterine leiomyoma. The presence of oestrogen and progesterone receptors supports a connection between BML and female reproductive tract and makes the basis for the rationale for using hormonal treatment [5, 20]. GnRH agonists are often used and are described to give favourable therapeutic outcomes in terms of preventing the enlargement of nodules [21]. According to the published data, the periods of GnRH agonist treatment vary from 3 to 42 months [22, 23]. In the current case, we had a unique opportunity to longitudinally observe the growth dynamics of the pulmonary metastases, which followed the pattern of goserelin treatment. The enlargement of metastases, when patient discontinued the treatment because of the unfavourable side effects, provided the rationale for continuing the hormone therapy.

According to our knowledge, this is the first study using WES to explore SNVs of BML specimen. Even though WES revealed several somatic candidate-mutations in the pulmonary BML tissue, only a heterozygous mutation in the *BMP8B* gene corresponded to the criteria we used to

select the probable disease-associated mutations. Wu et al. used the Ion AmpliSeq Comprehensive Cancer Panel that targets the exons of 409 tumor suppressor genes and oncogenes to find possible mutations in three cases of synchronous pulmonary and uterine leiomyomata tissues [8]. Somatic mutations were found in all investigated tissues, and shared alterations between uterine leiomyoma and pulmonary metastases were found in two out of three cases, but no recurrent mutations were observed. The authors concluded that the probability of finding the same alterations in different cases was very low as none of the detected mutations has commonly been described in leiomyomas. Unfortunately, as the *BMP8B* gene is not a common cancer-gene, it is also not included in the Cancer Panel and therefore the presence or absence of mutations in this gene could not be evaluated in the study by Wu and colleagues. BMPs represent a family of signalling molecules that belong to the transforming growth factor- $\beta$  superfamily of proteins and play crucial roles in all organ systems [24]. In cancer, BMPs can either suppress or promote tumorigenesis and are involved in the metastasis of cancer cells [25]. *BMP8B* is a gene encoding a protein with a role in spermatogenesis [26] and in thermogenesis [27]. *BMP8B* has not been detected as a mutational cancer driver; however, there are some reports describing altered expression of the *BMP8B* gene in cancers [28–30]. Reduced *BMP8B* mRNA expression has been detected in tumour tissues compared to adjacent normal tissues, whereas experimental induction of the *BMP8B* overexpression inhibited cell growth [29], proposing that *BMP8B* could act as a tumour suppressor gene [28]. This gene locates on the short arm of chromosome 1 and the mutation detected in pulmonary metastasis locates in the last (seventh) exon of the gene. The mutation affects amino acid constitution of the protein (tyrosine-to-cysteine substitution) and because both PolyPhen2 and SIFT annotate it as probably damaging, we can speculate that it plays a role in BML lesions' growth and metastasis. Unfortunately, we had no possibility to test the impact of the mutation on protein function level as we had only limited FFPE material of pulmonary metastasis. The same mutation was not present in the leiomyoma tissue of the patient; and therefore, we can assume that a) the mutation has occurred in the lung BML lesion only; b) the patient suffered from multiple leiomyomas, and the pulmonary BML did not arise from that particular uterine leiomyoma tissue analysed in the current study; or c) BML does not originate from leiomyoma. It has been demonstrated that leiomyomas develop as clonal lesions but multiple nodules in a single uterus may have different clonal origin [31] and harbour different chromosomal aberrations [32]. Also, the study by Wu et al. revealed shared somatic mutations only in two out of three pairs of uterine leiomyoma and BML metastases [8]. Our clonality analysis confirmed the non-

random X-chromosome inactivation in both uterine leiomyoma and pulmonary metastasis, with the same allele being inactivated. However, this finding can also be coincidental showing just the clonal origin of these tumours.

In addition to leiomyoma, the patient suffered from endometriosis that resulted in the development of a large ovarian endometrioma. According to the theories of endometriosis development, endometrial tissue is the most probable source of endometriosis. Therefore, we examined the endometrioma specimen for the presence of the *BMP8B* gene mutation, but the analysis revealed only a wild-type allele. Thus, the co-occurrence of endometriosis and BML in the current patient is probably random, as previously only a few reports have described BML-associated endometriosis [33, 34].

In conclusion, we described the longitudinal follow-up of a patient suffering from BML. We demonstrated that GnRH agonist therapy gave favourable outcome and treatment discontinuation caused enlargement of the lung lesions. Genetic analysis revealed a *BMP8B* gene mutation in the lung lesion; however, the link between mutations in the *BMP8B* gene and pulmonary BML needs to be corroborated by further studies involving additional patients and exploring the functional consequences of the here-described mutation.

## Additional files

**Additional file 1:** Supplementary methods. DNA extraction and sequencing. (DOCX 21 kb)

**Additional file 2: Table S1.** Summary of somatic variants identified in pulmonary metastasis of the BML patient by whole exome sequencing. (XLSX 34 kb)

**Additional file 3: Figure S1.** A non-random X-chromosome inactivation pattern of leiomyoma specimen of the BML patient. *Hpa*II + denotes enzyme-digested DNA and *Hpa*II – means undigested DNA. (PPTX 46 kb)

## Abbreviations

BML: Benign metastasizing leiomyoma; BMP8B: Bone morphogenetic protein 8B; CNV: Copy number variance; FFPE: Formalin-fixed, paraffin-embedded; GnRH: Gonadotropin-releasing hormone; HRCT: High-resolution computed tomography; IHC: Immunohistochemistry; SNV: Single nucleotide variation; WES: Whole exome sequencing

## Acknowledgements

We thank the patient who kindly gave consent for these findings to be presented in this case report.

## Funding

The research was funded by grant IUT34–16 from the Estonian Ministry of Education and Research, by Enterprise Estonia, grant no EU48695, and by the European Commission Horizon 2020 research and innovation programme under grant agreements 692065 (project WIDENLIFE) and 691058 (MSCA-RISE-2015 project MOMENDO).

## Availability of data and materials

A list of all variants detected in the pulmonary metastasis is available in Additional file 2. The WES data that support the findings of this study are available upon request from the author of this case report [MP]. This data is not publicly available due to information that could compromise the patient's privacy.

## Authors' contributions

DS analyzed and interpreted the patient's data and wrote the case report. HiT performed analysis of the WES data. RR and HaT performed and interpreted the histological examination of both the pulmonary metastases and uterine leiomyoma. TL-P critically reviewed the case report and created Fig. 3. PS analysed and interpreted the patient's data regarding the gynaecological examinations. AA analyzed and interpreted the patient's data regarding the pulmonary involvement, performed the patient's treatment and follow-up, as well as reviewed critically the case report. AS analyzed data and contributed to writing the case report. MP performed and interpreted the DNA analyses and participated in writing of the case report. All authors read and approved the final case report.

## Ethics approval and consent to participate

Written informed consent for sequencing analysis and any other DNA manipulations was obtained from the patient. As the data presented are part of the clinical practice at the Tartu University Hospital and are being published retrospectively, the ethics committee was not involved.

## Consent for publication

The patient has signed informed consent form for publication, including the clinical information and images.

## Competing interests

The authors declare that they have no competing interests.

## Publisher's Note

Springer Nature remains neutral with regard to jurisdictional claims in published maps and institutional affiliations.

## Author details

<sup>1</sup>Institute of Clinical Medicine, Department of Obstetrics and Gynaecology, University of Tartu, Tartu, Estonia. <sup>2</sup>Elite Clinic, Sangla 63, 50407 Tartu, Estonia. <sup>3</sup>Competence Centre on Health Technologies, Tartu, Estonia. <sup>4</sup>Institute of Biomedicine and Translational Medicine, Department of Biomedicine, University of Tartu, Tartu, Estonia. <sup>5</sup>Department of Pathology, Tartu University Hospital, Tartu, Estonia. <sup>6</sup>Tartu University Hospital's Women's Clinic, Tartu, Estonia. <sup>7</sup>Department of Pulmonary Medicine, University of Tartu, Tartu, Estonia. <sup>8</sup>Lung Clinic, Tartu University Hospital, Tartu, Estonia. <sup>9</sup>Department of Obstetrics and Gynaecology, University of Helsinki and Helsinki University Hospital, Helsinki, Finland.

Received: 28 June 2017 Accepted: 24 January 2018

Published online: 31 January 2018

## References

- Rivera JA, Christopoulos S, Small D, Trifiro M. Hormonal manipulation of benign metastasizing leiomyomas: report of two cases and review of the literature. *J Clin Endocrinol Metab.* 2004;89(7):3183–8.
- Abell MR, Littler ER. Benign metastasizing uterine leiomyoma. Multiple lymph nodal metastases. *Cancer.* 1975;36(6):2206–13.
- Kayser K, Zink S, Schneider T, Dienemann H, Andre S, Kaltner H, et al. Benign metastasizing leiomyoma of the uterus: documentation of clinical, immunohistochemical and lectin-histochemical data of ten cases. *Virchows Arch.* 2000;437(3):284–92.
- Abu-Rustum NR, Curtin JP, Burt M, Jones WB. Regression of uterine low-grade smooth-muscle tumors metastatic to the lung after oophorectomy. *Obstet Gynecol.* 1997;89(5 Pt 2):850–2.
- Awonuga AO, Shavell VI, Imudia AN, Rotas M, Diamond MP, Puscheck EE. Pathogenesis of benign metastasizing leiomyoma: a review. *Obstet Gynecol Surv.* 2010;65(3):189–95.
- Lin J, Song X, Liu C. Pelvic intravascular leiomyomatosis associated with benign pulmonary metastasizing leiomyoma: clinicopathologic, clonality, and copy number variance analysis. *Int J Gynecol Pathol.* 2014;33(2):140–5.
- Patton KT, Cheng L, Papavero V, Blum MG, Yeldandi AV, Adley BP, et al. Benign metastasizing leiomyoma: clonality, telomere length and clinicopathologic analysis. *Mod Pathol.* 2006;19(1):130–40.
- Wu RC, Chao AS, Lee LY, Lin G, Chen SJ, Lu YJ, et al. Massively parallel sequencing and genome-wide copy number analysis revealed a clonal relationship in benign metastasizing leiomyoma. *Oncotarget.* 2017;8(29):47547–54.

9. Styer AK, Rueda BR. The epidemiology and genetics of uterine Leiomyoma. *Best Pract Res Clin Obstet Gynaecol.* 2016;34:3–12.
10. Lee HJ, Choi J, Kim KR. Pulmonary benign metastasizing leiomyoma associated with intravenous leiomyomatosis of the uterus: clinical behavior and genomic changes supporting a transportation theory. *Int J Gynecol Pathol.* 2008;27(3):340–5.
11. Nucci MR, Drapkin R, Dal Cin P, Fletcher CD, Fletcher JA. Distinctive cytogenetic profile in benign metastasizing leiomyoma: pathogenetic implications. *Am J Surg Pathol.* 2007;31(5):737–43.
12. Viljanen AA, Viljanen BC, Halttunen PK, Kreis KE. Pulmonary diffusing capacity and volumes in healthy adults measured with the single breath technique. *Scand J Clin Lab Invest Suppl.* 1982;159:21–34.
13. Laisk T, Haller-Kikkatalo K, Laanpere M, Jakovlev U, Peters M, Karro H, et al. Androgen receptor epigenetic variations influence early follicular phase gonadotropin levels. *Acta Obstet Gynecol Scand.* 2010;89(12):1557–63.
14. Giudice LC, Kao LC. Endometriosis. *Lancet.* 2004;364(9447):1789–99.
15. Hull ML, Escareno CR, Godsland JM, Doig JR, Johnson CM, Phillips SC, et al. Endometrial-peritoneal interactions during endometriotic lesion establishment. *Am J Pathol.* 2008;173(3):700–15.
16. Beck MM, Biswas B, D'Souza A, Kumar R. Benign metastasizing leiomyoma after hysterectomy and bilateral salpingo-oophorectomy. *Hong Kong Med J.* 2012;18(2):153–5.
17. Tietze L, Gunther K, Horbe A, Pawlik C, Klosterhalfen B, Handt S, et al. Benign metastasizing leiomyoma: a cytogenetically balanced but clonal disease. *Hum Pathol.* 2000;31(1):126–8.
18. Bowen JM, Cates JM, Kash S, Itani D, Gonzalez A, Huang D, et al. Genomic imbalances in benign metastasizing leiomyoma: characterization by conventional karyotypic, fluorescence in situ hybridization, and whole genome SNP array analysis. *Cancer Genet.* 2012;205(5):249–54.
19. Hodge JC, Morton CC. Genetic heterogeneity among uterine leiomyomata: insights into malignant progression. *Hum Mol Genet.* 2007;16 Spec No 1:R7–13.
20. Lewis EI, Chason RJ, DeCherney AH, Armstrong A, Elkas J, Venkatesan AM. Novel hormone treatment of benign metastasizing leiomyoma: an analysis of five cases and literature review. *Fertil Steril.* 2013;99(7):2017–24.
21. Taftaf R, Starnes S, Wang J, Shipley R, Namad T, Khaled R, et al. Benign metastasizing leiomyoma: a rare type of lung metastases-two case reports and review of the literature. *Case Rep Oncol Med.* 2014; 2014:842801.
22. Hague WM, Abdulwahid NA, Jacobs HS, Craft I. Use of LHRH analogue to obtain reversible castration in a patient with benign metastasizing leiomyoma. *Br J Obstet Gynaecol.* 1986;93(5):455–60.
23. Jacobson TZ, Rainey EJ, Turton CW. Pulmonary benign metastasizing leiomyoma: response to treatment with goserelin. *Thorax.* 1995;50(11): 1225–6.
24. Guo X, Wang XF. Signaling cross-talk between TGF-beta/BMP and other pathways. *Cell Res.* 2009;19(1):71–88.
25. Ehata S, Yokoyama Y, Takahashi K, Miyazono K. Bi-directional roles of bone morphogenetic proteins in cancer: another molecular Jekyll and Hyde? *Pathol Int.* 2013;63(6):287–96.
26. Wang RN, Green J, Wang Z, Deng Y, Qiao M, Peabody M, et al. Bone morphogenetic protein (BMP) signaling in development and human diseases. *Genes Dis.* 2014;1(1):87–105.
27. Whittle AJ, Carobbio S, Martins L, Slawik M, Hondares E, Vazquez MJ, et al. BMP8B increases brown adipose tissue thermogenesis through both central and peripheral actions. *Cell.* 2012;149(4):871–85.
28. Wisniewski F, Leal MF, Calcagno DQ, Santos LC, Gigeck CO, Chen ES, et al. BMP8B is a tumor suppressor gene regulated by Histone Acetylation in gastric cancer. *J Cell Biochem.* 2017;118(4):869–77.
29. Cheng Z, Cui W, Ding Y, Liu T, Liu W, Qin Y, et al. BMP8B mediates the survival of pancreatic cancer cells and regulates the progression of pancreatic cancer. *Oncol Rep.* 2014;32(5):1861–6.
30. Mima K, Fukagawa T, Kurashige J, Takano Y, Uchi R, Ueo H, et al. Gene expression of bone morphogenetic protein 8B in the primary site, peripheral blood and bone marrow of patients with gastric cancer. *Oncol Lett.* 2013;6(2):387–92.
31. Cai YR, Diao XL, Wang SF, Zhang W, Zhang HT, Su Q. X-chromosomal inactivation analysis of uterine leiomyomas reveals a common clonal origin of different tumor nodules in some multiple leiomyomas. *Int J Oncol.* 2007; 31(6):1379–89.
32. Medikare V, Kandukuri LR, Ananthapur V, Deenadayal M, Nallari P. The genetic bases of uterine fibroids; a review. *J Reprod Infertil.* 2011; 12(3):181–91.
33. Haberal A, Kayikcioglu F, Caglar GS, Cavusoglu D. Leiomyomatosis peritonealis disseminata presenting with intravascular extension and coexisting with endometriosis: a case report. *J Reprod Med.* 2007; 52(5):422–4.
34. Mahmoud MS, Desai K, Nezhat FR. Leiomyomas beyond the uterus; benign metastasizing leiomyomatosis with paraaortic metastasizing endometriosis and intravenous leiomyomatosis: a case series and review of the literature. *Arch Gynecol Obstet.* 2015;291(1):223–30.

Submit your next manuscript to BioMed Central and we will help you at every step:

- We accept pre-submission inquiries
- Our selector tool helps you to find the most relevant journal
- We provide round the clock customer support
- Convenient online submission
- Thorough peer review
- Inclusion in PubMed and all major indexing services
- Maximum visibility for your research

Submit your manuscript at  
[www.biomedcentral.com/submit](http://www.biomedcentral.com/submit)

