



Case report

Saccharomyces cerevisiae osteomyelitis in an immunocompetent baker

Piseth Seng^{a,b,c,*}, Alexandre Cerlier^d, Carole Cassagne^{e,f}, Mathieu Coulange^g,
Regis Legré^d, Andreas Stein^{a,b,c}

^a Centre de Référence des Infections Ostéo-Articulaires (CRIOA) Interrégional Sud-Méditerranée, Hôpital de la Conception, 147, boulevard Baille, Marseille, France

^b Service des Maladies Infectieuses, Hôpital de la Conception, 147, boulevard Baille, 13005 Marseille, France

^c Aix-Marseille Université, URMITE, UM 63, CNRS 7278-IRD 198, INSERM 1095, Faculté de Médecine, 27 Bd Jean Moulin, 13385 Marseille, France

^d Service de chirurgie réparatrice, Hôpital de la Timone, Marseille, France

^e Parasitology and Mycology, Assistance Publique-Hôpitaux de Marseille, Hôpital Timone, 13385 Marseilles Cedex 5, France

^f Aix-Marseille University, UMR MD3 IP-TPT, 13885 Marseilles, France

^g Centre de médecine hyperbare, Pôle RUSH, Hôpital Sainte-Marguerite, Marseille, France

ARTICLE INFO

Article history:

Received 14 February 2016

Received in revised form 13 May 2016

Accepted 13 May 2016

Keywords:

Saccharomyces cerevisiae

Osteomyelitis

Bone infection

Baker

Infection

Human

ABSTRACT

Invasive infection caused by *Saccharomyces cerevisiae* is rare. We report the first case of osteomyelitis caused by *S. cerevisiae* (baker's yeast) in a post-traumatic patient. The clinical outcome was favorable after surgical debridement, prolonged antifungal treatment and hyperbaric oxygen therapy.

© 2016 The Authors. Published by Elsevier Ltd. This is an open access article under the CC BY-NC-ND license (<http://creativecommons.org/licenses/by-nc-nd/4.0/>).

Background

Brewer's yeast and baker's yeast were both *Saccharomyces cerevisiae* but different strains [1]. Invasive infection caused by *S. cerevisiae* is rare and usually occurs in patients in an immunocompromised situation, such as patients with solid cancers or hematological malignancies [2,3], or patients who have undergone organ transplantation [2,4,5]. In immunocompetent patients, ingestion of the yeast has been associated with fever [6]. In this paper, we report a case of osteomyelitis caused by *S. cerevisiae* in a young female baker with no apparent immunodeficiency following trauma.

Case presentation

A previously healthy, 39-year-old female baker presented to the emergency department with a distal humerus fracture which was classified as a Cauchoix-Duparc type 3 fracture (Figs. 1 and 2). She

had been working at a bakery and her right upper extremity had been caught in an electrical bakery dough mixer. Surgical debridement, copious lavage and removal of all necrotic tissues were performed. The fracture was temporized and stabilized using an external fixation. Following surgery, she was treated with oral amoxicillin-clavulanic acid 3 g/day. On the fifth day after surgery, she underwent a second surgical debridement and reconstruction of the lost complex humeral tissue using the latissimus dorsi flap. External fixation was maintained to prevent sepsis, but realignment was performed. Bacterial cultures of deep surgical samples were positive for *Pseudomonas aeruginosa* and *Enterobacter cloacae*. She was treated with intravenous imipenem-cilastatin 1000 mg every 12 h and oral ciprofloxacin 500 mg every 8 h.

On the fifteenth day of her hospitalization, and despite antibiotherapy, she developed a purulent discharge from the posterolateral surface of the right arm. Bone samples obtained from surgical biopsies tested negative for bacterial pathogens, but fungal cultures grew for *S. cerevisiae*. Antifungal susceptibility testing, using the E-test assay, of this *S. cerevisiae* isolate showed low MICs for itraconazole (0.12 mg/L), fluconazole (4 mg/L), voriconazole (0.06 mg/L) and, amphotericin B (0.25 mg/L) and relatively higher MIC for posaconazole (0.25 mg/L). She was

* Corresponding author at: Centre de Référence des Infections Ostéo-Articulaires interrégional Sud Méditerranée, Service des Maladies Infectieuses, Hôpital de la Conception, 147, boulevard Baille, Marseille, France. Tel.: +33 04 91 38 41 24; fax: +33 04 91 38 20 41.

E-mail address: sengpiseth@yahoo.fr (P. Seng).

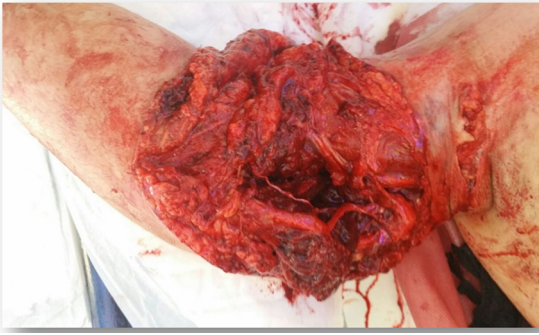

Fig. 1. Traumatic right upper arm wound image.

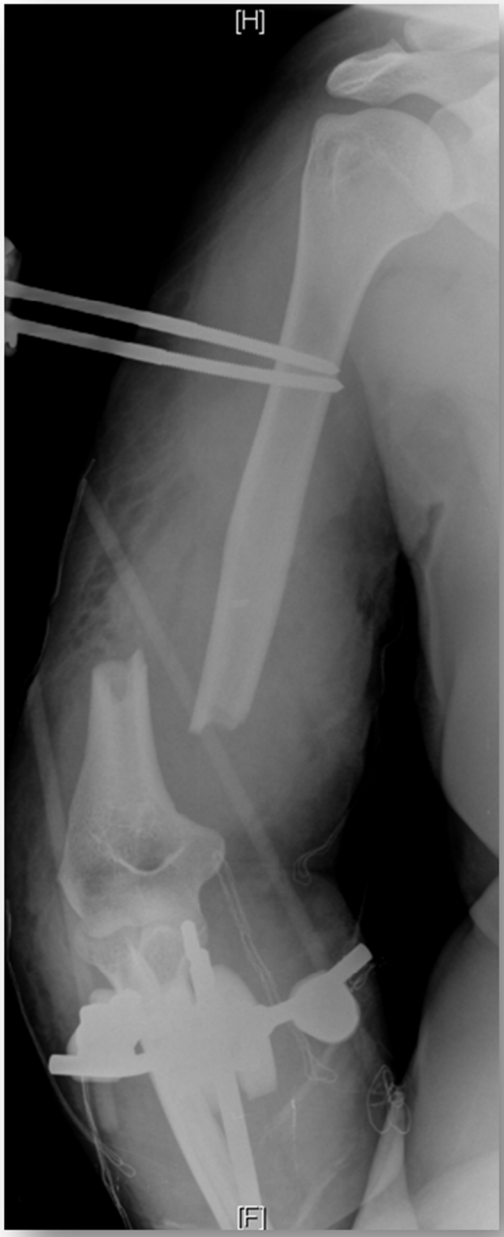


Fig. 2. Bone radiograph of distal humerus fracture presenting a Cauchoix and Duparc type 3 fracture at her admission.

treated with hyperbaric oxygen therapy, voriconazole 250 mg twice daily orally and antibacterial therapy. Imipenem-cilastatin and oral ciprofloxacin were continued. The clinical outcome was favorable with the disappearance of purulent wound drainage

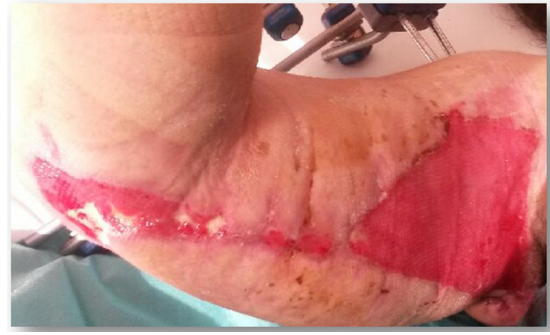

Fig. 3. Traumatic right upper arm wound image on 25 days after admission.

(Fig. 3) and she was discharged 25 days after her admission. Overall, she was treated with three months of antibacterials and nine months of voriconazole. An adjunctive treatment with hyperbaric oxygen therapy was performed. The skin had healed after six weeks. External fixation was removed after six weeks with a humeral nonunion repair by double external fixation (Fig. 4).

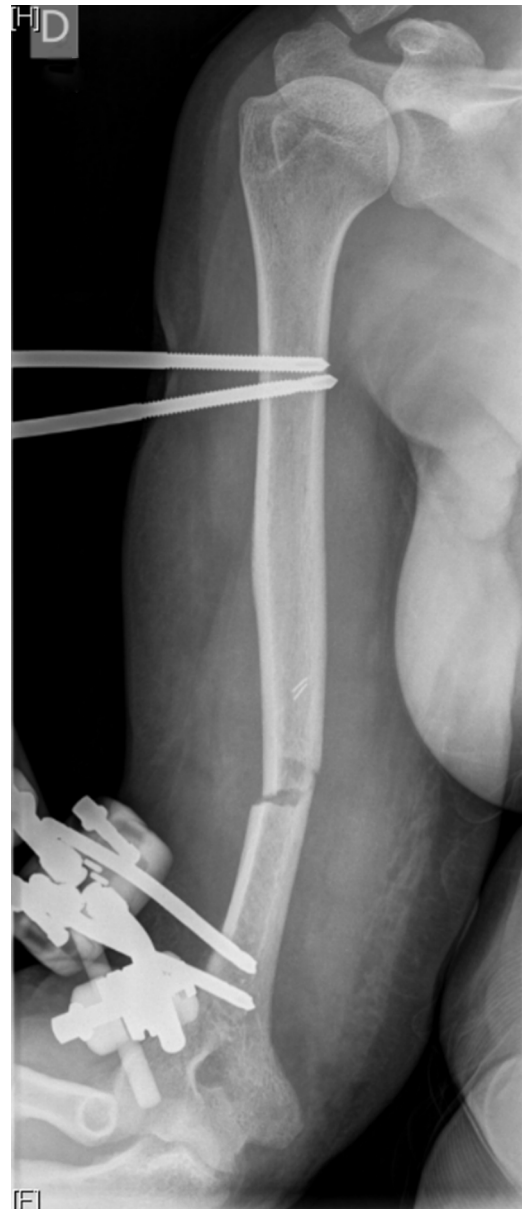

Fig. 4. Bone radiograph of distal humerus on 25 days after admission.

Discussion

Saccharomyces bone and joint infections are extremely rare and have only previously reported in immunocompromised hosts [7,8]. We report the first case of *S. cerevisiae* osteomyelitis in an immunocompetent patient who acquired the infection following traumatic humeral fracture using a bread dough mixer in a bakery.

To the best of our knowledge, only two cases of bone and joint infection caused *S. cerevisiae* have been reported including one case of arthritis in a 73-year-old woman with rheumatoid arthritis and Sjögren's syndrome [7] and one case of mandibular osteomyelitis in a 4-year-old boy who had undergone chemotherapy for an acute lymphoid leukemia [8].

Osteoarticular infection caused by *S. cerevisiae* may be a monomicrobial infection such as in the case of mandibular osteomyelitis [8]. However, this infection may also be polymicrobial, such as in the arthritis case reported [7] or misidentified such as in our case at the beginning of management that was initially diagnosed as osteomyelitis caused by *P. aeruginosa* and *E. cloacae*. *S. cerevisiae* was identified only at the second surgical deep samples culture. Physicians should consider *S. cerevisiae* as potential pathogen of osteomyelitis when infection has occurred in patients who have had wound contact with baker's or brewer's yeast.

Identification of *S. cerevisiae* was first performed by MALDI-TOF MS from the cultivation of a biopsy on Sabouraud medium and was then confirmed by sequencing of the ITS2 region of the rRNA gene as described by Cassagne et al. [9]. The antifungal agent of choice for the treatment of invasive infection by *S. cerevisiae* is unknown. *S. cerevisiae* is consistently susceptible to amphotericin B, to fluconazole and itraconazole. However, in vitro azole resistance have been reported [10]. After surgical debridement, oral antifungal agent with voriconazole was chosen in combination hyperbaric oxygen therapy and antibacterial therapy to treat this patient for early returning to rehabilitation center.

There is no data reported on hyperbaric oxygen for fungi osteomyelitis. Therefore, hyperbaric oxygen therapy was used as an adjunctive treatment of diabetic foot infections and refractory osteomyelitis for over sixty years [11–14]. In our case, hyperbaric oxygen therapy has improved the postoperative care for this complex case of osteomyelitis caused by mixed bacterial and fungi infection.

Conclusion

Osteomyelitis due to *S. cerevisiae* is rare, but may occur in immunocompetent hosts, as our patient demonstrates. The organism should be considered as a potential cause of infection in patients who may have been at risk for inoculation with brewer's or baker's yeast, particularly when they fail to respond to antibacterial therapy and surgical debridement and lavage.

Ethical approval

This study was approved by the institutional research ethics board (*Comite de Protection des Personnes Sud Méditerranée 1*), and written informed consent was obtained from the patient for publication of this case report and any accompanying images. A copy of the written consent is available for review by the Editor-in-Chief of this journal.

Funding

The authors have no relevant affiliations or involvement with any organization or entity with a financial interest or conflict with the

subject matter or materials discussed in the manuscript. No medical writer or editor involved in the generation of this manuscript.

Conflicts of interest

The authors declare no conflicts of interest.

Authors' contributions

PS (MD, Ph.D.): first and corresponding author, involved in clinical data collection, substantial contributions to study conception and drafting the manuscript. AC (M.D.): second author, involved in drafting the manuscript, clinical data verification and revision of the manuscript. CC (Phar.D., Ph.D.): third author, microbiological data collection and revision of the manuscript. MC (M.D., Ph.D.): fourth author, revision of the manuscript. RL (M.D., Ph.D.): fifth author, discussion section and revision of the manuscript. AS (M.D., Ph.D.): last author, clinical data verification, discussion section and final approval of the version to be published. All authors read and approved the final manuscript.

Acknowledgements

The authors thank junior Dr. Stanislas Houdoux and Dr. Estelle Honnorat for their assistance with patient management. The authors obtained permission from Stanislas Houdoux and Estelle Honnorat for this acknowledgement.

References

- [1] Moyad MA. Brewer's/baker's yeast (*Saccharomyces cerevisiae*) and preventive medicine: part I. *Urol Nurs* 2007;27:560–1.
- [2] Aucott JN, Fayen J, Grossnicklas H, Morrissey A, Lederman MM, Salata RA. Invasive infection with *Saccharomyces cerevisiae*: report of three cases and review. *Rev Infect Dis* 1990;12:406–11.
- [3] Williams JS, Mufti GJ, Powell S, Salisbury JR, Higgins EM. *Saccharomyces cerevisiae* emboli in an immunocompromised patient with relapsed acute myeloid leukaemia. *Clin Exp Dermatol* 2007;32:395–7. <http://dx.doi.org/10.1111/j.1365-2230.2007.02375.x>.
- [4] Oliver WJ, James SA, Lennard A, Galloway A, Roberts IN, Boswell TC, et al. Nosocomial transmission of *Saccharomyces cerevisiae* in bone marrow transplant patients. *J Hosp Infect* 2002;52:268–72. <http://dx.doi.org/10.1053/jhin.2002.1314>.
- [5] Popiel KY, Wong P, Lee MJ, Langelier M, Sheppard DC, Vinh DC. Invasive *Saccharomyces cerevisiae* in a liver transplant patient: case report and review of infection in transplant recipients. *Transpl Infect Dis* 2015;17:435–41. <http://dx.doi.org/10.1111/tid.12384>.
- [6] Jensen DP, Smith DL. Fever of unknown origin secondary to brewer's yeast ingestion. *Arch Intern Med* 1976;136:332–3.
- [7] Feld R, Fornasier VL, Bombardier C, Hastings DE. Septic arthritis due to saccharomyces species in a patient with chronic rheumatoid arthritis. *J Rheumatol* 1982;9:637–40.
- [8] Hovi L, Saarinen UM, Donner U, Lindqvist C. Opportunistic osteomyelitis in the jaws of children on immunosuppressive chemotherapy. *J Pediatr Hematol Oncol* 1996;18:90–4.
- [9] Cassagne C, Normand A-C, Bonzon L, L'Ollivier C, Gautier M, Jeddi F, et al. Routine identification and mixed species detection in 6,192 clinical yeast isolates. *Med Mycol* 2015. <http://dx.doi.org/10.1093/mmy/mvv095>.
- [10] Muñoz P, Bouza E, Cuenca-Estrella M, Eiros JM, Pérez MJ, Sánchez-Somolinos M, et al. *Saccharomyces cerevisiae* fungemia: an emerging infectious disease. *Clin Infect Dis Off Publ Infect Dis Soc Am* 2005;40:1625–34. <http://dx.doi.org/10.1086/429916>.
- [11] Leslie CA, Sapico FL, Ginunas VJ, Adkins RH. Randomized controlled trial of topical hyperbaric oxygen for treatment of diabetic foot ulcers. *Diabetes Care* 1988;11:111–5.
- [12] Kaide CG, Khandelwal S. Hyperbaric oxygen: applications in infectious disease. *Emerg Med Clin North Am* 2008;26:571–95. <http://dx.doi.org/10.1016/j.emc.2008.01.005>. xi.
- [13] Tiemann AH, Hofmann GO. Principles of the therapy of bone infections in adult extremities: are there any new developments? *Strateg Trauma Limb Reconstr* 2009;4:57–64. <http://dx.doi.org/10.1007/s11751-009-0059-y>.
- [14] Skeik N, Porten BR, Isaacson E, Seong J, Klosterman DL, Garberich RF, et al. Hyperbaric oxygen treatment outcome for different indications from a single center. *Ann Vasc Surg* 2015;29:206–14. <http://dx.doi.org/10.1016/j.avsg.2014.07.034>.