

Does Retrograde Femoral Nailing through a Normal Physis Impair Growth? An Experimental Porcine Model

Ahmed A Abood¹, Ole Rahbek², Morten L Olesen³, Bjørn B Christensen⁴, Bjarne Møller-Madsen⁵, Søren Kold⁶

ABSTRACT

Aim and objective: The insertion of an intramedullary nail may be beneficial in certain cases of leg length discrepancy (LLD) in children. However, it is unknown if the physal injury due to the surgery may cause bone bridge formation and thereby growth arrest after removal. This study aimed to assess longitudinal interphysal growth 16 weeks after insertion and later removal of a retrograde femoral nail passing through the physis. Moreover, to analyse the tissue forming in the empty physal canal after removal of the nail.

Materials and methods: The study was carried out using an experimental porcine model. Eleven juvenile female porcines were randomized for insertion of a retrograde femoral nail in one limb. The other limb acted as a control. The animals were housed for 8 weeks before the nail was removed and housed for 8 additional weeks, that is, 16 weeks in total. Growth was assessed by interphysal distance on 3D magnetic resonance imaging (MRI) after 16 weeks and the operated limb was compared to the non-operated limb. Histomorphometric analysis of the physal canal was performed.

Results: No difference in longitudinal growth was observed when comparing the operated femur to the non-operated femur using MRI after 16 weeks. No osseous tissue crossing the physis was observed on MRI or histology. The empty canal in the physis after nail removal was filled with fibrous tissue 16 weeks after primary surgery.

Conclusion: Growth was not impaired and no bone bridges were seen on MRI or histology 16 weeks after insertion and later removal of the retrograde femoral nail.

Clinical significance: The insertion of a retrograde intramedullary femoral nail centrally through the physis and later removal might be safe, however, long-term follow-up is needed.

Keywords: Children, Intramedullary nail, Leg length discrepancy.

Strategies in Trauma and Limb Reconstruction (2021): 10.5005/jp-journals-10080-1515

INTRODUCTION

Limb deformities, such as leg length discrepancy (LLD) is a common cause of referral in paediatric orthopedics.¹ In the growing child, bone lengthening might be indicated if the LLD is too large to be treated with epiphysiodesis of the longest leg or when both LLD and an angular bone deformity are corrected conjunctly.²⁻⁴

The gold standard for limb lengthening in the growing child is widely believed to be by the well-established external fixation.⁵⁻⁷ There are, however, complications associated with the use of the external frame. These include pin infections, soft tissue tethering, joint contracture, deep infections, and difficulties in applying the circular frame in anatomical regions as the thigh in addition to the anti-social effect associated with the frame treatment. Furthermore, after frame removal, there is a risk of developing a deformity in an immature regenerate in addition to fracture through the regenerate or a pin site.⁸⁻¹¹ Internal bone lengthening by intramedullary lengthening nails has been introduced to avoid the external frame and the associated complications.^{12,13} However, in the growing child, the physis needs to be injured for the intramedullary nail to be inserted. The iatrogenic physal injury may result in growth arrest due to bone bridge formation.¹⁴⁻¹⁶ Hammouda et al. have investigated the insertion of an antegrade femoral nail through the greater trochanter in children and did not detect complications in this approach.¹⁷ The antegrade femoral nail can mainly achieve lengthening over the anatomical axis without mechanical axis correction. On contrary, it is possible to correct significant mechanical axis deformities of

^{1,2,6}Department of Orthopaedics and Reconstruction, Aalborg University Hospital, Aalborg, Denmark

³⁻⁵Department of Orthopaedics and Reconstruction, Aarhus University Hospital, Aarhus, Denmark

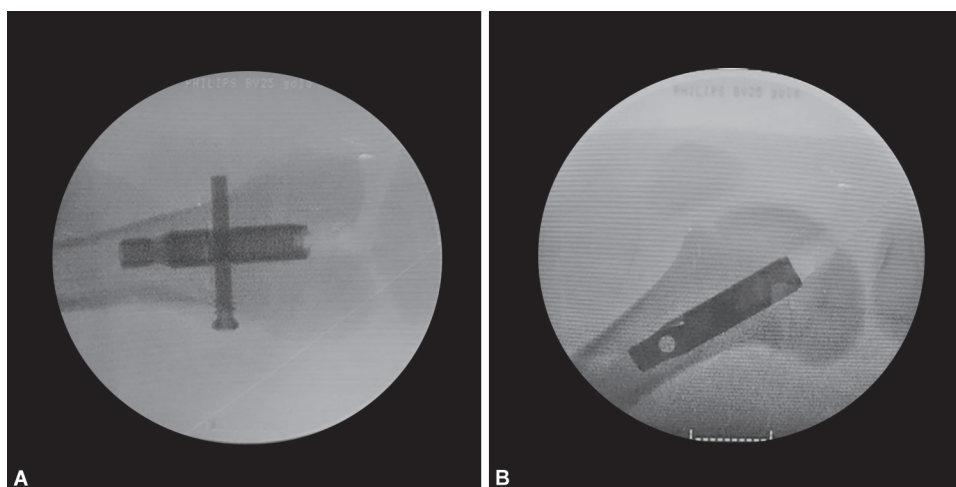
Corresponding Author: Ahmed A Abood, Department of Orthopaedics and Reconstruction, Aalborg University Hospital, Aalborg, Denmark, Phone: +45 23902990, e-mail: a.abood@rn.dk

How to cite this article: Abood AA, Rahbek O, Olesen ML, et al. Does Retrograde Femoral Nailing through a Normal Physis Impair Growth? An Experimental Porcine Model. *Strategies Trauma Limb Reconstr* 2021;16(1):8-13.

Source of support: Nil

Conflict of interest: None

the femur by a distal femoral osteotomy and retrograde insertion of a lengthening nail.^{18,19} In a recent experimental ovine study, it has been shown that overall growth does not seem to get affected when implanting a retrograde nail that injures up to 7% of the cross-sectional physal area.²⁰ In the clinical setting the nail is subsequently removed after achieving desired bone length, leaving an empty canal through the physis. Knapik et al.²⁰ did not examine the physal healing in the empty canal and possible growth disturbance after nail removal. Therefore, further experimental studies regarding physal injury and healing are needed before the potential transfer of this technique into clinical use. This study aimed to assess physal growth and healing



Figs 1A and B: Postoperative fluoroscopic images: (A) Anteroposterior view; (B) Lateral view

including potential growth deformities after inserting a retrograde femoral intramedullary nail, centrally in both planes through a normal physis, and later removal in a skeletally immature experimental porcine model.

The primary outcome was the difference in physeal growth between operated and non-operated limbs after 16 weeks. We hypothesized that insertion and subsequent removal of a retrograde femoral intramedullary nail through the centre of the distal femoral physis would not influence physeal growth compared to the non-operated contralateral femur.

MATERIALS AND METHODS

Eleven 3-month-old skeletally immature female porcines (Yorkshire–Landrace–Duroc) were included. The mean weight was 37 kg (range 34–41). The animals applied in this study are juvenile porcines with physeal closure occurring around the age of 3 years.²¹ A retrograde intramedullary nail was inserted into one femur and each animal was housed for 8 weeks. The nail was then removed and the animal was housed for 8 additional weeks. The total housing period was 16 weeks. One animal died due to an unknown cause of death after 8 weeks. This animal was only subject to an 8-week analysis. Ten animals ($n = 10$) completed the study period and were subject to the full analysis.

All animals underwent magnetic resonance imaging (MRI) scans at baseline, after nail removal, and before euthanasia.

The primary outcome was the mean difference in physeal growth, detected on MRI, between the operated and non-operated femur 16 weeks after primary surgery. Secondary outcomes were, the difference in physeal growth after 8 weeks between the operated and non-operated femur, the physeal healing after 16 weeks, uneven physeal growth in the total physis after 16 weeks, physeal water content, and proportion of damaged physeal area evaluated on MRI,²² and tissue fractions evaluated by histomorphometry.²³

Intramedullary Nail

A custom-made straight intramedullary nail (length: 60 mm, diameter: 10.7 mm) was used. It was made of the same material as the lengthening nail by PRECICE® (medical-grade titanium alloy Ti–6Al–4V). No osteotomies were made. The nail was kept in place

and locked with one single locking screw. The locking screw was inserted proximal to the physis to mimic the clinical insertion of a retrograde femoral nail aiming to preserve the growth potential of the physis (Fig. 1).

Anaesthesia and Surgery

All operations were performed in theatres with a sterile environment and under general anaesthesia. Intubation was performed after infusion of intravenous (IV) Hypnomidate (0.5 mg/kg). Anaesthesia and analgesia were upheld during surgery by continuous Propofol (10 mg/kg/h) and Fentanyl (60 µg/kg/h) IV infusion. Before surgery, an intraarticular 1:1 injection of Lidocaine and Bupivacaine (25 mg + 25 mg) was administered into the knee joint.

The distal femur was exposed using an infrapatellar approach. A k-wire was inserted through the physis centrally in both planes under fluoroscopic guidance. Access to the medullary canal was obtained using a cannulated drill. The medullary canal was reamed in 0.5 mm successive steps from 9 mm to 12 mm. The nail was inserted into the medullary canal until spanning the physis (Fig. 1).

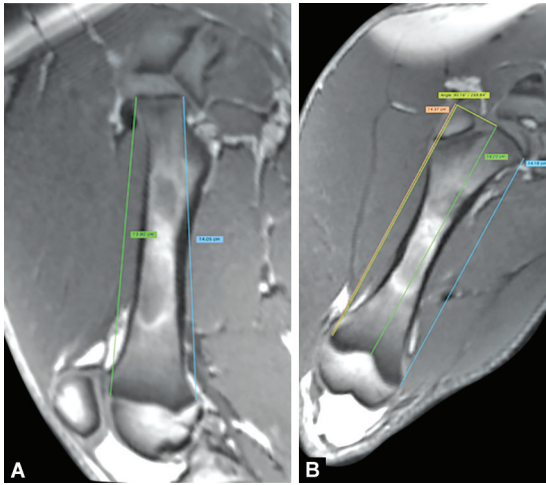
The nail was removed after 8 weeks using the same surgical approach.

All animals were euthanized at 16 weeks by an IV injection of a lethal dose of Pentobarbital (200 mg/mL). A bone sample (1.5 cm × 1.5 cm × 3 cm) of the distal femur including the physis was kept for further analysis.

Magnetic Resonance Imaging

All MRI scans were performed with the animal sedated with Zoletil.²⁴

MRI (Siemens Skyra, 3.0 Tesla) was performed at baseline prior to nail insertion ($n = 11$), and after nail removal at 8 weeks ($n = 11$), and prior to euthanasia at 16 weeks ($n = 10$). MRI at baseline was carried out one day before surgery, whilst MRI after nail removal was done one day after surgery. Thus, no MRI was performed with the nail *in situ*. Standardized protocol scans with three-dimensional T1, T2, and water content T1 map scans were performed of both the operated and non-operated femurs in each animal.²⁵ The interphyseal distance was measured in both limbs, at five different sites both pre- and post-operatively, and prior to euthanasia: medial, central, lateral, anterior, and posterior (Fig. 2). A mean value from the five sites was calculated to represent the total physeal growth. The calculated growth was defined as the difference in interphyseal



Figs 2A and B: Interphyseal distance in the femur (5 sites) is measured on MRI

distance from the baseline to 8 weeks and 16 weeks. Mean growth at all sites in the operated limb was compared to the non-operated limb at both 8 weeks and 16 weeks.

Intra-observer reproducibility was calculated from repeated measurements of growth in all sites on MRI from five animals with at least one month between measurements. The repeated measurements were compared to the primary measurements and the mean coefficient of variation was calculated with belonging 95% confidence interval. A value of 10% or less was considered excellent, while less than 20% is considered acceptable.²⁶ The coefficient of variation showed excellent reproducibility with a mean value of 1.3% (0.9; 1.6).

The presence or absence of bony union at the physis was determined on MRI.

Percentage damaged area of the physis by both the nail and reamer was calculated by dividing the area of the nail crossing the physis (0.899 cm²) and the area of the reamer (1.13 cm²) by the determined physeal cross-sectional area on MRI.

Water content was quantified using computer software (Siswin v.0.9 (Ringgaard S, 2008)).²⁵ To evaluate the water content of the physeal healing site in comparison to the whole physis, a gap ratio was determined. The gap ratio was calculated using MRI before euthanasia at 16 weeks.

$$\text{Gap ratio} = \frac{\text{water content of gap}}{\text{water content of physis}}$$

The MRI scans performed shortly after the removal of the nails were used to assess the penetration point of the nail through the physis. The axes were placed accordingly and the distance was measured from the medial and lateral edge of the empty canal left by the nail to the medial-lateral border of the physis, respectively. This was done in both the coronal and sagittal planes.

Physeal Cross-sectional Area

Three-dimensional MRI was used to assess the physeal cross-sectional area. The axes were aligned accordingly through the physis. Physeal cross-sectional area was estimated in the axial plane. The physis was located in the axial plane and the area was measured using OsiriX[®] (OsiriX, Pixmeo, Switzerland).

To compare the physeal cross-sectional area with a human reference, MRI scans of the knee for 9 children aged 12–15 years were included in this study. None of the children suffered from any growth disturbances. The cross-sectional area of the physis was defined in the same manner as for the animals.

Histology

The tissue samples harvested upon euthanasia were dehydrated in ethanol (up to 96%) and cleared in xylene. Embedding was carried out in paraffin at 63°C. The samples were subject to histomorphometric quantitative evaluation of the morphologic characteristics in the physeal repair tissue according to Foldager et al.²³ Each sample was cut parallel to the coronal plane at 8 levels with 1200 μm between each level. Sections were collected at each level and stained with haematoxylin and eosin.²⁷ A region of interest was defined as a rectangular region between the medial and lateral damaged part of the physis using computer software (Visio, Visiopharm[®]). A 3 by 3-point counting grid was imposed into the region of interest using the software and counting was performed at 20× magnification. All points in the grid and within the region of interest were counted. A total of 33% of the region of interest was counted. Tissue fractions were calculated for the empty canal through the physis. Repeated histomorphometric analysis was performed in 5 animals for 4 weeks after primary analysis. The mean coefficient of variation was acceptable with a mean of 13% (6.1; 19.5).

Design, Statistics, and Ethics

The study was designed as a paired study. One hind limb was selected for intramedullary nail insertion upon randomization. Each animal was in its control as the operated femur was compared to the non-operated femur. All analyses were carried out blinded to avoid bias in data collection between operated and control femurs.

Statistics were calculated using STATA 13 (SataCorp. 2013 Stata Statistical Software: Release 13. College Station, TX: StataCorp Lp.). Data were checked for normal distribution and paired sample t-test was done.

The study including all procedures was evaluated and granted by The Animal Experimentation Council before initiation. All interventions complied with Danish Animal Research Guidelines. The animals were operated and cared for by authorized personal with relevant education.

The study was conducted and reported according to the ARRIVE guideline.²⁸

RESULTS

No postoperative surgical infections or implant failure were observed during the study period. Normal gait with full weight-bearing was observed latest on the second postoperative day. All results are reported as mean values with corresponding 95% confidence intervals. Growth difference is reported as the difference between interphyseal distance of the operated and non-operated femur.

A mean growth difference was measured to 0.61 mm (−3.20; 1.96) with the nail *in situ* for 8 weeks and 1.73 mm (−0.52; 1.79) 16 weeks after primary surgery.

In this study, no abnormal longitudinal growth was detected between the operated and non-operated femur after nail removal at 8 weeks (Table 1) or after a total of 16 weeks (Fig. 3).

No bony unions were observed on MRI after 16 weeks. Water content (Fig. 4) assessment using MRI showed the mean gap ratio

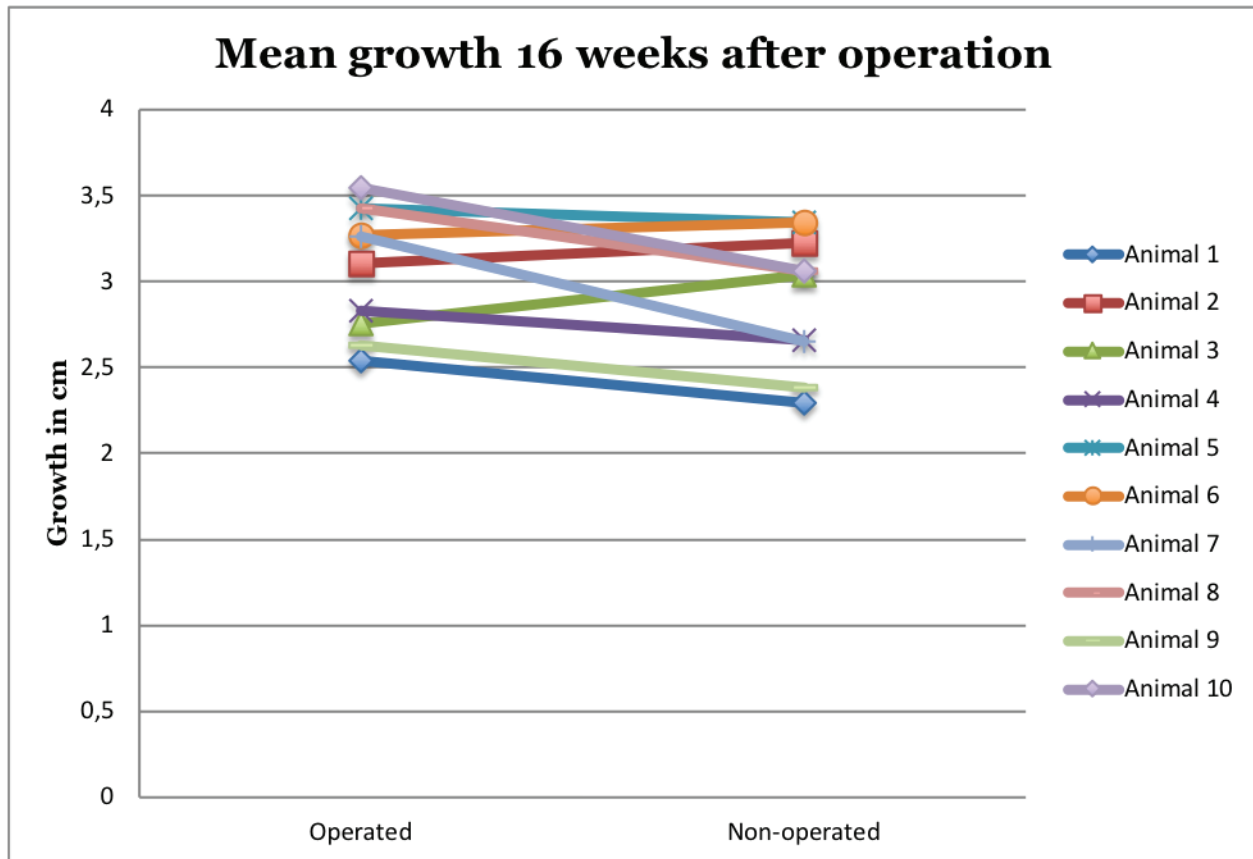


Fig. 3: Interphyseal growth after 16 weeks. The paired distribution between operated and non-operated femurs for each animal shows no clear pattern

Table 1: Growth differences in centimeter between operated and non-operated femurs just after nail removal at 8 weeks ($n = 11$)

	Mean	95% Confidence Interval	p-value
Anterior	0.36	(-3.23; 3.95)	0.84
Posterior	-0.27	(-3.31; 2.77)	0.85
Central	0.13	(-3.20; 3.45)	0.94
Lateral	-1.84	(-5.41; 1.73)	0.29
Medial	-3.04	(-7.47; 1.39)	0.17

of 0.98 (0.90; 1.07). Mean cross-sectional physeal area was 15.8 cm² (15.2; 16.3). The mean percentage of the physis damaged by the nail was 5.7% (5.5; 5.9) and 7.2% (6.9; 7.5) by the reamer. The human referential physeal cross-sectional area was 23.7 cm² (22.4; 24.9). The possible mean physeal damage by the nail, if implanted, in the referential human physis was 3.8% (3.6; 4.0) by the nail and 4.8% (4.5; 5.1) by the reamer.

Histomorphometric analysis showed that the empty canal left in the physis 8 weeks after nail removal was mainly filled with fibrous tissue (Fig. 5 and Table 2). No bone bridges were observed.

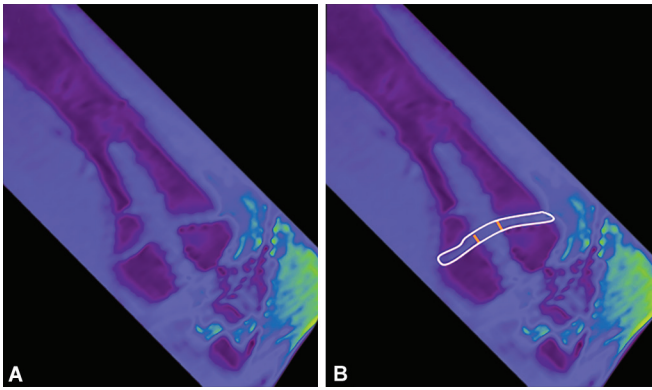
The MRI assessment of the nail penetration point through the physis showed a mean posterior shift by 1.3 mm (0.4; 2.4) and lateral shift by 0.1 mm (-0.6; 0.8) from the centre of the physis.

DISCUSSION

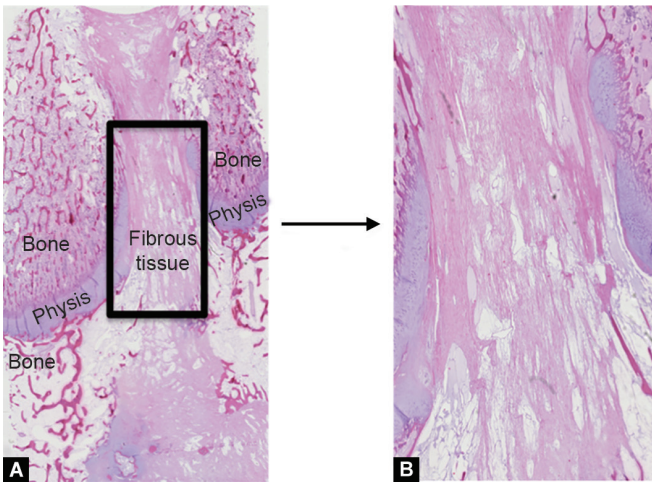
The retrograde insertion and later removal of a femoral intramedullary nail through the physis of the juvenile pig did

not impair longitudinal growth and did not cause any physeal bone bridge nor growth deformities. Post-traumatic growth abnormalities are usually caused by the growth arrest due to the bony union in the physis.²⁹ It has been proven that bony union centrally in the physis will cause limb shortening whilst if located peripherally an angular bone deformity can be expected.^{22,29,30} Using an intramedullary-lengthening nail clinically, the most severe growth disturbance will be an angular bone deformity. Hence, a retrograde femoral intramedullary nail should aim towards passing the physis centrally in both planes. We found a similar water content gap ratio at the physeal injury site compared with the remaining physis, confirming the absence of a bone bridge.²⁵ This is likely the result of the nail crossing the physis in the acute phase after physeal injury leaving no space for bony healing at the physeal injury site. If no nail had been inserted, the bony union might have occurred at the physis. This has been observed in a recent physeal gap porcine model.³¹ However, after nail removal leaving an empty canal through the physis, the bony union was still not observed and growth abnormalities did not occur. This might be a result of the bony healing taking place whilst the nail was still placed in situ at the physis, and thus preventing bony bridging.

The size of traumatic injury to the physis caused by the nail insertion would be expected to cause growth abnormalities if a bony bridge had occurred. In this study, the reamer damaged 7% of the physeal area, and a previous study in rabbits suggested a bone bridge of 7% would result in significant growth disturbance.³²



Figs 4A and B: (A) T1 map water content image of distal femoral physis 8 weeks after removal of nail showing similar water content in the whole physis; (B) The physis is marked white. The injured part of the physis is the area between the two red lines which is used to calculate the water content of the gap



Figs 5A and B: Histology shows fibrous healing in the central part of the physal canal left by the nail. (Light microscopy, A: 1.25x magnification and B: 4x magnification, haematoxylin and eosin stain)

Table 2: Tissue fractions of physal healing after removal of the nail. Values are reported as means with corresponding 95% confidence intervals (*n* = 10)

Cartilage tissue (%)	Bone (%)	Fibrous tissue (%)	Fat tissue (%)	Total
4.77	14.11	68.83	12.29	100
(2.31; 7.22)	(10.58; 17.65)	(63.20; 74.45)	(9.35; 15.22)	

Considering the referential human MRI scans, assessed in this study, the 10.7 mm nail would injure less than 4% of the physis and a 14 mm diameter nail should be inserted to injure 7% of the physis, in our 12–15-years-old human reference population. Despite that the physal damage caused in this study was larger than in the clinical setting, we could not establish any bone growth disturbances.

Our study indicates that insertion of the retrograde femoral nail might be a safe procedure with no growth disturbances to following in agreement with the findings in the ovine animal study by Knapik et al.²⁰ In contrast to, Knapik et al. our study examines the

risk of bone bridge formation and longitudinal growth disturbance after removal of the nail. Our study has limitations and further experimental research is warranted. We may have been unable to detect an induced growth arrest due to inadequate sample size (type II error). Furthermore, it has been shown that bone lengthening in the growing child may affect the growth plate, even though no consensus exists on the matter.^{33–36} We did not lengthen the femur and consequently are not able to examine the possible effect on the physis. It remains uncertain if such lengthening may influence the risk of physal growth injury. The main indication for bone lengthening with a retrograde inserted intramedullary nail is the need for simultaneous mechanical axis correction in addition to the desired lengthening. These corrections require a distal femoral osteotomy and often a de-central penetration of the physis for large corrections. The current study examined the impact of an intramedullary nail passing through a normal physis centrally, assessed by MRI, and confirming the central passing of the nail through the physis. The nail was locked proximally to the physis to allow continuous growth and mimic the nail placement in a lengthening setting to assess physal healing. Finally, it is not known how a central chondral lesion and subsequent fibrous healing through the femoral notch might influence long-term knee function.

CONCLUSION

This is an experimental animal study in healthy juvenile porcines. Central and perpendicular injury to the normal physis with a retrograde femoral nail followed by removal did not cause any longitudinal growth deformities when compared to the unoperated contralateral femur. The empty canal after nail removal was filled with fibrous tissue. No bone bridge formation was detected.

CLINICAL SIGNIFICANCE

This preliminary experimental study proved that the physis could be injured with a centrally placed nail without subsequent bone bridge formation or growth disturbance in a juvenile porcine model. Central physal injury seems to be a safe procedure. However, further research is needed, especially to evaluate long-term follow-up in addition to the effect of an osteotomy and lengthening on the physis in a translational animal model before introducing this approach in children.

REFERENCES

1. Friend L, Widmann RF. Advances in management of limb length discrepancy and lower limb deformity. *Curr Opin Pediatr* 2008;20(1):46–51. Available from: <https://insights.ovid.com/crossref?an=00008480-200802000-00008>. DOI: 10.1097/MOP.0b013e3282f35eeb.
2. Li W, Xu R, Huang J, et al. Treatment of rabbit growth plate injuries with oriented ECM scaffold and autologous BMSCs. *Sci Rep* 2017;7:44140. Available from: <http://www.ncbi.nlm.nih.gov/pubmed/28266598>. DOI: 10.1038/srep44140.
3. Liu XC, Fabry G, Molenaers G, et al. Kinematic and kinetic asymmetry in patients with leg-length discrepancy. *J Pediatr Orthop* 1998;18(2):187–189. Available from: <http://www.ncbi.nlm.nih.gov/pubmed/9531400>.
4. Wagner H. Operative lengthening of the femur. *Clin Orthop Relat Res* 1978;(136):125–142. Available from: <http://www.ncbi.nlm.nih.gov/pubmed/729276>.

5. Ilizarov GA. The tension-stress effect on the genesis and growth of tissues. Part I. The influence of stability of fixation and soft-tissue preservation. *Clin Orthop Relat Res* 1989;(238):249–281. Available from: <http://www.ncbi.nlm.nih.gov/pubmed/2910611>.
6. Ilizarov GA. The tension-stress effect on the genesis and growth of tissues: Part II. The influence of the rate and frequency of distraction. *Clin Orthop Relat Res* 1989;(239):263–285. Available from: <http://www.ncbi.nlm.nih.gov/pubmed/2912628>.
7. Ilizarov GA. Clinical application of the tension-stress effect for limb lengthening. *Clin Orthop Relat Res* 1990;(250):8–26. Available from: <http://www.ncbi.nlm.nih.gov/pubmed/2403497>.
8. Burke NG, Cassar-Gheiti AJ, Tan J, et al. Regenerate bone fracture rate following femoral lengthening in paediatric patients. *J Child Orthop* 2017;11(3):210–215. Available from: <http://www.ncbi.nlm.nih.gov/pubmed/28828065>. DOI: 10.1302/1863-2548.11.160216.
9. Saran N, Hamdy RC. DEXA as a predictor of fixator removal in distraction osteogenesis. *Clin Orthop Relat Res* 2008;466(12):2955–2961. Available from: <http://www.ncbi.nlm.nih.gov/pubmed/18820988>. DOI: 10.1007/s11999-008-0514-y.
10. Danziger MB, Kumar A, DeWeese J. Fractures after femoral lengthening using the Ilizarov method. *J Pediatr Orthop*;15(2): 220–223. Available from: <http://www.ncbi.nlm.nih.gov/pubmed/7745098>.
11. Calder PR, Laubscher M, Goodier WD. The role of the intramedullary implant in limb lengthening. *Injury* 2017;48 Suppl 1:552–558. Available from: <https://linkinghub.elsevier.com/retrieve/pii/S0020138317302565>. DOI: 10.1016/j.injury.2017.04.028.
12. Paley D. PRECICE intramedullary limb lengthening system. *Expert Rev Med Devices* 2015;12(3):231–249. Available from: <http://www.ncbi.nlm.nih.gov/pubmed/25692375>. DOI: 10.1586/17434440.2015.1005604.
13. Singh S, Lahiri A, Iqbal M. The results of limb lengthening by callus distraction using an extending intramedullary nail (Fitbone) in non-traumatic disorders. *J Bone Joint Surg Br* 2006;88(7):938–942. Available from: <http://online.boneandjoint.org.uk/doi/10.1302/0301-620X.88B7.17618>. DOI: 10.1302/0301-620X.88B7.17618.
14. Chung R, Foster BK, Xian CJ. Preclinical studies on mesenchymal stem cell-based therapy for growth plate cartilage injury repair. *Stem Cells Int* 2011;2011:570125. Available from: <http://www.pubmedcentral.nih.gov/articlerender.fcgi?artid=3144692&tool=pmcentrez&rendertype=abstract>. DOI: 10.4061/2011/570125.
15. Kawamoto K, Kim W-C, Tsuchida Y, et al. Incidence of physeal injuries in Japanese children. *J Pediatr Orthop B* 2006;15(2):126–130. Available from: <https://insights.ovid.com/crossref?an=01202412-200603000-00010>. DOI: 10.1097/01.bpb.0000191874.69258.0b.
16. Mann DC, Rajmaira S. Distribution of physeal and nonphyseal fractures in 2,650 long-bone fractures in children aged 0–16 years. *J Pediatr Orthop* 1990;10(6):713–716. Available from: <http://www.ncbi.nlm.nih.gov/pubmed/2250054>. DOI: 10.1097/01241398-199011000-00002.
17. Hammouda AI, Jauregui JJ, Gesheff MG, et al. Trochanteric entry for femoral lengthening nails in children: is it safe? *J Pediatr Orthop* 2017;37(4):258–264. Available from: <http://insights.ovid.com/crossref?an=01241398-201706000-00014>. DOI: 10.1097/BPO.0000000000000636.
18. Rozbruch SR. Adult posttraumatic reconstruction using a magnetic internal lengthening nail. *J Orthop Trauma* 2017;31(6 Suppl):S14–S19. Available from: <http://www.ncbi.nlm.nih.gov/pubmed/28486285>. DOI: 10.1097/BOT.0000000000000843.
19. Baumgart R. The reverse planning method for lengthening of the lower limb using a straight intramedullary nail with or without deformity correction. A new method. *Oper Orthop Traumatol* 2009;21(2):221–233. Available from: <http://www.ncbi.nlm.nih.gov/pubmed/19685230>. DOI: 10.1007/s00064-009-1709-4.
20. Knapik DM, Zirkle LG, Liu RW. Consequences following distal femoral growth plate violation in an ovine model with an intramedullary implant: a pilot study. *J Pediatr Orthop* 2018;38(10):e640–e645. Available from: <http://www.ncbi.nlm.nih.gov/pubmed/30074588>. DOI: 10.1097/BPO.0000000000001234.
21. Swindle MM, Makin A, Herron AJ, et al. Swine as models in biomedical research and toxicology testing. *Vet Pathol* 2012;49(2):344–356. Available from: <http://vet.sagepub.com>. DOI: 10.1177/0300985811402846.
22. Jawetz ST, Shah PH, Potter HG. Imaging of physeal injury: overuse. *Sports Health* 2015;7(2):142–153. Available from: <http://www.ncbi.nlm.nih.gov/pubmed/25984260>. DOI: 10.1177/1941738114559380.
23. Foldager CB, Nyengaard JR, Lind M, et al. A stereological method for the quantitative evaluation of cartilage repair tissue. *Cartilage* 2015;6(2):123–132. Available from: <http://www.ncbi.nlm.nih.gov/pubmed/26069715>. DOI: 10.1177/1947603514560655.
24. Janovsky M, Tataruch F, Ambuehl M, et al. A Zoletil®-Rompun® mixture as an alternative to the use of opioids for immobilization of feral red deer. *J Wild Dis* 2000;36(4):663–669. Available from: <http://www.ncbi.nlm.nih.gov/pubmed/11085427>. DOI: 10.7589/0090-3558-36.4.663.
25. Shigetomi-Medina JM, Ramirez-GI JL, Stødkilde-Jørgensen H, et al. Systematized water content calculation in cartilage using T1-mapping MR estimations: design and validation of a mathematical model. *J Orthop Traumatol* 2017;18(3):217–220. Available from: <http://www.ncbi.nlm.nih.gov/pubmed/27771808>. DOI: 10.1007/s10195-016-0433-8.
26. Gottlieb M. Guided growth of long bones using the tension band plating technique. Aarhus University Hospital; 2012.
27. Christensen BB, Foldager CB, Hansen OM, et al. A novel nano-structured porous polycaprolactone scaffold improves hyaline cartilage repair in a rabbit model compared to a collagen type I/III scaffold: in vitro and in vivo studies. *Knee Surg Sports Traumatol Arthrosc* 2012;20(6):1192–2204. Available from: <http://www.ncbi.nlm.nih.gov/pubmed/21971941>. DOI: 10.1007/s00167-011-1692-9.
28. Kilkeny C, Browne WJ, Cuthill IC, et al. Improving bioscience research reporting: the arrive guidelines for reporting animal research. *PLoS Biol* 2010;8(6):e1000412. Available from: <http://www.ncbi.nlm.nih.gov/pubmed/20613859>. DOI: 10.1371/journal.pbio.1000412.
29. Ecklund K, Jaramillo D. Patterns of premature physeal arrest: MR imaging of 111 children. *AJR Am J Roentgenol* 2002;178(4): 967–972. Available from: <http://www.ajronline.org/doi/10.2214/ajr.178.4.1780967>. DOI: 10.2214/ajr.178.4.1780967.
30. Wang DC, Deeney V, Roach JW, et al. Imaging of physeal bars in children. *Pediatr Radiol* 2015;45(9):1403–1412. Available from: <http://link.springer.com/10.1007/s00247-015-3280-5>.
31. Abood AAH, Møller-Madsen B, Shigetomi-Medina JM, et al. Autologous cartilage and fibrin sealant may be superior to conventional fat grafting in preventing physeal bone bridge formation—a pilot study in porcines. *J Child Orthop* 2020;14(5): 459–465. DOI: 10.1302/1863-2548.14.200024.
32. Mäkelä EA, Vainionpää S, Vihtonen K, et al. The effect of trauma to the lower femoral epiphyseal plate. An experimental study in rabbits. *J Bone Joint Surg Br* 1988;70(2):187–191. Available from: <http://www.ncbi.nlm.nih.gov/pubmed/3346285>. DOI: 10.1302/0301-620X.70B2.3346285.
33. Sharma M, MacKenzie WG, Bowen JR. Severe tibial growth retardation in total fibular hemimelia after limb lengthening. *J Pediatr Orthop* 1996;16(4):438–444. Available from: <http://www.ncbi.nlm.nih.gov/pubmed/8784694>.
34. Sabharwal S, Paley D, Bhave A, et al. Growth patterns after lengthening of congenitally short lower limbs in young children. *J Pediatr Orthop* 2000;20(2):137–145. Available from: <http://www.ncbi.nlm.nih.gov/pubmed/10739271>.
35. Lee SH, Szöke G, Simpson H. Response of the physis to leg lengthening. *J Pediatr Orthop B* 2001;10(4):339–343. Available from: <http://www.ncbi.nlm.nih.gov/pubmed/11727380>.
36. Shapiro F. Longitudinal growth of the femur and tibia after diaphyseal lengthening. *J Bone Joint Surg Am* 1987;69(5):684–690. Available from: <http://www.ncbi.nlm.nih.gov/pubmed/3597468>