

Outcome and genetic analysis of patients affected by retinal capillary hemangioblastoma in von Hippel Lindau syndrome

Vittoria Murro,¹ Myrta Lippera,¹ Dario Pasquale Mucciolo,^{1,2} Letizia Canu,³ Tonino Ercolino,⁴ Giuseppina De Filpo,³ Dario Giorgio,¹ Giovanna Traficante,⁵ Andrea Sodi,¹ Gianni Virgili,^{1,6} Fabrizio Giansanti¹

¹Department of Neuroscience, Psychology, Drug Research and Child Health, University of Florence, Florence, Italy;

²Ophthalmology Unit, San Jacopo Hospital, Pistoia, Italy; ³Department of experimental and clinical Biomedical Sciences, University of Florence, Florence, Italy; ⁴Endocrinology Unit, Careggi University Hospital, Florence, Italy; ⁵Medical Genetics Unit, Meyer Children's University Hospital, Florence, Italy; ⁶Fondazione GB Bietti, Roma, Italy

Purpose: To describe genetic analysis, treatment results, and complications of patients affected by retinal capillary hemangioblastoma (RCH) in von Hippel Lindau (VHL) syndrome.

Methods: We collected 17 patients with VHL syndrome, who underwent a molecular test and an ophthalmic evaluation at the Eye Clinic of the University Hospital of Florence from January 2005 to February 2020. We focused on eyes showing RCHs examined using color fundus photographs, fluorescein angiography, and optical coherence tomography.

Results: Eight eyes of six patients (6/17; 35%) showed RCHs at the fundoscopic examination. All RCHs were treated with laser therapy. Three eyes underwent episcleral surgery, one eye showing vitreous hemorrhage received three intravitreal (IV) anti-VEGF injections and three cryotherapy procedures, and one eye underwent vitrectomy. In patients with RCHs, five were characterized by a truncating mutation of the VHL protein, and one patient showed a missense mutation. We have reported two VHL mutations not reported in literature.

Conclusions: Patients with multiple RCHs, who developed RCH secondary effects, showed truncating mutations of the VHL protein. We recommend early screening and close monitoring, especially if RCHs are detected at presentation, for every patient with VHL syndrome independently of the results of the molecular test for a missense or a truncating mutation in *VHL*.

Von Hippel Lindau (VHL) disease (OMIM 193300) is a hereditary cancer predisposition syndrome. The pattern of inheritance is autosomal dominant, characterized by high penetrance [1]. In most cases, the patient inherits a germline mutation from one parent, and a second “hit” can be detected in the tumor tissue [2,3]. Nonetheless, 20% of VHL diseases are reported as sporadic, due to a de novo mutation [4]. The mutation occurs in the *VHL* gene (OMIM 608537), located on chromosome 3p25–26, which encodes for a tumor suppression protein [5]. The mutations of the *VHL* gene, as well as the disease phenotypes, are highly varied, and the syndrome predisposes to the development of multiple organ malignant and benign tumors [2]. The most frequent are retinal or central nervous system (CNS) hemangioblastomas, renal clear cell carcinoma, and pheochromocytoma [6].

The VHL syndrome incidence rate is 1:36,000 live births [6]. In particular, a retinal capillary hemangioblastoma

(RCH) prevalence is described in approximately half of patients with VHL syndrome [7,8]. RCHs represent one of the earliest manifestations of the syndrome, with a mean age onset of 26 years [1,9]. They are detected during fundus oculi examination as orange-red vascular hamartomas, fed by tortuous and dilated feeder and drainage vessels. RCHs are described as multiple in one-third of cases and bilateral in half of affected patients [10]. The peripheral retina is more frequently affected, with only 11%–15% of RCHs arising juxtapapillary [10]. RCHs might remain quiescent or grow progressively, leading to visual impairment and exudative or tractional secondary effects [11]. Fluorescein angiography (FA) adds information by highlighting the tumors and their associated abnormal vascular supply [12]. Whenever possible, treatment consists of laser photocoagulation of the lesion [13]. However, in literature alternative treatment techniques are described, such as cryotherapy, photodynamic therapy (PDT), thermotherapy, intravitreal injections of anti-VEGF, and vitreoretinal surgery [8]. The aim of this study is to describe genetic analysis, treatment results, and complications of patients affected by RCH in VHL syndrome.

Correspondence to: Dario Pasquale Mucciolo, Department of Neuroscience, Psychology, Drug Research and Child Health, University of Florence, Careggi Teaching Hospital, Florence Regional Reference Center for Retinal Degenerations, ERN-EYE MEMBER, Largo Brambilla, 3 - 50134 Florence; Phone:+39 0557946975; Ophthalmology Unit, San Jacopo Hospital, Pistoia, Italy; via Ciliegiole 97, 51100; email: dario.mucciolo@gmail.com

METHODS

We retrospectively studied 17 patients affected by VHL syndrome (9 patients were females; 52,9%) who had been examined (with a molecular test and an ophthalmic evaluation) at the Careggi Teaching Hospital from January 2005 to February 2020; more specifically, we considered patients affected with RCHs (6 patients, 6/17; mean age 39±14 years). This study was approved by the local research Ethics Committee (Careggi Teaching Hospital Ethics Committee) in accordance with the principles of the Declaration of Helsinki. Informed written consent was obtained from all individual participants included in the study.

Sanger sequencing and MLPA for mutation screening: Whole blood is taken from the patient's venous circulation and stored at 4 °C. Subsequently 200 µl of whole blood are used for genomic DNA extraction using the QIASymphony CDN Kit, QIASymphony SP (Qiagen, Hilden, Germany), which allows to obtain the eluted DNA ready for use. In short, the extraction procedure is divided into various steps starting with a lysis, where lysate and magnetic particles are transferred in the sample preparation cartridge, subsequently DNA binds to magnetic particles, and then two separation steps follow magnetic interspersed with a wash to arrive at the release of the eluate. The DNA quality and quantity were measured with a Qubit ds assay on Qubit 2.0 Fluorometer (Thermo Fisher Scientific, Monza, Italy). When we searched for germline mutations of the *VHL* gene, the coding regions and exon-intron boundaries were amplified by PCR: 100 ng of DNA was PCR-amplified using the forward and reverse primers located at exon-intron boundaries, performed in standard reaction conditions with an initial denaturation at 95 °C for 5 min followed by 30 cycles each composed of 1 min at 95 °C, 30 s at 58 °C, 30 s at 72 °C, and a final extension of 7 min at 72 °C. Total PCR products were then purified using a PCR purification kit (Qiagen, Milan, Italy). To perform the cycle-sequencing reaction, 5 ng of DNA were then blended with each primer (0.8 µM) in a terminator ready reaction mix containing big dye terminators (Applied Biosystems, Thermo Fisher Scientific) and submitted to 1 minute at 96 °C and 25 cycles at 96 °C for 10 s, 50 °C for 5 s, 60 °C for 4 min. A second purification step was necessary for the big dye removal with DyeEx 2.0 Spin Kit (Qiagen). Five µl of marked and purified DNA were submitted to sequencing analysis with ABI PRISM 310 Genetic Analyser (Applied Biosystems). Subsequently we searched eventual genomic rearrangements using the MLPA test (multiplex ligation-dependent probe amplification/MRC Holland, SALSA Kit P016-C2 VHL version C2) approach. For analysis of MLPA data we used Coffalyser.Net software (MRC, Holland, Netherlands).

Analysis of variant by querying different databases i.e. Clinvar-NCBI-NIH and Intervar (Clinical Interpretation of genetic variants by ACMG/AMP 2015 guideline) allowed us to classify the variant [14].

Treatment and ophthalmic assessment of RCHs: The standard follow-up ophthalmologic examination included measurement of best corrected visual acuity (BCVA), tonometry, and funduscopic evaluation. In addition, all patients underwent, before or after the treatment or both, fundus photography (Zeiss Retinograph Carl Zeiss, Dublin, CA), ultrawide field scanning laser ophthalmoscopy (UWF-SLO; Daytona, Optos, Dunfermline, UK), optical coherence tomography (OCT) scanning (Topcon 3D OCT-1000, Topcon Medical Systems Inc., Oakland, NJ, and Heidelberg Spectralis SD-OCT, Heidelberg Engineering, Dossenheim, Germany), and FA (Heidelberg Retina Angiograph 2 Heidelberg Engineering; Zeiss Retinograph Carl Zeiss). Argon green laser was performed using a QuadrAspheric Indirect Contact Laser Lens (Volk, Mentor, OH) in one or more sessions. The photocoagulation was targeted on the retina adjacent to the tumor, and then the laser was directed on the top of the hemangioblastoma, as suggested by Schmidt et al., to reduce the risk of retinal detachment [13]. Feeder vessels were not treated directly using laser to avoid vitreous hemorrhage. Additional individualized therapies were collected and have been described.

RESULTS

We included 17 patients carrying mutations in *VHL* from ten families. Specifically, six patients (6/17; 35.3%), from six different families (Figure 1), were characterized with RCHs at the funduscopic examination. The clinical findings of the patients with VHL syndrome are reported in Table 1.

Genetic analysis: The results of the genetic analysis revealed four missense mutations, four nonsense mutations, one frameshift mutation, and one genomic deletion. Genetic results are summarized in Table 2. Nonsense mutations were reported in three out of six patients (3/6; 50%) affected by RCHs: In detail, the premature translational stop signal was at the codon 161 (c.481C> T; p.Arg161Ter) in patient P5, and patients P8 and P9 were characterized by the same mutation in *VHL* (c.337C> T; p.Arg113Ter) although the patients were not in the same family (family 4 and family 5, respectively). Patient P10 reported a genomic deletion (c.341+1_341-1(463*1_?)) and patient P2 a missense mutation (novel mutation, not reported in literature), causing a replacement of a proline with a leucine at nucleotide 192 (c.575C> T; p.Pro192Leu). Finally, a novel frameshift mutation was reported in patient P1, due to a deletion of a cytosine in position 154 (c.461delC;

p.Pro154Glnfs4*) which causes sliding of the reading frame. We examined both parents of five out of six patients affected by RCHs and identified three de novo mutations in patients P1, P8, and P10.

Management and follow-up of RCHs: Eight eyes, of six patients with VHL syndrome (6/17; 35%), showed RCHs at the first fundoscopic examination. Mean age at diagnosis of the ocular disease was 30 years (range 14–42 years). Mean BCVA at the first ophthalmic visit was 20/32 (range 20/640 to 20/20). All observed RCHs were peripheral and did not involve the posterior pole. At presentation, only two eyes of two different patients (2/6; 33%; patients P1 and P2) showed a single RCH; the remaining six eyes of four patients (4/6; 66.7%; patients P5, P8, P9, and P10) showed multiple tumors with bilateral involvement in two patients (patients P5 and P8). At diagnosis, secondary tractional or exudative effects or both of RCHs had caused retinal detachment in two eyes (patient P5 and P10) and severe retinal exudation in one eye

(patient P8). All patients underwent laser photocoagulation of the RCHs. Additional treatment techniques were necessary in four eyes: cryotherapy (patients P8, P5, P10, and P9) and intravitreal (IV) injections of anti-VEGF (three IV injections were performed in the left eye of patient P8). A scleral buckle was performed in three eyes (patients P9, P5, and P10). Follow-up lasted an average of 99 months (range 6–168 months). During follow-up, patient P2 underwent barrage laser and pars plana vitrectomy for the development of a retinal tear and a full-thickness macular hole (FTMH), respectively; patient P8 developed a vitreous hemorrhage, and patients P5 and P9 a chronic retinal detachment with neovascular glaucoma (NVG). All these events happened in the affected eyes. At the end of the follow-up period, the mean BCVA was 20/32 (range no light perception (nlp) to 20/20)). Regarding the 11 patients with VHL syndrome who did not show RCHs at the first fundoscopic examination, we did not observe any further retinal findings during the follow-up period (mean follow-up of 74 months; range 6–1480).

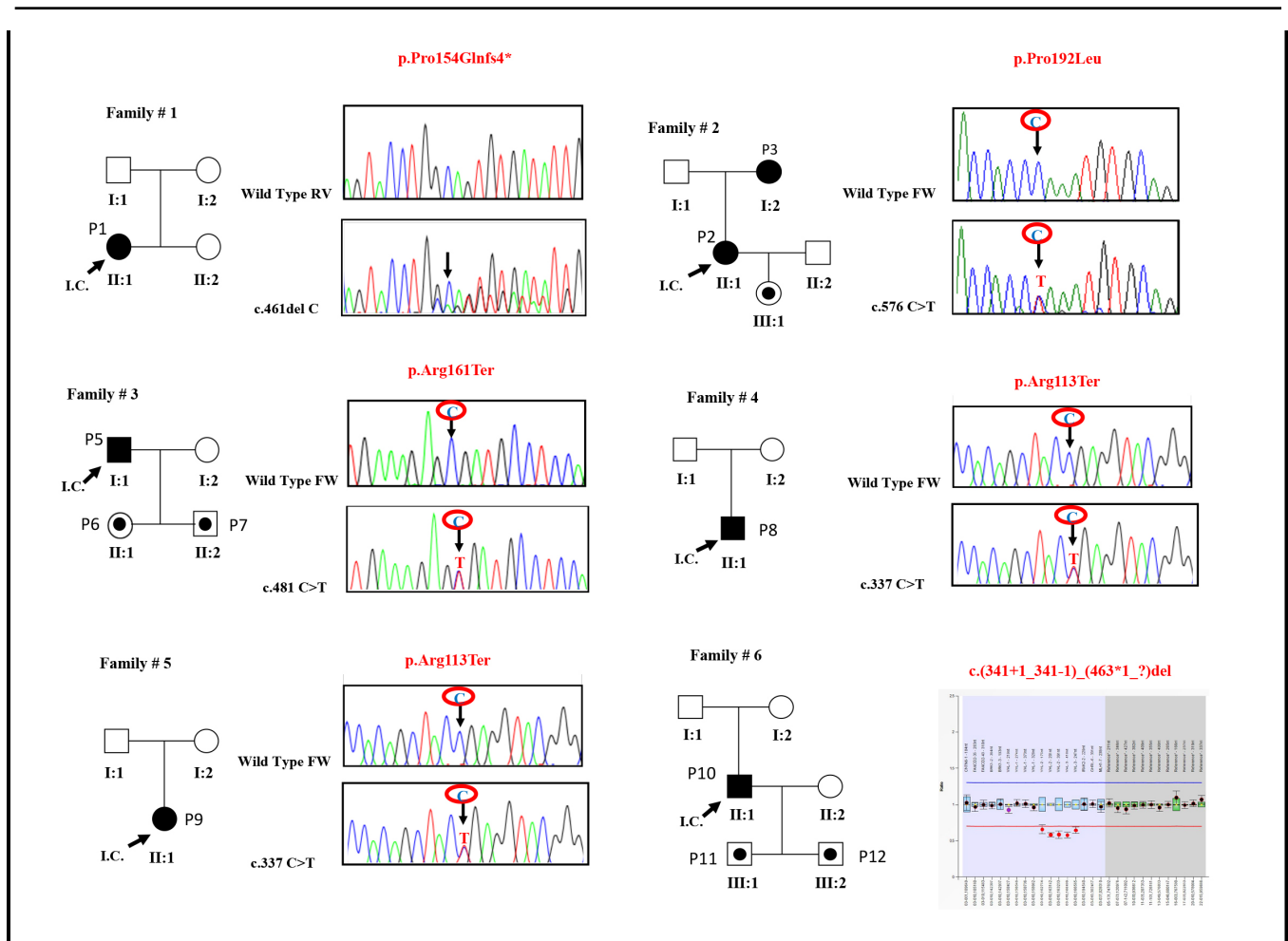


Figure 1. Pedigrees of the six patients with VHL syndrome characterized by RCHs.

TABLE 1. CLINICAL FINDINGS OF VHL PATIENTS.

ID patient	ID family	Sex	Follow-up (months)	Age at diagnosis	CNS hemangioblastomas	Other tumors	Eye	BCVA at presentation	Number of RCHs	Tractional retinal detachment	Exudative maculopathy	BCVA (last examination)	Treatment technique	surgery	Complications
P1	F1	F	53	24 y	n	n	OD	20/20	0	n	n	20/20	n	n	n
P2	F2	F	128	42	n	n	OS	20/20	1	n	n	20/20	laser	n	n
							OD	20/20	0	n	n	20/20	n	n	n
							OS	20/25	1	n	n	20/25	laser	Vitreotomy (for FTMH)	retinal tear, FTMH
P3	F2	F	126	61	n	y	OU	20/25	0	n	n	20/25	n	n	n
P4	F2	F	126	6	n	n	OU	20/20	0	n	n	20/20	n	n	n
P5	F3	M	109	32 y	y	y	OD	20/25	3	y	n	20/20	cryo+laser	episcleral buckle	n
P6	F3	F	6	10	n	n	OS	20/20	2	n	n	20/20	laser	n	n
P7	F3	M	6	7	n	n	OU	20/20	0	n	n	20/20	n	n	n
P8	F4	M	6	14 y	y	n	OD	20/20	4	n	n	20/20	laser	n	n
P9	F5	F	168	32 y	y	y	OS	20/640	>10	n	y	20/640	cryo+laser +IVT	n	vitreous hemorrhage
							OD	20/20	0	n	n	20/25	n	n	n
							OS	20/25	>5	y	y	nlp	cryo+laser	episcleral buckle	chronic retinal detachment, NVG
P10	F6	M	130	37 y	y	y	OD	20/400	>10	y	n	nlp	cryo+laser	episcleral buckle	chronic retinal detachment, NVG
P11	F6	M	24	12	n	n	OS	20/20	0	n	n	20/20	n	n	n
P12	F6	M	24	10 y	y	n	OU	20/20	0	n	n	20/20	n	n	n
P13	F7	F	108	17	n	y	OU	20/20	0	n	n	20/20	n	n	n
P14	F8	M	24	33	n	y	OU	20/20	0	n	n	20/20	n	n	n
P15	F9	F	108	50 y	y	y	OU	20/25	0	n	n	20/25	n	n	n
P16	F9	M	84	20	n	y	OU	20/20	0	n	n	20/20	n	n	n

ID	ID family	Sex	Follow-up (months)	Age at diagnosis	CNS hemangioblastomas	Other tumors	Eye	BCVA at presentation	Number of RCHs	Tractional retinal detachment	Exudative maculopathy	BCVA (last examination)	Treatment technique	Complications
P17	F10	F	180	28	n	y	OU	20/25	0	n	n	20/25	n	n

Descriptions of RCH clinical cases:

Patient P1—A 24-year-old woman underwent her first retinal examination due to the detection of a cerebellar hemangioblastoma. BCVA was 20/20 in both eyes (OU); at the fundus examination, the right eye (OD) showed no alterations, while a single peripheral RCH (inferior nasal) was present in the left eye (OS; Figure 2). Laser was performed on the retina surrounding the lesion in one session. During the follow-up (the last performed in September 2019), the tumor in OS was stable in size without exudation, and we did not detect the development of RCHs in OD.

Patient P2—A 42-year-old woman was referred to the Eye Clinic due to a lesion in OS. OD was normal. BCVA was 20/25, and a peripheral RCH with a macular pseudohole was observed at the fundoscopic examination (Figure 3). The tumor was treated using laser photocoagulation and required several treatment sessions. One week after the first laser session, the pseudohole progressed to a lamellar macular hole (LMH) and after some months, to a FTMH. BCVA worsened to 20/63 in 2012, and pars plana vitrectomy was successfully performed: The macular epiretinal membrane and internal limiting membrane were peeled. During follow-up, a retinal tear was detected (in 2014), and it was treated using a barrage laser. The last follow-up visit (in September 2019) revealed a good macular profile and RCH regression; BCVA in OS was 20/25. During the follow-up, OS did not develop lesions.

Patient P5—A 32-year-old man accessed the ophthalmic emergency service in 2010. BCVA was 20/32 in OD, and the fundoscopic examination revealed three peripheral RCHs with retinal detachment and a juxtapapillary fibrovascular membrane (Figure 4). Moreover, two small retinal lesions were detected in OS, and BCVA of OS was 20/20. The patient

underwent retinal surgery in OS (scleral buckle and transscleral cryotherapy); then, the lesions of both eyes were treated with multiple laser sessions. The CNS imaging revealed the presence of multiple cerebellar and spinal hemangioblastomas. In 2012, cataract surgery was performed in OD. In August 2019, BCVA was 20/20 OU, and regression of all the RCHs was observed.

Patient P8—In October 2019, visual impairment was diagnosed in a 14-year-old boy. BCVA was 20/20 and 20/640 in OD and OS, respectively. Four peripheral RCHs were detected in OD. In OS, multiple RCHs were present; the largest was located temporally, and it consisted in the coalescence of many RCHs. The visual impairment of OS was due to the severe exudative process which involved the macula. Moreover, FA revealed numerous microhemangioblastomas that could not be detected using other diagnostic techniques. Laser therapy was performed in OU, but vitreous hemorrhage occurred in OS. Therefore, three anti-VEGF IV (bevacizumab) and simultaneous transscleral cryotherapies were performed under general anesthesia. Many laser sessions were necessary to obtain regression of the RCHs. Further investigations revealed the presence of a cerebellar hemangioblastoma.

Patient P9—In 2005, a 32-year-old woman was examined at the clinic. The patient had been diagnosed in 2000 with multiple cerebellar and spinal hemangioblastomas. BCVA was 20/20 and 20/25 in OD and OS, respectively. No retinal abnormalities were found in OD. A peripheral superior RCH, already partially treated with laser photocoagulation, was observed in OS. FA showed the presence of many tiny RCHs that surrounded the major lesion. Further laser treatments were scheduled, but the patient was lost at follow-up. She

TABLE 2. GENETIC RESULTS.

Family ID	Coding DNA change	Exon	Effect Protein	Type	Pathogenicity Prediction	Reported in literatures
F1	c.461delC	2	p.Pro154Glnfs4*	Frameshift	Uncertain significance	Novel
F2	c.575C>T	3	p.Pro192Leu	Missense	Uncertain significance	Novel
F3	c.481C>T	3	p.Arg161Ter	Nonsense	Pathogenic	Yes
F4	c.337C>T	1	p.Arg113Ter	Nonsense	Pathogenic	Yes
F5	c.337C>T	1	p.Arg113Ter	Nonsense	Pathogenic	Yes
F6	c.341+1_341-1(463*1_?)	1-3	c.341+1_341-1(463*1_?)	Genomic deletion	Pathogenic	Yes
F7	c.355T>C	1	p.Phe119Leu	Missense	Pathogenic	Yes
F8	c.154G>T	1	p.Glu52Ter	Nonsense	Uncertain significance	Yes
F9	c.194C>G	1	p.Ser65Trp	Missense	Pathogenic	Yes
F10	c.524A>G	3	p.Tyr175Cys	Missense	Pathogenic	Yes

came to the ophthalmic emergency service three years later; BCVA of OS had decreased to 20/640, and she presented an exudative retinal detachment that involved the posterior pole. The partially treated RCH of OS had become more extensive, and FA revealed that the tiny RCHs had increased in number. In 2008, a scleral buckle with transscleral cryotherapy was performed in OS; however, at follow-up the retinal detachment was still present, and the patient developed neovascular glaucoma with a seclusio pupillae. Visual acuity of OS was no light perception. RCHs were not detected during follow-up in OD.

Patient P10—In 2009, a 37-year-old man accessed the emergency service, and a nasal retinal detachment was detected in OD. Multiple RCHs were present in all the quadrants; the biggest lesion was located nasally. It was made up of the coalescence of many tumors and measured approximately 4 optic disc diameters (DD). BCVA was 20/400, also

due to the presence of macular scars. CNS imaging detected multiple cerebellar and bulbar hemangioblastomas. Nasal scleral buckle and cryotherapy were performed, and several laser photocoagulation treatment sessions were performed. In 2012, the patient developed a new tractional retinal detachment in OD and NVG. Visual acuity of OD was nlp. At the last follow-up visit (in 2019), we did not detect RCHs in OS. Clinical details are summarized in Table 1.

DISCUSSION

We report different treatment techniques, long-term follow-up, and molecular tests of six patients with VHL syndrome who presented RCHs in eight eyes. The management and treatment of RCHs in VHL syndrome are not standardized. It is well-known that laser photocoagulation is the gold standard in the case of peripheral tumors smaller than 1 DD [8,13,15]. However, different approaches may be required

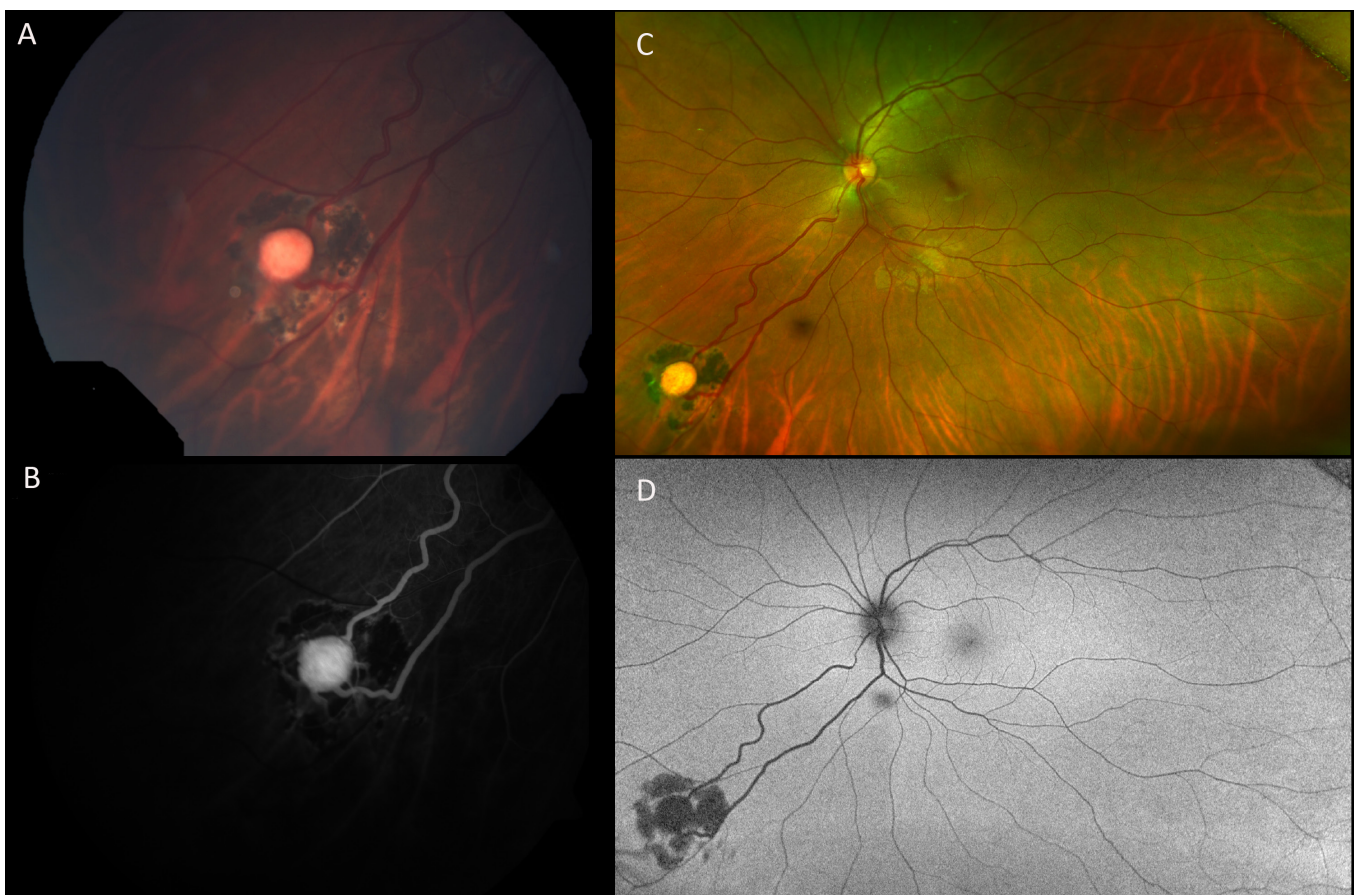


Figure 2. Patient P1. Color fundus photograph (A) shows the single peripheral RCH after one session of laser photocoagulation treatment (2015). Fluorescein angiography (FA; B) displays the feeder vessels and the early hyperfluorescence of the retinal capillary hemangioblastoma (RCH) lesion (2015). The ultrawide field (UWF) color fundus photograph (C) shows the inferonasal location of the RCH (2019). During follow-up, the lesion remained stable. UWF autofluorescence imaging (D) shows the retinal scar following the treatment (hypoautofluorescence lesion).

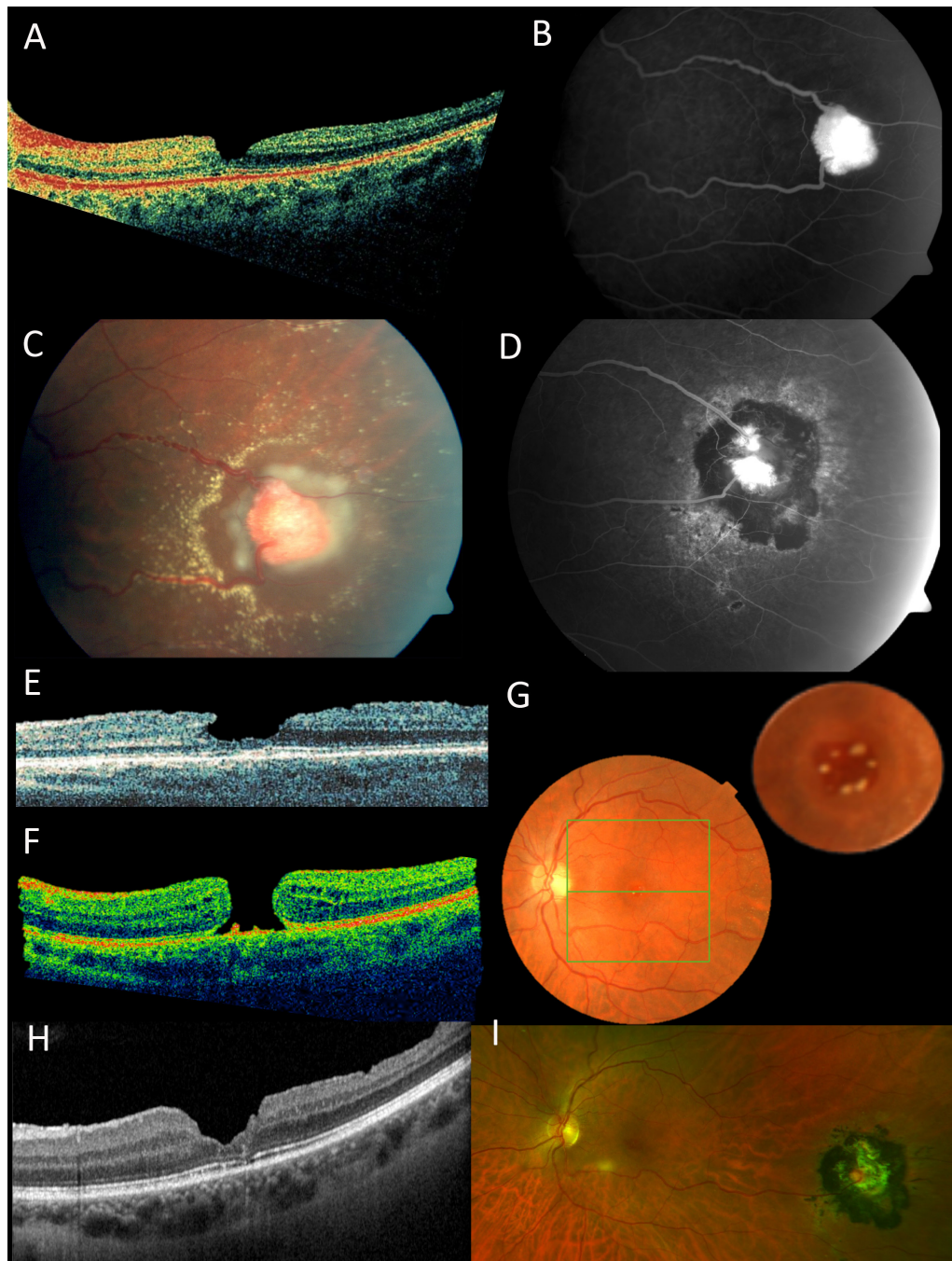


Figure 3. Patient P2. FA of the right eye of patient P2 shows the RCH (hyperfluorescence round lesion) before (B) and after (D) multiple laser sessions. The color fundus photograph shows the retinal capillary hemangioblastoma (RCH) after the first laser session (C). The optical coherence tomography (OCT) scan shows the irregularities of the inner retinal surface before treatment (pseudohole; 2009; A). Two months after the beginning of the laser treatment, the OCT scan shows a lamellar macular hole (E) and then a full-thickness macular hole (FTMH) in 2010 (F). In particular, hyperreflective abnormalities above the RPE can be seen in the bed of the hole (F) which appear as round yellowish lesions in the color fundus photograph (G). The yellow lesions are particularly evident in the magnified foveal image performed in 2012 which shows the increase in the number and size of the yellowish dots during follow-up (G). The OCT scan (H) shows the closure of the FTMH after vitrectomy. At the last follow-up visit in 2019, the ultrawide field (UWF) color fundus photograph (I) shows the RCH regression.

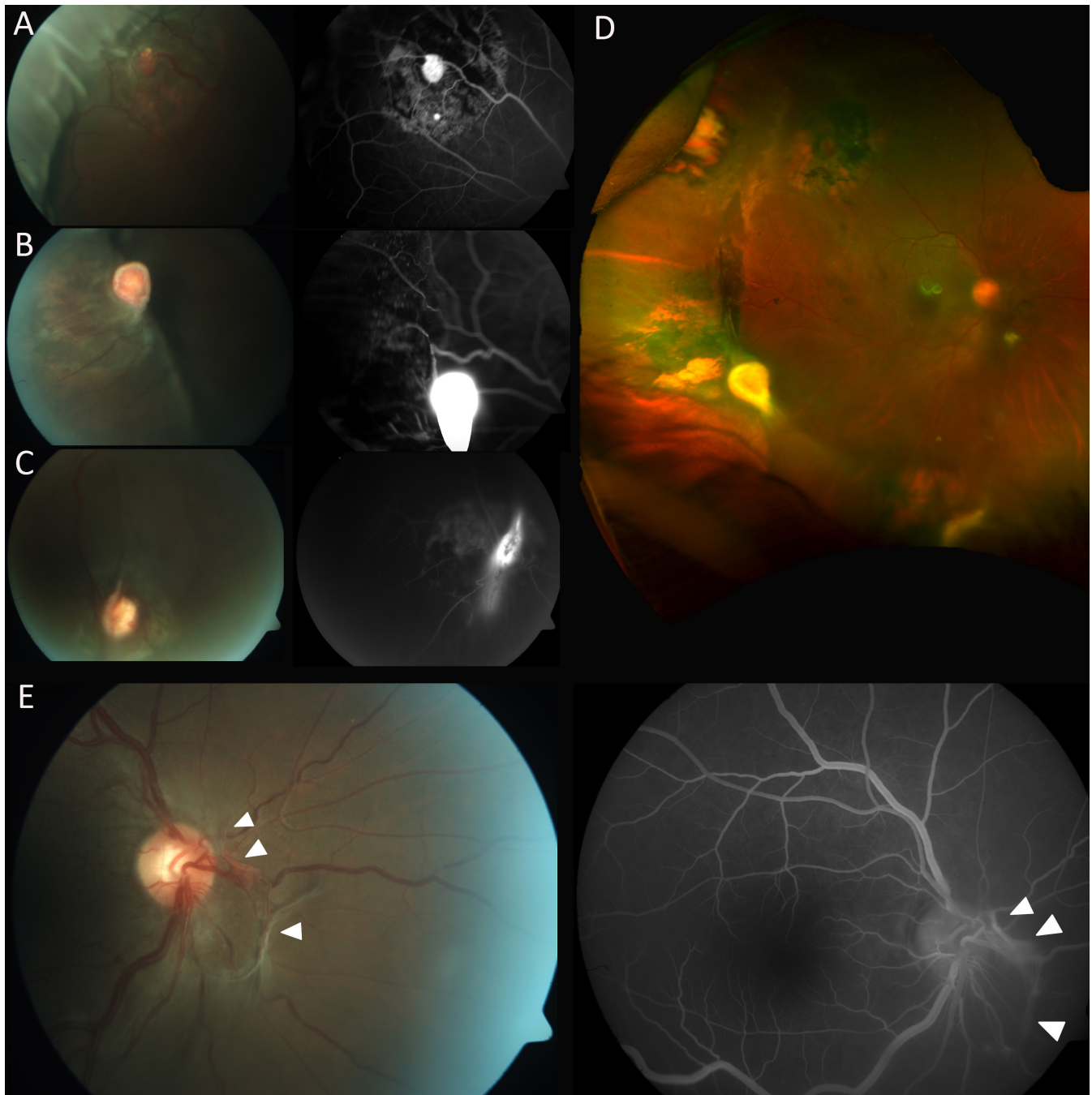


Figure 4. Patient P5. **A, B, C, D, E:** Color fundus photograph and FA of the right eye of patient P5. The color fundus photograph shows a well-positioned scleral buckle and three peripheral retinal capillary hemangioblastoma (RCHs) (**A, B, C**) with scarring on the surrounding retina due to the cryotherapy (2 weeks after surgery, in 2010). On the right, the fluorescein angiography (FA) images highlight the blood supply of the three RCHs after cryotherapy and laser. **A:** Peripheral RCH located at 11 o'clock. **B:** Peripheral RCH at 8 o'clock. **C:** Peripheral RCH at 6 o'clock. **D:** In 2019, ultrawide field (UWF) color fundus photography shows the effect of the scleral buckle and the peripheral three lesions at 6, 8, and 11 o'clock. **E:** Color fundus photograph and FA of the right eye show a juxtapapillary fibrovascular membrane (white arrowheads).

in some cases, such as RCHs localized adjacent to the optic disc or the macula, voluminous RCHs, and in cases of retinal detachment [8]. In the case of a large peripheral lesion, cryotherapy of the tumor is generally adopted as treatment. Nonetheless, there are no guidelines, or what additional, or alternative, therapeutic techniques should be used instead of laser photocoagulation for RCHs. Moreover, the definition of a successful treatment varies in literature. In a recent study, the American Academy of Ophthalmology defined as effective the treatment that determined normalization of the RCH feeder vessel diameters and an absence of RCH fluorescein leakage, detected using FA [8]. However, other parameters are described as valid, such as reduction of the tumor size. Observation and close follow-up can be effective management in selected cases [15,16]; spontaneous regression of an RCH and life-long quiescent RCHs have been reported [17].

In this study, all the detected RCHs were treated using laser photocoagulation of the lesions. However, in four eyes (4/8; 50%) of four patients (4/6; 67%) additional treatments were required: cryotherapy and anti-VEGF IV injections. Specifically, three eyes (3/8; 38%) of three patients (3/6; 50%) required retinal surgery due to the development of a retinal detachment. In the present series, a retinal detachment was present at diagnosis in two eyes of two patients (P5 and P9), while it developed in OD of patient P9, who was lost at follow-up for 3 years. The patients all underwent episcleral surgery and concomitant transscleral cryotherapy. Patient P5 reached a final visual acuity of 20/20, and surgery was successful. However, chronic retinal detachment, NVG, and vision loss developed in two eyes of two patients (P9, P10). These two eyes also developed tiny new multiple retinal lesions, detectable using FA, showing progression of the ocular VHL disease.

The exudative and tractional effects of RCHs on the retina, and consequent retinal detachments, are the major causes of vision loss in patients with VHL syndrome [11]. Although pars plana vitrectomy has shown a good success rate for retinal detachment [18,19], there are few specific studies in literature on the results of episcleral surgery with a large number of patients with VHL syndrome.

No relapses or new lesions occurred in the remaining six eyes with RCHs, or in the contralateral eyes without RCHs (at diagnosis) during follow-up. In particular, among the four patients with unilateral RCHs at presentation, we did not detect the development of any further ophthalmic lesions during the mean follow-up of 99 months. Similarly, we did not observe any ocular involvements in the eyes of the 11 patients with VHL syndrome with no RCHs at presentation during the mean follow-up of 101 months.

Different prevalence rates of new RCH development during follow-up in already treated eyes have been reported [7,11,13,15]. From the present results, it is therefore unlikely that patients with no ocular tumors at presentation progress to ophthalmic involvement in VHL syndrome within a period of approximately 8 years.

In fact, a second mutation of the *VHL* gene, or “second hit,” is necessary in the cells of the tissue that develop VHL-related tumors: Only when a second mutation procedure in the somatic cells is added to the first mutation, which generally happens in the germinal cells, does the VHL protein lose its function, and the tumor develop [3]. Although the development of a VHL tumor in a new tissue may not necessarily occur, or it can require a long time to develop, periodic follow-up is mandatory.

An uncommon manifestation of VHL ocular syndrome, distinct from an RCH lesion, consists of tiny new peripapillary vessels that may become a fibrotic proliferation or cause an epiretinal membrane (ERM) [20]. Their pathogenic mechanism may lie in the fact that the second mutation in the *VHL* gene affects a different cell precursor from the one that causes RCH to develop [20]. In the right eye of patient P5, a juxtapapillary fibrovascular membrane was detected at presentation. The fibrovascular complex was stable, without tractional effects on the retina or an increase in the vessel diameter size or number, during the 109 months of follow-up.

The presence of ERMs has been described in literature associated with VHL ocular involvement, in a few cases also leading to the formation of a macular hole [21,22]. This condition is attributable to the RCH therapy (laser or cryotherapy treatment) [21,22]; however, ERMs have also been described in eyes with still untreated RCHs [23]. It has been hypothesized that an ERM formation could be due to the biologic behavior of VHL syndrome; an electron-microscopic analysis of an excised ERM showed abnormal remodeling of collagenous stroma in VHL disease [22,23]. The ERM is usually removed surgically; however, a complete spontaneous separation of the membrane from the retinal surface, with normalization of the retinal profile, has been described as a rare event in VHL syndrome [22,23], and in one case, resolution of the ERM occurred after laser photocoagulation of the RCH [23].

In the present study, patient P2 presented with a macular pseudohole and a peripheral RCH at diagnosis. After 2 months, and multiple laser sessions, the pseudohole evolved to an LMH and in less than 1 year, to a FTMH. It is interesting to notice the presence of tiny yellowish deposits in the macular hole bed, also visible at the OCT scan; they disappeared after vitrectomy which resulted in FTMH closure. Similar

deposits, also described as Klein's tags [24], were observed in idiopathic holes, and their significance is uncertain [25]. However, they have been related to proliferations of RPE, caused by RPE exposure to the vitreous, or deposits of macrophages containing eosinophilic or lipofuscin material [25,26]. Their formation may be related to the inflammatory response following laser photocoagulation. Tiny yellowish deposits associated with FTMH have also been reported in six out of 17 eyes that developed FTMH after momentary exposure to high-power handheld blue lasers [26]. These findings suggest that vitreous-related dynamics may be altered in the eyes that develop RCHs, and these modifications can easily lead to the formation of a vitreomacular interface disease. Not only could the VHL disease itself change the physiologic anatomy of the vitreous, but the RCH could also directly perform a tractional effect on the retina. Finally, the laser photocoagulation treatment, and the following inflammation, may trigger further changes in an already altered vitreoretinal balance.

We report a new frameshift mutation in *VHL* in patient P1: c.461delC (p.Pro154Glnfs4*). This mutation is peculiar because the proline residue is normally highly conserved in individuals and families with VHL syndrome. Moreover, the residues from 63 to 154 form the seven-stranded β sandwich of the β domain, and in detail, p154 is the last codon located in the loop that connects the β to the α domain of the VHL protein [27]. Thus, this site could cause an important alteration in the final conformation of the VHL protein [27]. In addition, the family segregation showed that this is also a de novo mutation. De novo mutations are described in fewer than one out of four patients with VHL syndrome [4,28]. However, studies conducted on the Chinese population suggested the possibility of a higher percentage, up to 56.3%, of sporadic mutations in the *VHL* gene [29]. In the present case series, three out of five patients where both parents were molecularly tested (P1, P8, and P10) carried a de novo mutation suggesting the possibility of a higher percentage than that described in literature. The mutation c.575C>T, (p.Pro192Leu) has been described in ClinVar; however, it is not reported in literature. We have described the clinical picture associated with this mutation.

Considering possible phenotype–genotype associations, different studies have searched for correlations between the mutation in *VHL* and the prevalence or the severity of ocular involvement, showing contradictory results [30]. It has been reported that complete protein deletions have the lowest prevalence of RCHs and the best prognosis in terms of visual outcome, when compared to other mutations in *VHL* [2]. In addition, truncating mutations (deletions, insertions, frameshift, and splice-site mutations) have shown a higher

prevalence of ocular disease compared to missense mutations [2,31]. Missense mutations, however, were related to a higher number of RCHs and complications [7,31]; a radical early treatment and more frequent follow-up, therefore, were indicated for patients carrying missense mutations [31]. In the present series, five out of six patients carrying a truncating mutation showed ocular involvement, and only one out of four patients carrying a missense mutation developed ocular lesions. A higher prevalence of the ophthalmic disease could be observed for truncating mutations in this series. However, severe disease (presence of multiple RCHs and eventual bilateral disease) was present in four out of six patients: Three carried nonsense mutations and one a deletion. Therefore, these data differ from the results of previous studies, as nonsense mutations and deletion of the VHL protein were associated with bilateral and multiple RCHs or worse visual prognosis or both (P8, P5, P9, and P10) in the patients with VHL syndrome in the present study. It is likely that other unknown factors, other than the genotype, are responsible for the phenotype variability in ocular VHL disease.

In conclusion, patients with multiple RCHs, who developed RCH secondary effects, showed truncating mutations of the VHL protein. We recommend early screening and close monitoring, especially if RCHs are detected at presentation, for every patient with VHL syndrome, independently of the results of the molecular test for a missense or a truncating mutation in *VHL*. Furthermore, in the present patients we report that vitreoretinal interface abnormalities may be related to VHL disease and RCH therapy.

REFERENCES

1. Lonser RR, Glenn GM, Walther M, Chew EY, Libutti SK, Linehan WM, Oldfield EH. von Hippel-Lindau disease. *Lancet* 2003; 361:2059-67. [PMID: 12814730].
2. Wong WT, Agrón E, Coleman HR, Reed GF, Csaky K, Peterson J, Glenn G, Linehan WM, Albert P, Chew EY. Genotype-phenotype correlation in von Hippel-Lindau disease with retinal angiomas. *Arch Ophthalmol* 2007; 125:239-45. [PMID: 17296901].
3. Knudson AG Jr. Mutation and cancer: statistical study of retinoblastoma. *Proc Natl Acad Sci USA* 1971; 68:820-3. [PMID: 5279523].
4. Richards FM, Payne SJ, Zbar B, Affara NA, Ferguson-Smith MA, Maher ER. Molecular analysis of de novo germline mutations in the von Hippel-Lindau disease gene. *Hum Mol Genet* 1995; 4:2139-43. [PMID: 8589692].
5. Roe JS, Kim H, Lee SM, Kim ST, Cho EJ, Youn HD. p53 stabilization and transactivation by a von Hippel-Lindau protein. *Mol Cell* 2006; 22:395-405. [PMID: 16678111].

6. Latif F, Tory K, Gnarr J, Yao M, Duh FM, Orcutt ML, Stackhouse T, Kuzmin I, Modi W, Geil L. Identification of the von Hippel-Lindau disease tumor suppressor gene. *Science* 1993; 260:1317-20. [PMID: 8493574].
7. Dollfus H, Massin P, Taupin P, Nemeth C, Amara S, Giraud S, Bérout C, Dureau P, Gaudric A, Landais P, Richard S. Retinal hemangioblastoma in von Hippel-Lindau disease: a clinical and molecular study. *Invest Ophthalmol Vis Sci* 2002; 43:3067-74. [PMID: 12202531].
8. Krivosic V, Kamami-Levy C, Jacob J, Richard S, Tadayoni R, Gaudric A. Laser Photocoagulation for Peripheral Retinal Capillary Hemangioblastoma in von Hippel-Lindau Disease. *Ophthalmol Retina*. 2017; 1:59-67. [PMID: 31047395].
9. Maher ER, Yates JR, Harries R, Benjamin C, Harris R, Moore AT, Ferguson-Smith MA. Clinical features and natural history of von Hippel-Lindau disease. *Q J Med* 1990; 77:1151-63. [PMID: 2274658].
10. Singh AD, Shields CL, Shields JA. von Hippel-Lindau disease. *Surv Ophthalmol* 2001; 46:117-42. [PMID: 11578646].
11. Kreusel KM, Bechrakis NE, Krause L, Neumann HP, Foerster MH. Retinal angiomatosis in von Hippel-Lindau disease: a longitudinal ophthalmologic study. *Ophthalmology* 2006; 113:1418-24. [PMID: 16769118].
12. Chen X, Sanfilippo CJ, Nagiel A, Hosseini H, Mitchell D, McCannel CA, Schwartz SD, McCannel TA. EARLY DETECTION OF RETINAL HEMANGIOBLASTOMAS IN VON HIPPEL-LINDAU DISEASE USING ULTRA-WIDEFIELD FLUORESCIN ANGIOGRAPHY. *Retina* 2018; 38:748-54. [PMID: 28368975].
13. Schmidt D, Natt E, Neumann HP. Long-term results of laser treatment for retinal angiomatosis in von Hippel-Lindau disease. *Eur J Med Res* 2000; [PMID: 10720563].
14. Li Q, Wang K. InterVar: Clinical Interpretation of Genetic Variants by the 2015 ACMG-AMP Guidelines. *Am J Hum Genet* 2017; 100:267-80. [PMID: 28132688].
15. Singh AD, Nouri M, Shields CL, Shields JA, Perez N. Treatment of retinal capillary hemangioma. *Ophthalmology* 2002; 109:1799-806. [PMID: 12359597].
16. Wiley HE, Krivosic V, Gaudric A, Gorin MB, Shields C, Shields J, Aronow ME, Chew EY. MANAGEMENT OF RETINAL HEMANGIOBLASTOMA IN VON HIPPEL-LINDAU DISEASE. *Retina* 2019; 39:2254-63. [PMID: 31259811].
17. Whitson JT, Welch RB, Green WR. Von Hippel-Lindau disease: case report of a patient with spontaneous regression of a retinal angioma. *Retina* 1986; 6:253-9. [PMID: 3554423].
18. Gaudric A, Krivosic V, Duguid G, Massin P, Giraud S, Richard S. Vitreoretinal surgery for severe retinal capillary hemangiomas in von hippel-lindau disease. *Ophthalmology* 2011; 118:142-9. [PMID: 20801520].
19. Avci R, Yilmaz S, Inan UU, Kaderli B, Cevik SG. Vitreoretinal surgery for patients with severe exudative and proliferative manifestations of retinal capillary hemangioblastoma because of Von Hippel-Lindau disease. *Retina* 2017; 37:782-8. [PMID: 27533771].
20. Wong WT, Yeh S, Chan CC, Kalina RE, Kinyoun JL, Folk JC, Coleman HR, Chew EY. Retinal vascular proliferation as an ocular manifestation of von Hippel-Lindau disease. *Arch Ophthalmol* 2008; 126:637-43. [PMID: 18474773].
21. Loewenstein JI. Bilateral macular holes in von Hippel-Lindau disease. *Arch Ophthalmol* 1995; 113:143-4. [PMID: 7864744].
22. Inoue M, Yamazaki K, Shinoda K, Ishida S, Shinoda H, Noda K, Oguchi Y. A clinicopathologic case report on macular hole associated with von Hippel-Lindau disease: a novel ultra-structural finding of wormlike, wavy tangles of filaments. *Graefes Arch Clin Exp Ophthalmol* 2004; 42:881-6. [PMID: 15052488].
23. Kolomeyer AM, Eller AW, Martel JN. Spontaneous resolution of macular epiretinal membranes after fluorescein potentiated argon laser treatment of Von Hippel-Lindau associated retinal hemangiomas: case report and review of literature. *Retin Cases Brief Rep* 2016; 10:145-50. [PMID: 26421964].
24. Friedman NJ, Kaiser PK. Posterior Segment. In: *Case Reviews in Ophthalmology*; 2018.
25. Dhoot DS. Gass' Atlas of Macular Diseases. *Br J Ophthalmol*. 2012.
26. Alsulaiman SM, Alrushood AA, Almasaud J, Alkharashi AS, Alzahrani Y, Abboud EB, Nowilaty SR, Arevalo JF, Al-Amry M, Alrashaed S, Ghazi NG. King Khaled Eye Specialist Hospital Collaborative Retina Study Group. Full-Thickness Macular Hole Secondary to High-Power Handheld Blue Laser: Natural History and Management Outcomes. *Am J Ophthalmol* 2015; 160:107-13.e1. [PMID: 25892126].
27. Ercolino T, Becherini L, Valeri A, Maiello M, Gagliano MS, Parenti G, Ramazzotti M, Piscitelli E, Simi L, Pinzani P, Nesi G, Degl'Innocenti D, Console N, Bergamini C, Mannelli M. Uncommon clinical presentations of pheochromocytoma and paraganglioma in two different patients affected by two distinct novel VHL germline mutations. *Clin Endocrinol (Oxf)* 2008; 68:762-8. [PMID: 18031321].
28. Sgambati MT, Stolle C, Choyke PL, Walther MM, Zbar B, Linehan WM, Glenn GM. Mosaicism in von Hippel-Lindau disease: lessons from kindreds with germline mutations identified in offspring with mosaic parents. *Am J Hum Genet* 2000; 66:84-91. [PMID: 10631138].
29. Wang X, Zhang N, Ning X, Li T, Wu P, Peng S, Fan Y, Bu D, Gong K. Higher prevalence of novel mutations in VHL gene in Chinese Von Hippel-Lindau disease patients. *Urology* 2014; 83:675.e1-5. [PMID: 24581539].
30. Wittström E, Nordling M, Andréasson S. Genotype-phenotype correlations, and retinal function and structure in von Hippel-Lindau disease. *Ophthalmic Genet* 2014; 35:91-106. [PMID: 24555745].
31. Hajjaj A, van Overdam KA, Oldenburg RA, Koopmans AE, van den Ouweland AMW, de Klein A, Kiliç E. Retinal haemangioblastomas in von Hippel-Lindau germline

mutation carriers: progression, complications and treatment

outcome. *Acta Ophthalmol* 2020; 98:464-71. [PMID: [32003155](https://pubmed.ncbi.nlm.nih.gov/32003155/)].

Articles are provided courtesy of Emory University and the Zhongshan Ophthalmic Center, Sun Yat-sen University, P.R. China. The print version of this article was created on 2 September 2021. This reflects all typographical corrections and errata to the article through that date. Details of any changes may be found in the online version of the article.